Print ISSN: 2321-6379
Online ISSN: 2321-595X

Original Article

Ventriculoperitoneal Shunt Surgery and the Incidence of Shunt Revision in Pediatric Patients

Sheik Mohammed Sameer Khan[1], Rjvv Prasad[2], Asit Roy[1], Rajachaitanya Reddy[1], R. Veerapandian[3]

[1]Postgraduate, Department of Neurosurgery, Madurai Medical College and Government Rajaji Hospital, Madurai, Tamil Nadu, India, [2]Consultant Neurosurgeon, Department of Neurosurgery, Velammal Medical College, Madurai, Tamil Nadu, India, [3]Professor and Head, Department of Neurosurgery, Madurai Medical College and Government Rajaji Hospital, Madurai, Tamil Nadu, India

Abstract

Introduction: Ventriculoperitoneal shunt (VPS) insertion for the treatment of hydrocephalus is associated with several complications including infections, mechanical failure, obstruction, bowel perforation with or without extrusion through natural orifices, nonvisceral perforation, shunt migrations, and shunt disconnection. Many of these complications occurring following VPS implantation require shunt revision, and the requirement of revisions is significantly more in pediatric patients compared to adults.

Objective: The objective of the study was to analyze 100 cases of hydrocephalus, their etiology, VPS failures, and incidence of shunt revision in pediatric population.

Materials and Methods: We selected 100 cases of pediatric patients who underwent shunt surgeries for various reasons and presented with complication of the procedure. Demographic details, etiology of first shunt surgery, causes for shunt failure, and age at which revision of shunt done are tabulated and analyzed. In our study, we have either done revision of shunt on same side, the other side or endoscopic third ventriculostomy (ETV).

Results: Out of 100 cases studied, the most common cause for shunt surgery was post-meningitis hydrocephalus, and most common age at first surgery was <3 months. Upper end failure was most common reason for shunt failure, age at revision was 2–5 years, and lower end failure is reason for most of multiple shunt revisions. Most of the patients underwent revision on same side, followed by opposite side, ETV, shunt removal, etc.

Conclusion: VPS procedure is the mainstay treatment for hydrocephalus in pediatric age group, but in long term it is often associated with manifold complications which necessitate its revision.

Key words: Shunt failures, Shunt related complications, Shunt revision, Ventriculoperitoneal shunt

INTRODUCTION

Hydrocephalus has been described in medical writings since the time of Hippocrates. In 1914, Dandy and Blackfan[1] first established the pathology of hydrocephalus and developed sound anatomical, physiological, and surgical principles for its treatment. In 1955, Scott *et al.*[2] described the use of a ventriculoperitoneal shunt (VPS). Scarf[3] tabulated the published results of the different methods up to 1963; he found a strong tendency for the VPS to become obstructed at the distal end and a high incidence (30–50%) of permanent failures.

Access this article online

IJSS

www.ijss-sn.com

Month of Submission : 02-2021
Month of Peer Review : 03-2021
Month of Acceptance : 03-2021
Month of Publishing : 04-2021

Ventriculoperitoneal shunt (VPS) insertion for the treatment of hydrocephalus is associated with several complications including infections, mechanical failure, obstruction, bowel perforation with or without extrusion through natural orifices, nonvisceral perforation, shunt migrations, and shunt disconnection.[4-6] Many of these complications occurring following VPS implantation require shunt revision, and the requirement of revisions is significantly more in pediatric patients compared to adults.[4,6]

Objective

The objective of the study was to analyze 100 cases of hydrocephalus, their etiology, VPS failures, and incidence of shunt revision in pediatric population.

Corresponding Author: Dr. Rjvv Prasad, Department of Neurosurgery, Velammal Medical College, Madurai, Tamil Nadu, India.

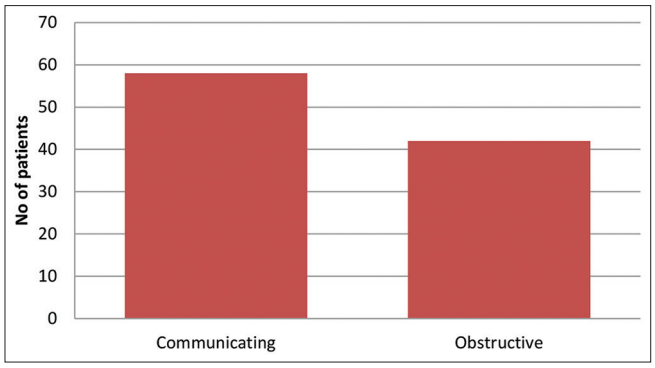

Graph 1: Type of hydrocephalus

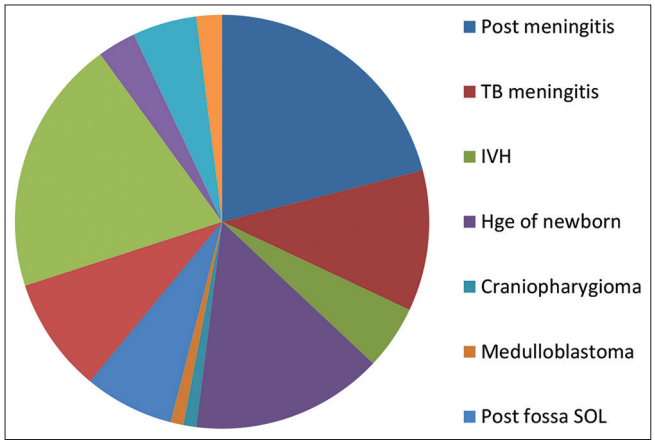

Graph 2: Etiology of hydrocephalus and indication for ventriculoperitoneal shunt surgery

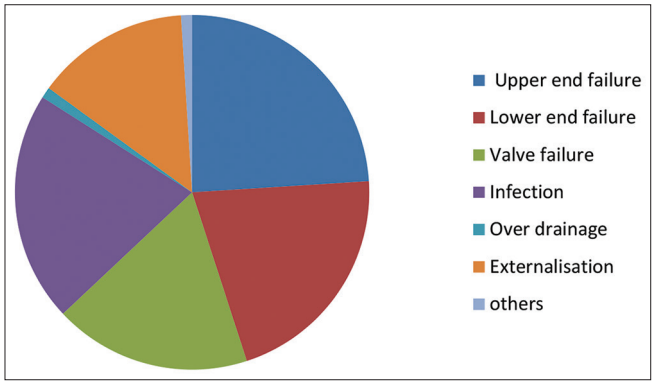

Graph 3: Various causes of shunt revision

MATERIALS AND METHODS

We selected 100 cases of pediatric patients who underwent shunt surgeries for various reasons and presented with complication of the procedure. Demographic details, etiology of first shunt surgery, causes for shunt failure, and age at which revision of shunt done are tabulated and analyzed. In our study, we have either done revision of shunt on same side, the other side or endoscopic third ventriculostomy (ETV).

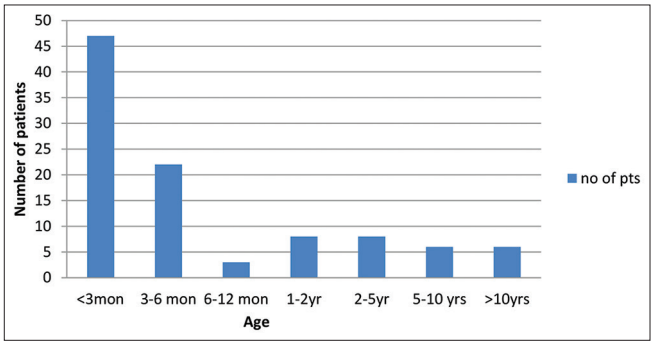

Graph 4: Age at which first shunt was done

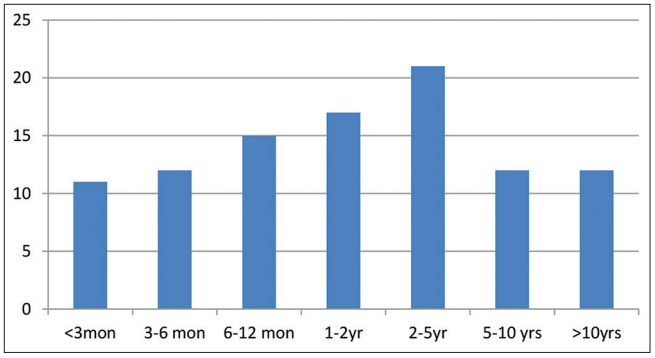

Graph 5: Age ranges at which shunt revision was done

RESULTS

Out of 100 cases studied, the most common cause for shunt surgery was post-meningitis hydrocephalus, and most common age at first surgery was <3 months. Upper end failure was most common reason for shunt failure, age at revision was 2–5 years, and lower end failure is reason for most of multiple shunt revisions. Most of the patients underwent revision on same side, followed by opposite side, ETV, shunt removal, etc.

DISCUSSION

In our study, 58 cases were communicating and rest were obstructive type of hydrocephalus [Graph 1]. The spectrum etiology with which they presented is tabulated in Graph 2. All the cases underwent right VPS surgery at the time of presentation.

Most of the cases were due to meningitis, communicating hydrocephalus of which major portion was due to tuberculosis, followed by hemorrhagic disease of new born [Graph 3]. Children younger than 3 months of age underwent shunt surgeries for the 1st time, followed by age between 3 and 6 months [Graphs 4 and 5].

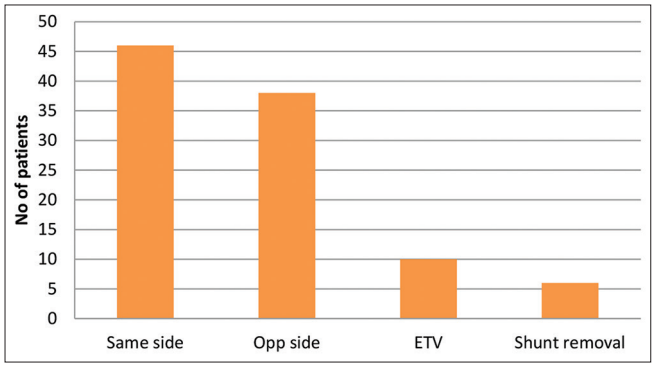

Graph 6: Methods of shunt revision done

Figure 1: (a) Clinical picture of baby showing progressive head size in spite of shunt in situ, (b) skin erosions over reservoir, (c) computed tomography scan of the baby showing unresolved hydrocephalus with shunt *in situ*, (d) erect X-ray of abdomen shows lower end failure in the form entangled shunt tube

Most of the shunt system dysfunction is due to upper end failure [Figure 1], followed by lower end failure [Figure 2], but cause for multiple shunt revision surgeries is due to lower end failure. Few of miscellaneous causes include peritubal effusion [Figure 3].

In as many as 46 patients, revision is done on same side either by upper or lower end revision alone or replacing the entire shunt system on same side. However, 38 patients underwent revision on opposite side. ETV is done in ten

Figure 2: Pictures showing extrusion of shunt tube through anal canal

Figure 3: Clinical pictures of a boy with shunt tube disconnection and peritubal effusion

patients and permanent shunt removal done in remaining six patients who became shunt independent [Graph 6].

CONCLUSION

This retrospective study evaluates various complications associated with VPS surgeries in pediatric population. We found that upper end failures are the common cause for shunt failure and shunt infection remains an avoidable cause for the same. However these complications can be avoided by proper pre-operative assessment, adopting periprocedural sterile environment, and meticulous surgical techniques.

ACKNOWLEDGMENT

Since we come across many cases of congenital hydrocephalus in our institute, we did a retrospective study in ventriculoperitoneal surgery and its complications. We wish to share our experience of 100 such cases through your esteemed journal publication.

REFERENCES

1. Dandy WE, Blackfan KD. Internal hydrocephalus: An experimental, clinical and pathological study. Am J Dis Child 1914;8:406-82.
2. Scott M, Wycis HT, Murtagh F, Reyes V. Observations on ventricular and lumbar subarachnoid peritoneal shunts in hydrocephalus in infants. J Neurosurg 1955;12:165-75.
3. Scarff JE. Treatment of hydrocephalus: An historical and critical review of methods and results. J Neurol Neurosurg Psychiatry 1963;26:1-26.
4. Paff M, Alexandeu-Abrams D, Muhonen M, Loudon W. Ventriculoperitoneal shunt complications: A review. Interdiscip Neurosurg 2018;13:66-70.
5. Lee L, Low S, Low D, Ng LP, Nolan C, Seow WT, *et al*. Late pediatric ventriculoperitoneal shunt failures: A singapore tertiary institution's experience. Neurosurg Focus 2016;41:E7.
6. Ghritlaharey RK, Budhwani KS, Shrivastava DK, Srivastava J. Ventriculoperitoneal shunt complications needing shunt revision in children: A review of 5 years of experience with 48 revisions. Afr J Paediatr Surg 2012;9:32-9.

How to cite this article: Khan SMS, Prasad RJV, Roy A, Reddy R. Ventriculoperitoneal Shunt Surgery and the Incidence of Shunt Revision in Pediatric Patients. Int J Sci Stud 2021;9(1):103-106.

Source of Support: Nil, **Conflicts of Interest:** None declared.