Print ISSN: 2321-6379
Online ISSN: 2321-595X

Original Article

Close Reduction and Percutaneous Pinning in NEER Type 2 and 3 Proximal Humerus Fractures in Adults

Satyajit Mura[1], Arnab Karmakar[2], Tanmay Datta[2], Dibyendu Biswas[2], A. K. Pal[3]

[1]RMO, Department of Orthopaedics, Midnapore Medical College and Hospital, Midnapore, Kolkata, India, [2]Associate Professor, Department of Orthopaedics, Institute of Post Graduate Medical Education and Research, Seth Sukhlal Karnani Memorial Hospital, Kolkata, West Bengal, India, [3]Professor, Department of Orthopaedics, Institute of Post Graduate Medical Education and Research, Seth Sukhlal Karnani Memorial Hospital, Kolkata, West Bengal, India

Abstract

Introduction: Proximal humeral fractures account for 4–5% of all fractures. Open reduction and internal fixation entail an extensive surgical exposure and risks damage to the vascular supply of the fragments. Closed reduction and percutaneous pinning (CRPP) have a low risk of neurovascular complications or interference with glenohumeral joint motion.

Materials and Methods: Thirty patients with proximal humeral fracture were taken into consideration and treated with CRPP. Patients were assessed using Constant-Murley score (CMS) (pain, activity of daily living, range of motion, strength).

Results and Analysis: There was excellent outcome = 36.4% (4) and good = 63.6% (7) of patients (11) in NEER' type 2 group and in type 3 group, there was excellent = 26.3% (5), good = 57.9% (11), fair = 10.5 (2), and poor = 5.3% (1) of patients (19) according to CMS.

Conclusion: CRPP of proximal humerus fractures in adults is a viable alternative modality of treatment as this method possess affordability, minimal invasive, stable construct pertaining good control of infection, shorter hospital stays, early return to work, and easy implant removal under local anesthesia and most importantly easy to learn and reproducible.

Key words: External fixation, K-wires, NEER type, Percutaneous pinning

INTRODUCTION

Proximal humeral fractures account for 4–5% of all fractures; most of them involving elderly and osteoporotic people. About 51% of such fractures are displaced. Fractures with minimal displacement, regardless of the number of fracture lines, can be treated with closed reduction and early mobilization, but anatomical reduction in displaced fractures is difficult to obtain and the incidence of pseudarthrosis is high.[1,2]

Open reduction and internal fixation entail an extensive surgical exposure and risks damage to the vascular supply of the fragments. Fixed angle locking plates enable fixation of many complex fractures although their long-term functional outcomes remain unknown. It provides early functional recovery, but we had to pay special attention to some of the surgical details to minimize complications.[3-9] Locked intramedullary nails can be inserted using a minimally invasive technique but associated with the risk of proximal impingement.[10-15]

Closed reduction and percutaneous pinning (CRPP) have a low risk of neurovascular complications or interference with glenohumeral joint motion.[16-25] Transcutaneous reduction and external fixation achieve a satisfactory fracture stability once closed reduction is achieved, safer healing, superior functional result, low cost, and less patient morbidity as compared to conservative treatment.[26-50] We evaluated the results of close reduction and external fixation of proximal humeral fractures in adults.

In this study, we evaluated the role of CRPP in the management of proximal humerus fractures in adults for effective functional recovery of shoulder.

Access this article online

www.ijss-sn.com

Month of Submission : 12-2020
Month of Peer Review : 12-2020
Month of Acceptance : 01-2021
Month of Publishing : 02-2021

Corresponding Author: Dr. Arnab Karmakar, Cloud 9, Flat No-6A, Nimbus Block, 4 Bhukailash Road, Mominpore, Kolkata - 700023, India.

MATERIALS AND METHODS

We conducted the study at the Orthopaedics Department of Institute of Post Graduate Medical Education and Research and S.S.K.M. Hospital, Kolkata-20, from January 2015 to August 2016. In this prospective longitudinal study, 30 patients with proximal humeral fracture were taken into consideration and treated with CRPP. Minimum follow-up period was 6 months (6–20 months).

Operated patients were assessed using Constant-Murley score (CMS) (pain, activity of daily living, range of motion, strength).

Patients age, sex, fracture duration, NEER' type, etc., were taken into consideration. Average age of our study population was 48.57 years. Majority were female 16 (53.3%) and 14 (47.7%) were male. Frequency of NEER' type 3 was more 19 (63.30%) and type 2 was 11 (36.70%).

Only NEER type 2 and 3 fractures were included in the study. We excluded any head split fracture, fracture with dislocation, and fracture with significant bone loss requiring bone grafting and untreated fracture more than 3 weeks old.

Surgical Technique

Under regional or general anesthesia, manipulation done and the fracture is reduced. Reduction is checked with C-arm in both the views. Reduction is maintained with gentle traction [Figure 1a and b]. Then 3 kires are planned to be inserted as- the first one just lateral to bicipital groove, the other one in true lateral plane, and the third one posterior to the central one. The shoulder kept externally rotated during placement of the greater tuberosity K-wire so as to move the axillary nerve and the posterior circumflex artery farther away from the humeral neck. Three threaded K-wires were inserted in the shaft of humerus 2 cm distal to the fracture line in the same horizontal plane: Central one in true lateral plane, another one at 30° anteriorly, and the other one at 30° posteriorly. One K-wire inserted just proximal to the lateral k-wire in line with the central K-wire of head and proximal shaft. Aim of reduction was to bring the fragment in an acceptable position, i.e., <45° of angulation and <1 cm of displacement, and to hold these fragments in place [Figure 2a and b]. After fixing with sufficient numbers of K-wires, link joints and connecting rods are attached and the final frame is formed [Figure 3].

Following instruments are required:

External stabilization system with the associated instrumentation set including:

- Threaded K-wires, 2–2.5 mm thick
- Link joints of stainless-steel blocks with 2 offset holes to which K-wires and connecting rods are clamped
- Connecting rods, 3–4 mm in diameter and of suitable lengths
- Allen keys
- K-wire bender
- K-wire cutter
- Power drill/T handle.

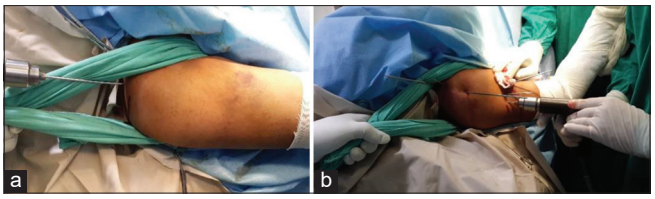

Figure 1: (a) Reduction followed by superior K-wires insertion (b) anterior and lateral K-wire

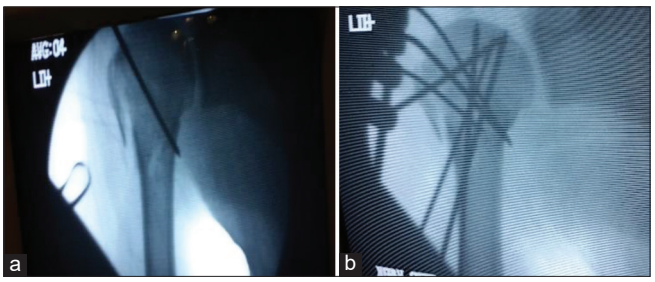

Figure 2: (a) Confirmation by C-ARM (b) final construct C-ARM picture

Figure 3: Final construct

Rehabilitation started as soon as pain tolerance. Patients were encouraged to start shoulder and elbow mobilizing exercises. Special importance was given to prevent pin tract infection by doing regular dressing with saline and application of gentamycin drops locally.

Patients were followed at 4 weeks, 6 weeks, 8 weeks, and then 4 weekly intervals, looking for clinical and radiological union, movements achieved, CMS and for complications if any [Figures 4 and 5].

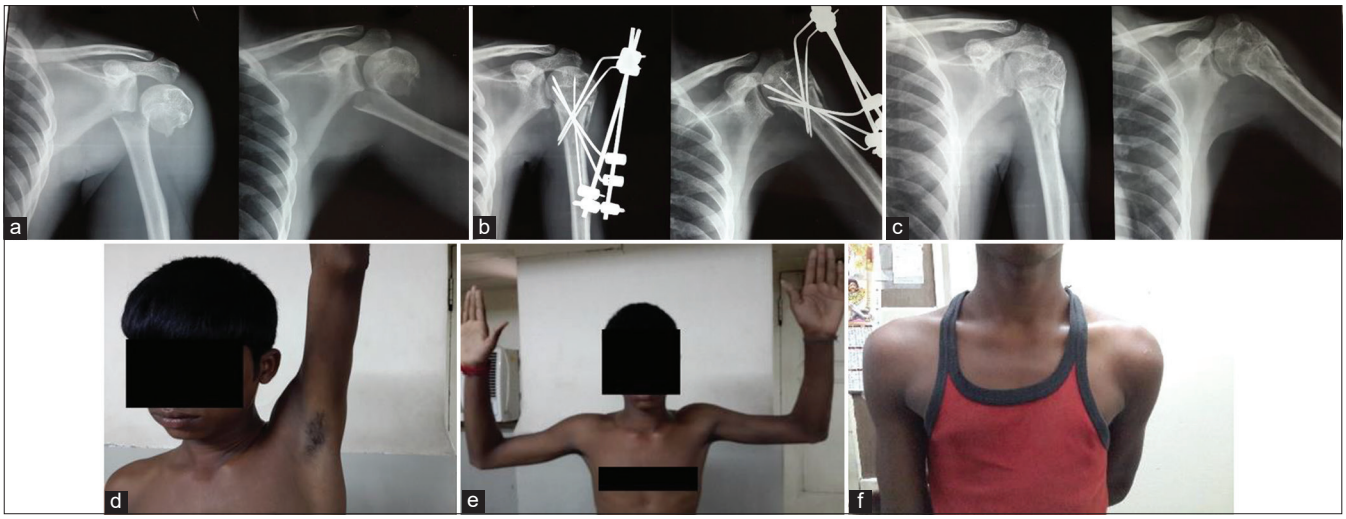

Figure 4: (a) Case 1-19 years male pre of X-ray AP/lat, (b) Case 1–6 weeks post-operative X-ray, (c) Case 1 – X-ray after implant removal, (d) Case 1 – final ROM elevation, (e) Case 1 – final ROM external rotation, (f) Case 1 – final ROM internal rotation

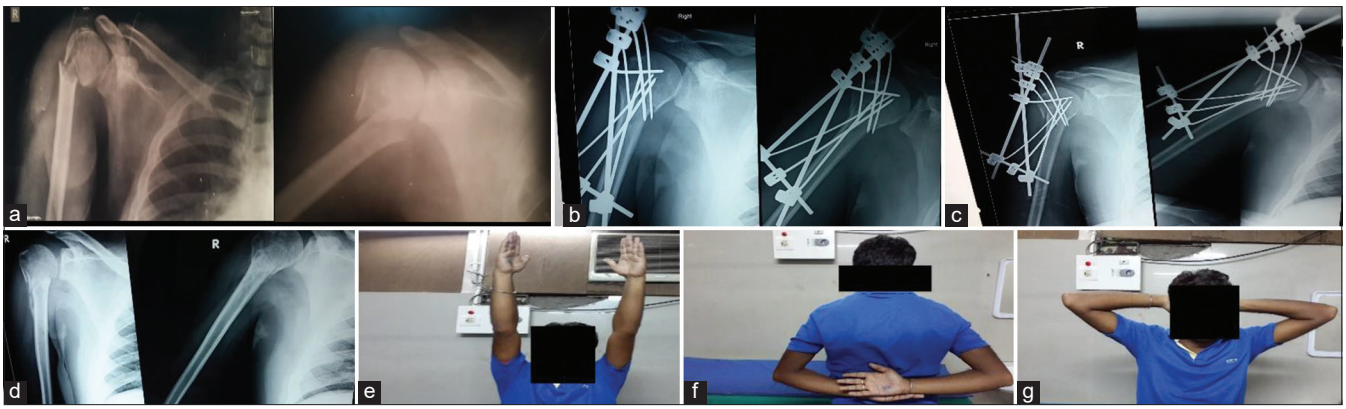

Figure 5: (a) Case 2 – 23 years male pre-operative X-ray AP/lat, (b) Case 2 – immediate after post-operative X-ray, (c) Case 2 – 4 weeks after post-operative X-ray, (d) Case 2 – X-ray after implant removal, (e) Case 2 – final ROM elevation, (f) Case 2 – final ROM extension, (g) Case 2 – final ROM external rotation

RESULTS AND ANALYSIS

The frequency of NEER's type in study group was: NEER' type 2 = 36.7% (11) and type 3 = 63.3% (19) [Chart 1].

The distribution of age (years) in type 2 NEER' group, minimum age was 19 years, maximum 52 years and mean age 40.9 years; in type 3 NEER' group, minimum age was 40, maximum 70 years and mean age 53 years [Chart 2].

The distribution of sex in NEER' type 2 study group was 10 (90.9%) male, 1 (9.1%) female and 4 (21.1%) male, 15 (78.9%) female in NEER' type 3 group [Chart 3].

The distribution of side in study group was NEER' type 2 left side = 7 (63.6%) and right side = 4 (36.4%); type 3 left side = 5 (26.3%) and right side = 14 (73.7%) [Chart 4].

The earliest recorded time of fracture union as determined by clinical and radiological evaluation was 1.5 months among the study group and longest recorded time was 2.5 months with mean time of union being 2.04 months in type

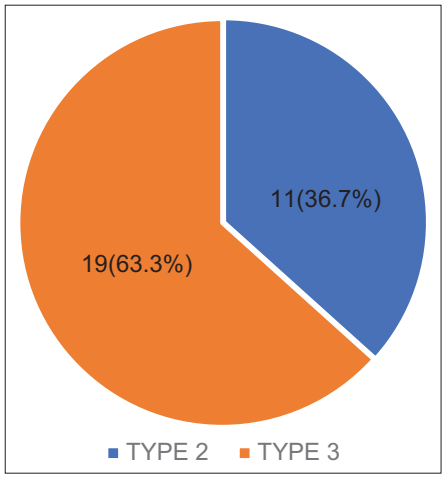

Chart 1: Pie chart showing frequency of NEER' type (2/3 part) in study group. Interpretation: Frequency of NEER' type: type 2=36.7% (11) and type 3=63.3% (19)

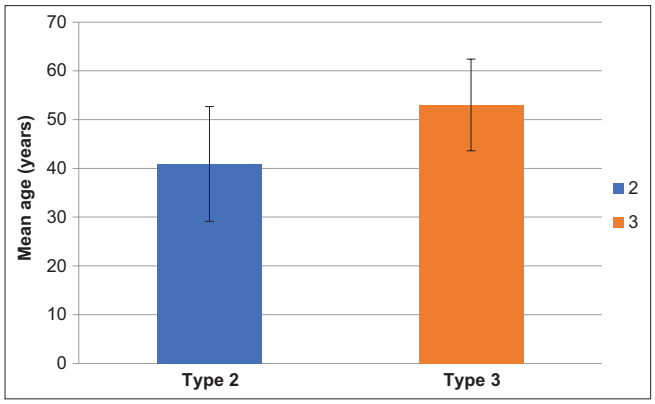

Chart 2: Bar diagram showing distribution of age (years) in NEER' type of group. Interpretation: In type 2 NEER' group, minimum age (years)=19, maximum=52, and mean age=40.9; In type 3 NEER' group, minimum age=40, maximum=70, and mean age (years)=53

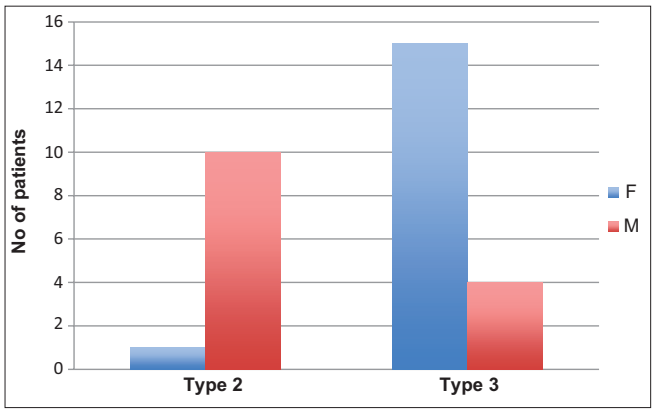

Chart 3: Distribution of sex in NEER' type of study group. Interpretation: There were 10 (90.9%) male, 1 (9.1%) female in NEER' type 2 group and 4 (21.1%) male, 15 (78.9%) female in NEER' type 3 group

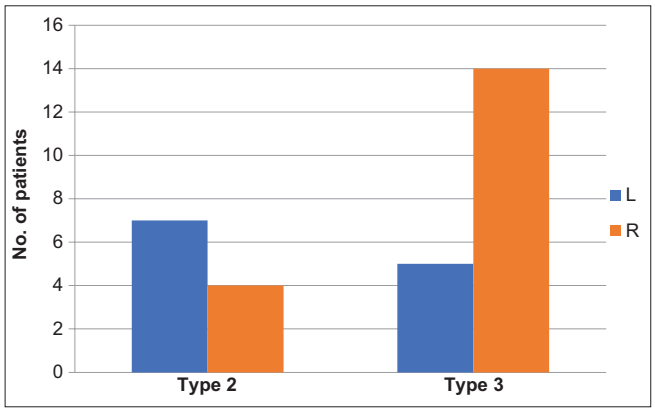

Chart 4: Distribution of side in NEER' type of study group. Interpretation: NEER' type 2 left side=63.6% and right side=36.4%; type 3 left side=26.3% and right side=73.7%

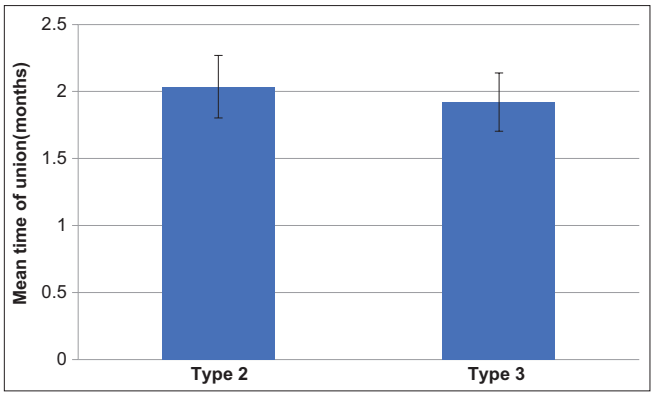

Chart 5: Bar diagram showing distribution of mean time of union (months) in NEER' type of study group. Interpretation: NEER' type 2 patients' (11) minimum time of union (month)=1.5, maximum=2.5, and mean=2.04; type 3 patients'(19), minimum=1.5, maximum=2.2, and mean=1.92

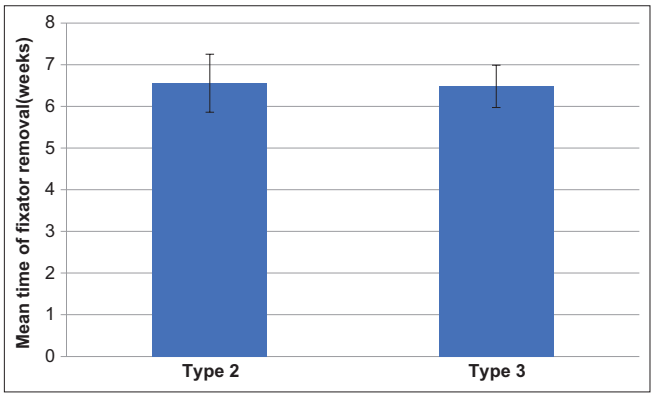

Chart 6: Bar diagram showing distribution of mean time of removal of fixation (weeks) in NEER' type of study group. Interpretation: Minimum time of removal of fixation (weeks)=6, maximum=8, and mean=6.55 in NEER' type 2 (11); in type 3 (19), minimum=6, maximum=7, and mean time=6.48

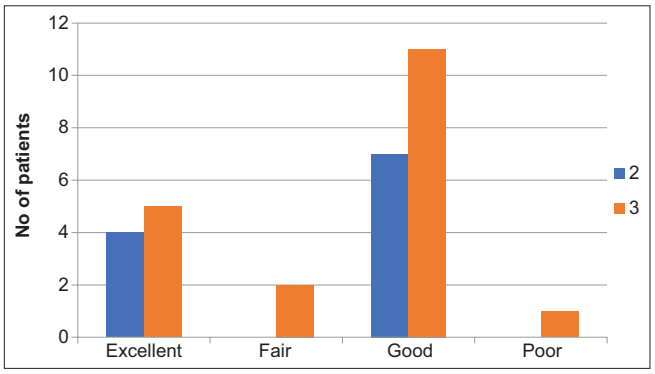

Chart 7: Distribution of outcome in NEER' type of study group. Interpretation: In NEER' type 2 group, there were excellent=36.4% (4), good=63.6 (7) outcome and in NEER' type 3 group, there were excellent=26.3 (5), good=57.9% (11), fair=10.5 (2), and poor=5.3% (1) outcome and *P* = 0.5704

2 NEER' group and for type 3 group it was 1.5 months and longest recorded time was 2.2 months with mean time of union being 1.92 months [Chart 5].

The earliest implant (K-wires) removal time was 6 weeks and longest recorded time was 8 weeks with mean removal time being 6.55 weeks in type 2 NEER' group and for type

3 group it was 6 weeks and longest recorded time was 7 weeks with mean removal time being 6.47 weeks [Chart 6].

In type 2 NEER' group, there was two patients with pin tract infection (resolved later on) and in type 3 group, one patient with pin tract infection (resolved later on), two patients with K-wire loosening (statistically non-significant data with $P = 0.3126$) [Table 1].

There was excellent outcome = 36.4% (4), good = 63.6% (7) of patients (11) in NEER' type 2 group and in type 3 group, there was excellent = 26.3% (5), good = 57.9% (11), fair = 10.5 (2), and poor = 5.3% (1) of patients (19) according to CMS (statistically non-significant data with $P = 0.5704$) [Chart 7].

The CMS of all the patients also suggest the good outcome [Chart 8].

Table 1: Distribution of complications in NEER' type of study group

	NEER' type		
Complications	2	3	Total
K-wire loosening	0	2	2
Row %	0.0	100.0	100.0
Col %	0.0	10.5	6.7
None	9	16	25
Row %	36.0	64.0	100.0
Col %	81.8	84.2	83.3
Pin tract infection (resolved later)	2	1	3
Row %	66.7	33.3	100.0
Col %	18.2	5.3	10.0
Total	11	19	30
Row %	36.7	63.3	100.0
Col %	100.0	100.0	100.0

P=0.3126; Chi-square=2.3254

DISCUSSION

Court-Brown *et al.*[30] conducted 5-year prospective study of the epidemiology of 1027 proximal humeral fractures and found that higher incidence occurs in female. In our study, we found higher incidence in females in type 3 fracture.

Gupta *et al.* (2012)[50] evaluated 16 patients the functional results of closed NEER's 2- and 3-part proximal humerus fractures treated by Joshi's external stabilizing system and they found mean time of union was 6.5 ± 1.18 weeks. Whereas in our study it was 8 weeks in type 2 fracture and 7 weeks in type 4 fractures.

Gupta *et al.* (2012)[50] also reported one case of K-wire loosening and one case of pin tract infection which is very much similar to our study.

Table 2: Showing outcome comparing with other series

Results	Our study (%)	Gupta *et al.*[50] (2012) (%)	Altay *et al.*[49] (%)	Monga *et al.*[50] (%)	Kristiansen *et al.*[49] (1987) (%)
No. of cases	30	16	14	19	23
Excellent	30	18.75	Nil	50	8.69
Good	60	62.5	62.5	30	43.48
Fair	6.67	18.75	25	10	43.48
Poor	3.33	Nil	12.9	10	4.35

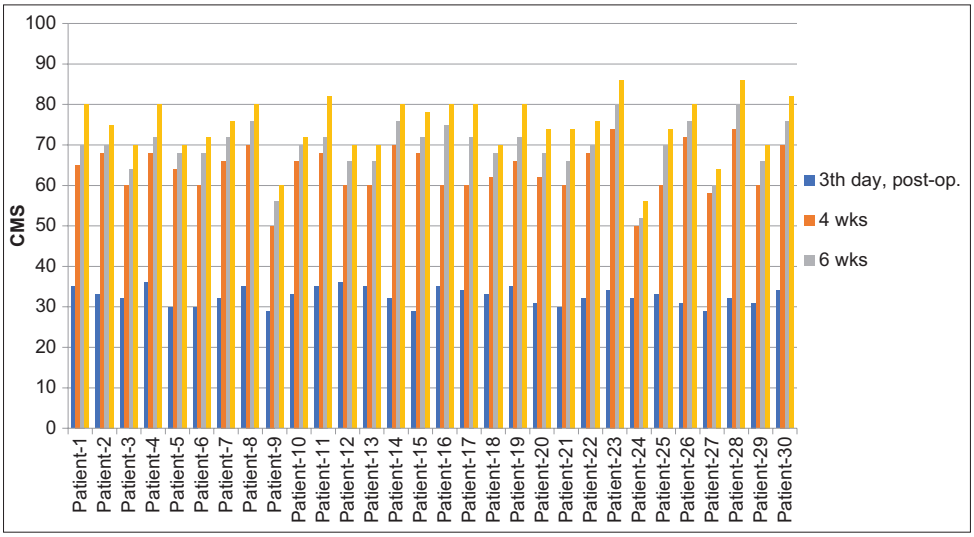

Chart 8: Constant–Murley shoulder score during the follow-up period of the study group

The study was randomized for age, sex, and fracture pattern and baring the exclusion criteria, it demonstrated results that are comparable to authors who have attempted to treat such fractures with external fixation. It also showed statistically comparable incidences of union, shoulder function, and complications with authors who have published results of close reduction and external fixation for such fractures [Table 2].

CONCLUSION

We conclude that CRPP of proximal humerus fractures in adults is a viable alternative modality of treatment as this method is promising and avoids the complication of other methods. The main advantage of the procedure being affordability, minimal invasive, stable construct pertaining good control of infection, shorter hospital stays, early return to work, and easy implant removal under local anesthesia and most importantly easy to learn and reproducible.

REFERENCES

1. Wallace WA, Hellier M. Improving radiographs of the injured shoulder. Radiography 1983;49:229-33.
2. Hoffmeyer P. The operative management of displaced fractures of the proximal humerus. J Bone Joint Surg Br 2002;84:469-80.
3. Gaebler C, McQueen MM, Court-Brown CM. Minimally displaced proximal humeral fractures: Epidemiology and outcome in 507 cases. Acta Orthop Scand 2003;74:580-5.
4. Gerber C, Werner CM, Vienne P.Internal fixation of complex fractures of the proximal humerus. J Bone Joint Surg Br 2004;86:848-55.
5. Lill H, Bewer A, Korner J, Verheyden P, Hepp P, Krautheim I, *et al*. Conservative treatment of dislocated proximal humeral fractures. Zentralbl Chir 2001;126:205-10.
6. Gerber C, Schneeberger AG, Vinh TS. The arterial vascularisation of the humeral head. An anatomical study. J Bone Joint Surg Am 1990;72:1486-94.
7. Plaschy S, Leutenegger A, Rüedi TP. Humeral head C fractures in boys Patients: Can head necrosis be avoided? Trauma surgeon 1995;92:63-8.
8. Hertel R, Hempfing A, Stiehler M, Leunig M. Predictors of humeral head ischemia after intracapsular fracture of the proximal humerus. J Shoulder Elbow Surg 2004;13:427-33.
9. Gerber C, Hersche O, Berberat C. The clinical relevance of posttraumatic avascular necrosis of the humeral head. J Shoulder Elbow Surg 1998;7:586-90.
10. Resch H, Povacz P, Frohlich R, Wambacher M. Percutaneous fixation of three and four-part fractures of the proximal humerus. J Bone Joint Surg Br 1997;79:295-300.
11. Kamineni S, Ankem H, Sanghavi S. Anatomical considerations for percutaneous proximal humeral fracture fixation. Injury 2004;35:1133-6.
12. Banco SP, Andrisani D, Ramsey M, Frieman B, Fenlin JM Jr. The parachute technique: Valgus impaction osteotomy for two-part fractures of the surgical neck of the humerus. J Bone Joint Surg Am 2001;83 Suppl 2:38-42.
13. Darder A, Darder A Jr., Sanchis V, Gastaldi E, Gomar F. Four-part displaced proximal humeral fractures: Operative treatment using Kirschner wires and a tension band. J Orthop Trauma 1993;7:497-505.
14. Kristiansen B, Christensen SW. Plate fixation of proximal humeral fractures. Acta Orthop Scand 1986;57:320-3.
15. Robinson CM, Page RS. Severely impacted valgus proximal humeral fractures. J Bone Joint Surg Am 2004;86 Suppl 1:143-55.
16. Hessmann M, Baumgaertel F, Gehling H, Klingelhoeffer I, Gotzen L. Plate fixation of proximal humeral fractures with indirect reduction: Surgical technique and results utilizing three shoulder scores. Injury 1999;30:453-62.
17. Kwon BK, Goertzen DK, O'Brien PJ, Broekhuyse HM, Oxland TR. Biomechanical evaluation of proximal humeral fracture fixation supplemented with calcium phosphate cement. J Bone Joint Surg Am 2002;84:951-61.
18. Brems JJ. Shoulder arthroplasty in the face of acute fracture: Puzzle pieces. J Arthroplasty 2002;17 4 Suppl 1:32-5.
19. Demirhan M, Kilicoglu O, Altinel L, Eralp L, Akalin Y. Prognostic factors in prosthetic replacement for acute proximal humerus fractures. J Orthop Trauma 2003;17:181-9.
20. Court-Brown CM, Garg A, McQueen MM. The translated two-part fracture of the proximal humerus. Epidemiology and outcome in the older patient. J Bone Joint Surg Br 2001;83:799-804.
21. Lill H, Hepp P, Rose T, König K, Josten C. The angle stable locking proximal-humerus-plate (LPHP) for proximal humeral fractures using a small anterior-lateral-deltoid-splitting-approach technique and first results. Zentralbl Chir 2004;129:43-8.
22. Court-Brown CM, Cattermole H, McQueen MM. Impacted valgus fractures (B1.1) of the proximal humerus. The results of nonoperative treatment. J Bone Joint Surg Br 2002;84:504-8.
23. Szyszkowitz R, Seggl W, Schleifer P, Cundy PJ. Proximal humeral fractures. Management techniques and expected results. Clin Orthop Relat Res 1993;292:13-25.
24. Herscovici D Jr., Saunders DT, Johnson MP, Sanders R, DiPasquale T. Percutaneous fixation of proximal humeral fractures. Clin Orthop Relat Res 2000;375:97-104.
25. Wijgman AJ, Roolker W, Patt TW, Raaymakers EL, Marti RK. Open reduction and internal fixation of three and four-part fractures of the proximal part of the humerus. J Bone Joint Surg Am 2002;84:1919-25.
26. Burkhart SS. Arthroscopic subscapularis tenolysis: A technique for treating refractory glenohumeral stiffness following open reduction and internal fixation of a displaced three-part proximal humerus fracture. Arthroscopy 1996;12:87-91.
27. Muckter H, Herzog L, Becker M, Vogel W, Meeder PJ, Buchholz J. Angle- and rotation stable internal fixation of proximal humerus fractures with the humerus fixation plate. Early clinical experience with a newly developed implant. Chirurg 2001;72:1327-35.
28. Healy WL, Jupiter JB, Kristiansen TK, White RR. Non-union of the proximal humerus. A review of 25 cases. J Orthop Trauma 1990;4:424-31.
29. Bosch U, Skutek M, Fremerey RW, Tscherne H. Outcome after primary and secondary hemiarthroplasty in elderly patients with fractures of the proximal humerus. J Shoulder Elbow Surg 1998;7:479-84.
30. Court-Brown CM, Garg A, McQueen MM. The epidemiology of proximal humeral fractures. Acta Orthop Scand 2001;72:365-71.
31. Clifford PC. Fractures of the neck of the humerus: A review of the late results. Injury 1980;12:91-5.
32. Kristiansen B, Christensen SW. Proximal humeral fractures. Late results in relation to classification and treatment. Acta Orthop Scand 1987;58:124-7.
33. Stableforth PG. Four-part fractures of the neck of the humerus. J Bone Joint Surg Br 1984;66:104-8.
34. Drosdowech DS, Faber KJ, Athwal GS. Open reduction and internal fixation of proximal humerus fractures. Orthop Clin North Am 2008;39:429-39.
35. Young AA, Hughes JS. Locked intramedullary nailing for treatment of displaced proximal humerus fractures. Orthop Clin North Am 2008;39: 417-28.
36. Kristiansen B. External fixation of proximal humerus fracture. Clinical and cadaver study of pinning technique. Acta Orthop Scand 1987;58:645-8.
37. Kristiansen B, Kofoed H. Transcutaneous reduction and external fixation of displaced fractures of the proximal humerus. A controlled clinical trial. J Bone Joint Surg Br 1988;70:821-4.
38. Hodgson SA, Mawson SJ, Stanley D. Rehabilitation after two-part fracture of the neck of the humerus Bone Joint Surg 2003;85:419-22.
39. Jakob RP, Miniaci A, Anson PS, Jaberg H, Osterwalder A, Ganz R. Four-part valgus impacted fracture of the proximal humerus. J Bone Joint Surg 1991;73:295-8.
40. Zyto K, Kronberg M, Brostrom LA. Shoulder function after displaced fractures of the proximal humerus. J Shoulder Elbow Surg 1995;4:331-6.
41. Koval KJ, Blair B, Takei R, Kummer FJ, Zuckerman JD. Surgical neck fractures of the proximal humerus: A laboratory evaluation of ten fixation techniques. J Trauma 1996;40:778-3.

42. Siegel J, Dines D. Proximal humerus malunions. Orthop Clin North Am 2000;31:35-49.
43. Wijgman AJ, Roolker W, Patt TW, Raaymakers EL, Marti RK. Open reduction and internal fixation of three and four-part fractures of the proximal part of the humerus. J Bone Joint Surg Am 2002;84:1919-25.
44. Neer CS. Displaced humeral fractures. J Bone Joint Surg 1970;52:1077-89.
45. Hirschmann MT, Fallegger B, Amsler F, Regazzoni P, Gross T. Clinical longer-term results after internal fixation of proximal humerus fractures with a locking compression plate (PHILOS). J Orthop Trauma 2011;25: 286-93.
46. Olerud P, Ahrengart L, Ponzer S, Saving J, Tidermark J. Internal fixation versus nonoperative treatment of displaced 3-part proximal humeral fractures in elderly patients: A randomized controlled trial. J Shoulder Elbow Surg 2011;20:747-55.
47. Altay T, Karapinar L, Kaya A, Oztürk H. Treatment of two-part proximal humeral fractures with external fixators. Ulus Travma Acil Cerrahi Derg 2005;11:153-6.
48. Monga P, Verma R, Sharma VK. Closed reduction and external fixation for displaced proximal humeral fractures. J Orthop Surg (Hong Kong) 2009;17:142-5.
49. Kristiansen B. External fixation of proximal humerus fracture. Clinical and cadaver study of pinning technique. Acta Orthop Scand 1987;58:645-8.
50. Gupta AK, Gupta M, Senger G, Nath R. Functional outcome of closed fractures of proximal humerus managed by Joshi's external stabilizing system. Indian J Orthop 2012;46:216-20.

How to cite this article: Mura S, Karmakar A, Datta T, Biswas D, Pal AK. Close Reduction and Percutaneous Pinning in NEER Type 2 and 3 Proximal Humerus Fractures in Adults. Int J Sci Stud 2021;8(11):87-93.

Source of Support: Nil, **Conflicts of Interest:** None declared.