Print ISSN: 2321-6379
Online ISSN: 2321-595X

Original Article

Clinical, Radiological, and Functional Outcome of Delayed Presenting Congenital Talipes Equinovarus Cases Managed by Joshi's External Stabilization System: A Prospective Study

N Thanappan[1], K Singaravel[2], T Saravanamuthu[2], P Sivakaran[3], M Thirumurugan[3]

[1]Professor, Department of Orthopaedics and Traumatology, Madurai Medical College, Madurai, Tamil Nadu, India, [2]Assistant Professor, Department of Orthopaedics and Traumatology, Madurai Medical College, Madurai, Tamil Nadu, India, [3]Postgraduate Student, Department of Orthopaedics and Traumatology, Madurai Medical College, Madurai, Tamil Nadu, India

Abstract

introduction: Clubfoot and its management have been the topic of keen interest to the orthopedics field ever since time immemorial and many techniques in the successful management of these have been advocated till date. This study discusses one such technique of management in children with Joshi's external stabilization system (JESS) fixator.

Aim: This study aims to evaluate the role of JESS in the management of neglected, resistant and relapsed congenital talipes equinovarus (CTEV), in the age group of 1–6 years.

Materials and Methods: A total of 20 feet in 20 children underwent JESS fixation surgery at the Department of Orthopaedics, Government Rajaji Hospital, Madurai Medical College, from October 2015 to September 2018.

Results: Four patients had excellent results, 12 patients had good results with an average score of 78, three patients had fair results, and poor results in one patient. The average pre-operative Pirani score was 4.5 and post-operative score of 0.93 with $P < 0.001$ which was statistically significant. The average pre-operative Dimeglio score was 12 (Stage III) which statistically improved post-operative ($P < 0.001$) to 5 (Stage 1).

Conclusion: By controlled differential distraction using JESS apparatus, a painless, Pliable, plantigrade. The perfect sized and cosmetically acceptable foot has been obtained even in children 1 year–6 years. Controlled differential distraction using JESS fixator has got a definite role in the management of relapsed and neglected CTEV and it does not prevent the foot from being treated surgically at a later date if needed.

Key words: Congenital talipes equinovarus, Joshi's external stabilization system fixator outcome

INTRODUCTION

Clubfoot is the most common congenital foot disorder, with an incidence of 0.9/1000 live births[1] in India. The etiology, pathological anatomy, and treatment of congenital talipes equinovarus (CTEV) remain controversial. Clubfoot may result from an osseous, muscular or neuropathic error, or idiopathic. Of these, the last is by far the most frequent. Many theories have been advanced, including intrauterine molding, developmental defects, and anomalies of other systems (neurogenic, myogenic, and vascular). Both genetic and environmental factors (especially maternal smoking) have been implicated. There are many tissue abnormalities in CTEV, including deficiency of calf muscle bulk, changes in muscle histology, bone and joint deformities (e.g. talus and calcaneocuboid joint), and vascular hypoplasia. The right age to perform the surgical procedure is still on the debate, with most surgeons delay it till infant is 4–6 months old.[2] Procedures of soft tissues are usually done up to first 2 years till a maximum of 4 years, after which it

Access this article online

www.ijss-sn.com

Month of Submission : 02-2019
Month of Peer Review : 03-2019
Month of Acceptance : 03-2019
Month of Publishing : 04-2019

Corresponding Author: Dr. K Singaravel, Department of Orthopaedics and Traumatology, Madurai Medical College, Madurai, Tamil Nadu, India. E-mail: drsingaravel95ykc@gmail.com

has been combined with wedge resection, osteotomies, and arthrodesis, due to changes in growing bones and incongruity of joints.[3] However, these feet during the end of treatment were far from normal and usually are small scarred and stiff.[3] However, with advancement and enthusiasm showed in complex deformity correction using Ilizarov technique, pediatric and foot surgeons have applied the same principles of distraction histogenesis in the treatment of CTEV.[4] This provided a good alternative to those feet which would have needed extensive surgical procedures, with an added advantage of less stiffness and shortening that occurred due to extensive surgeries. Dr. B. B. Joshi[5] designed an external fixator by the use of simple K-wires, link joints, and distractors for correction of equinovarus deformities. This works on the basis of controlled fractional differential distraction. Its advantage is that it can even be applied to small non-ambulatory children.

AIM

This study aims to study the Joshi's external stabilization system (JESS) fixator in the correction of deformities in neglected and relapsed cases of CTEV.

MATERIALS AND METHODS

This prospective study was conducted in the Department of Orthopaedics at Government Rajaji Hospital, Madurai Medical College in patients who are diagnosed as neglected, relapsed, or recurrent CTEV aged between 1 and 6 years. 20 feet in 20 children were treated by controlled differential distraction technique with the help of external fixator based on Joshi's Apparatus during the period from October 2015 to September 2018. A total of 21 cases were taken for the study, of which one was lost to follow-up, hence, excluded from the study. No bilateral case was taken up for the study. In 12 children, the right side was affected, and in eight children, the left side was affected. Among the 20 cases, eight cases had no previous surgical exposure. The remaining cases had the posteromedial release done earlier.

All patients were thoroughly evaluated preoperatively both clinically and radiologically. The clinical assessment comprised detailed history with emphasis on known factors associated with CTEV and a thorough physical examination. Clinical evaluation of the foot was done using a modified Pirani scoring system and Dimeglio scoring system. Radiologically, the foot was evaluated as per guidelines laid down by Simons. Each set of JESS fixator consists of the following standard components: Link joints, distractors, K-wires, and connecting rods. The surgical procedure was carried out under general anesthesia in the supine position. The dressing is performed thrice a week with a povidone-iodine solution. Scabs if any are removed. Distraction commences on the 3rd–7th post-operative day depending on the settling down of edema. The calcaneometatarsal distraction proceeds at the rate of 1 mm/day on the medial side and 0.5 mm/day on the lateral side. Correction achieved at the end of treatment is documented clinically and radiologically and assessment of the maintenance of the correction is done at regular

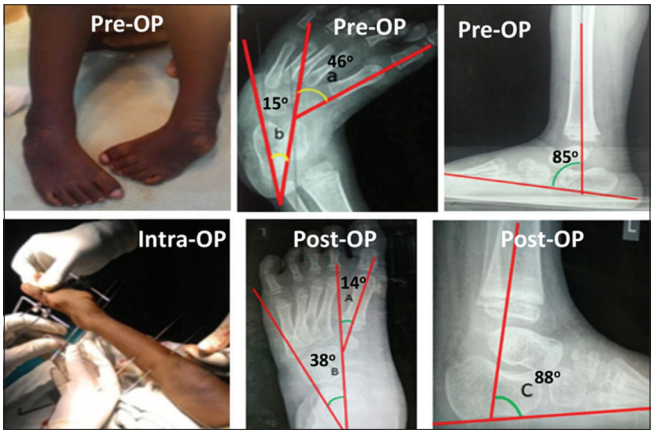

Figure 1: Case illustration

Figure 2: An 18-month post-operative functional rating score 85

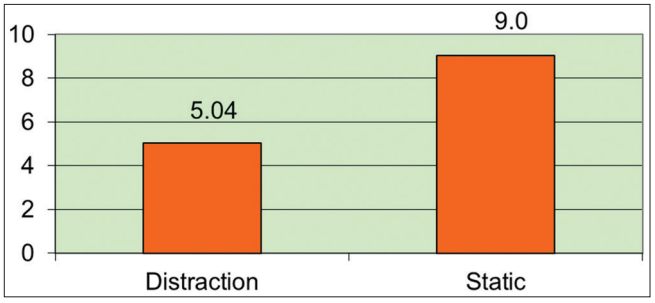

Figure 3: Correction period

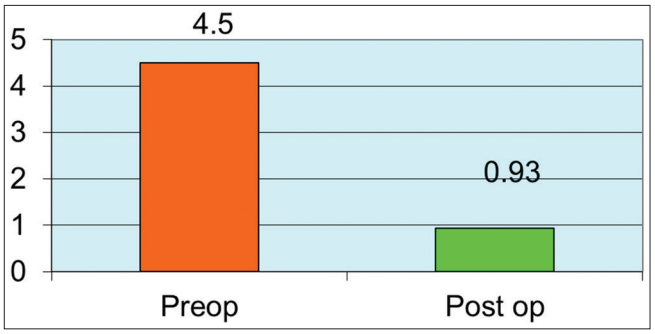

Figure 4: Pirani score

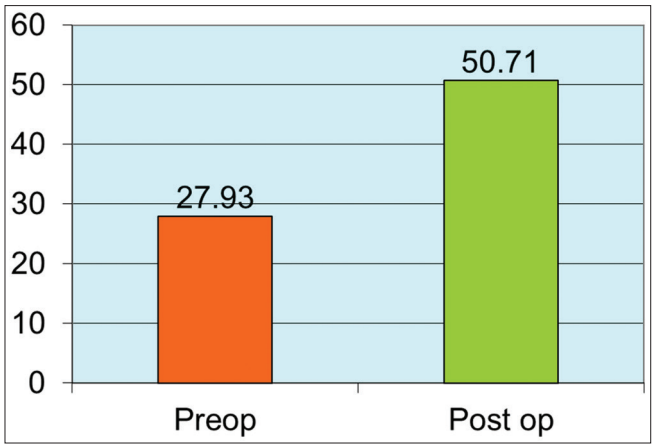

Figure 5: Talocalcaneal index

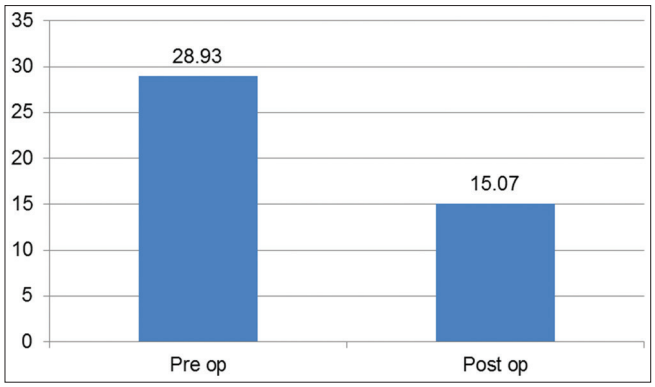

Figure 6: Talo-1st metatarsal angle

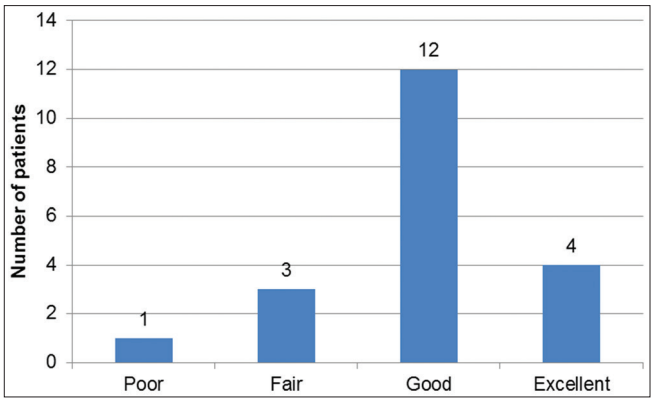

Figure 7: Functional rating system score

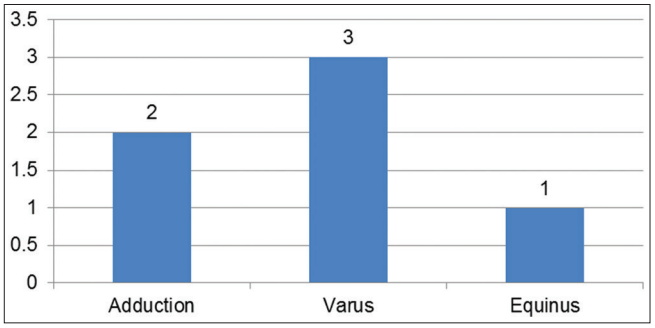

Figure 8: Residual deformity

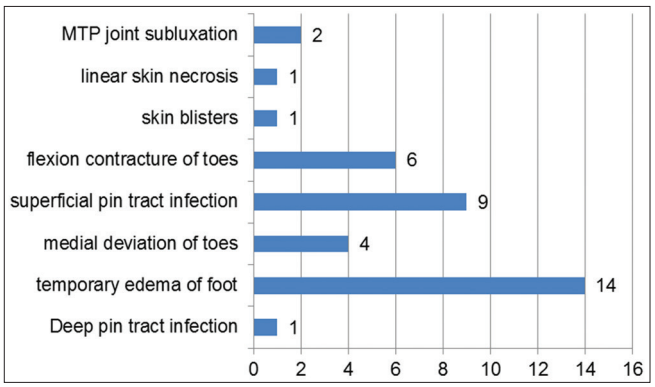

Figure 9: Complications

intervals. The correction is evaluated by the functional rating system score once the foot is stable without pain and limitation of joint motion directly attributable to the fixator. The observations made of the pre-operative severity and adequacy of post-operative correction are tabulated and analyzed to comment on the efficacy and limitations of the fixator.

RESULTS

In our series, 16 feet (80%) had excellent and good results and 4 feet (20%) had fair and poor results Figure 1 and Figure 2. In one case of poor result, the patient aged 3½ years had undergone posteromedial release 3 times earlier and had an extensive scar over the posteromedial aspect of foot and leg. All the deformities were fixed and the foot was very stiff. The foot was distracted for 4½ weeks and when the feet appeared corrected the apparatus was removed after 8 weeks of static phase. Postoperatively, the X-ray showed the spurious correction with varus on the right side and the function of the feet was very much limited. In another case aged 2 years, the apparatus was removed at the initial period of static phase due to deep pin tract infection and the pop frequently removed for dressing purpose. In our study, the mean age of patients was 2.82 years and most of them were in the age group of 2–4 years (64.3%). Among the sex distribution, 13 cases were male (65%) of the 20 cases. The average pre-operative Pirani score was 4.5 and post-operative score of 0.93 with $P < 0.001$ which was statistically significant Figures 3 and 4. The average pre-operative Dimeglio score was 12 (Stage III) which statistically improved post-operative ($P < 0.001$) to 5 (Stage 1). The average talocalcaneal angle in AP view was 19.9 and in lateral view was 8.02. The average talocalcaneal index pre-operative was 27.3 which statistically improved ($P < 0.001$) post-operative to 50.7 Figures 5 and 6. The average talus-first metatarsal angle pre-operative was 28.9 and post-operative was 15 ($P < 0.001$) which was

statistically significant. The mean correction period was 14 weeks with average distraction phase of 5 weeks and static phase of 9 weeks. By post-operative functional rating system score evaluation, the maximum score obtained was 90 in two patients aged (<2 years).

Four patients had excellent results, 12 patients had good results with an average score of 78, three patients had fair results, and poor results in one patient Figure 7. We had six cases of residual deformities post-fixator removal three cases of heel varus, two adductions, and one equinus deformity. The most common complication in our study was temporary edema of the foot followed by superficial pin tract infection Figures 8 and 9.

DISCUSSION

The management of relapsed and neglected CTEV with distraction system has obvious advantages in that it causes minimal injury to soft tissues including neurovascular structures, preserves the pliability of the foot, improves the range of motion of foot and ankle joints, and maintains the foot length. Moreover, it does not prevent the foot from being treated surgically at a later date if needed. Most studies have shown the efficacy of Ilizarov fixator in achieving good results in neglected and relapsed clubfoot. However, it can be applied only to older children and adolescents. Our study has shown that JESS fixator using simple K-wires and distractors can be used successfully even in younger children from 1 to 5 years of age. While evaluating the results, a system used for evaluation should be simple yet comprehensive and could be easily done. It should have as many objective criteria as possible and could be used for comparison with other similar studies. In previous studies, only clinical appearance was considered in the evaluation of the surgical results. The achievement of the plantigrade foot was considered as having a good result. Hence, these studies documented a higher percentage of success rate through the feet were small, stiff, and functionally very poor. The evaluation of results improved considerably after the development of analytical radiology by SIMMONS.[6] However, still, the functional improvements of the foot were not considered in the evaluation system; the functional rating system, developed by ATAR and LEHMAN,[7] combines subjective and objective clinical criteria and functional parameters and radiographic assessment in the evaluation system. It is easily reproducible with less interobserver errors and it can be used effectively to compare the results of similar studies. In our study, 80% had excellent and good results, 15% had fair results, and 5% had poor results, which compares favorably with other studies. There were no major complications in our series. Superficial pin tract infections occurred in 32.75% of patients who were cured with antibiotics. Medial deviation of toes occurred in 27.3% of patients which were corrected with the inclusion of toes in a plaster cast. Deep infection at the pin tract site in 9.1% of patients and pressure sore over the medial aspect of foot in 1 patient (4.55%) necessitated earlier removal of fixator and contributed to the less satisfactory results. These complications in our study are comparable with earlier studies. De La Huerta[8] noted pin tract infections in 17% of his patients. Grant[9] reported a 35% incidence of pin tract infections. Oganesyan[10] reported 12% incidence of pin tract infection. Similar complications were reported by Joshi[5] and also on the basis of our results, we feel that JESS fixator can be applied to correct relapsed and neglected clubfoot with reasonable success in younger children of 1–4 years and also functional rating system can be used effectively to compare the results of the treatment of clubfoot. Even though we had many complications following JESS application, they were amenable to treatment. The better results of this present study can be attributed to enthusiastic and compliant parents and longer hospitalization during the post-operative period. Anwar and Arun[11] found a strong correlation between better results and children who strictly follow the distraction-static phase protocol and the final outcome, stressing the fact that parent involvement is an essential component in treating neglected and relapsed clubfeet. A longer period of post-operative stay provided a controlled environment for the static period and reduced the risk of pin tract infection and other complications. One drawback we noted in our study was that hindfoot varus was not effectively corrected by JESS. According to a Ponseti technique, where the entire forefoot and midfoot have to undergo full abduction and external rotation for talus to be reduced and subsequent reduction of hindfoot varus. Here, in JESS, we use medial and lateral distraction in 2:1 ratio and varus correction by another different distractor in 2:1 ratio, the correction of hindfoot varus remains questionable. In our study, we had three cases of isolated heel varus.

CONCLUSION

Even though JESS apparatus has inherent complications of an external fixator, they were amenable to treatment. Controlled differential distraction using JESS fixator has got a definite role in the management of relapsed and neglected CTEV; it does not prevent the foot from being treated surgically at a later date if needed. Parent involvement is an essential component in treating neglected and relapsed clubfeet.

REFERENCES

1. Mittal RL, Sekhon AS, Singh G, Thakral H. The prevalence of congenital orthopaedic anomalies in a rural community. Int Orthop 1993;17:11-2.

2. Bensahel H, Csukonyi Z, Desgrippes Y, Chaumien J. Surgery in residual clubfoot: One-stage medioposterior release "a la carte". J Pediatr Orthop 1987;7:145-8.
3. Smith RB, Clayden AD, Silk FF. The results of osteotomies in the management of congenital talipes equinovarus. J Bone Joint Surg Br 1983;65:1-7.
4. Rosman M, Brown K. Preoperative ilizarov frame construction for correction of ankle and foot deformities. J Pediatr Orthop 1991;11:238-40.
5. Joshi BB. Correction of (CTEV) by controlled dfferential fractional distraction using joshi's external stabilization system (JESS). J Pediatr Orthop 1990;15:22-49.
6. Simmons G. Analytical radiography and the progressive approach in talipes equinovarus. Orthop Clin North Am 1978;9:187-206.
7. Atar D, Lehman WB, Grant AD, Strongwater AM. Revision surgery in clubfeet. Clin Orthop Relat Res 1992;283:223-30.
8. De La Huerta F. Correction of the neglected clubfoot by the ilizarov method. Clin Orthop Relat Res 1994;301:89-93.
9. Grant AD, Atar D, Lehman WB. The ilizarov technique in correction of complex foot deformities. Clin Orthop Relat Res 1992;280:94-103.
10. Oganesian OV, Istomina IS. Talipes equinocavovarus deformities corrected with the aid of a hinged-distraction apparatus. Clin Orthop Relat Res 1991; 266:42-50.
11. Anwar MH, Arun B. Short term results of correction of CTEV with JESS distractor. J Orthop 2004;1:e3.

How to cite this article: Thanappan N, Singaravel K, Saravanamuthu T, Sivakaran P, Thirumurugan M. Clinical, Radiological, and Functional Outcome of Delayed Presenting Congenital Talipes Equinovarus Cases Managed By Joshi's External Stabilization System: A Prospective Study. Int J Sci Stud 2019;7(1):130-134.

Source of Support: Nil, **Conflict of Interest:** None declared.