Print ISSN: 2321-6379
Online ISSN: 2321-595X

Original Article

Study of Clinical and Radiological Presentation of Cerebral Venous Thrombosis and its Outcome – A Prospective Study

A Thomas Edwin Raj[1], R Nandini Alias Kiruthika[2], R Sownthariya[3]

[1]Assistant Professor, Department of Neurology, Government Thoothukudi Medical College, Tamil Nadu, India, [2]Senior Resident, Department of Neurology, Government Thoothukudi Medical College, Tamil Nadu, India, [3]Associate Professor, Department of Neurology, Government Thoothukudi Medical College, Tamil Nadu, India

Abstract

Introduction: Cerebral venous thrombosis is now recognized as a common cause of young stroke with increased incidence in Asian countries, significantly more prevalent in postpartum females in southern India. Diverse manifestations such as diffuse encephalopathy, focal localizing deficits, migrainous headache, seizures, and psychiatric symptoms make early clinical diagnosis difficult.

Aim: The objective of this study was to analyze the diverse clinical and radiological presentation of cerebral venous thrombosis and its correlation with the outcome of the patient.

Methods: A total of 40 patients with the diagnosis of cerebral venous thrombosis were recruited from general medicine and neurology ward in a tertiary care hospital and were interviewed, examined regarding clinical presentation and radiological investigation was collected.

Results: In our study group, cerebral venous thrombosis (CVT) was more prevalent in females (62.5%) than males. Postpartum was the most common associated risk factor (40%) and headache (92.5%) being the most common clinical presentation followed by seizures, vomiting, visual disturbances, and focal deficits. Transverse sinus (77.5%) was the most common involved sinus followed by superior sagittal sinus (52.5%).

Conclusion: Postpartum incidence of cerebral venous thrombosis is highlighted with significance in our study. Involvement of deep cerebral veins, the extension of thrombus up to internal jugular vein, the involvement of multiple venous channels, the patient presented with coma, and presence of frank massive intracerebral hemorrhage were associated with poor outcome in our study. Knowledge about diverse clinical features spectrum in CVT and factors associated with a poor outcome can help us in early diagnosis, reducing the mortality and morbidity among patients.

Key words: Cerebral venous thrombosis, Magnetic resonance venogram, Outcome

INTRODUCTION

Cerebral venous thrombosis (CVT) refers to occlusion of venous channels in the cranial cavity, including thrombosis of dural venous sinuses or the smaller feeding cerebral veins. CVT is more prevalent among young to middle-aged people and is more common in females.[1-4] It is a potentially life-threatening condition requiring early clinical suspicion and prompt treatment. Although most of the patients have an excellent outcome if treated early and appropriately, delayed diagnosis is often possible due to the broad clinical spectrum of symptoms, varied initial presentation, obscuring of symptoms and signs by the underlying disease like meningitis, and normal findings in neuroimaging.

In addition, there exists a vast difference in predisposing factors, presentations, therapeutic options, and outcome of cerebral venous thrombosis among developed and developing countries. For example, the International Study

Access this article online

www.ijss-sn.com

Month of Submission : 11-2020
Month of Peer Review : 11-2020
Month of Acceptance : 12-2020
Month of Publishing : 01-2021

Corresponding Author: R Nandini Alias Kiruthika, Government Thoothukudi Medical College, Tamil Nadu, India.

on Cerebral Vein and Dural Sinus Thrombosis (ISCVT) 3 reported obstetric CVT in only 20% of cases compared to reports from Mexico and India, which report a much higher frequency.[5,6]

Similarly, CVT incidence is uncertain since it has a wide range of clinical manifestations.[7] However, recently, Panagariya *et al*.[8] reported that 17% of all strokes and half of all strokes in young people are due to CVT. In certain studies, CVT incidence was higher in South Asia and the Middle East.[9,10] Most studies from India have reported many cases; hence, the incidence in India is not as rare as assumed earlier. In India, CVT accounts for 10–20% of young strokes.[10] However, no well-designed large-scale epidemiologic study on CVT has been conducted in South Asia, where it is comparatively frequent.

Aim

The aim of the study was as follows:

1. To analyze the various clinical presentation of cerebral venous sinus thrombosis.
2. To study the radiological characteristics of cerebral venous sinus thrombosis patients and correlate with their clinical presentation.
3. To analyze the various factors contributing to the outcome in cerebral venous thrombosis patients.

MATERIALS AND METHODS

This prospective study was done in the Department of Neurology at Thoothukudi Government Medical College Hospital, Tamil Nadu. All patients attending neurology outpatient department and admitted in the hospital diagnosed with cerebral venous sinus thrombosis from November 1, 2019, to October 31, 2020, were recruited in this study.

All patients included in this study are more than 18 years of age, who satisfy the inclusion criteria, with a confirmed clinical and radiological diagnosis of cerebral venous thrombosis. Patients <18 years of age, who are unwilling to participate in this study, with inconclusive radiological findings to support cerebral venous thrombosis diagnosis are excluded from this study.

A questionnaire was prepared, and all patients included in this study were interviewed and thorough clinical examination of these patients was performed after getting informed written consent. The patients or relatives were asked about the risk factors, presenting symptom, and associated symptoms in detail. Radiological investigations such as computed tomography brain and magnetic resonance imaging (MRI) brain with MR venogram are done, and detailed reports were collected. Treatment history of patients and duration of hospital stay were noted. Association of clinical symptoms, signs of cerebral venous thrombosis patients, and their corresponding radiological features are compared and analyzed with those patients' outcome through statistical analysis.

RESULTS

In this study, 40 patients with the diagnosis of cerebral venous thrombosis were included. Among them, 75% of patients were <40 years old, with the disease more particularly predominant in 21–30 years of age group (40.5%) [Figure 1]. In our study group, CVT was more prevalent in females (62.5%) than males (37.5%) [Figure 2].

Most of the patients presented with headache (92.5 %), being the most common symptom. Others presenting symptoms are seizures (77.5%), vomiting (55%), visual disturbances (50%), focal neurological deficits such as hemiparesis (22.5%), acute confusional state (2.5%), and quadriparesis (2.5%) in descending order, respectively [Figure 3].

Among the prevalent risk factors in our study group, the most common was pregnancy (postpartum CVT) which

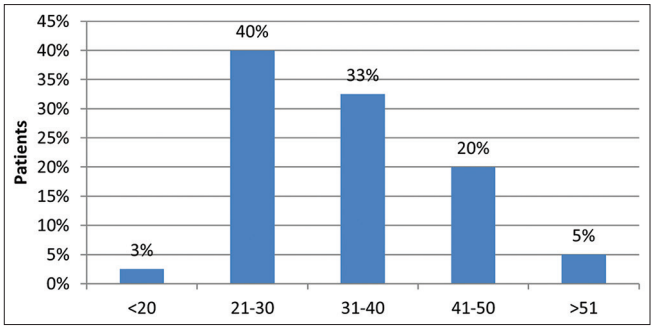

Figure 1: Age distribution of cerebral venous thrombosis

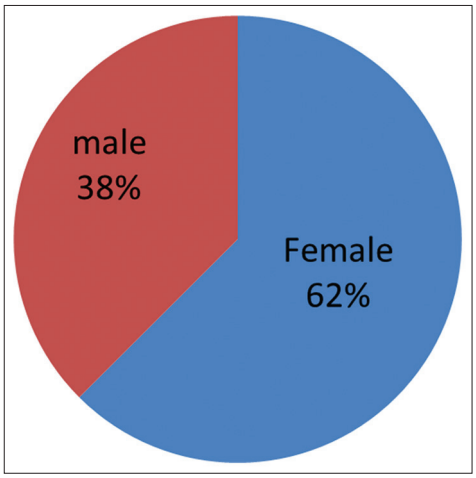

Figure 2: Gender distribution of cerebral venous thrombosis

accounts for 40% of cases. The second most common associated risk factor in our study group is alcoholism (30%), followed by diabetes mellitus (10%), OCP use (5%), diarrhea with dehydration (2.5%), connective tissue disorder (2.5%), and idiopathic causes (10 %), respectively [Figure 4].

Among our study group, 30% of patients presented with an altered level of consciousness, and 25% of patients had papilledema changes in fundus examination. Among higher mental function examination, 2 patients (5%) had aphasia. Furthermore, one patient had bilateral lateral rectus palsy due to raised intracranial pressure, and one patient with cavernous sinus thrombosis had ptosis, paresthesia over face (5th cranial nerve involvement), and 3rd and 4th nerve palsy. Moreover, in our study group, 35% of patients had hemiparesis and 1 (2.5%) patient had quadriparesis.

In our group, 15% of patients had hemorrhage in CT brain itself. In our study group, transverse sinus (77.5%) was the common involved dural venous sinus in MR venogram, followed by sigmoid (55%), superior sagittal sinus (52.5%) [Figures 5 and 6], straight sinus (32.5%), inferior sagittal sinus (10%), and petrosal sinus (10%). Four (10%) patients had deep cerebral veins involvement such as internal cerebral vein, deep vein of Galen, and cortical veins and 2 (5%) patients had thrombus extending to the internal jugular vein, and 1 (2.5%) patient presented with cavernous sinus thrombosis.

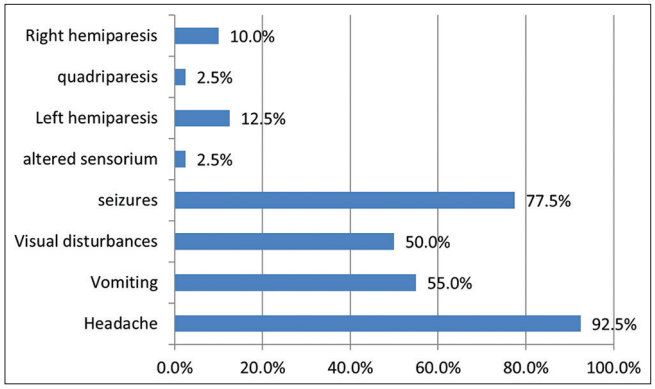

Figure 3: Clinical presentation spectrum of cerebral venous thrombosis in our study population

In MRI, 13 patients (32.5%) did not have any parenchymal changes. Ten patients (25%) had parenchymal edema, 17 (42.5%) patients had a frank intracerebral hemorrhage, and 3 patients (7.5%) had infarct with diffusion restriction among our study population [Figures 7 and 8].

All patients were treated with anticoagulants, antiepileptic drugs, anti-edema measures, supportive iv fluid supplementation, warfarin diet, and physiotherapy. Coagulation profile was monitored and INR was maintained between 2 and 3. Nearly all (38 patients – 95%) recovered while 2 patients (5%) died due to involvement of multiple sinuses, extensive intracerebral hemorrhage, and extension of thrombosis up to internal jugular vein or involvement of deep cerebral veins [Figure 9].

DISCUSSION

Cerebral venous thrombosis (CVT) is considered an uncommon cause of stroke and its incidence is much less common than cerebral arterial thromboembolism.[10] However, in India, CVT accounts for 10–20% of young strokes.[11] The clinical features are diverse; hence, CVT is more challenging to diagnose than other types of stroke.

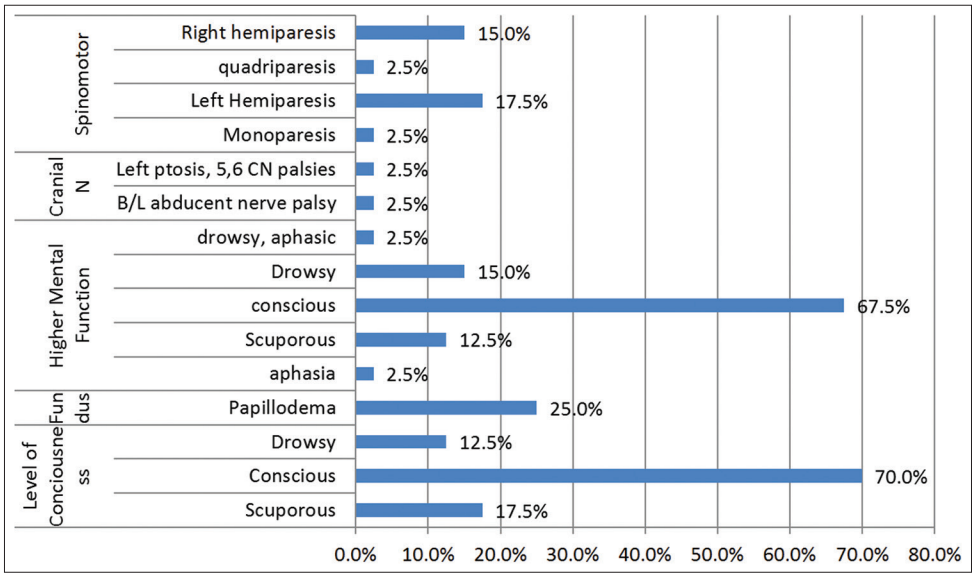

Figure 4: Clinical findings in our study group

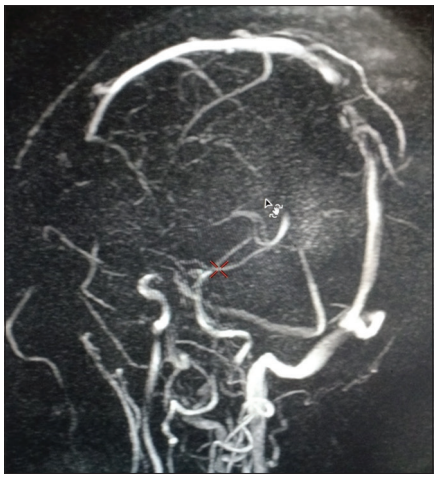

Figure 5: Mid superior sagittal sinus thrombosis in a postpartum female

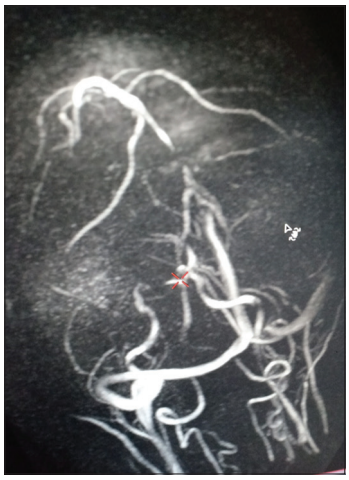

Figure 6: Mid superior sagittal sinus thrombosis

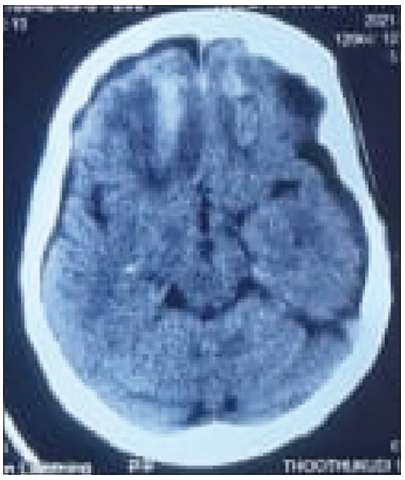

Figure 7: Bilateral frontal hemorrhage in a case of superior sagittal and bilateral transverse sinus thrombosis

Most patients have an excellent outcome if treated early and appropriately.

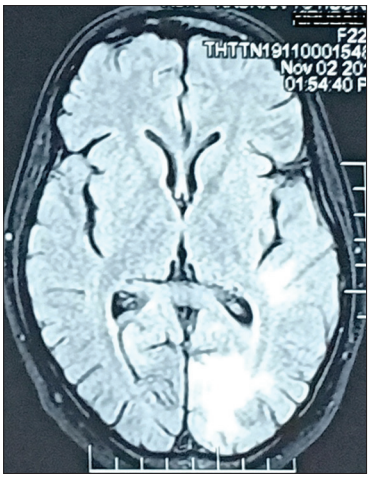

Figure 8: The left parietooccipital T2/FLAIR hyperintensities without diffusion restriction in a postpartum female with the left transverse sigmoid straight sinus thrombosis

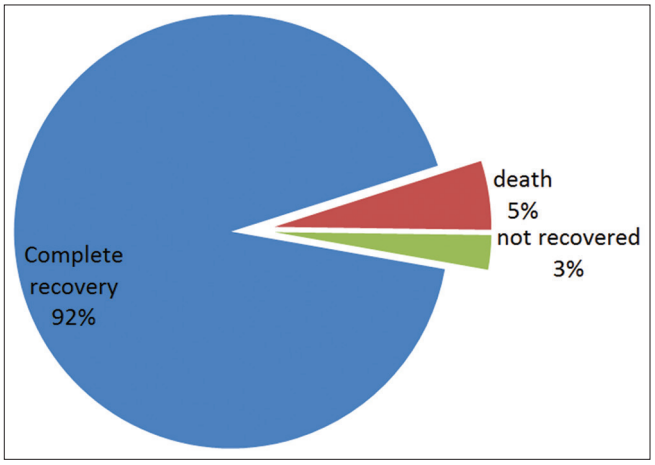

Figure 9: Outcome in our study group

Cerebral venous thrombosis is more common in the younger age group in contrary to arterial stroke. In our study population, it is more prevalent in <40 years age group (75%) comparable with Khaladkar *et al.* (57.5%).[12] It is more prevalent in females in our study population (62.5%), which is in accordance with Ameri and Bosser *et al.*[13] and Ferro *et al.*[14] This female preponderance may be due to risk factor pregnancy, puerperium (40%) and OCP use (5%) which contributed to the occurrence of CVT in our study group which is in accordance with the study by Banakar *et al.*[15] (56.25%, 9.37%) and in contrary to the study by Ferro *et al.* (15%).[14]

Cerebral venous thrombosis causes varied clinical features due to two pathophysiologic mechanisms. First, thrombosis of cerebral veins or sinuses results in increased venular and capillary pressure. As local venous pressure continues to raise, decreased cerebral perfusion results in ischemic injury and cytotoxic edema, disruption of blood–brain

Table 1: Correlation of risk factor with outcome of CVT in our study group

CVT	Outcome			Total	*P* value
	Complete recovery	Death	Not recovered		
Alcoholic	19	1	1	21	<0.0001
-/high platelet count	1	0	0	1	
Connective tissue disorder	1	0	0	1	
Postpartum	15	1	0	16	
Total	36	2	1	39	

barrier leads to vasogenic edema, and venous and capillary rupture culminates in parenchymal hemorrhage.

Second, obstruction of cerebral sinuses may also result in decreased cerebrospinal fluid absorption, which usually occurs through arachnoid granulation into the superior sagittal sinus. Thus, thrombosis of cerebral sinuses not only increases venous pressure but also impairs CSF absorption and ultimately leads to increased intracranial pressure. Increased intracranial pressure aggravates venular and capillary hypertension and leads to parenchymal hemorrhage, vasogenic and cytotoxic edema.[16] Experimental animal data suggest that vasogenic edema occurs earlier in venous stroke than in arterial stroke and cytotoxic edema is far less common in venous stroke.[17]

Hence, most patients in our study presented with headache, probably due to increased intracranial pressure (92.5%). Similar results were found in various studies by Daif *et al.* (82%),[18] Banakar *et al.* (82.7%),[15] Narayan *et al.* (94.4%),[19] and Halesh *et al.* (95%).[20]

Seizures were the second most common presenting feature (77.5%), whereas it is 60% in studies by Barinagarrementeria *et al.*[21] and 48% in the study by Einhaupl *et al.*,[22] and papilledema was seen in 25% of patients comparable with studies by Einhaupl *et al.* (27%).[22]

Among our study group, altered level of consciousness was seen in 30% of patients probably due to postictal confusion which is in accordance with the studies by Banakar *et al.* (54 %)[15] and in study by Barinagarrementeria *et al.* (63%).[19] Motor deficits were seen in 42.5% of patients in our study population according to 48% in a study by Halesh *et al.*[20] and 56.9% in a study by Stolz *et al.*[23]

Involvement of deep cerebral veins is associated with more catastrophic focal motor neurological deficits, and it correlates significantly in our study group ($P < 0.0001$).

The transverse sinus (77.5%) was the most common in our study in contrast to superior sagittal sinus being the most common sinus involved in many studies by Daif *et al.* (85%)[18] and Ameri and Bousser *et al.*[13] (72%). Sigmoid (55%) and superior sagittal sinus (52.5%) are the second most commonly involved sinus in our study population either alone or with other sinuses. Three patients in our study group had isolated superior sagittal thrombosis (7.5%), whereas the rest of the patients (90%) showed thrombosis involving multiple venous sinuses (2.5% cavernous sinus thrombosis).

Table 2: Correlation of venous channels involvement with outcome of CVT

Venous channels	Outcome			*P* value
	Complete recovery	Death	Not recovered	
SSS				
Negative	17	0	1	0.259
Positive	19	2	0	
ISS				
Negative	33	2	0	0.024
Positive	3	0	1	
Transverse				
Negative	7	1	0	0.187
Positive	29	1	1	
Sigmoid				
Negative	17	1	0	0.631
Positive	19	1	1	
Straight				
Negative	25	1	0	0.407
Positive	11	1	1	
Petrosal				
Negative	33	2	1	0.024
Positive	3	0	0	
DCV				
Negative	33	1	1	0.274
Positive	3	1	0	
Others				
CAV	1	0	0	0.169
IJV	1	1	0	
Negative	34	1	1	

In our study population, 95% showed complete recovery, which is contrary to studies by Banakar *et al.*[15] (44.3% had poor outcome). Moreover, among risk factors prevalent in our study population, puerperium correlates significantly with the incidence of cerebral venous thrombosis ($P < 0.0001$). Other risk factors such as chronic alcoholism and OCP use does not correlate

Table 3: Correlation of radiological features with outcome of CVT

MRI brain	Outcome			Total	*P* value
	Complete recovery	Death	Not recovered		
Non-specific findings	3	0	0	3	0.579
Edema	8	0	0	8	
Hemorrhage	15	2	0	17	
Normal	10	0	1	11	
Total	36	2	1	39	

significantly with CVT prevalence (P = 0.592, 0.972, respectively) [Table 1]. One patient was diagnosed with connective tissue disorder (SLE) after the occurrence of CVT in our study group.

Moreover, while comparing imaging findings with the outcome, the involvement of superior sagittal sinus, deep cerebral veins, an extension of thrombus up to internal jugular vein, and multiple extensive venous channels involvement were associated with poor outcome but it does not correlate significantly with death in our study due to small number of deaths in our study group (P = 0.259, 0.274, and 0.169, respectively) [Table 3]. In contrast, involvement of straight sinus was associated with poor outcome in a study by De Bruijn *et al.*[24] Moreover, the occurrence of frank intracerebral hemorrhage at presentation also predicts poor outcome yet significant correlation was not found in our study population due to same reason of small number of deaths deaths (P = 0.579) [Table 2].

CONCLUSION

Cerebral venous thrombosis, due to its broad spectrum of clinical presentation, might be confused with other pathologies, and hence, the diagnosis may get easily missed or delayed. The clinical picture can vary from headache to coma. CVT should be suspected when a young adult presents with stroke, particularly in the absence of vascular risk factors. Likewise, peripartum CVT is the leading risk factor in our setting, thus enforcing the importance of suspecting CVT in every peripartum female with neurological symptoms. Importantly, CVT should always be suspected whenever imaging of the brain shows hemorrhagic infarct, especially in non-arterial territories.

Although the outcome of CVT is in general good if promptly diagnosed and treated, the predictors of poor outcome and death such as involvement of deep cerebral veins, presentation with coma, or frank intracerebral hemorrhage in our study group may help us to provide extra vigilance in case of at-risk patients.

REFERENCES

1. Bousser MG, Ferro JM. Cerebral venous thrombosis: An update. Lancet Neurol 2007;6:162-70.
2. Bhojo AK, Mohammad W, Mohammed S, Erum S, Shahid MF, Ayeesha KK. Cerebral venous thrombosis: A descriptive multicenter study of patients in Pakistan and Middle East. Stroke 2008;39:2707-11.
3. Bansal BC, Gupta RR, Prakash C. Stroke during pregnancy and puerperium in young females below the age of 40 years as a result of cerebral venous/venous sinus thrombosis. Jpn Heart J 1980;21:171-83.
4. Bousser MG. Cerebral venous thrombosis: Diagnosis and management. J Neurol 2000;247:252-8.
5. Siddiqui FM, Kamal AK. Incidence and epidemiology of cerebral venous thrombosis. J Pak Med Assoc 2006;56:485-7.
6. Pillai LV, Ambike DP, Nirhale S, Husainy SM, Pataskar S. Cerebral venous thrombosis: An experience with anticoagulation with low molecular weight heparin. Indian J Crit Care Med 2005;9:14-8.
7. Wasay M, Azeemuddin M. Neuroimaging of cerebral venous thrombosis. J Neuroimaging 2005;15:118-28.
8. Panagariya A, Maru A. Cerebral venous thrombosis in pregnancy and puerperium--a prospective study. J Assoc Physicians India 1997;45:857-9.
9. Kamal MK. Computed tomographic imaging of cerebral venous thrombosis. J Pak Med Assoc 2006;56:519-22.
10. Sajjad Z. MRI and MRV in cerebral venous thrombosis. J Pak Med Assoc 2006;56:523-6.
11. Janjua N. Cerebral angiography and venography for evaluation of cerebral venous thrombosis. J Pak Med Assoc 2006;56:527-30.
12. Vogl TJ, Bergman C, Villringer A, Einhäupl K, Lissner J, Felix R. Dural sinus thrombosis: Value of venous MR angiography for diagnosis and follow-up. AJR Am J Roentgenol 1994;162:1191-8.
13. Ameri A, Bousser MG. Cerebral venous thrombosis. Neurol Clin 1992;10:87-111.
14. Ferro JM, Canhão P, Stam J, Bousser MG, Barinagarrementeria F, ISCVT investigators. Prognosis of cerebral vein and dural sinus thrombosis: Results of the International Study on Cerebral Vein and Dural Sinus Thrombosis (ISCVT). Stroke 2004;35:664-70.
15. Banakar BF, Hiregoudar V. Clinical profile, outcome, and prognostic factors of cortical venous thrombosis in a tertiary care hospital, India. J Neurosci Rural Pract 2017;8:204-8.
16. Ozsvath RR, Casey SO, Lustrin ES, Alberico RA, Hassankhani A, Patel M. Cerebral venography: Comparison of CT and MR projection venography. AJR Am J Roentgenol 1997;169:1699-707.
17. Virapongse C, Cazenave C, Quisling R, Sarwar M, Hunter S. The empty delta sign: Frequency and significance in 76 cases of dural sinus thrombosis. Radiology 1987;162:779-85.
18. Daif A, Awada A, Al-Rajeh S, Abduljabbar M, Al Tahan AR, Obeid T, *et al*. Cerebral venous thrombosis in adults. A study of 40 cases from Saudi Arabia. Stroke 1995;26:1193-5.
19. Narayan D, Kaul S, Ravishankar K, Suryaprabha T, Bandaru SC, Rukmini Mridula K, *et al*. Risk factors, clinical profile, and long-term outcome of 428 patients of cerebral sinus venous thrombosis: Insights from Nizam's Institute Venous Stroke Registry, Hyderabad (India). Neurol India 2012;60:154-9.
20. Halesh BR, Chennaveerappa PK, Vittal BG, Jayashree N. A study of the clinical features and the outcome of cerebral venous sinus thrombosis in a tertiary care centre in South India. J Clin Diagn Res 2011;5:443-7.

21. Barinagarrementeria F, Cantu C, Arredondo H. Aseptic cerebral venous thrombosis: Proposed prognostic scale. J Stroke Cerebrovasc Dis 1992;2:34-9.
22. Einhäupl KM, Villringer A, Meister W, Mehraein S, Garner C, Pellkofer M, *et al*. Heparin treatment in sinus venous thrombosis. Lancet 1991;338:597-600.
23. Stolz E, Rahimi A, Gerriets T, Kraus J, Kaps M. Cerebral venous thrombosis: An all or nothing disease? Prognostic factors and long-term outcome. Clin Neurol Neurosurg 2005;107:99-107.
24. De Bruijn SF, Budde M, Teunisse S, De Haan RJ, Stam J. Long-term outcome of cognition and functional health after cerebral venous sinus thrombosis. Neurology 2000;55:269-74.

How to cite this article: How to cite this article: Raj AT, Kiruthika R, Sownthariya R. Study of Clinical and Radiological Presentation of Cerebral Venous Thrombosis and its Outcome – A Prospective Study. Int J Sci Stud 2021;8(10):151-157.

Source of Support: Nil, **Conflicts of Interest:** None declared.