Original Article

DOI: 10.17354/ijss/2015/412

Correlation of Non-alcoholic Fatty Liver Disease and Diabetes Mellitus

S Ranjani[1], F Abubacker Sulaiman[2], Srinivasa Mudali[3], Ashraf Ahmed[4], Karunya Lakshmi[5]

[1]Post-graduate, Department of Radiology and Imaging Sciences, Chettinad Hospital and Research Institute, Kelambakkam, Kanchipuram, Tamil Nadu, India, [2]Associate Professor, Department of Radiology and Imaging Sciences, Chettinad Hospital and Research Institute, Kelambakkam, Kanchipuram, Tamil Nadu, India, [3]Professor, Department of Radiology and Imaging Sciences, Chettinad Hospital and Research Institute, Kelambakkam, Kanchipuram, Tamil Nadu, India, [4]Assistant Professor, Department of Radiology and Imaging Sciences, Chettinad Hospital and Research Institute, Kelambakkam, Kanchipuram, Tamil Nadu, India, [5]Post-graduate Resident, Department of Radiology and Imaging Sciences, Chettinad Hospital and Research Institute, Kelambakkam, Kanchipuram, Tamil Nadu, India

Abstract

Introduction: The non-alcoholic fatty liver disease is a metabolic disorder that has typical characteristics of insulin resistance. The portal vein transports the glucose absorbed from the intestinal tract to the liver. Though the metabolism of glucose is controversial, some authors suggest that absorbed glucose is retained in the liver, so the rise in peripheral glucose concentrations shows the effect on postprandial glucose levels. Thus, this proves liver's major role in the regulation of systemic blood glucose levels. Hence, non-alcoholic fatty liver disease tends to cause diabetes due to impairments in liver function. The grading of fatty liver is done with radiological imaging and their respective postprandial sugar levels are analyzed.

Aim: The aim of the study is to assess the correlation of non-alcoholic fatty liver and diabetes mellitus.

Materials and Methods: Ultrasound reports of 100 patient non-alcoholics were collected prospectively from January to May 2015. The co-relation of sugar levels and grading in ultrasound is done, and respective percentages were obtained.

Results: Out of 100 cases, 30 and above aged patients were diagnosed to have fatty liver, and they were more prone to diabetes mellitus with glucose levels higher as the grading increases.

Conclusion: In general, patients presenting with fatty liver in ultrasound examination should check for diabetes as they have more chances and as the grade of fatty liver in ultrasound increases the probability of occurrence of diabetes mellitus also increases.

Key words: Diabetes mellitus, Fatty liver, Ultrasound

INTRODUCTION

Non-alcoholic fatty liver disease always has natural co-existence of diabetes mellitus. It is a clinicopathologic condition of steatohepatitis in patients who do not consume alcohol. It is a wide range of metabolic syndrome.[1] It is a progressive disease from non-alcoholic steatosis to hepatic cancer rarely. Ballooning of hepatocytes due to the accumulation of fat and lobular inflammation, which is a typical characterization of non-alcoholic fatty liver disease.

Access this article online

www.ijss-sn.com

Month of Submission : 07-2015
Month of Peer Review : 08-2015
Month of Acceptance : 09-2015
Month of Publishing : 09-2015

It is the most common disease found in large population worldwide. Many studies have proven that non-alcoholic fatty liver is found to be in present in diabetes mellitus patient.[2]

The non-alcoholic fatty liver disease can be diagnosed using various imaging modality such as computed tomography, ultrasound, and histology. Where in ultrasound proves to be accurate and safe out of other noninvasive modality.[3,4] Though computed tomography and magnetic resonance imaging serves to be more accurate but has its own disadvantage of using ionizing and time-consuming procedure. The grading of fatty liver is done based on the appearance of the liver and its vascular structures. Diabetes mellitus is quite prevalent among all age groups wherein the predisposing factors such as obesity and impairment of lipid metabolism in the liver. In a study conducted on obese

Corresponding Author: Dr. Abubacker Sulaiman F, Department of Radiology and Imaging Sciences, Chettinad Hospital and Research Institute, Kelambakkam, Kanchipuram - 603 103, Tamil Nadu, India. Phone: +91-9710754999. E-mail: fasulaiman@hotmail.com

women with diabetes, it was proven that all the women had non-alcoholic fatty liver disease with elevated liver enzymes.[4-7]

Grading of fatty liver is done from Grade 0 to Grade III, where Grade 0 is normal appearance of liver with normal echotexture and size of liver (Figure 1), and as grade increases the echogenicity as the grade increases.

The increase in echogenicity solemnly depends on the accumulation of fat in hepatocytes, which makes the liver appear darker and reduces the contrast of the image. This makes the anechoic vascular structures invisible or unable to differentiate in terms of contrast.

Diabetes mellitus proven to be more earlier predictor of non-alcoholic fatty liver disease, which is been proven in many studies. Though ultrasound tends to have its own limitations in accuracy, it is proven to be better than other invasive techniques.

MATERIALS AND METHODS

In 100 non-alcoholic patients who have fulfilled the inclusion criteria are selected, and their liver are imaged using ultrasound and their postprandial sugar levels are diagnosed and a statistical co-relation of the collected data is done. The grading of fatty liver is done based on the appearance of liver's echogenicity and size is examined.

In Grade I, there is mild increase in echoes when compared to normal echogenicity with diaphragm appearing normal (Figure 2).

In Grade II, there is diffused increase in echoes and impaired appearance of anechoic vascular structures (Figure 3).

In Grade III, there is marked increase in echoes and no visualization of diaphragm and vasculature, due to loss of penetration of ultrasound waves. There is an increase in liver size also (Figure 4).

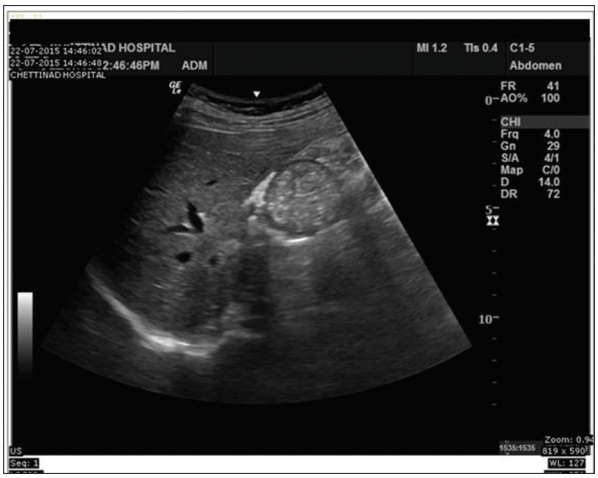

Figure 1: Grade 0 Fatty liver

Figure 3: Grade 2 Fatty liver

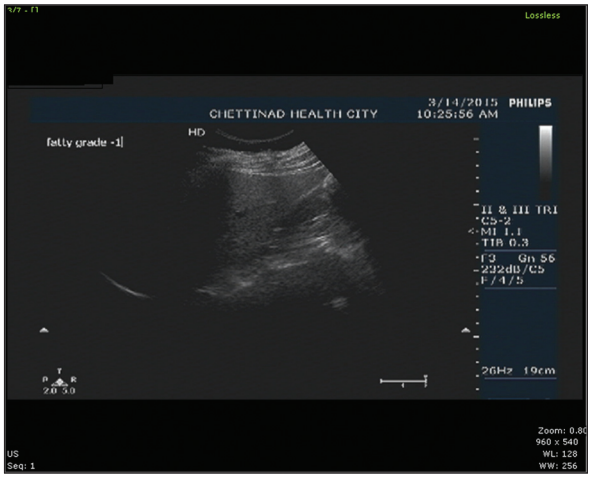

Figure 2: Grade 1 Fatty liver

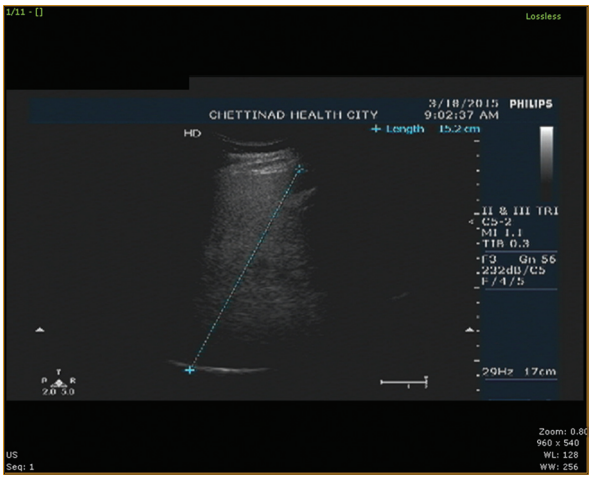

Figure 4: Grade 3 Fatty liver

These patients blood samples are collected and their postprandial sugar levels are investigated the values are collected, and statistical evaluation is done.

RESULTS

The study revealed that there is a significant correlation in fatty liver and occurrence of diabetes mellitus in patients without influence of alcohol consumption. In my study, it was 20 patients were graded to be Grade 0, i.e., normal appearance of liver, and out of it 17 patients had normal postprandial sugar levels (90-140 mg/dl) (Graph 1) and 3 patients had mild increase in sugar level (145-158 mg/dl) (Graph 2). About 38 patients were diagnosed to be Grade I in ultrasound examination (Graph 3), 24 patients were diagnosed to Grade II and 18 patients were diagnosed to be Grade III (Graph 4). Patients with Grade II and III fatty liver disease had obvious increase in postprandial blood sugar level. Grade I disease show borderline increase in sugar levels.

DISCUSSIONS

In our study, we were able to conclude that there was an association of non-alcoholic fatty liver and occurrence of diabetes mellitus. It was statistically proven that there was strong co-relation as grading of fatty liver increases there is a marked increase in postprandial sugar values. Thus which reveals that prevalence of diabetes mellitus is more when the severity of fat accumulation increases in the liver.[8] Hence, we were able to use the grading of fatty liver using ultrasound as a predictor for occurrence of diabetes mellitus. Though the sensitivity of ultrasound grading should be taken into account where the specificity is quite less comparatively other advanced modalities such as computed tomography, magnetic resonance imaging, and biopsy. However, few years before biopsy was considered to be ideal modality of diagnosing fatty liver due to the evolution of ultrasound and other non-invasive modalities nowadays it became obsolete.[9-11]

Administration of lipid-lowering drugs has been evaluated in patients with NAFLD/NASH, but not in large prospective controlled trials, and it has been associated with biochemical and histological improvement, but not all studies. The use of statins appears to be safe in patients monitored closely, to treat hyperlipidemia.[12]

The study shows that non-alcoholic fatty liver disease grading tends to be a precursor for the early detection of diabetes mellitus and which can be used an early diagnostic tool in detection of diabetes mellitus. This tends to prove that the prevalence of diabetes mellitus in non-alcoholic fatty liver disease patients is higher on higher grades such as Grade II and Grade III. In Grade 0, i.e., control group the blood glucose level is almost normal. And those patients who are likely to be diabetic are advised some lifestyle changes and weight control management to control their

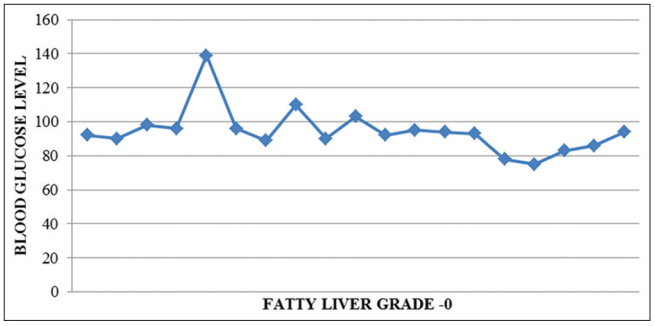

Graph 1: Fatty liver grade-0

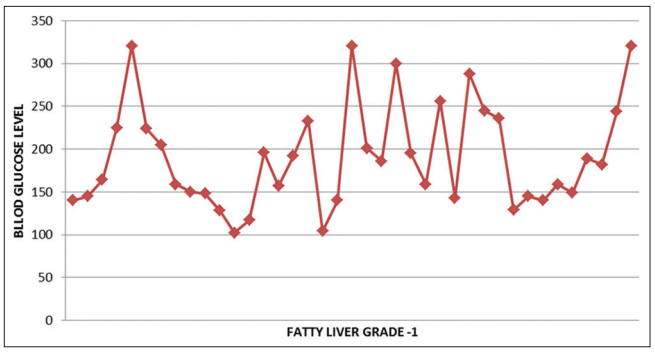

Graph 2: Fatty liver grade-1

Graph 3: Fatty liver grade-2

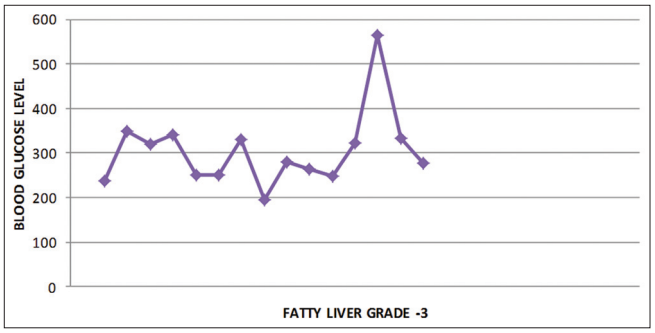

Graph 4: Fatty liver grade-3

blood glucose levels,[13] with follow-up checkup. There have been many studies proven earlier that non-alcoholic fatty liver disease patients are more prevalent to diabetes mellitus. In this study, the results seem to be similar. The age group of non-alcoholic fatty liver disease is commonly middle-aged group, especially 30 years old and above is more prone. The grade of fatty liver and as well as blood glucose levels seems to be high.[14]

CONCLUSIONS

In our study, we were able to conclude that there is strong association of non-alcoholic fatty liver and occurrence of diabetes mellitus. It is statistically proven that there is strong co-relation as grading of fatty liver increases there is a marked increase in postprandial sugar values.

ACKNOWLEDGMENT

With great pleasure and profound gratitude, authors deeply express their sincere thanks to their Vice Chancellor Prof. Dr. K Ravindran, Chettinad University for all his support. Authors feel privileged to express our sincere thanks to their Chief Radiographer Mr. P. M. Sethu Madhavan and all the radiology department staffs for their valuable support.

REFERENCES

1. Charlton M. Nonalcoholic fatty liver disease: A review of current understanding and future impact. Clin Gastroenterol Hepatol 2004;2:1048-58.
2. Bedogni G, Miglioli L, Masutti F, Tiribelli C, Marchesini G, Bellentani S. Prevalence of and risk factors for nonalcoholic fatty liver disease: The dionysos nutrition and liver study. Hepatology 2005;42:44-52.
3. Machado M, Marques-Vidal P, Cortez-Pinto H. Hepatic histology in obese patients undergoing bariatric surgery. J Hepatol 2006;45:600-6.
4. Namikawa C, Shu-Ping Z, Vyselaar JR, Nozaki Y, Nemoto Y, Ono M, *et al.* Polymorphisms of microsomal triglyceride transfer protein gene and manganese superoxide dismutase gene in non-alcoholic steatohepatitis. J Hepatol 2004;40:781-6.
5. de Alwis NM, Day CP. Non-alcoholic fatty liver disease: The mist gradually clears. J Hepatol 2008;48:S104-12.
6. Jou J, Choi SS, Diehl AM. Mechanisms of disease progression in nonalcoholic fatty liver disease. Semin Liver Dis 2008;28:370-9.
7. Vuppalanchi R, Chalasani N. Nonalcoholic fatty liver disease and nonalcoholic steatohepatitis: Selected practical issues in their evaluation and management. Hepatology 2009;49:306-17.
8. Haukeland JW, Damås JK, Konopski Z, Løberg EM, Haaland T, Goverud I, *et al.* Systemic inflammation in nonalcoholic fatty liver disease is characterized by elevated levels of CCL2. J Hepatol 2006;44:1167-74.
9. Hui JM, Hodge A, Farrell GC, Kench JG, Kriketos A, George J. Beyond insulin resistance in NASH: TNF-alpha or adiponectin? Hepatology 2004;40:46-54.
10. Crespo J, Cayón A, Fernández-Gil P, Hernández-Guerra M, Mayorga M, Domínguez-Díez A, *et al.* Gene expression of tumor necrosis factor alpha and TNF-receptors, p55 and p75, in nonalcoholic steatohepatitis patients. Hepatology 2001;34:1158-63.
11. Yuan M, Konstantopoulos N, Lee J, Hansen L, Li ZW, Karin M, *et al.* Reversal of obesity- and diet-induced insulin resistance with salicylates or targeted disruption of Ikkbeta. Science 2001;293:1673-7.
12. Hoad CL, Marciani L, Kaye P, Guha IN, Costigan C, Austin A, *et al.* Qualitative magnetic resonance imaging (MRI) in the evaluation of the degree of steatosis, iron accumulation and fibrosis in chronic liver diseases (MRKER study). Gut 2011;60:A55-6.
13. Choi CS, Savage DB, Kulkarni A, Yu XX, Liu ZX, Morino K, *et al.* Suppression of diacylglycerol acyltransferase-2 (DGAT2), but not DGAT1, with antisense oligonucleotides reverses diet-induced hepatic steatosis and insulin resistance. J Biol Chem 2007;282:22678-88.
14. Targher G, Bertolini L, Padovani R, Rodella S, Tessari R, Zenari L, *et al.* Prevalence of nonalcoholic fatty liver disease and its association with cardiovascular disease among type 2 diabetic patients. Diabetes Care 2007;30:1212-8.

How to cite this article: Ranjani S, Sulaiman AF, Mudali S, Ahmed A, Lakshmi K. Correlation of Non-alcoholic Fatty Liver Disease and Diabetes Mellitus. Int J Sci Stud 2015;3(6):148-151.

Source of Support: Nil, **Conflict of Interest:** None declared.