Print ISSN: 2321-6379
Online ISSN: 2321-595X

Case Report

Takayasu Arteritis in Young Female Present with Fever and Hypotension

H O Gupta, Tapasaya Nanda, Anshuman Tiwari, Vaibhav Meshram

Department of Medicine, Shyam Shah Medical College and Sanjay Gandhi Memorial Hospital, Rewa, Madhya Pradesh

Abstract

Takayasu arteritis also known as pulseless disease/reverse coarctation of aorta is an uncommon, inflammatory, stenotic disease of medium and large size arteries, with estimated annual incidence rate of 1.2–2.6 cases per million, most prevalent in adolescent girls and young women. We hereby reporting a clinical case of Takayasu arteritis presented with a complaint of fever, headache, right shoulder pain, and low blood pressure; she was dengue positive, no response with symptomatic therapy.

Key words: Medium- and large-sized vessels, Pulseless disease, Stenotic disease, Takayasu arteritis

INTRODUCTION

Takayasu arteritis is large vessel granulomatous vasculitis, most commonly affected artery seen by arteriography is subclavian artery.

Frequency of arteriographic abnormalities and potential clinical manifestation of arterial involvement in Takayasu arteritis.

Artery	% of arteriographic abnormalities	Potential clinical manifestation
Subclavian artery	93	Arm claudication, Raynaud`s phenomenon
Common carotid	58	Visual changes, syncope, TIA, stroke
Abdominal aorta	47	Abdominal pain, nausea, and vomiting
Renal	38	Hypertension, renal failure

The involvement of major branches of aorta is much more marked proximally than distally with marked intimal proliferation, fibrosis, scaring, vascularisation of media, destruction, degeneration of elastic lamina, narrowing of lumen occur with or without thrombosis, and vasa vasorum are frequently involved.

Access this article online

www.ijss-sn.com

Month of Submission : 01-2019
Month of Peer Review : 02-2019
Month of Acceptance : 02-2019
Month of Publishing : 03-2019

Geographical distribution – endemic in Japan and Southeast Asia (India), it is neither racially nor geographically restricted.[7]

This is systemic disease with generalized as well as vascular symptoms include malaise, fever, night sweats, arthralgia, and weight loss, which may occur month before vessel involvement is apparent, this symptoms merge into those related to vascular compromise and organ ischemia, pulse absent in involve vessel, particularly subclavian artery, hypertension occurs 32–93% of patients contribute to renal, cardiac, and cerebral injury.

Diagnosis of Takayasu arteritis should be suspected strongly in young women, who develop decrease or absent peripheral pulses, discrepancies in blood pressure (BP), and arterial bruit, the diagnosis is confirmed by characteristic pattern of arteriography which includes irregular vessel wall stenosis post-stenotic dilatation, aneurysm formation, occlusion, and evidence of increased collateral circulation,[9] most important laboratory findings are anemia and marked elevation of erythrocyte sedimentation rate or C-reactive protein. The gold standard of diagnosis is vascular study by arterial angiography, magnetic resonance angiography, and computed tomography angiography resonance.[1-4]

Clinical Criteria

Based on the American College of Rheumatology – 3 of 6

Corresponding Author: Dr. Tapasaya Nanda, Department of Medicine, Shyam Shah Medical College and Sanjay Gandhi Memorial Hospital, Rewa, Madhya Pradesh - 486001.

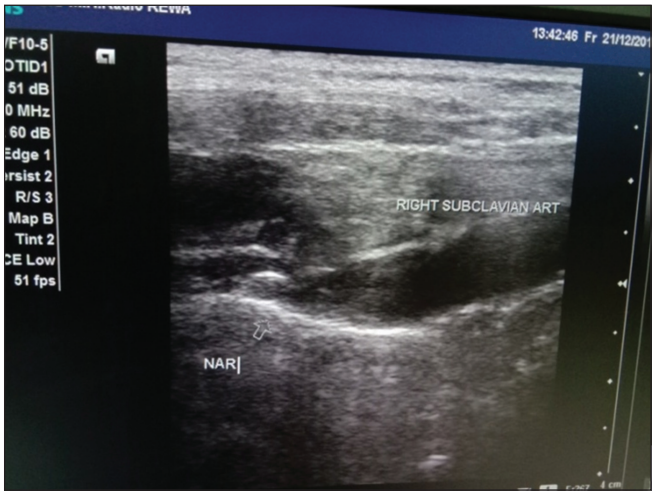

Figure 1: Narrowing of Right Subclavian Artery

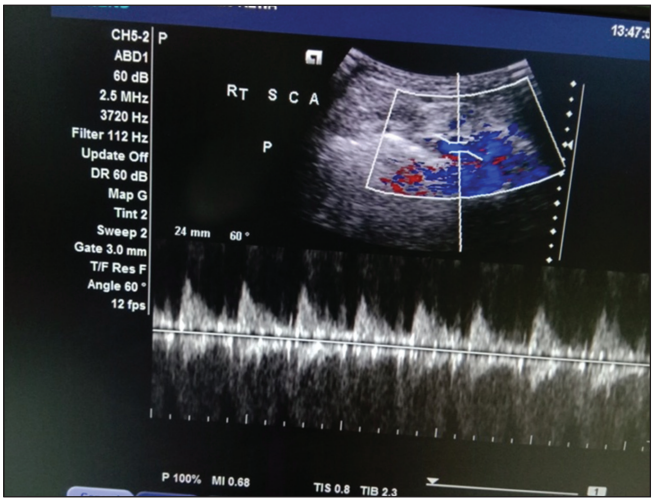

Figure 4: Narrowing of Right Subclavian Artery

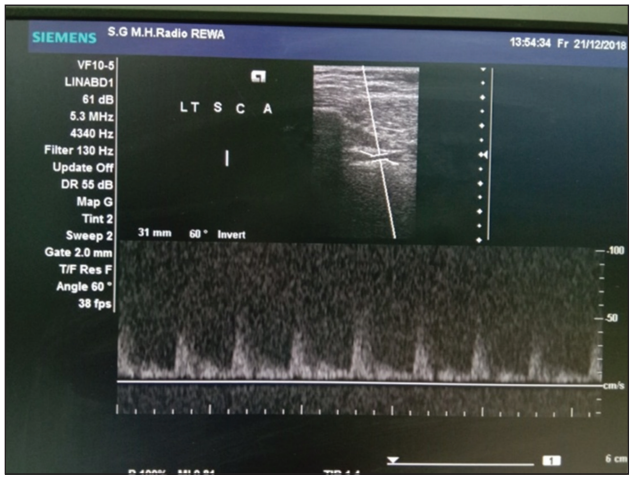

Figure 2: Narrowing of Right Subclavian Artery

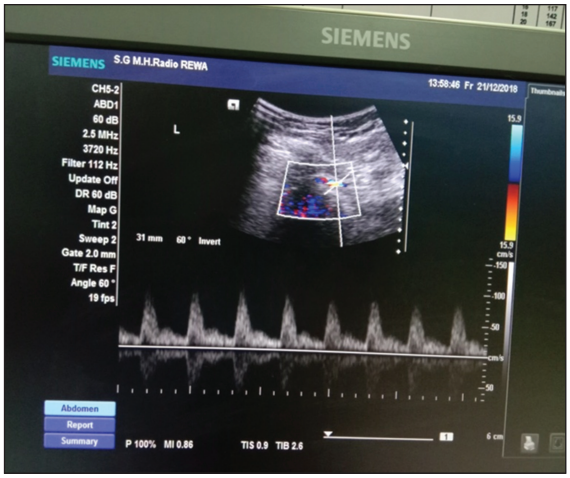

Figure 5: Narrowing of Right Subclavian Artery

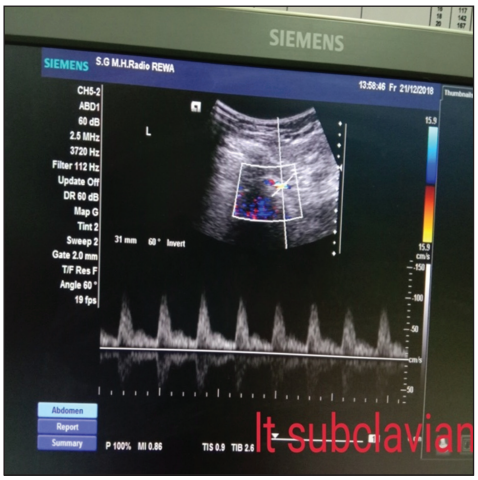

Figure 3: Narrowing of Right Subclavian Artery

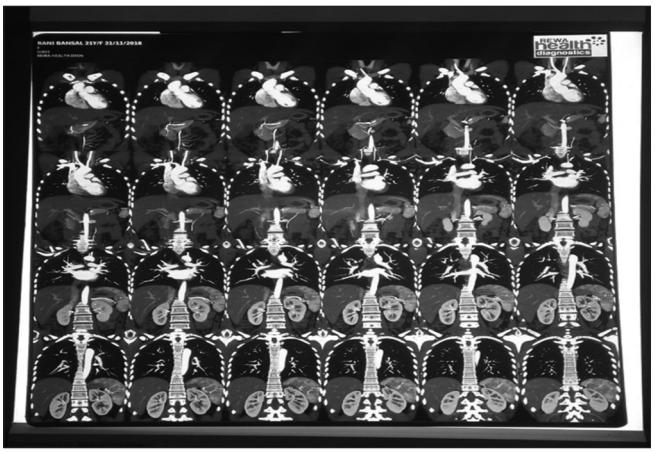

Figure 6: CT Angio. Chest & Upper abdomen

- Age <40 years.
- Arm claudication.
- Pulselessness.
- Difference of upper limb systolic BP>10 mmHg.
- Bruit over subclavian vessel or abdominal aorta.
- Angiographic demonstration of aorta and its branches.

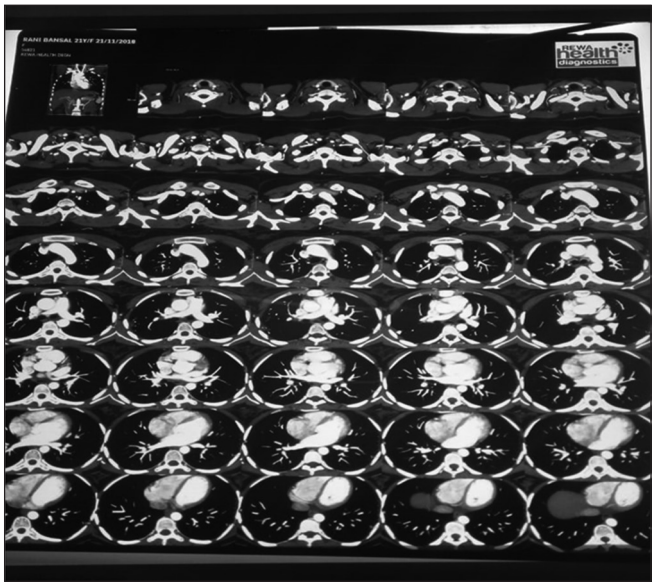

Figure 7: CT Angio. Chest & Upper abdomen

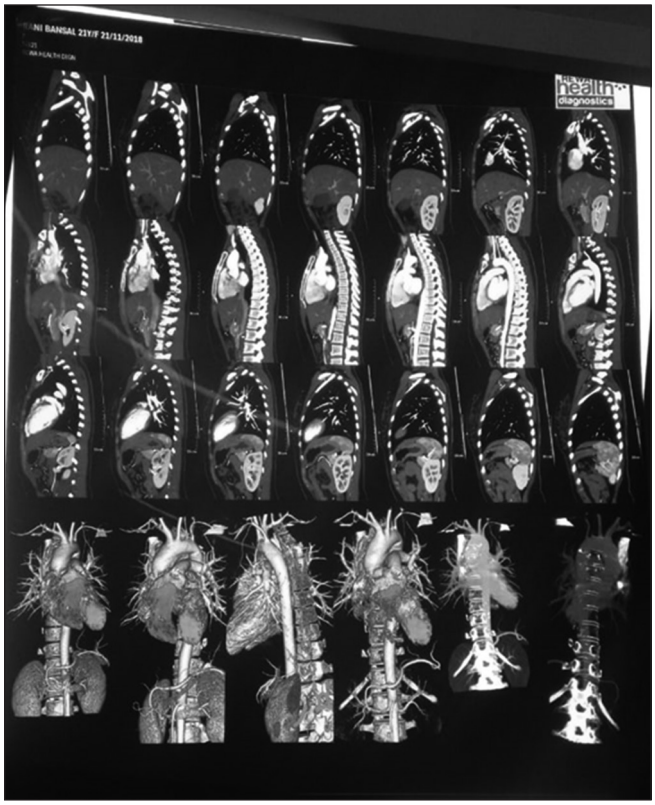

Figure 8: CT Angio. Chest & Upper abdomen

CASE REPORT

A 21-year-old female presented to our department with a chief complaint of fever and headache for 3 days, the patient had similar history of fever and headache for 6–7 years and also a history of pain in the right shoulder and fatigue and dizziness for the past 3–4 years. The patient is visiting frequently in near local clinics and improved by symptomatic treatment. History of pulmonary tuberculosis in childhood took complete treatment of 6 months.

On examination, the patient well-nourished with pulse absent on the right side, pulse was very feeble in the left side and BP recorded 90/60 by auscultatory method, and other peripheral pulses are palpable.

Investigation

CBC		
Hb-7	Total bilirubin - 0.2	ANCA - 7.4
mcv-85	OT/PT - 21/13	ANA - 17.3
TLC-2600 (65/30/3/2)	Total protein - 4.37	RF factor IgG - 5.6
Platelet - 1.18	Blood urea - 12	RF factor IgM - 4.8
	Serum creatinine - 0.52	

ANCA: Antineutrophil cytoplasmic antibodies, TLC: Thin-layer chromatography

- Fundus – wnl
- Two-dimensional echocardiogram – wnl,
- Carotid Doppler – normal
- Color Doppler of subclavian and axillary artery – showed stenotic lesion. Images are given below

Computerized Tomography (Ct) Angiogram Chest And Upper Abdomen

It reveals long segment >50% diameter stenosis of bilateral distal subclavian and axillary artery, right more than left with associated mild circumferential arterial wall thickening the involved arterial segment possibly arteritis? Takayasu arteritis.

Color Doppler Of Subclavian And Axillary Artery

It showed stenotic lesion. Images are given below.

DISCUSSION

As we know, the Takayasu arteritis disease is very slow growing so the patient was asymptomatic for many years. First time the patient diagnosed in our hospital accidently due to she was admitted for fever, and arthralgia with shoulder and arm pain.

On examination, arterial pulsation of upper limb feeble, even pulse absent on the right side, pressure difference in both upper limbs, after examination, the patient suspects on Takayasu arteritis and proceeds for further investigation.

On further investigation, CT angiogram chest and upper abdomen suggestive of bilateral distal subclavian (>50% of diameter) on Doppler carotid and subclavian right sided was more stenotic than left.

My patient was good response with steroid therapy.[1-4]

CONCLUSION

The study of this type of case suggests whenever young female come with a history of fever, headache, and arm claudication; they should have investigation for Takayasu arteritis or similar middle- to large-sized arteries vessel wall disease.

REFERENCES

1. Ghosh JC, Sen Gupta SN. Case of reverse coartation syndrome; An aortic arch syndrome. Br Med J 1957;1:137-9.
2. Kasper DL, Fauci AS, Hauser SL, Longo DL, Jameson JL, Loscalzo J. Takayasu arteritis. In: Harrison Principal of Internal Medicine. 20th ed. McGraw Hill Professional; 2018.
3. Barindra S, Deepak K, Dwijaraj S, Debnath K, Santa N. Primary tuberculosis of the thyroid gland-a rarity. J Indian Acad Clin Med 2006;7:363-4.
4. Krishna MV, Rudresh R, Namratha S. Takayasu's arteritis-stroke as an intial presentation. J Indian Acad Clin Med 2004;5:274-6.

How to cite this article: Gupta HO, Nanda T, Tiwari A, Meshram V. Takayasu Arteritis in Young Female Present with Fever and Hypotension. Int J Sci Stud 2019;6(12):245-248.

Source of Support: Nil, **Conflict of Interest:** None declared.