

# Use of Auricular Cartilage as A Graft in Cleft Rhinoplasty - 'An Ear For A Nose'

Vinay K N<sup>1</sup>, N Srinath<sup>2</sup>, H Nandakumar<sup>3</sup>, Sunil C<sup>4</sup>

1 MDS, MOMSRCPS, Oral and maxillofacial surgeon, Dar Al-Qudrah Medical Group, Riyadh 2 MDS, FDSRCS Professor, Department of Oral And Maxillofacial Surgery, Krishnadevaraya College Of Dental Sciences, Bangalore 3 MDS, Head of the Department and Professor, Department of Oral And Maxillofacial Surgery, Krishnadevaraya College of Dental Sciences Bangalore 4 MDS, Oral and maxillofacial surgeon, Venkateshwara Hospital, Bangalore

## Abstract

The aim is to study the use of auricular cartilage in cleft rhinoplasty. 10 patients with unilateral cleft lip nasal deformity underwent secondary cleft rhinoplasty using auricular cartilage as an onlay graft to augment the hypoplastic ala on the cleft side and also as a columellar strut. The patients were in the age group of 16 to 30 years, with a mean age of 21.1 years. All the cases have been followed up from the time of operation on a monthly basis up to a maximum of 24 months. The mean follow up period in this study was 12.8 months. Clinical analysis was performed preoperatively and 5 months post operatively and on a monthly basis ever since. The present study demonstrated that auricular cartilage proved to be a good onlay graft to augment the hypoplastic cartilage and also as a strong columellar strut. We have achieved a 23% decrease in the alar width, 30% increase in the alar height and 58% increase in the columellar height on the cleft side post operatively. There was no donor site or recipient site morbidity in any of our cases. Satisfactory results were obtained. This procedure can be regarded as a good method for correction of mild to moderate cleft lip nasal defects.

**Keywords:** Cleft rhinoplasty, Auricular cartilage

## Introduction:

The nose, as the most prominent facial feature, becomes the focus of psychologic and social attention when it is distinguished by anomalous features. Nasal aesthetics are central in our appreciation and attractiveness of the face. The balance of elements of the nose from any point of view affects the overall balance and aesthetics of the entire face. Understanding nasal aesthetics and the interdependence with the rest of the face is as important as the technical skill and expertise required to perform the elegant and complex operation of rhinoplasty.

Individuals born with a cleft lip have an associated characteristic nasal deformity. Cleft lip nasal deformity has lack of development of some

elements of the nose and displacement of other parts of the nasal anatomy. The cartilage giving shape to the tip of the nose is usually underdeveloped, flattened with less projection, and positioned lower than the tip cartilage. The nostril shape and width are not symmetrical. The septum is also deviated. One consequence of these cleft lip nasal deformities is nasal airway obstruction. Another consequence is the appearance that lacks symmetry and displays a characteristic appearance in the nose that may remain a reminder of the cleft lip, even after the best of cleft lip surgical repair.

Despite the current trend for increasing attention toward nasal reconstruction at the time of primary lip repair, a need still exists for achieving

aesthetic improvement of the cleft lip nasal deformity at a later date.

The final defining component receiving attention by parents, practitioners, and patients in achieving a normal appearance in a patient with cleft features currently is the nose. In current practice, we are better able to reconstruct the faces of children with cleft features to near-normal anatomic form and physiologic function. We are now able to counsel parents with modern knowledge and technology, and their children, whose appearance may seem somewhat disfiguring at birth, can be transformed into children with near normal appearances and acceptable smiles.

### **Methodology:**

The present study was done in Department Of Oral and Maxillofacial Surgery, Krishnadevaraya College of Dental Sciences, Bangalore. Ten patients with unilateral cleft lip nasal deformity underwent secondary cleft rhinoplasty using auricular cartilage as an onlay graft to augment the hypoplastic ala on the cleft side and also as a columellar strut. Auricular cartilage was harvested using posterior auricular approach. An open rhinoplasty was performed and the harvested cartilage was used as a columellar strut and also for reinforcing the lower lateral alar cartilage on the cleft side. Clinical analysis of patients was done pre-operatively (figure 1 and 2) and for 5 months post operatively.

### **Procedure:**

The patients were operated under general anaesthesia. This procedure consists of two steps. First auricular cartilage was harvested and then cleft rhinoplasty was performed.

### **Harvesting Auricular Cartilage:**

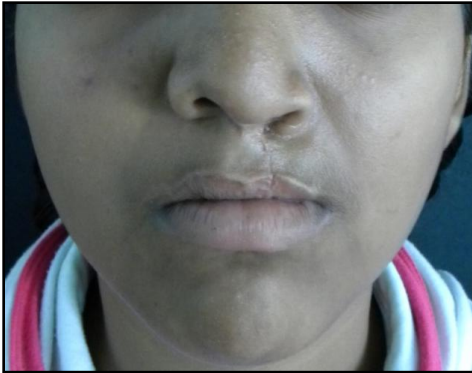Standard skin was preparation done. Patient was draped in a sterile fashion. A linear incision was marked in the retroauricular region (figure 3). About 5cc of local anesthesia with adrenaline (1:200000) was injected in the operative site. A linear incision was placed behind the ear. Overlying skin and

perichondrium were raised to expose the underlying auricular cartilage. The periphery of the desired graft was defined with an incision over the exposed cartilage. The cartilage was then slowly dissected off its underlying attachments and was harvested without causing any perforations in the graft and the underlying soft tissue (figure 4, 5, 6). One layer closure was achieved using ethilon 4-0 by placing continous locking sutures (figure 7). Betadine dressing was given over the sutures and pressure pack was placed over the concha.

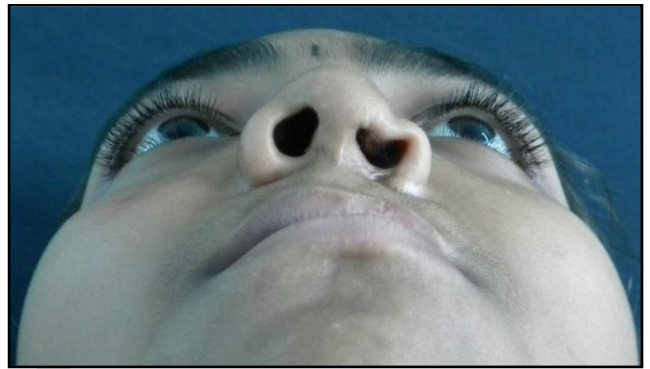### **Procedure of Rhinoplasty:**

An incision line was marked with indelible ink. Transcolumellar incision with infracartilagenous rim incision was marked bilaterally (figure 8). About 10cc of local anesthesia with adrenaline (1:200000) was injected in the operative site with a 26 gauge spinal needle. It facilitated hydro dissection, local hemostasis and post operative analgesia at the site. A 'V' shaped notch was made in the transcolumellar incision, which was placed at the junction of the lower one third and upper two third of the columella. The nostril rim was held gently with an alar hook and infracartilagenous rim incisions were placed. The skin was dissected over the tip and the alar cartilages in the submuscular aponeurotic plane. Dissection superficial to this plane results in compromise of the vascular supply to the soft tissues and makes the dissection very difficult. The lower lateral cartilages were freed of all its attachments. The entire cartilaginous skeleton of the lower lateral cartilages were exposed (figure 9).

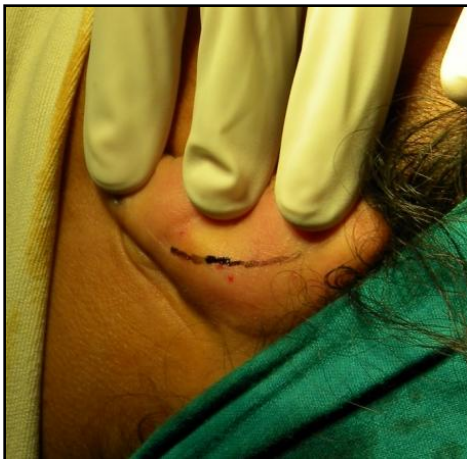The harvested auricular cartilage was divided into three strips over a sterile glass slab. One of the strips was used as an onlay graft over the deformed ala. It was sutured to the lateral crus (figure 10). A pocket was created in between the two medial crura in the columellar region. The remaining two strips were sutured to each other to form a columellar strut and placed in the pocket. It was then sutured with ethilon 4-0 to the medial crura on either side (figure 11). The degree of the tip projection needed on the deformed side as well as the columellar height was determined.



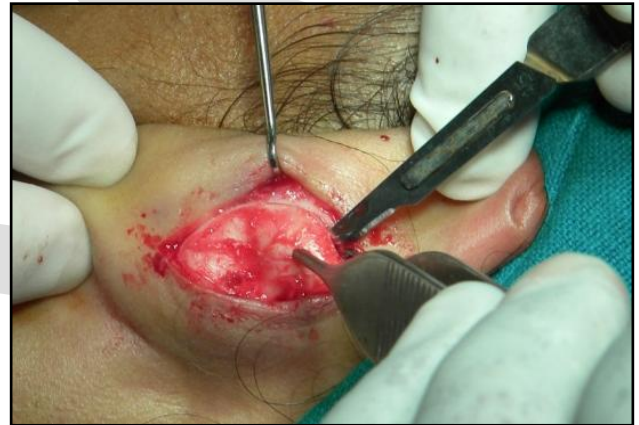**Figure 1: Pre-Operative Photograph Of the Defect**



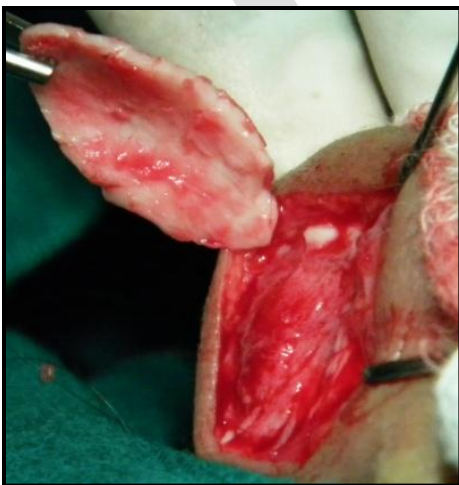**Figure 2: Pre Operative Worm's Eye**



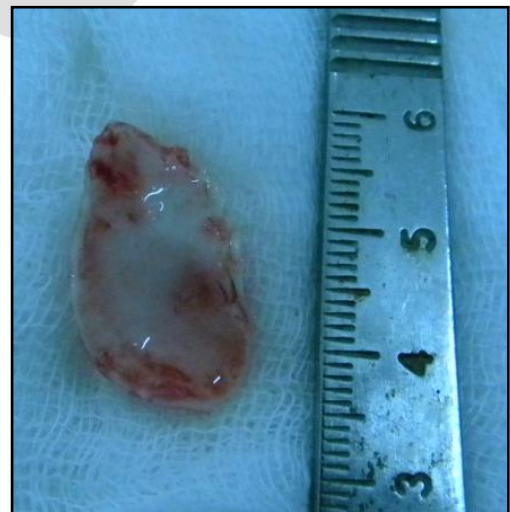**Figure 3: Linear Incision**



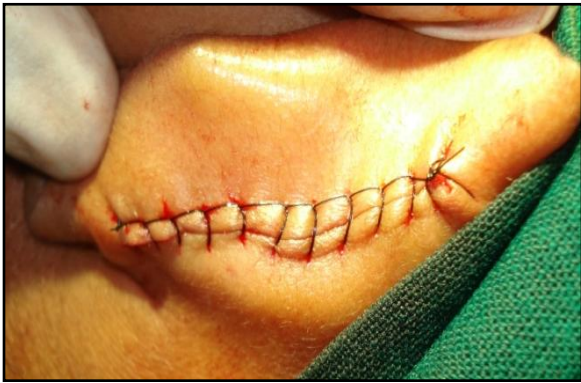**Figure 4: Auricular Cartilage Identified and Marked Before Harvesting**



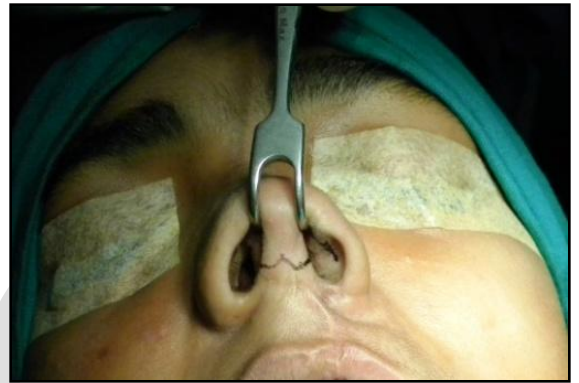**Figure 5: Auricular Cartilage Being Freed of Its Attachment from the Underlying Tissues**



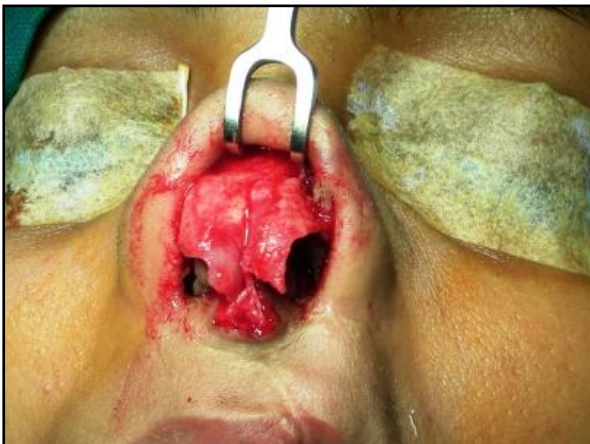**Figure 6: Auricular Cartilage**



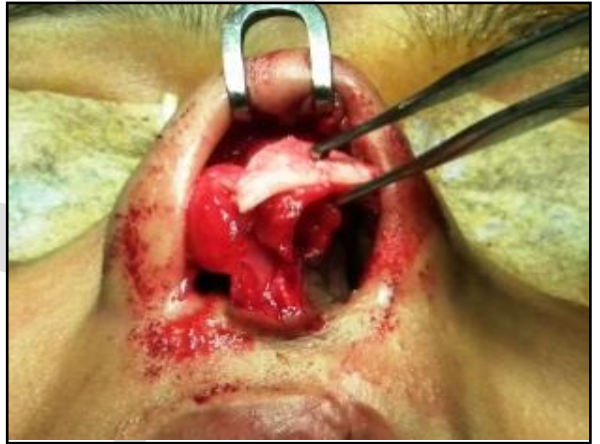**Figure 7: Continuous Locking Sutures Placed**



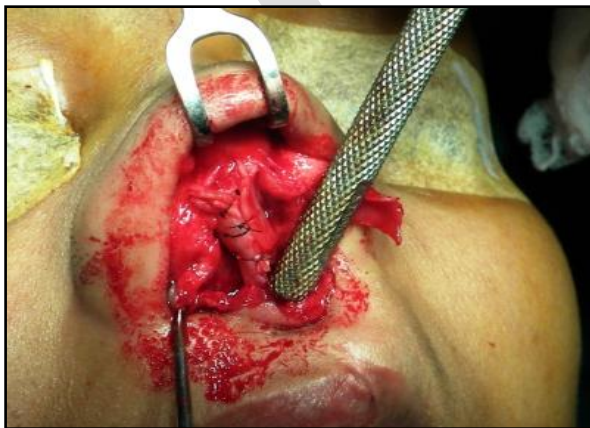
**Figure 8: Transcolumellar Incision Marked**



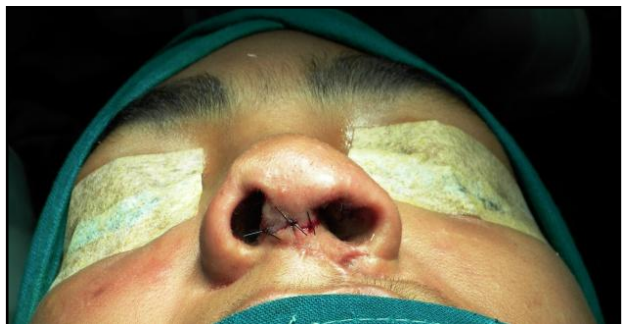**Figure 9: Dissection Done and Alar Cartilages Freed Completely from All**



**Figure 10: Onlay Alar Cartilage Graft Placed**



**Figure 11: Columellar Strut Placed and Sutured in the Pocket Created Between the Medial Crura**



**Figure 12: Final Closure Done**

Corrections were performed until the desired outcome was achieved. After augmentation was completed, incisions were closed endonasally with 4-0 vicryl, absorbable sutures. The skin and soft tissue envelope were carefully redraped over the nasal skeleton and sutured in place with 5-0 ethilon (figure 12). A soframycin nasal pack was placed and nasal dressing was done to hold the cartilaginous framework in the new desired position. Patients were educated on standard postoperative instructions. Appropriate postoperative prophylactic antibiotics were administered. Patients were advised to avoid any heavy lifting, straining, or vigorous physical activity. Nasal pack was removed on the 2<sup>nd</sup> postoperative day and the nasal dressing was repeated. All sutures were removed after 10 days. Nasal dressings were continued for another 10 days (figure 13 and 14).

### Results:

The patients were in the age group of 16 to 30 years, with a mean age of 21.1 years. All the cases have been followed up from the time of operation on a monthly basis upto 24 months. Clinical analysis was performed preoperatively and 5 months post operatively. Clinically they were evaluated for nasal width, Nasolabial angle, alar width, alar height, columellar height and the angle between medial and lateral crura. Photographs were taken in Frontal view, lateral view, worm's eye view and bird's eye view pre operatively and 5 months post operatively. The cleft lip nasal deformity is disfiguring mainly due to the asymmetry of the external nares, therefore the success of cleft rhinoplasty can be evaluated by comparing the differences between the non cleft and cleft side pre and post operatively.

We found that in all patients preoperatively on an average the alar width on the cleft side was 4 – 5 mm more than the non cleft side. The height of the columella and the ala on the cleft side was found to be 2-3 mm deficient. The Nasolabial angle was decreased and the intra crural angle was markedly obtuse on the cleft side. (figure 15 and 16)

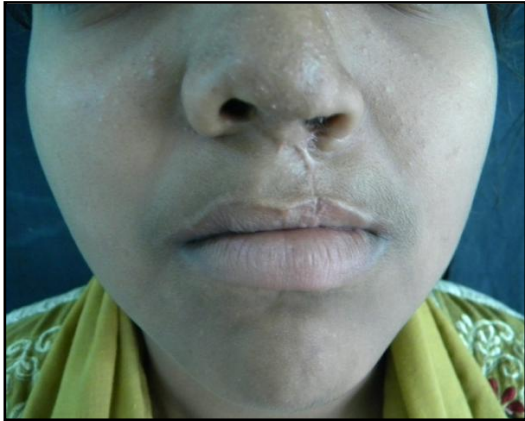Postoperatively when evaluated the changes observed on the non cleft side were not significant but whereas, on the cleft side, there were statistically significant changes. The mean alar width on the cleft side showed a decrease by 3 mm, columellar height and alar height increased by 1.5 mm, the nasal width decreased by 4-5mm, the Nasolabial angle increased by 10° and the intercrural angle decreased by 13.5° (figure 17 to 18) postoperatively on the cleft side there was a 23% decrease in the alar width, 30% increase in the alar height and 58% increase in the columellar height. Donor site morbidity was not seen in any patient and none of the patients developed any complications.

### Discussion:

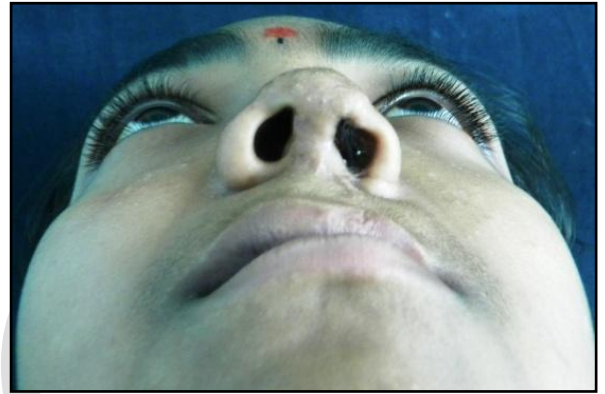
The nasal deformity in unilateral clefts is an integral part of the complex cleft syndrome that includes the lip, alveolus, palate, maxilla, and nose. Unilateral clefting, both complete and incomplete, results in a nasal deformity that may be caused by three major factors: (a) imbalance of the facial musculature, (b) hypoplasia of the skeletal base, and (c) asymmetry of the cartilaginous framework.<sup>1</sup>

#### Imbalance of the facial musculature

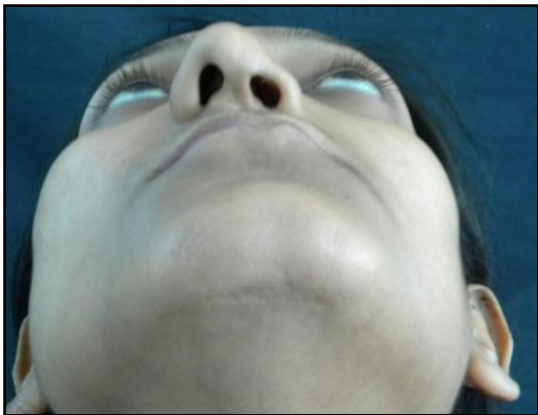
Muscle imbalance affects nasal symmetry. Disruption of the orbicularis oris muscle creates a situation in which the facial muscles attached to the orbicularis oris on the cleft side pull the base of the ala more laterally than on the normal side. The greater the separation of the orbicularis oris, the more severe the cleft nasal deformity. The existing muscle imbalance results in displacement of the alar base and changes the orientation of the nostril from oblique to horizontal. This affects the position of the lower lateral cartilage. Correction of the muscle imbalance, which takes place during primary lip repair, does not necessarily alleviate the existing nasal deformity totally because displacement of the lower lateral cartilage persists, resulting in a typical unilateral cleft lip nasal deformity.



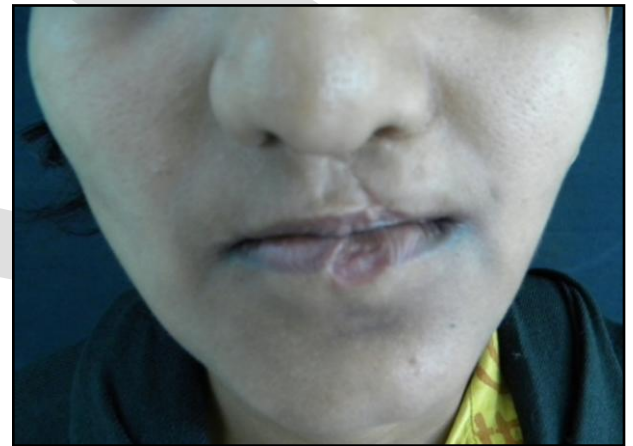**Figure 13: Five Months Post Operative**



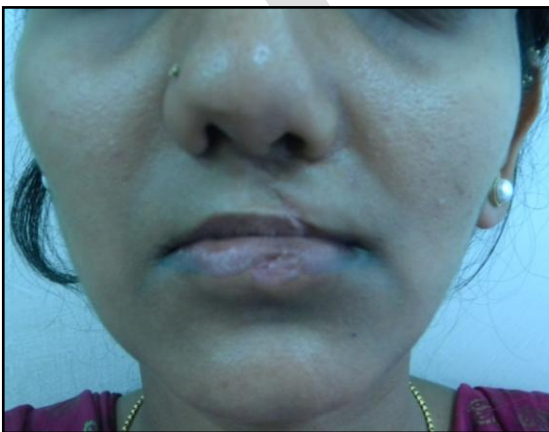**Figure 14: Post Operative Worm's Eye View**



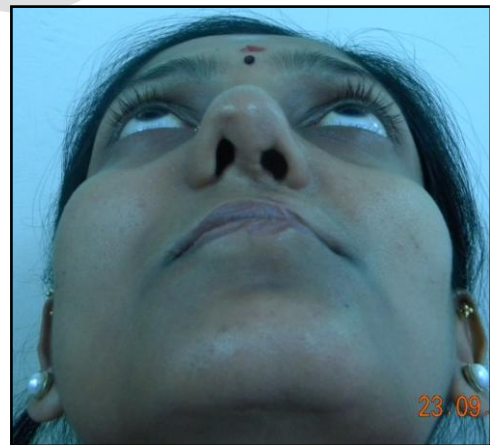**Figure 15: Pre Operative Worm's Eye View**



**Figure 16: Pre Operative View of the Defect**



**Figure 17: Post Operative View of the Defect**



**Figure 18: Post Operative Worm's Eye View**

**Table 1: Pre Operative Values:**

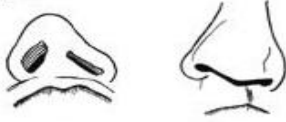			P1	P2	P3	P4	P5	P6	P7	P8	P9	P10
1	NASAL WIDTH in mm		32	40	29	34	33	31	34	33	38	40
2	NASOLABIAL ANGLE		70°	95°	85°	90°	80°	95°	80°	76°	60°	90°
4	ALAR WIDTH in mm	N	10	9	7	7	6	8	7	5	11	9
		C	13	21	11	11	9	12	16	9	14	14
5	ALAR HEIGHT in mm	N	8	9	9	8	9	10	7	8	6	8
		C	5	6	7	5	6	7	4	5	3	5
6	COLUMELLA HEIGHT in mm	N	6	5	7	6	6	5	5	5	5	5
		C	3	2	4	4	4	3	2	2	2	2
7	ANGLE BETWEEN MEDIAL & LATERAL CRULA	N	85°	63°	60°	90°	65°	88°	90°	70°	100°	85°
		C	105°	90°	85°	115°	100°	95°	125°	95°	115°	120°

**Table 2: Post Operative Values:**

			P1	P2	P3	P4	P5	P6	P7	P8	P9	P10
1	NASAL WIDTH in mm		29	37	28	31	30	30	32	30	35	38
2	NASOLABIAL ANGLE		90°	100°	95°	100°	95°	100°	85°	84°	75°	95°
4	ALAR WIDTH in mm	N	9	9	6	7	6	8	7	5	11	9
		C	11	12	8	9	7	9	11	7	12	12
5	ALAR HEIGHT in mm	N	8	9	9	8	9	10	7	8	6	8
		C	7	7	8	7	7	9	5	7	5	6
6	COLUMELLA HEIGHT in mm	N	6	5	7	6	6	5	5	5	5	5
		C	5	4	6	5	5	5	3	3	4	3
7	ANGLE BETWEEN MEDIAL & LATERAL CRULA	N	80°	60°	55°	90°	65°	85°	90°	70°	95°	85°
		C	90°	80°	65°	100°	85°	90°	110°	90°	100°	100°



Unless lip repair is combined with simultaneous repositioning of the alar base and lower lateral cartilage, the nasal deformity will not improve with growth. The majority of patients require secondary correction to rearrange the lower lateral cartilage.<sup>1</sup>



### Hypoplasia of the skeletal base

The most severe deformity occurs in complete unilateral clefts owing to the asymmetry and hypoplasia of the maxillary segments. Hypoplasia of the lesser maxillary segment occurs most commonly along its edges and at the edge of the piriform aperture. The existing hypoplasia may accentuate the nasal deformity owing to the imbalance and asymmetry of the alar base. Asymmetry of these segments and the width of the cleft greatly contribute to the extent and severity of the nasal deformity.

### Asymmetry of the cartilaginous framework.

The lower lateral cartilage may be deformed in several ways. The orientation of the medial to lateral crura is changed because the ala is extended with its base pulled laterally and inferiorly. The medial crus is shorter than that on the noncleft side, whereas the lateral crus is longer than its noncleft counterpart. The domes also differ; the dome on the cleft side is obtuse and lower than the dome on the noncleft side. This cartilage also is deformed in the sense that it is rotated downward in the area of the nasal tip and drawn into an S-shaped fold because the ala is pulled laterally and the cartilage buckles. This distortion of the lower lateral cartilage, when severe, is difficult to correct during the primary operation.<sup>1</sup>

The columella and nasal septum also may be affected by the morphologic changes associated with the unilateral cleft. Since the medial crus of the lower lateral cartilage is shorter on the cleft side, the columella is also shorter. The columella is pulled to the noncleft side by the muscles entering its base and

joined by the orbicularis oris muscle. The septal deformity almost always is present; however the severity of it varies greatly. The caudal edge usually is deviated to the noncleft side, and the entire septum may be deformed in two planes- sagittal and frontal. The base of the septum is dislocated from the groove on the crest of the maxilla. The septal deviation may be so severe that it partially or completely obstructs the nasal passage on the cleft side.<sup>1,2</sup>

There is no question that each of these factors - muscle imbalance, nasomaxillary hypoplasia, and asymmetry of the cartilaginous frame work, results in a nasal deformity of various degrees of severity. However, a combination of these factors, which occurs in almost all patients with complete unilateral clefts, produces the most severe forms of nasal deformities.

For the full correction of the deformities of the nose in the cleft patient, the maxilla, the paranasal region, and the nose may all require correction. These can be either addressed in one sitting, or they can be staged. First, the maxilla is corrected by Le fort I osteotomy. This will improve the position of the upper lip and nasal tip. Next the oronasal fistula is closed and bone grafting performed in the paranasal region thus improving the alar base. Lastly the nose is corrected.<sup>2</sup> In our study, none of the cases selected for secondary rhinoplasty wished to undergo Le fort I osteotomy. 4 cases underwent secondary alveolar bone grafting prior to rhinoplasty, because their paranasal region was severely deficient and the alar bases needed to be supported.

In the evolution of surgical repair of cleft lip nose deformity, numerous methods of repair have been proposed, testifying to the complexity of the problem and the continuing pursuit for improved results.<sup>3</sup> Sorting through the various procedures, it is apparent that they can be reduced to two basic architectural principles. The first involves composite rotation of ala and the second emphasises correction of the cartilaginous framework and soft tissues by alar cartilage transposition, relocation, or suture suspension and by cartilage grafting.<sup>4</sup>

The best approach to proper correction of the cleft lip nasal deformity is through the external approach using transcolumellar incisions. The alar cartilages are too asymmetrical to easily correct through intranasal approach. Accurate suturing under direct vision offers the best hope for repair.<sup>3</sup>

In our study we have placed an incision similar to the incision described by Goodman and Zorn, which they called it the “butterfly incision”, which is a modification of the potter’s incision. A ‘V’ shaped notch was placed in the transcolumellar incision, Instead of placing an inverted v at the middle of the columella as described by Goodman and Zorn. This slight modification allowed us to engage the skin hook in the V shaped tissue, which helped us in retracting the columella superiorly.<sup>3,5,6</sup>

As Potter (1954) we also felt a more complete release was necessary. We freed up all the attachments to the lateral crus except for a medially based chondromucosal flap. The lateral crus was advanced anteriorly and medially and sutured to the normal alar cartilage.<sup>6,7</sup>

Onlay grafts are required to achieve the ideal cosmetic result, despite best attempts at reconfiguring the ala via simple rotation or advancement. Grafts contribute to bulk for improved cosmesis and may serve to reinforce the atrophic weak alar cartilage.

Grafts may be used as spreader grafts and for augmentation of the dorsum, tip, ala, radix and columella. Autologous grafts are preferable over other options, such as homologous grafts and alloplastic materials, because the use of the patient’s own tissue generally results in fewer complications. Bone and cartilage grafts are among the most widely used adjuvants for rhinoplasty. Cartilage grafts can be harvested from the septum, ear, or rib; bone grafts from the cranium, rib, and iliac crest; and fascial grafts from the temporoparietal fascia or cadavers.<sup>6,8</sup> If autologous grafts are not available, other options include alloplastic materials such as medpor, silicone, and siliastic.

Cartilage grafts are classically divided into contouring grafts and structural grafts.

Contouring cartilage grafts are added to the native osteocartilaginous nose in order to obtain an aesthetically pleasing appearance. The dorsum and infratip are the most common sites of contouring graft implantation, which produces a harmonious dorsal unit and optimizes tip projection. The grafts are placed in the coronal plane. They must be secured, for instance using resorbable or nonresorbable sutures or glue. Changes over time at the graft-skin interface may lead to unbecoming graft visibility through the skin.<sup>9</sup>

Reconstructive grafts play a biomechanical role that ensures stability of the cartilaginous framework of the mobile nose. These grafts correct or prevent inspiratory collapse of the middle third of the nose and of the nares. Spreader grafts stabilize the triangular cartilages at the dorsum. Columellar struts stabilize the base of the nose. Alar batten grafts strengthen the lateral crura. Reconstructive grafts are positioned chiefly in the sagittal plane. Their stability over time is highly satisfactory, particularly when they are secured via an open approach. Reconstructive grafts allow morphological and functional reconstruction of the nasal tip in patients undergoing secondary cleft rhinoplasty.<sup>9</sup>

Cartilage grafts are usually harvested from the septum, which has the obvious advantage of being located at the surgical site but its disadvantage being minimal volume and deformation due to cleft. The inferior lateral cartilage may be used, its main advantage being thinness and its main drawback being limited volume. When the amount of available septal cartilage is inadequate, auricular cartilage can be used. It may offer a large area for graft harvesting, which does not usually induce local sequelae. When very large amount of cartilage is needed, for instance to perform augmentation of the dorsum, rib cartilage can be taken from the lower chest, the main disadvantages being a scar, increased operating time, some degree of postoperative pain and donor site morbidity. Rib cartilage is abundant and easy to shape.<sup>9,10</sup>

In this study we have utilised Auricular cartilage as onlay cartilage grafts and columellar struts. It proved to be an excellent source for an

onlay alar graft because it recreated the natural curvature of the ala. Onlay cartilage grafts augmented the weak alar cartilage on the cleft side. It corrected alar buckling, improved contour of flattened ala, corrected obtuse intracural angle and also improved nasal tip projection. The working columella strut gave strength to the medial crura, and has also been used as a splint for the caudal edge of the septum when there are horizontal angulations of the septum. The columella strut is sutured directly to the caudal septum so that the whole complex prevents caudal angulations of the septum and strengthens tip support.<sup>10</sup> In our experience, we obtained satisfactory results by using auricular cartilage as a graft material for augmentation in cases of secondary cleft rhinoplasty.

## Conclusion

The multitude of approaches to secondary unilateral cleft lip nasal repair is a testament to the challenge of secondary cleft lip nasal reconstruction. An individualized approach, with the appropriate surgical technique and an understanding of the fundamental anatomical changes, is imperative to a successful outcome. Ten patients with unilateral cleft lip nasal deformity were included in our study. Open rhinoplasty was performed and auricular cartilage was used to augment the alar cartilage on the cleft side and also as a columellar strut.

We found auricular cartilage to be very beneficial. As it is a part of the patients own body, rejection never occurs. It shows greater resistance to infection than any alloplastic material. The harvested cartilage conformed to the shape of the ala and it was easy to carve to the required size and shape; hence it was able to cope with individual variations. The success rate of auricular cartilage graft was 100% in our study and same results were seen in a study conducted by Murrell and George.<sup>11</sup>

The open rhinoplasty approach offered better visualisation of the defect and easier manipulation of the cartilages. The advantages outweighed the cost of minimal scar over the columella. The success of cleft rhinoplasty was evaluated by comparing the

symmetry, Nasolabial angle and the intracural angle of the nares on the non cleft and cleft sides pre and post operatively. There was no donor site or recipient site morbidity in any of our cases and satisfactory results were obtained.

## References:

1. Janusz Bardach and Court Cutting: Nasal Deformity Associated with Unilateral Clefts. Excerpt from Multidisciplinary Management of Cleft Lip and Palate. 2001
2. Matukas, P.J.Louis: Secondary management of the nose in the cleft patient. International journal of oral and maxillofacial surgery 22:195 – 199, 1993
3. Cronin D.Thomas and Denkler A.K: Correction of unilateral cleft lip nose. Plastic Reconstructive Surgery 82. (3) 419, 1988.
4. Blackwell J.S. et al: Onlay cartilage graft of the alar lateral crus for the cleft lip nasal deformities. Plastic Reconstructive Surgery 76: 395, 1985.
5. Matsuya T et al: Secondary rhinoplasty using flying bird and vestibular tornado incisions for unilateral cleft lip patients. Plastic Reconstructive Surgery. 112. (2): 390, 2003.
6. Pollet J: Three autogenous a struts for nasal tip support. Plastic Reconstructive Surgery. 49(5) 527-532, 1972.
7. Tajjma S and Maruyama M: Reverse “U” incision for secondary repair of cleft lip nose. Plastic Reconstructive Surgery.60: 256-61, 1977.
8. Cusons.P.D et al: A panel based assessment of early versus no nasal correction of the cleft lip nose. British journal of plastic surgery.46: 7:12, 1993.
9. François: Clinical practice recommendations “Cosmetic and Functional rhinoplasty”. French society for otorhinolaryngology and head-and-neck surgery & French Society for Oral and Maxillofacial Surgery. 91 : 240, 2007.

10. Richard T. Farrior, Edward H. Farrior :Special Rhinoplasty Techniques: Chapter 48.
11. Murrell GL: Auricular cartilage grafts and nasal surgery. Laryngoscope. 2004 Dec; 114(12):2092-102.

**Corresponding Author**

**Dr. Vinay K N,**  
Oral and maxillofacial surgeon,  
Dar Al-Qudrah Medical Group, Riyadh  
**Email id:** *vinayomfs@gmail.com*