Original Article

Anomalous Branching Pattern of the External Carotid Artery in Cadavers

Vishnu Gupta[1], Rakesh Agarwal[2]

[1]*Associate Professor & MD in the Department of Anatomy MMC, Muzaffarnagar UP, India,*
[2]*Post-Graduate Student in the Department of Anatomy MMC, Muzaffarnagar UP, India*

Corresponding Author: *Dr. Vishnu Gupta, Professor Department of Anatomy MMC, Muzaffarnagar UP, India. Phone: 9412617346. E-mail: Vishnu.gupta007@yahoo.com*

Abstract

Background: With increasing use of invasive diagnostic and interventional procedures in cardio-vascular disease, it is important to find out type and frequencies of vascular variations. Variations in the course, branching and distribution of carotid arteries are commonly encountered.

Material & Method: In the present study we have observed variations of the branching pattern of external carotid artery. We examined the 30 cadavers during routine dissection.

Result: One cadaver had common trunk of lingual, facial and superior thyroid artery on one side (i.e thyrolinguofacial trunk) and in four cadavers there were unilateral common trunk of lingual and facial artery i.e linguofacial trunk.

Conclusion: Anatomical knowledge of the origin, course and branching pattern of external carotid artery will be useful during head & neck surgeries. The present study thus provides useful information for clinical application. The clinical importance of this variation is discussed.

Keywords: External carotid artery, Lingualfacial trunk, Thyrolingualfacial trunk

INTRODUCTION

External carotid artery is the chief artery of Head & Neck region in humans. It arises from the common carotid artery, lateral to the upper border of the thyroid cartilage, level with intervertebral disc between the third and forth cervical vertebrae. From its origin it take a slightly curved course, passes upward and forward, and then inclines backward to the space behind the neck of the mandible, where it divides in to the superficial temporal artery and maxillary artery within the parotid gland. It is decreases in size in its course up to the neck, owing to the number and large size of the branches extending from it. It has eight named branches distributed to the head & neck.[1] The facial artery normally arises from external carotid artery, just above the lingual artery, at the level of greater cornu of hyoid bone in the carotid triangle. The reported variation of facial artery includes its intraparotid origin,[2] origin as a common trunk with lingual artery as linguofacial trunk.[3,4] Another variation in branches of external carotid artery are as follows – the lingual artery form a common trunk with the facial (lingofacial trunk) in 10-20 % cases, a rare combination branch of the external carotid artery is a thyrolinguofacial trunk,[5] also reported about the presence of linguofacial trunk, thyrolingual trunk, thyrolingualfacial trunk in human fetus.[6] In the surgical literature, Catell, Phillips and Gorskie[7] had discussed the danger of injury atypically originating large cervical arteries during operation on thyroid gland.

These variations can pose a dangerous situation during surgeries like thyroidectomy, laryngectomy and other neck surgeries, preoperative selective arterial angiograms, in management of head neck tumors. So it is important for surgeons, radiologist to be aware of the variations among these arteries. Surgeons should be able to differentiate between the facial and lingual artery to insure accurate arterial ligation during oral and maxillofacial surgery and radical neck dissection. This knowledge can also help radiologist to understand and interpreted carotid system imaging.[8] The present study was undertaken to know the anatomy of the variation in the branching pattern of external carotid artery as-common liguofacial trunk and rare variation thyro-linguofacial trunk.

MATERIAL AND METHOD

Thirty properly embalmed (sixty sides), formalin preserved cadavers were selected for the study. The present study was carried out during 2006 to 2013 in the department of Anatomy, Muzaffarnagar Medical College, Muzaffarnagar (U.P). This dissection of head and neck carried out according to the instruction by Cunningham's manual of practical anatomy (Vol.3, 15th editions, 130-135). The dissection took place during the year 2006 to 2013. The meticulous dissection of external carotid artery was carried out in the carotid triangle and infratemporal fossa, clearly delineating its origin and all the branches.

RESULT AND OBSERVATIONS

During routine dissection for undergraduate students in the Department of Anatomy, MMC, Muzaffarnagar an unusual branching pattern of external carotid artery was observed in cadavers. Variations in the origin facial, lingual and superior thyroid artery from the external carotid artery on both sides was observed in cadavers. In present study we recorded one of thyrolingual facial trunk (common origin of superior thyroid, lingual artery and facial artery arises from anterior surface of external carotid artery on left side i.e. 3.3%) (Figure 1). The lingual and facial artery were originating (in two cadaver right side and in two cadaver left side i.e. 11.3%) as the common lingual facial trunk from the anterior side of external carotid artery, above the carotid bifurcation (Figures 2 and 3). The facial lingual artery trunk was running medially and upwards, which was crossed by hypoglossal nerve.

DISCUSSION

The location of carotid bifurcation, the branching pattern of external carotid artery and variations of the branch origins are known quite well. The branches of external carotid artery may arise irregularly or alter in number. When increase in number (by two or more), they arises as common stem, or by addition of branches not usually derived from this artery, such as sternomastoid branch of superior thyroid or occipital artery.[5]

There are reports in literature of origin of lingual artery from common carotid artery, lingual facial trunk or thyrolingualfacial trunk from external carotid artery. In present study one such case of thyrolingualfacial trunk was found which originated from anterior surface of external carotid artery (Figure 1) unusual case of origin of superior thyroid, lingual was also described by Arthur Thomson in his notes an Unusual variation[9] Budhiraja and Rastogi reported variable origin of thyrolingual trunk from right and left common carotid artery respectively[10] Ozur et. al.[6] classified the origin of these arteries which were arises from the external carotid artery in four types and reported their incidences. The separate origins of the arteries were defined type 1 (in 90% of the cases), the lingual facial trunk as type 2 (7.5%), thyrolingual trunk as a type 3 (2.5%) and thyrolingualfacial trunk as type 4.[11] Livini[12] observed the origin of superior thyroid artery in common with facial and lingual artery in 1.5 % of cadavers. The Thyrolingual trunk was found in 3.5% of cases by Shintani,[13] in 2% of cases by Gaillard[14] and Md Banna.[15] In present study we recorded one case of the common thyrolingofacial trunk i.e. 3.3% of cases arises from anterior surface of external carotid

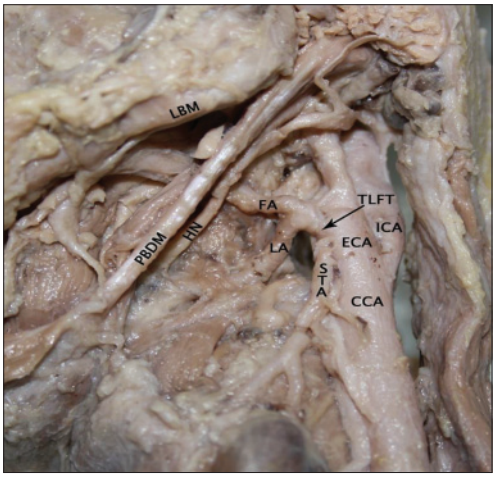

Figure 1: Variant left thyro-linguofacial trunk arising from external carotid artery (TLFT:Thyro linguo facial trunk, CCA: Common carotid artery, ICA: Internal carotid artery, ECA: External carotid artery, STA: Superior thyroid artery, LFT: Linguo facial trunk, LA: Lingual artery, FA: Facial artery, HN: Hypoglossal nerve, PBDM: Posterior Belly of diagastic muscle)

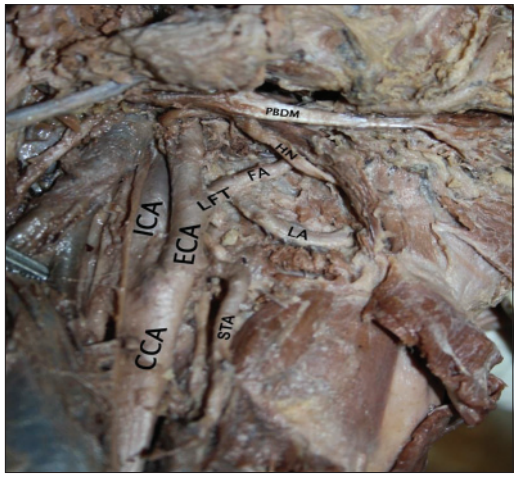

Figure 2: Variant Right linguofacial trunk arising from external carotid artery (CCA: Common carotid artery, ICA: Internal carotid artery, ECA: External carotid artery, STA: Superior thyroid artery, LFT: Linguo facial trunk, LA: Lingual artery, FA: Facial artery, HN: Hypoglossal nerve, PBDM: Posterior Belly of diagastic muscle)

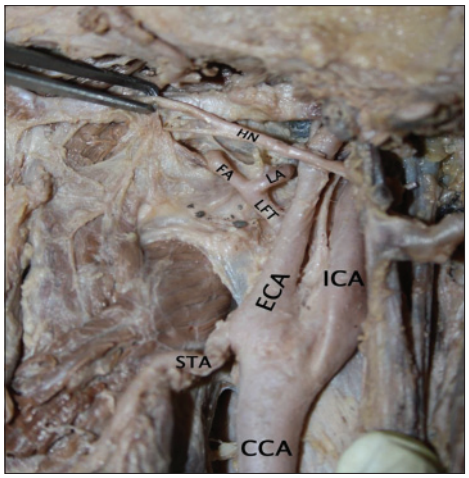

Figure 3: Variant Left linguofacial trunk arising from external carotid artery (CCA: Common carotid artery, ICA: Internal carotid artery, ECA: External carotid artery, STA: Superior thyroid artery, LFT: Linguo facial trunk, LA: Lingual artery, FA: Facial artery, HN: HypoglossaL nerve)

artery on left side. Zumre et al in their study on human fetuses found lingualfacial trunk in 20%, a thyrolingual turnk in 2.5 % and thyrolingualfacial trunk in 2.5% of human fetuses studied.

According to Anil A (2000)[16] the lingual artery arises from a common trunk with the facial as a linguofacial trunk in 10 to 20% of cases. Yildrim et al (2001)[17] also observed the total 6 (15%) linguofacial trunk in 40 neck side (20 adult human cadavers). Lappas et al (2002)[18] also found out linguofacial trunk in 14% cases and in a study conducted by Sanjeev et al,[19] the linguofacial trunk present in 18.92% cases. In present study it was 13.3%. Knowledge of variations of the external carotid artery and its branches and their recognition during diagnostic imaging are also important for vascular surgical procedure in the region, such as carotid endoplasty for the treatment of carotid stenosis[20-22] extra cranial – intracranial arterial bypass for treatment of patients with occlusive cerebrovascular disease, skull base tumors or aneurysms.[23] In our study, we found in four cadavers linguofacial trunk (11.3%) and in one cadaver thyrolinguofacial trunk(3.3%).

This present study to show differences in the branching pattern as compare to the available literature so far, which may be due to racial differences. This implies that these vessels show great variability (as given in Tables 1 & 2).

CONCLUSION

The branches of the external carotid artery are the key land marks for adequate exposure and appropriate placement of cross –clamp on the carotid arteries. The branches of the carotid arteries located in the carotid triangle are also the key land marks for adequate dissection on the carotid arteries and should be identified before cross clamps are placed and an arteriotomy is performed. So awareness of details and topographic anatomy of variations of the external carotid artery may be useful for both radiologists and vascular surgeons to prevent diagnostic error.

Table 1: Comparison of the prevalence of linguofacial trunk in different studies

Name of author	Year	Linguofacial trunk (%)
Ozgur et al.	2008	7.5
Lappas	2002	14
Yildirin et al.	2001	15
Sanjeev et al.	2010	18.92
Lucev	2000	20
Zumre et al.	2005	20 (In faetus)
Shintami	1999	31
Present study	2013	11.3

Table 2: Comparison of the prevalence of thyrolinguofacial trunk in different studies

Name of author	Year	Linguofacial trunk (%)
Jitender Patel	2011	1
Livini	1900	1.5
Takkallapalli Anitha et al.	2011	2
Zumre et al.	2005	2.5 (In faetus)
Present Study	2013	3

REFERENCES

1. Standring S. Gray's Anatomy. The Anatomical basis of clinical practice. 39th Ed. Edinburg. Elsevier Churchill Livingstone. 2005; 31:p.543-544.
2. Nayak S. Abnormal intra-parotid origin of the facial artery, Saudi Med J, Blanchard & Lea, Philadelphia, 1862;374-76.
3. Gray H, Anatomy, descriptive and surgical, second edition, Blanchard & Lea, Philadelphia, 1862;374-76.
4. Midy D., Maures B., Vergnes P., Caliot P.A. Contribution to the study of the facial artery, its branches and anastomoses; application to the anatomic vascular bases of facial flaps. *Surg Radiol Anat*. 1986;8(2):99-107.
5. Bergman RA, Thompson SA, Afifi AK, Saadeh FA, Compendium of human anatomic variations, urban and Schwarzenberg, Baltimore, 1988, 65.
6. Zumre O, Salbacak A, Cicekcibasi AE, Tuncer I, Seker M. Investigation of the bifurcation level of the common carotid artery and variations of the branches of the external carotid artery in human fetuses. *Ann Anat*. 2005; 187:361-369.
7. Cattell RB, philips ES- Anomalous superior thyroid artery; a finding during resection of carotid body tumor. *Post Grand Med*. 1949;5:137.
8. Thwin S S, Soe MM, Myint M, Than M, Lwin S. Variations of the origin and branches of the external carotid artery in a human cadaver. *Singapore Med Case Report J* 2010;51(2):e40.
9. Thomson A. Notes on some unusual variations in human anatomy. *Anat physiol*. 1885; 19: 328-332.
10. Budhiraja V, Rastogi R. Variant origin of thyrolingual trunk from left common carotid artery. *International journal of Anatomical Variations*. 2010; 3: 44-45.
11. Ozgur Z, Govsa F, Ozgrs T. Assessment of origin of characteristics of the front branches of ECA. *J Cranio Fac Surg*. 2008, 19, 1159-1166.
12. Livini studio morfologicadelle arteria tiroidee sperm. *Arg Biel Norma Patol*. 1900;34(42):129.
13. Shintani S, Terakado N, Alcalde RE, Tamizawa K, Narayas Ueyema Y et al. An anatomical study of the arteries for intra arterial chemotherapy of Head and Neck cancer. *International Journal of Clinical Oncology*. 1999; 4:327-330.

14. Gailloud P, Khan HG, Nathalie K, Rufenacht DA, Fasel JND. The supra isthmic anastomotic arch. *AJR. 1998*;170:497-198.
15. Banna M, Lasjaunias P. The arteries of the lingual thyroid; angiographic findings and anatomic variations. *Am J Neu- roradiol*. 1990;11:730-732.
16. Anil A, Turgut Hb, Peker T, Pelin C, Variations of the branches of the external carotid artery. *Gazi Med J*. 2000;11(2): 81-83.
17. Yildrin, M, Tanyeli, E, Solyluoglu, A. I: & Tuna, Y. Truncus linguofacialis siklig. *Morfoloji Der*. 2001;9(1):33-4.
18. Lappas DA, Kamberos SP, Gisakis JG, Takis CH, Lykaki G. Anatomic study of the variations in the origin of the branches of the external carotid artery. *Beta Medical Arts* 2002:81.
19. Sanjeev IK, Anita H, Aswini M, Mahesh U, Rairam GB, Branching pattern of external carotid artery in humans. *Journal of Clinical and Diagnostic Research*. 2010; 4: 3128-3133.
20. Hayashi N, Hori E, Ohtani Y, Ohtani O, Kuwayama N, Endo S. Surgical anatomy of the cervical carotid artery for carotid endarterectomy. *Neurol Med Chir*. 2005;45: 25-30.
21. Brown MM, Butler P, Gibbs J, Swash M, Waterston J, Feasibility of percutaneous transluminal angioplasty for carotid artery stenosis. *J Neurol Neurosurg Psychiat* 1990; 53: 238-243.
22. Dillon EH, van Leeuwen MS, Fernandez MA, Eikelboom BC, Mail WPTM. CT Angiography application to the evaluation of carotid artery stenosis. *Radiology* 1993;189: 221-219.
23. Gratzl O, Schmiedek P, Spetzler R, Steinhoff H, Marguth F. Clinical experience with extra-intracranial arterial anastomosis in 65 cases. *J Neurosurg* 1976; 44: 313-324.

How to cite this article: Vishnu Gupta, Rakesh Agarwal. "Anomalous Branching Pattern of the External Carotid Artery in Cadavers". Int J Sci Stud. 2014;2(1):28-31.

Source of Support: Nil, **Conflict of Interest:** None declared.