A Rare Presentation of Ileal Perforation Secondary to Adenocarcinoma of Lung

Korumilli Ramesh Kumar[1], G Gautham Reddy[2]

[1]*Professsor of General Surgery, SVS Medical College, Mahabubnagar, Andhra Pradesh, India,*
[2]*Assistant Professor of General Surgery, SVS Medical College, Mahabubnagar, Andhra Pradesh, India*

Corresponding Author: *Dr. Korumilli Ramesh Kumar, Plot no. 70, Gruhalaxmi Colony, Old Kakaguda, Secunderabad, Andhra Pradesh, India - 500015, Phone: 09885044904.*
E-mail: rameshkorumilli@gmail.com

Abstract

Ileal perforation due to typhoid or tuberculosis is a well known entity. Ileal perforation secondary to metastasis from a primary is rare. We report a case of perforation in proximal ileum which was later diagnosed as metastatic deposit from a primary in the lung. A 35 yrs old male presented to the casualty with clinical picture of peritonitis, later confirmed as ileal perforation secondary to adenocarcinoma of the lung.

Keywords: Ileal perforation, Lung carcinoma, Metastasis from primary, Peritonitis

INTRODUCTION

Metastatic tumors involving the small bowel are much more common than primary neoplasms. The most common metastasis to the small intestine are those arising from intra-abdominal organs[1] Metastases from extra-abdominal tumors are rare but may be found in patients with adenocarcinoma of breast and carcinoma of the lung.[2] We report an interesting case of carcinoma of the lung with metastasis to the small intestine leading to perforation and present a review of the literature.

CASE REPORT

A 35 years old male patient presented to the casualty with complaints of sudden onset of acute abdominal pain and fever of one day duration. He has a history of smoking of 15 years duration.

On examination, abdomen was distended. There was generalised tenderness all over the abdomen, with local rise of temperature and guarding and rigidity. Obliteration of liver dullness was present. Bowel sounds were absent. X-Ray erect abdomen showed free air under right dome of diaphragm. X-Ray of chest reported as normal study except an evidence of old fracture of third rib on the left side. A provisional diagnosis of hollow viscus perforation was made and exploratory laparotomy was done.

Operative findings were 200 ml of purulent fluid and 0.5 × 0.5 cm perforation on the mesenteric side of proximal ileum approximately 100 cm from ileo-caecal junction. Thickening of ileal wall along with mesentery on either side of perforation was noted (Figure 1). Multiple enlarged lymph nodes were found in the mesentery. Liver and peritoneum were normal. Based on the intraoperative findings a differential diagnosis of carcinoma of small bowel, carcinoid tumor or ruptured gastro-intestinal stromal tumor (GIST) was made. Resection of ileum with 5 cm margin on either side of the perforation, with end to end anastomosis was done. The peritoneal cavity was irrigated with normal saline. The abdomen was closed after placing a pelvic drain.

The histopathological report showed moderately differentiated adenocarcinoma with multiple lymphatic emboli with involvement of serosa and also perforation (Figure 2). Post operative period was uneventful.

Patient was referred to medical oncologist for further management. He came back after 10 days with chest pain. ECG showed normal study. X-ray chest showed a suspicious opacity. CT scan of chest was done which showed lung malignancy – stage III B (Figure 3). A CT guided FNAC was done which showed evidence of adenocarcinoma of the lung. To further characterize the nature of the tumor, we carried out immunostaining of TTF-1 on the resected

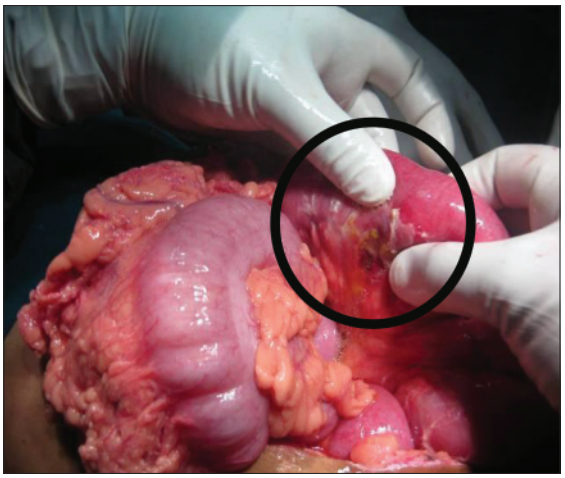

Figure 1: Perforation of ileum along with enlarged lymph nodes in the mesentery

Figure 2: Multiple secondaries in the small bowel

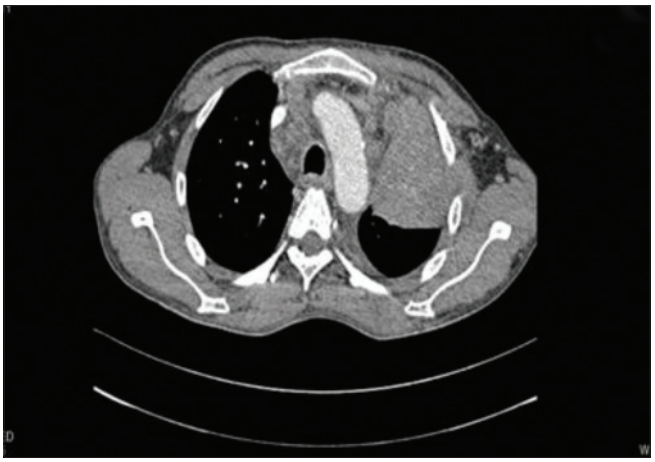

Figure 3: CT Thorax showing lung malignancy in anterior segment of left upper lobe

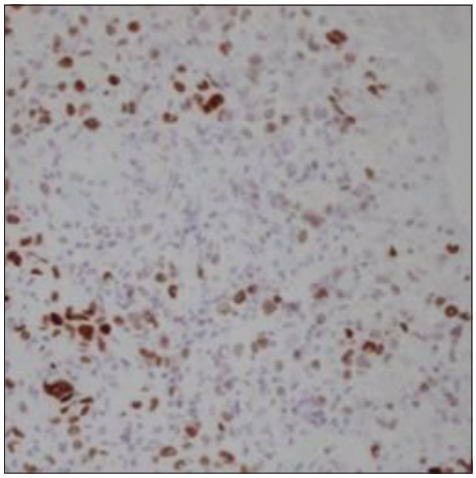

Figure 4: Tumor cells positive for thyroid transcription factor-1

specimen and it was positive (Figure 4). TTF-1 positivity is highly restricted to primary lung carcinoma and thyroid tumor. Since CT revealed lung tumor, we finally diagnosed this tumor as small bowel metastasis from primary lung adenocarcinoma.

DISCUSSION

Primary lung cancer often metastasizes to the brain, liver, adrenal glands and bone.[3] But metastasis to the digestive tract is rare.[4]

Small bowel metastasis from primary lung cancer exhibits symptoms such as abdominal pain and obstruction which are most common and others such as vomiting, melena, weight loss, gastrointestinal perforation, but most cases are asymptomatic.[5]

In normal tissue, TTF-1 is expressed in epithelial cells of thyroid and type II pneumocytes and Clara cells in lung. Carcinomas arising in lung and thyroid show TTF-1 expression frequently.[6] Thus, TTF-1 is a very good marker to determine the lung origin in small bowel metastasis.[7,8]

In one review of literature by Paul McNeil et al. from Virginia University in 1987, autopsy of 431 deaths due to lung cancer was done. 46 cases had deposits in small bowel and they often had lead to perforation.

In another review from world journal of gastroenterology 2005 by Davor Thomas et al. secondaries of small intestine are common than primaries. Small intestine carcinomas, especially when multiple, metastasis from lung should be first excluded, because it seems that they are more common than expected.

CONCLUSION

Small bowel metastasis from primary lung adenocarcinoma is rare and therefore difficult to diagnose. In such cases,

TTF-1 can be a very useful immunohistochemical marker to determine the lung origin.

REFERENCES

1. Courtney M. Townsend Jr., Mark Evers, R.Deniel Beauchamp, Kenneth L. Mattox. Sabiston textbook of surgery 18th edition, vol. 2, chapter 48, page 1318.
2. Wootton DG, Morgan SC, Hughes RK. Perforation of a metastatic bronchogenic carcinoma to the jejunum. *Ann Thorac Surg* 1967; 3:57-59.
3. Hillers TK, Sauve MD, Guyatt GH. Analysis of published studies on the detection of extrathoracic metastases in patients presumed to have operable non-small cell lung cancer. *Thorax.* 1994;49 (1):14-19.
4. Yoshimoto A, Kasahara K, Kawashima A. Gastrointestinal metastases from primary lung cancer. *Eur J Cancer* 2006;42:3157-3160.
5. Ryo H, Sakai H, Ikeda T, Hibino S, Goto I, Yoneda S, Noguchi Y. Gastrointestinal metastasis from lung cancer. *Nihon Kyobu Shikkan Gakkai Zasshi.* 1996;34 (9):968-972.
6. Comperat E, Zhang F, Perrotin C et al. Variable sensitivity and specificity of TTF-1 antibodies in lung metastatic adenocarcinoma of colorectal origin. Modern Pathology. 2005;18,1371-1376.
7. Reis-Filho JS, Carrilho C, Valenti C, Leitão D, Ribeiro CA, Ribeiro SG, Schmitt FC. Is TTF1 a good immunohistochemical marker to distinguish primary from metastatic lung adenocarcinomas? *Pathol Res Pract*. 2000;196:835-840.
8. Moldvay J, Jackel M, Bogos K, Soltész I, Agócs L, Kovács G, Schaff Z. The role of TTF-1 in differentiating primary and metastatic lung adenocarcinomas. *Pathol Oncol Res*. 2004;10:85-88.

How to cite this article: Korumilli Ramesh Kumar, G Gautham Reddy. "A Rare Presentation of Ileal Perforation Secondary to Adenocarcinoma of Lung". Int J Sci Stud. 2014;2(1):43-45.

Source of Support: Nil, **Conflict of Interest:** None declared.