Tolosa Hunt Syndrome: Reported From West Bengal, India

Ayan Basu[1], Arpan Mandal[2]

[1]MD, RMO cum Clinical Tutor, Department of Tropical Medicine, School of Tropical Medicine, Kolkata, [2]MD, Assistant Professor, Department of General Medicine, Bankura Sammilani Medical College, Bankura

Corresponding Author: Dr. Ayan Basu, 46/27A, Becharam Chatterjee Road, Behala, Kolkata - 700034, West Bengal, India, Mobile: +919830371557. E-mail: ayanbasustm@gmail.com

Abstract

Tolosa Hunt Syndrome (THS) is a rare cause of painful ophthalmoplegia. It is caused by nonspecific inflammation of the cavernous sinus or superior orbital fissure. Our article describes a case of a middle aged female who presented with retro orbital pain, diplopia and third, fourth and sixth cranial nerve palsy. She had no other neurodeficit. Her CT & MRI scan was normal. We treated her with systemic steroids because of the suspicion of THS and the patient recovered dramatically. This is probably the first reported case of Tolosa Hunt Syndrome with normal neuroimaging from West Bengal, India.

Keywords: Normal MRI, Painful ophthalmoplegia, Tolosa hunt syndrome

INTRODUCTION

Recurrent painful ophthalmoplegia is a rare condition first described by Tolosa in 1954 in a male patient who had died soon after an operation to explore the sella turcica for left retro-orbital pain and ophthalmoplegia. The autopsy demonstrated nonspecific granulomatous inflammation in the cavernous sinus, surrounding the intracavernous portion of the left internal carotid artery and cranial nerves III, IV, ophthalmic division of V, and VI.[1] In 1961 Hunt et al. reported six cases with similar clinical findings and called this syndrome painful ophthalmoplegia. The authors proposed the clinical criteria for the diagnosis of this condition.[2] In 1966, Smith and Taxdal were the first to apply the eponym "Tolosa-Hunt syndrome" to this entity and they emphasized the dramatic response of the symptoms to systemic steroid therapy.[3] Although newer imaging modalities like CECT and MRI (also MR angiography and venography) with special attention to cavernous sinus, superior orbital fissure and orbital apex can detect several abnormalities in patients with THS but few studies revealed normal imaging finding.[4] In this article we described a patient with clinical features of Tolosa Hunt Syndrome with normal imaging.

CASE REPORT

A 34 years old female patient presented with painful ophthalmoplegia in right eye and diplopia for last 5 days. She had no other complaints or any systemic symptoms. She had a past history of painful diplopia 7 months ago. Those symptoms resolved spontaneously after few weeks without any medication. That time Ophthalmoscopic examination and CT scan was normal.

On examination, she had right sided 3rd, 4th and 6th cranial nerve palsy (Figure 1). Right sided pupil slightly larger in size than the left one. Ophthalmoscopic examination revealed no abnormality. There was no other neurological impairment. She was normotensive. Other systemic examinations were normal.

Laboratory investigations revealed normal CBC, euglycemia, euthyroid. Serum ANA and ACE were negative, ICTC was also nonreactive. CSF study was normal.

Both plain and Contrast Enhanced CT scan were normal. MRI with MR Angiography was also normal (Figures 2 & 3). During MRI study special attention was given to cavernous sinus, superior orbital fissure and orbital apex.

Based on the clinical findings a diagnosis of Tolosa Hunt Syndrome was made and Methylprednisolone at a dose of 32 mg OD for 7 days and then gradual tapering was done. There was dramatic improvement of pain within 3 days. Ptosis and diplopia almost corrected after 2 weeks of therapy (Figure 4).

DISCUSSION

Tolosa Hunt Syndrome (THS) is a rare painful ophthalmoplegia caused by nonspecific inflammation of the cavernous sinus or superior orbital fissure and is responsive to steroid therapy. THS can affect people of age group of 1st to the 8th decades of life, with no sex or side predilection. Uniformly, patients complain of pain, which is a defining symptom. The pain lasts an average of 8 weeks if untreated. Ocular motor cranial nerve palsies may coincide with the onset of pain or follow it within a period of up to 2 weeks.[5] All three ocular motor cranial nerves may be involved, in various combinations. Pupillary reactions may be normal. Since Tolosa[1] described a case of periarteritis of the cavernous carotid artery creating a painful ophthalmoplegia in 1954 there has been considerable interest in THS. In 1961, Hunt et al.[2] outlined six clinical criteria characterizing the syndrome: 1) steady, gnawing or boring retro orbital pain; 2) defects in the IIIrd, IVth, VIth, or 1st branch of the Vth cranial nerve, with less common involvement of the optic nerve or sympathetic fibres around the cavernous carotid artery; 3) symptoms lasting days to weeks; 4) occasional spontaneous remission; 5) recurrent attacks and 6) prompt response to steroid therapy.

Initial radiographic evaluation consisted of carotid artery and superior ophthalmic vein angiography, which often demonstrated narrowing of the carotid siphon or thrombosis of the superior ophthalmic vein and/or cavernous sinus. However, a normal orbital venogram or arteriogram does not exclude THS, and one series found

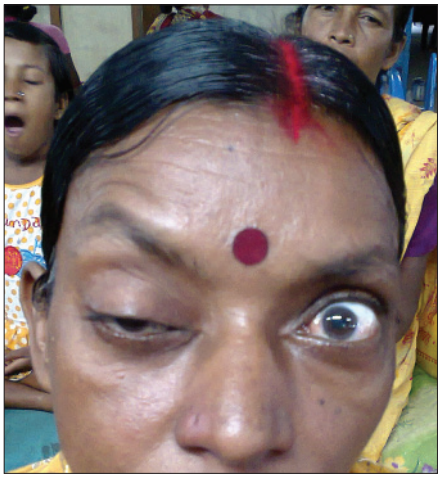

Figure 1: Patient-before treatment

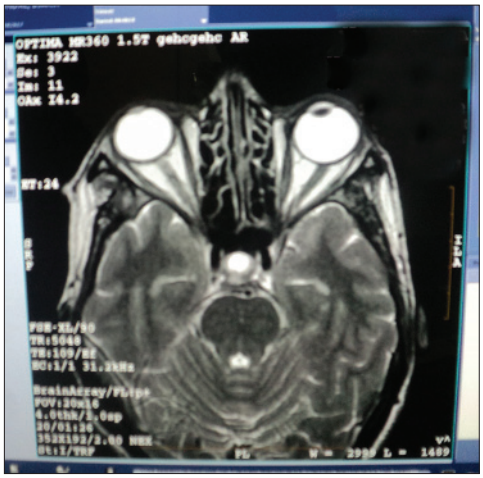

Figure 2: MRI-Coronal & axial view, showing normal cavernous sinus, superior orbital fissure and orbital apex of the patient

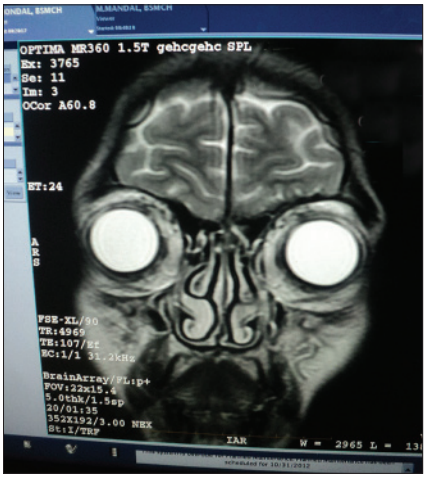

Figure 3: MRI-Coronal & axial view, showing normal cavernous sinus, superior orbital fissure and orbital apex of the patient

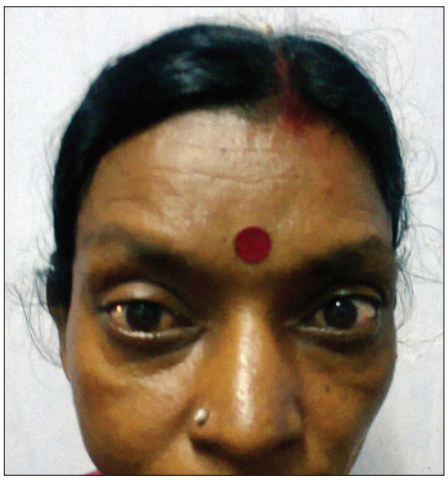

Figure 4: Patient-after treatment

no vascular abnormality in 16 of 26 cases.[6] High resolution CT can also demonstrate soft tissue changes in the region of the cavernous sinus/superior orbital fissure, but is less sensitive than MRI. Contrast enhanced MRI with multiple views; particularly coronal sections demonstrated an area of abnormal soft tissue in the region of the cavernous sinus in most, but not all, patients with THS. Typically, the abnormality is seen as intermediate signal intensity on T1 and intermediate weighted images, consistent with an inflammatory process. There is enhancement of the abnormal area after intravenous injection of paramagnetic contrast. With corticosteroid therapy, the abnormal area decreases in volume and signal intensity in most reported cases.[7]

Yousem et al[4] examined 11 patients and reported pathological MRI findings (abnormal signal and/or mass lesions) in the cavernous sinus in nine. Two patients had normal MR studies of the orbit and cavernous sinuses just like our case. In eight cases the abnormality was hypointense relative to fat and isointense with muscle on T1 weighted images; isointense with fat on T2 weighted scans.

The clinical differential diagnosis[8,9] of steroid responsive painful ophthalmoplegia includes metastases, carotid-cavernous fistulae, pituitary adenomas, vasculopathic cranial neuropathy, aspergillus invasion, Wegener's granulomatosis, sarcoidosis, lymphoma and ophthalmoplegic migraine. Meningiomas and aneurysms may rarely cause pain when of sufficient size. While metastases, pituitary adenoma, aspergillus infection, some meningiomas and some cases of lymphoma are often hyper intense relative to fat on long TR images; Sarcoidosis, lymphoma and meningiomas may display hypointensity or isointensity on short TR/TE and long TR/TE sequences as in THS. However, sarcoidosis & lymphoma will often have systemic symptoms and meningiomas will not resolve with steroid therapy. Vascular abnormalities such as arteritides, carotid-cavernous fistulae, ophthalmoplegic migraines and aneurysms are not associated with masses in the cavernous sinus or orbital apex as in THS.

CONCLUSION

In the appropriate clinical setting of painful ophthalmoplegia, MR findings of a cavernous sinus abnormality and a prompt response to steroid therapy, THS need not merely be a diagnosis of exclusion, although other lesions may have similar intensity characteristics, a small percentage of patients with THS may have lesions not detectable with current imaging techniques.

ACKNOWLEDGEMENT

Department of General Medicine, Bankura Sammilani Medical College, Bankura, West Bengal, India.

REFERENCES

1. Tolosa E. Periarteritic lesions of the carotid siphon with the clinical features of a carotid infraclinoid aneurysm. *J Neurol Neurosurg Psychiatry.* 1954;17:300-2.
2. Hunt WE, Meagher JN, Le Fever HE *et al*. Painful ophthalmoplegia. Its relation to indolent inflammation of the cavernous sinus. *Neurology.* 1961;11:56-62.
3. Smith JL, Taxdal DSR. Painful ophthalmoplegia. The Tolosa-Hunt syndrome. *Am J Ophthalmol.* 1966;61:1466-72.
4. Yousem DM, Atlas SW, Grossman RI, *et al*. MR imaging of Tolosa-Hunt syndrome. *AJNR Am J Neuroradiol.* 1990;10:1181-4.
5. Förderreuther S, Straube A. The criteria of the International Headache Society for Tolosa-Hunt syndrome need to be revised. *Neurol.* 1999;246:371-7.
6. Muhletaler CA, Gerlock AJ. Orbital venography in painful ophthalmoplegia (Tolosa-Hunt syndrome). *Am J Radiol.* 1979;133:31-4.
7. Kline LB, Hoyt WF. The Tolosa-Hunt syndrome. *J Neurol Neurosurg Psychiatry.* 2001;71:577-82.
8. Khera PS, Singh S, Chowdhury V, Dixit R. Tolosa-Hunt syndrome: A Case Report *Ind J Radil Imag.* 2006;16 (2):175-7.
9. Goadsby PJ, Lance JW. Clinicopathological correlation in a case of painful ophthalmoplegia: Tolosa-Hunt syndrome. *J Neurol Neurosurg Psychiatry.* 1989;52:1290-3.

How to cite this article: Ayan Basu, Arpan Mandal. "Tolosa Hunt Syndrome: Reported from West Bengal, India". Int J Sci Stud. 2014;2(1):51-53.

Source of Support: Nil, **Conflict of Interest:** None declared.