Original Article

DOI: 10.17354/ijss/2016/181

Correlation between Deviated Nasal Septum and Sinusitis: A Clinical and Histopathological Study

Mani Arora[1], Sadakat Ali[2], A K Choudhary[3], K Suchit[3], Chetan Bansal[4]

[1]Associate Professor, Department of Anatomy, Sheikh-Ul-Hind Mahmood Mahmood Hasan Medical College, Saharanpur, Uttar Pradesh, India, [2]Associate Professor, Department of Anatomy, Shri Guru Ram Rai Institute of Medical & Health Sciences, Dehradun, Uttarakhand, India, [3]Assistant Professor, Department of Anatomy, Shri Guru Ram Rai Institute of Medical & Health Sciences, Dehradun, Uttarakhand, India, [4]Assistant Professor, Department of ENT, Shri Guru Ram Rai Institute of Medical & Health Sciences, Dehradun, Uttarakhand, India

Abstract

Introduction: Deviated nasal septum is a frequently occurring condition which alters the normal air flow pattern making it turbulent, producing a nasal obstruction in an individual. It may result in permanent changes in the nasal and sinus mucosa. This study makes an attempt to evaluate the deviated nasal septum and associated sinus pathology.

Materials and Methods: Study was done in 30 patients of rhino-sinusitis, divided into 2 groups - control and study group of 15 each. Patients were then assessed clinically by using various parameters such as Patency test, Rhinoscopy, Nasal diagnostic endoscopy, X-ray peripheral nervous system, and computed tomography scan. Histopathological examination of mucosal biopsies from maxillary sinus of patients was also done.

Results: Incidences of symptoms and signs of acute and chronic inflammation of nasal and sinus mucosa were high in the study group.

Conclusion: Our study shows that most common anatomical variant associated with chronic inflammation of sinuses is deviated nasal septum.

Key words: Deviated nasal septum, Maxillary sinus, Sinusitis

INTRODUCTION

The nasal septum divides nasal cavity into the left and right halves both anatomically and physiologically. It is an accepted fact that some amount of deviation of nasal septum is common and having a perfectly straight septum is a rarity.[1] Various reasons have been attributed to the occurrence of deviated nasal septum including racial factors, birth molding of septum during parturition trauma and developmental deformities of septum.[2] Deviated nasal septum may cause nasal obstruction and symptoms of rhinosinusitis. Normally paranasal air sinuses drain the mucous and fluid into the nose through various openings. Severe obstruction may block these openings triggering chronic sinusitis. Tocík[3] evaluated the relationship between deviation of the nasal septum and diseases of the paranasal sinuses. Aust *et al.*[4] stated that if ostium size is <2.5 mm, it predisposes to the development of disease. Smith and Cable[5] assessed maxillary antral mucosa in chronic sinusitis patients.

In our present study, we tried to analyze the role of deviated nasal septum in sinus pathology in patients.

Access this article online

www.ijss-sn.com

Month of Submission : 02-2016
Month of Peer Review : 03-2016
Month of Acceptance : 04-2016
Month of Publishing : 04-2016

MATERIALS AND METHODS

The present study was conducted in the Departments of Anatomy and E.N.T. at Himalayan Institute of Medical Sciences Dehradun and Shri Guru Ram Rai Institute of Medical and Health Sciences Dehradun. The study was divided into two groups (15 each).

Group - A (Control): It comprised of 15 patients with a midline nasal septum, with symptoms of rhinosinusitis.

Corresponding Author: Sadakat Ali, Department of Anatomy, Shri Guru Ram Rai Institute of Medical & Health Sciences, Dehradun, Uttarakhand, India. Phone: +91-9634333944. E-mail: drsadakat786@gmail.com

Group - B (Study): It comprised of 15 patients with a deviated nasal septum, taken up for septal surgery.

Total we have taken 30 patients with symptoms of rhinosinusitis.

Chronic sinusitis in our patients was defined as inflammation of the nasal and paranasal mucosa, with persistent mucoid or mucopurulent discharge for longer than 3 months that was resistant to repeated antimicrobial therapy and antral irrigation.

Patients with allergic rhinitis, polyps, or abnormal mass in nasal cavity and grossly deformed nose due to pathological condition were excluded from the study.

After examining ears, throat, mouth, larynx, a detailed examinations of the nose and paranasal sinuses was done.

Maxillary sinuses are most commonly involved in chronic sinusitis as drainage is against gravity because of higher position of its Ostia. Therefore, in this study, only maxillary sinus was taken into account.

We observed following parameters:

I. Clinical examination:

1. A detailed examination of nose and paranasal sinuses was done through various methods as:
   - Rhinoscopy
   - Patency test
   - Antral puncture (proof puncture) - Only in selected cases with the help of antral trocar and cannula
   - Nasal diagnostic endoscopy - Wherever necessary.
2. X-ray of nasal cavity and paranasal sinuses (Occipitomental [Water's] view) was done in all patients.
3. Computed tomography CT-scan - Was done in some patients, wherever required.

The results were compared between the two groups.

II. Histopathological examination:

Mucosal biopsies from maxillary sinus were taken from patients who underwent septal surgery to yield diagnostic information to guide post-operative treatment for optimal long-term results. These were fixed in 10% formalin and further processed for paraffin sections and were stained by Hematoxylin and Eosin method.

RESULTS

I. Clinical examination:

1. All incidences of symptoms and signs seen by rhinoscopy and patency test were high in Group B (Tables 1 and 2).

The incidence of findings seen by nasal diagnostic endoscopy was found to be high in Group B except concha, bullosa, mucoid discharge, and accessory Ostia (Table 3).

Group A - Done on 5 patients

Group B - Done on 10 patients.

2. X-ray nose and PNS - Incidences of all findings were found to be high in Group B (Table 4, Figures 1 and 2).
3. CT-scan nose and PNS.

Incidences of most of the findings were found to be high in Group B (Table 5 and Figure 3).

Table 1: Incidence of symptoms and signs by rhinoscopy

Symptoms/ signs	Group A		Group B	
	Number of cases	Percent cases	Number of cases	Percent cases
Inferior turbinate hypertrophy	2	13.3	12	80
Middle turbinate hypertrophy	1	6.6	2	13.3
Nasal discharge	5	33.3	12	80
Congested nasal mucosa	7	46.6	10	66.6

Table 2: Incidence of positive cases (patency test)

Side	Group A		Group B	
	Number of cases	Percent cases	Number of cases	Percent cases
Right side	5	33.3	5	33.3
Left side	7	46.6	4	26.6
Both side	3	20	1	6.66

Table 3: Incidence of findings by endoscopy

Signs	Group A		Group B	
	Number of cases	Percent cases	Number of cases	Percent cases
Inferior turbinate hypertrophy	2	40	10	100
Middle turbinate hypertrophy	1	20	4	40
Spur	0	0	2	20
Concha bullosa	2	40	1	10
Paradoxical middle turbinate	1	20	2	20
Accessory ostia	2	40	1	10
Mucoid discharge	3	60	2	20
Mucopurulent discharge	2	40	6	60

Table 4: Incidence of cases by X-ray

Findings	Group A		Group B	
	Number of cases	Percent cases	Number of cases	Percent cases
Mucosal thickening	6	40	15	100
Inferior turbinate hypertrophy	2	13.33	12	80
Air-fluid level	0	0	4	26.67

Group A - Done on 2 patients
Group B - Done on 7 patients.

II. Histopathological examination:

On microscopic examination of mucosa, it was observed that Findings suggestive of acute as well as chronic inflammation were seen.

- Acute inflammation - There was hemorrhage in lamina propria and submucosa with infiltration of polymorphs (Figure 4)

Table 5: Incidence of cases by CT-scan

Findings	Group A		Group B	
	Number of cases	Percent cases	Number of cases	Percent cases
Mucosal thickening	1	50	7	100
Air-fluid level	1	50	4	57.14
Inferior turbinate hypertrophy	1	50	3	42.85

CT: Computed tomography

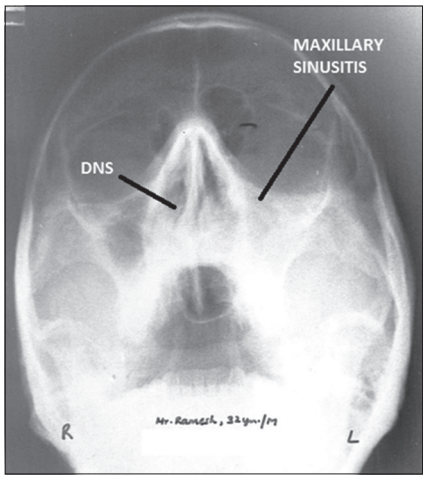

Figure 1: X-ray of patient having deviated septum showing mucosal thickening in maxillary sinus

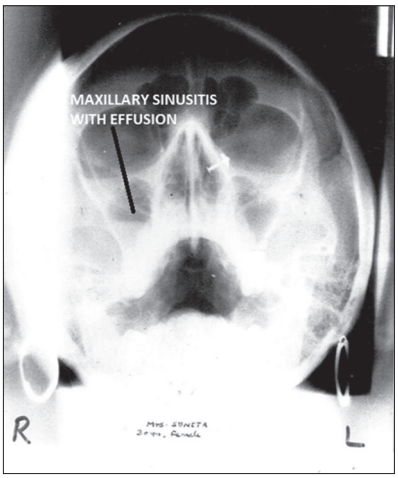

Figure 2: X-ray of patient having deviated septum showing air-fluid level in maxillary sinus

- Chronic inflammation - Epithelial erosion was seen along with edema in submucosa. Glands were exceedingly numerous and hyperplastic (Figure 5).

DISCUSSION

In the present study, we observed nasal septal deviation as one of the prime cause of chronic sinusitis.

In clinical study, incidence of all findings in patients related with sinus disease was high in Group B in comparison to Group A. In patients with midline septum, few cases of chronic sinusitis were confirmed with other pathological abnormalities in ostiomeatal area. To confirm this and differentiate the pathogenesis of chronic sinusitis in both groups (Groups A and B), CT-scan was performed in few patients of both groups.

Histological findings from mucosal biopsies correlated well with clinical findings. There were marked changes in mucosa of maxillary sinus like acute as well as chronic inflammation.

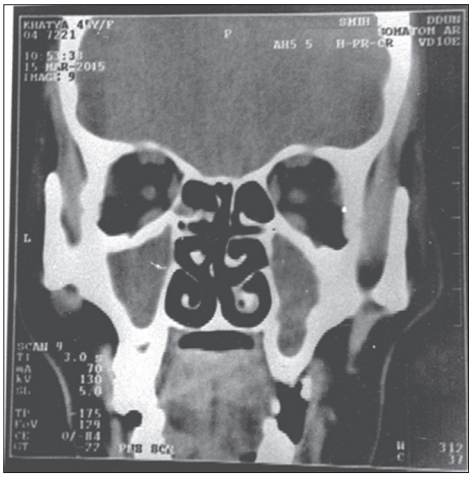

Figure 3: Coronal computed tomography-scan of a patient having deviated nasal septum showing bilateral hyper density in maxillary sinuses

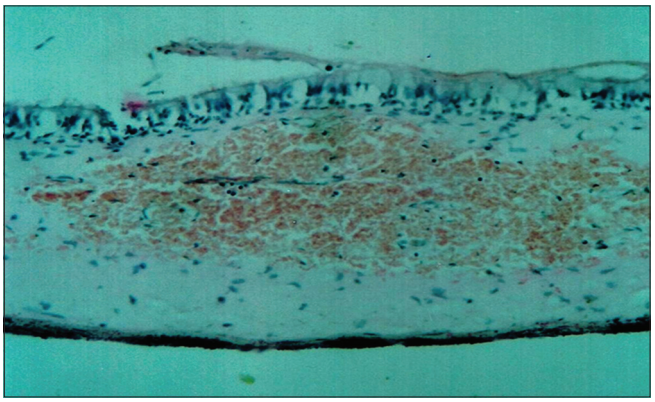

Figure 4: Sinus mucosa of patient having deviated septum showing acute inflammation. Hemorrhage in lamina propria and submucosa is seen with infiltration of polymorphs (H&E, ×200)

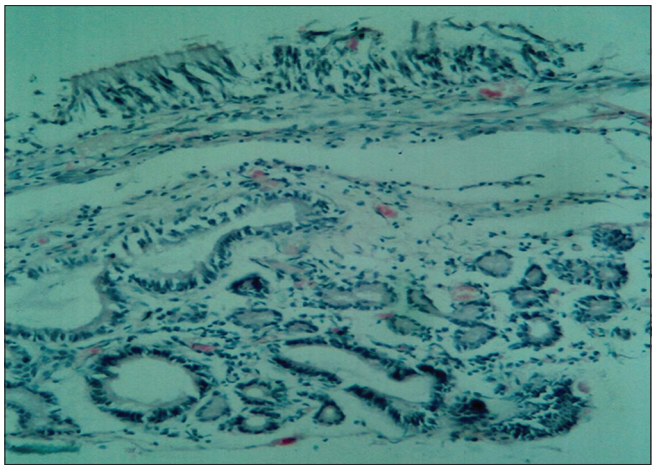

Figure 5: Sinus mucosa of patient having deviated septum showing chronic inflammation. Epithelial erosion along with oedema in submucosa is seen. Glands are exceedingly numerous and hyperplastic (H&E, ×200)

In previous studies, Inagi[6] investigated the histological changes in mucous membrane of human nasal septum in relation to the deviation of septum. Schall[7] studied the histology of mucosa of maxillary sinuses in humans in detail.

Collet *et al.*[8] evaluated the role of septal deviation in adults in pathogenesis of chronic sinusitis. Arslan *et al.*[9] did CT study and found most common anatomical variant was septal deviation in 36%.

CONCLUSION

In the present study, detailed clinical and radiological examination of patients was done along with histo-pathological examination of maxillary sinus mucosa, which proves that all cases of chronic maxillary sinusitis were associated with anatomical variations and most common was deviated nasal septum. Therefore, it is recommended that management of chronic maxillary sinusitis should include simultaneous treatment of any anatomical variation. For treating chronic sinusitis along with deviated nasal septum, nowadays treatment of choice is Septoplasty along with Functional Endoscopic Sinus Surgery (FESS). FESS technique is used for managing sinus infection and ostial obstruction.

REFERENCES

1. Gray LP. Deviated nasal septum. Incidence and etiology. Ann Otol Rhinol Laryngol Suppl 1978;87:3-20.
2. Neskey D, Eloy JA, Casiano RR. Nasal, septal and turbinate anatomy and embryology. Otolaryngol Clin North Am 2009;42:193-205.
3. Tocík J. Relation between deviation of the nasal septum and diseases of the paranasal sinuses. Cesk Otolaryngol 1989;38:41-4.
4. Aust R, Drettner B, Hemmingsson A. Elimination of contrast medium from the maxillary sinus. Acta Otolaryngol 1976;81:468-74.
5. Smith MC, Cable HR. Correlation of the sinoscopic appearance of the maxillary antrum with histological and bacteriological findings. J Laryngol Otol 1988;102:1086-8.
6. Inagi K. Histological study of mucous membranes in the human nasal septum. Nihon Jibiinkoka Gakkai Kaiho 1992;95:1174-89.
7. Schall LR. The histology and chronic inflammation of the nasal mucous membrane. Ann Otol Rhinol Laryngol 1933;42:15-38.
8. Collet S, Bertrand B, Cornu S, Eloy P, Rombaux P. Is septal deviation a risk factor for chronic sinusitis? Review of literature. Acta Otorhinolaryngol Belg 2001;55:299-304.
9. Arslan H, Aydinlioglu A, Bozkurt M, Egeli E. Anatomic variations of the paranasal sinuses: CT examination for endoscopic sinus surgery. Auris Nasus Larynx 1999;26:39-48.

How to cite this article: Arora M, Ali S, Choudhary AK, Suchit K, Bansal C. Correlation between Deviated Nasal Septum and Sinusitis: A Clinical and Histopathological Study. Int J Sci Stud 2016;4(1):21-24.

Source of Support: Nil, **Conflict of Interest:** None declared.