

Role of Hepatic Artery Embolization in Giant Hemangioma of Liver

Prajwalit Gaur¹, Ashwini Bakde Umredkar², Aarti Anand³, Jawahar Rathod¹, Manish Agrawal⁴

¹Associate Professor, Department of Radiodiagnosis, Government Medical College, Nagpur, Maharashtra, India, ²Assistant Professor, Department of Radiodiagnosis, Government Medical College, Nagpur, Maharashtra, India, ³Professor and Head, Department of Radiodiagnosis, Government Medical College, Nagpur, Maharashtra, India, ⁴Fellow, Department of Radiodiagnosis, Government Medical College, Nagpur, Maharashtra, India

Abstract

Introduction: Endovascular management in the form of transarterial embolization (TAE) is offered in cases of symptomatic hemangiomas, unresectable hemangiomas, preoperatively, in diffuse hemangiomatosis, in progressively growing hemangiomas, and those at a high risk of bleeding. Recent studies have shown that TAE is a safe and effective treatment option for lesions that are large and located peculiarly on inferior surface of liver and high risk of rupture.

Purpose: The purpose is to study the radiological features of giant haemangioma on various modalities, to assess the safety, feasibility, and efficacy of TAE of hepatic artery in giant liver haemangioma, and to evaluate post-procedural complications and follow-up (FU) examinations to look for success of embolization.

Materials and Methods: It is a prospective retrospective study conducted in Radiodiagnosis Department of GMCH, Nagpur. All giant hemangiomas detected on ultrasonography, computed tomography, or magnetic resonance imaging in symptomatic patients and already diagnosed cases presenting with recurrence/relapse and complicated giant hemangiomas were included in the study. Exclusion criteria were hemangiomas <4 cm in size and general contraindications to angiography, intolerance of contrast media, and peripheral vascular disease.

Results: The study revealed significant reduction in the size of lesion ($P < 0.0001$ – highly significant [HS]) at 3- and 9-month FU, respectively, in the right lobe of liver and ($P < 0.0105$ – significant [S] at 3-month FU and $P < 0.0032$ - HS at 9-month FU) the left lobe of liver.

Conclusions: TAE in giant hepatic hemangiomas is safe, feasible, efficient, minimally invasive with good patient acceptance, with minimal complications, and no mortality. Hence, transcatheter arterial embolization should be performed in the management of giant hepatic hemangiomas.

Key words: Computed tomography, Giant hepatic hemangiomas, Hepatic artery embolization, Transarterial embolization, Ultrasonography

INTRODUCTION

The modalities for the management of giant hemangiomas include corticosteroid therapy, radiofrequency ablation, hepatic artery ligation, intra-arterial embolization,

anatomic liver resection, enucleation, and rarely liver transplantation.¹⁻³ Surgical liver resection or enucleation is an effective curative treatment for giant hemangiomas; however considering the risk of massive intraoperative bleeding and following shock, surgery should be considered only for patients with established complications, diagnostic uncertainty, and incapacitating symptoms, where operative risk is acceptable.¹ Occasionally, liver transplantations are necessary when the giant hemangioma occupies the entire liver, diffuse hemangiomatosis, or ruptured.² Various other treatment methods such as corticosteroid injection, hepatic artery ligation, and radiotherapy show controversial results and their long-term results have been poor.⁴⁻⁶

Access this article online



www.ijss-sn.com

Month of Submission : 02-2017
Month of Peer Review : 03-2017
Month of Acceptance : 03-2017
Month of Publishing : 04-2017

Corresponding Author: Dr. Ashwini Bakde Umredkar, Plot No. 150/A, Flat No. 303, Prajakta Orchid Apartment, Pandey Layout, Khamla, Nagpur - 440 025, Maharashtra, India. Phone: +91-9822909771. E-mail: ashwiniumredkar@yahoo.co.in

Diagnosis of hemangioma can be made using various modalities such as ultrasound (USG), contrast-enhanced computed tomography (CECT), magnetic resonance imaging (MRI), technetium 99m-labeled red blood cell scanning, and digital subtraction angiography (DSA). However, histopathological diagnosis using fine-needle aspiration or biopsy is not recommended due to risk of rupture and high bleeding.

Transcatheter hepatic artery embolization is an interventional radiological technique. It is a minimally invasive procedure and can be done within much less time on patients and is not associated with significant morbidity when compared to open surgical procedures.

Hemangioma is one of the most common benign tumors of liver, accounting for 0.4-7.3% of all space-occupying hepatic lesions.⁷ Adam *et al.* defined hemangiomas as “giant” if their diameters exceed more than 4 cm.⁸

Endovascular management in the form of transarterial embolization (TAE) is offered in cases of symptomatic hemangiomas, unresectable hemangiomas, i.e., involving both lobes,⁹ as a pre-operative temporizing procedure in ruptured hemangiomas,¹⁰ in diffuse hemangiomatosis, in progressively growing hemangiomas, and those at a high risk of bleeding. Recent studies have shown that TAE is a safe and effective treatment option for lesions that are large and located peculiarly on inferior surface of liver and high risk of rupture. Many case studies have been published to date on the role of hepatic artery embolization in giant liver hemangioma without any significant complications. The most common complications of embolization are pain, pyrexia, leukocytosis, and nausea, which last for a few days. Post-embolization pain is due to thrombosis and necrosis. Severe complications are rare and include infection, hepatic abscess and sepsis, and migration of the embolization agent into lungs and kidneys.

MATERIALS AND METHODS

The study was conducted in Intervention Radiology Unit, Department of Radiodiagnosis, Government Medical College, Nagpur, for 2 years (September 2013 to August 2015), over 29 patients.

Source of patients: Intervention Radiology Unit and Department of Surgery, Government Medical College Hospital, Nagpur.

Inclusion Criteria

1. All giant hemangiomas detected on USG, CT, or MRI in symptomatic patients or giant hemangiomas

incidentally detected on USG, CT, or MRI in asymptomatic patients with undue risk of rupture

2. Known cases of giant hemangiomas with TAE or resection done and presenting with recurrence/relapse/not responding to treatment
3. Ruptured/complicated giant hemangiomas as intratumoral bleed.

Exclusion Criteria

1. Hemangiomas <4 cm in size
2. Patients with portal vein thrombosis
3. General contraindications to angiography, intolerance of contrast media, peripheral vascular disease
4. Hemorrhagic diathesis (international normalized ratio >1.4)
5. Deranged renal functions (serum creatinine >1.5 mg/dl)
6. Extremely debilitated and terminally ill patients.

Selection of Patients

Patients were selected by pre-procedural imaging diagnosis using USG, abdominal CT, and/or MRI with certain diagnosis of giant hemangioma of liver, either single or multiple, and after prior investigations, patients were subjected to transcatheter hepatic artery embolization.

Detailed history of patients was collected including medical history and personal history.

Ethical clearance was obtained from the Institutional Ethical Review Committee of Government Medical College, Nagpur.

Equipment used and Preparation of Patients

Patients' blood pressure and pulse rate are monitored. Coagulation profile, hemoglobin and hematocrit, HIV and hepatitis B surface antigen status, liver and renal function tests were investigated. Patients were advised to be nil by mouth for 6 h at least before the procedure, and any history of allergies were ruled out.

Part preparation in the form of hair removal in puncture site, i.e., in bilateral inguinal region should be done before the procedure.

Premedication was given to the patients in the form of injection atropine 0.6 mg intramuscularly 10-15 min before the procedure. An eye bandage was given to the patient to reduce anxiety and apprehension. Patients were positioned supine on fluoroscopic table with C-arm positioned over the upper abdomen. The puncture site (inguinal region) was cleaned with povidone-iodine and surgical spirit. Using aseptic precautions, 2% lignocaine was utilized for local anesthesia. Using sterile dry cloths, the whole body was covered except for puncture site.

TAE Procedure

Under local anesthesia, the right femoral artery was punctured with single puncture needle using Seldinger technique. 5-F angiosheath was pushed and placed in position. Around 3000 U of heparin was given through the sheath.

Using Terumo guide wire, cobra catheter was placed in descending aorta. Coeliac, hepatic, and superior mesenteric angiograms are taken using contrast agent.

Angiography showed the intrahepatic slug or popcorn-like tumor signal. In the early arterial phase, the periphery of hepatic hemangioma was stained first, and the contrast agent gradually filled the inside of the lesion, known as “early leaving but late returning, hanging nut on a twig” sign.

After confirmation of the feeding arteries and the location, size, and number of hepatic hemangiomas, a microcatheter was superselectively placed in feeding arteries, and a mixture of polyvinyl alcohol (PVA) particles with lipiodol was slowly injected. Gelfoam was used in some patients, however coils were not utilized as a part of embolization procedure.

Post-procedural Care

Immediate postprocedural compression was given for 10 min at the site of femoral puncture to stop bleeding and a dressing was applied. The patient was reassured, and blood pressure, pulse rate, and respiratory rate were monitored. In case of pain, oral analgesics were given.

All patients were monitored postoperatively (vital signs, oxygen saturation) with particular attention paid to the lower limb skin temperature and color and dorsalis pedis pulses. Rehydration was considered paramount to protect the liver and prevent infection.

Follow up: The patients were followed up for around 9 months to observe for change in tumor size, appearance on USG, CT imaging, and symptoms.

RESULTS

In this study, only those patients who were diagnosed as giant hemangioma of liver on CECT and MRI were included; 1 patient who was initially diagnosed as giant hemangioma on USG, suggestive of hepatocellular carcinoma on CECT, was excluded from the study. Hence, analysis was made on 28 patients.

Analysis of the following important observations was made.

Female-to-male ratio was 2:1, and majority of the patients were in the age group of 31-50 years, i.e., 20 patients accounting for 71.4% of cases.

Table 1 shows clinical presentation of cases. Most of the patients were symptomatic, presented with discomfort and fullness of abdomen (39.2%), abdominal pain (21.4%), and with jaundice (3.6%). Around 35.7% of patients presented incidentally, out of which 5 patients had hepatomegaly and palpable mass.

USG Features (Figure 1)

USG is an important preliminary investigation in the diagnosis of hemangioma. Thirteen (46%) cases of giant hemangioma are solitary and rest of the cases show multiple giant hemangioma.

Only right lobe involvement was seen in 14 cases; solely left lobe involvement in 3 cases and both lobes' involvement seen in 11 cases.

Table 1: Distribution based on clinical presentation of cases

Clinical presentation	Number of cases (%)
Abdominal discomfort	11 (39.2)
Abdominal pain	6 (21.4)
Incidentally	10 (35.7)
Jaundice	1 (3.6)

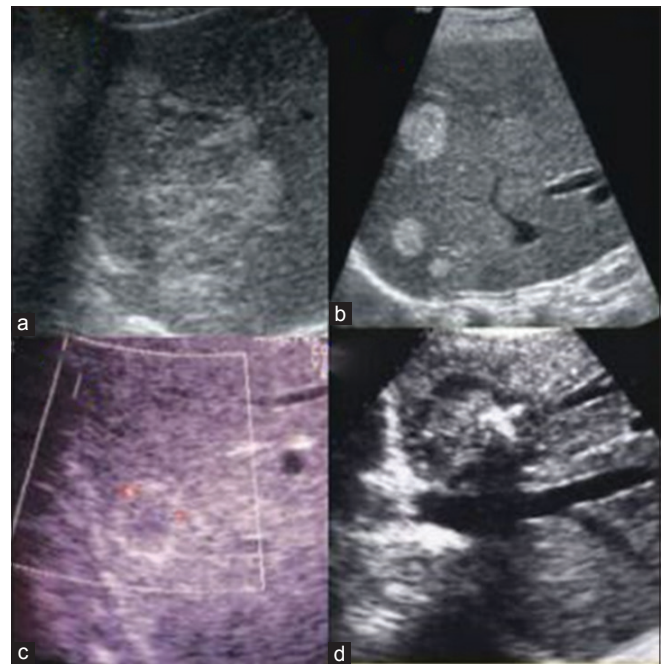


Figure 1: Ultrasound appearances of hepatic hemangioma. (a) Transverse section of liver showing heterogeneous hyperechoic lesion in the right lobe, (b) multiple small hemangiomas in the right lobe, (c) atypical hemangioma with echogenic border with isoechoic center and (d) isoechoic lesion with peripheral calcification

Twenty-one (76%) cases appeared as hyperechoic (heterogeneously hyperechoic, hyperechoic, hypoechoic with hyperechoic rim, and echogenic), 4 (14%) as heterogeneous, and 3 (10%) as hypoechoic in echogenicity. Most of the lesions showed no-to-minimal vascularity. Mild vascularity was seen in only 3 (11%) cases. Most of the lesions were not associated with any other condition. Only in 4 (15%) cases, hepatic cysts were detected.

CECT Features (Figure 2)

On CECT, solitary lesion was seen in 10 (35.7%) cases, 2 to 3 lesions were seen in 13 (46.5%) cases and ≥ 4 lesions were seen in 5 (17.9%) cases. Twenty-one (72.4%) cases appeared as hypodense and 27 (93.1%) cases showed progressive centripetal gradual filling with delayed persistent of contrast of typical giant hemangioma. One case showed peripheral contrast enhancement with delayed persistent of contrast as of atypical giant hemangioma (hyalinized hemangioma) and 1 case showed early homogeneous contrast enhancement with rapid washout of contrast as a feature of hepatocellular carcinoma.

Few, discrete calcifications were seen in 2 cases, and in 1 case, few, central, scattered cystic changes were seen. These calcification and cystic changes were suggestive of atypical findings.

Hepatic cysts were found in 5 (18%) cases and cholelithiasis and fatty liver were seen in 2 (7%) cases each.

On comparing USG findings with CECT, 18 cases (GH) and 3 cases (AGH) were correctly diagnosed as giant hemangioma. Two cases each were misdiagnosed as hepatocellular carcinoma and metastasis on USG. One case each was misdiagnosed as hepatic abscess, focal nodular hyperplasia, and hepatic adenoma. The detection rate of USG for giant hemangioma including atypical and typical is 71.4%.

MRI Features (Figure 3)

MRI was not done in all patients. It was done in 4 cases only. MRI showed T1-weighted (T1W) images as hypo- and iso-intense in 2 cases each, T2W images appeared as hyperintense in all 4 cases, and T1W contrast sequence showed progressive centripetal gradual contrast filling in all the 4 cases.

DSA (Figure 4)

Twenty-five cases (89.28%) showed vascular supply from only hepatic artery (Figure 4). Two cases (7.1%) showed add-on vascular supply from aberrant hepatic artery, branch from superior mesenteric artery, and 1 case showed add-on vascular supply from the branch of inferior phrenic artery.

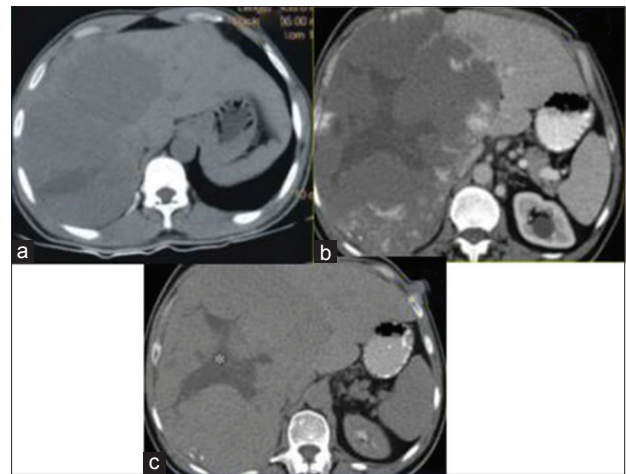


Figure 2: Computed tomography (CT) appearances of hepatic hemangioma. Axial section plain CT (a) showing large hypodense lesion in the right lobe of liver, portal venous-phase CT, (b) showing typical giant hemangioma with peripheral puddling of contrast, delayed-phase CT, (c) showing delayed centripetal enhancement with central non-enhancing areas (*) consistent with central fibrous scar

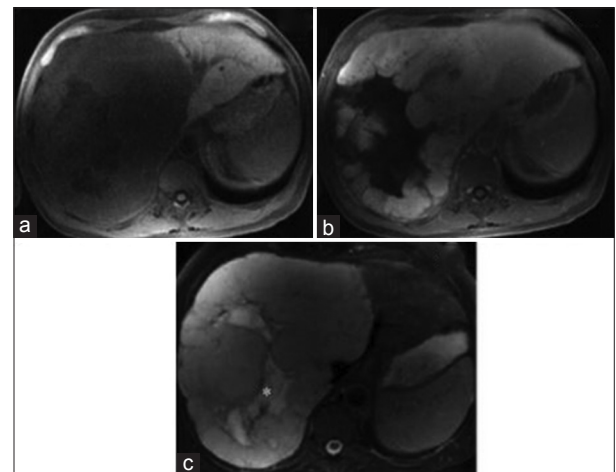


Figure 3: Magnetic resonance imaging (MRI) appearances of giant hepatic hemangioma. Unenhanced T1-weighted (T1W) MRI (a) showing large iso- to hypo-intense mass in the right lobe of liver. Axial T2W MRI (b) showing intermediate signal intensity with central loculation of higher signal intensity (*) corresponding to central scar. Gadolinium-enhanced T1W MRI (c) showing peripheral nodular puddling with progressive centripetal enhancement

DSA procedure was performed well in almost all patients. Six cases (21.4%) complained of fever and pain as immediate complications (within 6 days following procedure), 4 cases (14.2%) complained of distention of abdomen, and 4 cases showed rise in leukocyte count. Puncture site hematoma occurred in 1 case. Twenty-seven cases (96.4%) showed no significant complications on long-term follow-up (FU). One case showed abscess formation in giant hemangioma.

Table 2 shows significant rise in platelet count before and after the TAE procedure ($P = 0.0006$).

Tables 3 and 4 and Chart 1 show comparison and interpretation of average size of lesion at pre-TAE and 3- and 9-month FU on CECT in the right and left lobes of the liver. It shows significant reduction in the size of lesion ($P < 0.0001$ - highly significant [HS]) from 8.97 ± 4.95 cm to 7.48 ± 4.34 cm and 6.41 ± 3.60 cm at 3- and 9-month FU, respectively, in the right lobe of the liver. Similar significant reduction in the size of lesion ($P < 0.0001$ - HS at 3-month FU and $P < 0.0004$, HS at 9-month FU) noted in the left lobe of liver from 4.13 ± 4.80 cm to 3.46 ± 4.10 cm (3-month FU) and 3.05 ± 3.41 cm (9-month FU) (Figure 5).

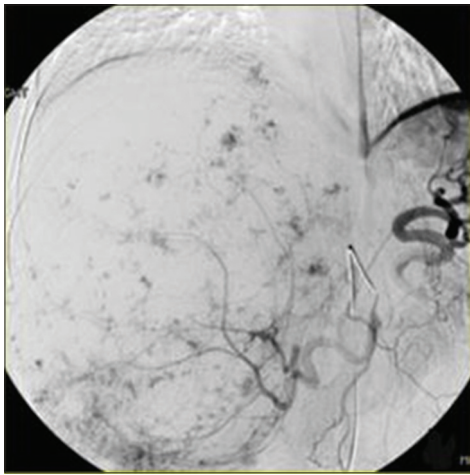


Figure 4: Classic snowy tree or cotton wool appearance of giant hemangioma on predominantly embolization angiography of the right hepatic artery

Table 2: Average pre-and post-TAE platelet counts

Statistical value	Pre-TAE platelet count	Post-TAE platelet count
Mean \pm SD	210500 \pm 76441.94	233678.6 \pm 58177.92
P value	0.0006-HS	

SD: Standard deviation, TAE: Transarterial embolization, HS: Highly significant

Table 3: Comparison of size of lesions at pre-TAE and 3-and 9-month FU on CECT

Site of lesion	Pre-TAE	3-month FU	9-month FU
Right lobe	8.97 \pm 4.95	7.48 \pm 4.34	6.41 \pm 3.60
Left lobe	4.13 \pm 4.80	3.46 \pm 4.10	3.05 \pm 3.41

CECT: Contrast-enhanced computed tomography, TAE: Transarterial embolization, FU: Follow-up

Tables 5 and 6 show comparison and interpretation of average size of lesion at pre-TAE and 3- and 9-month FU on USG in the right and left lobes of the liver (Figure 6). It shows significant reduction in the size of lesion ($P < 0.0001$ - HS) from 9.7 ± 5.29 to 7.66 ± 4.18 cm and 6.39 ± 3.50 cm at 3- and 9-month FU, respectively, in the right lobe of liver. Similar significant reduction in the size of lesion ($P < 0.0105$ - significant at 3-month FU and $P < 0.0032$ - HS at 9-month FU) noted in the left lobe of liver from 3.82 ± 5.46 to 3.45 ± 4.07 cm (3-month FU) and 3.01 ± 3.44 cm (9-month FU).

Table 7 shows the comparison of appearance of lesion on USG on pre-TAE, 3 months following post-TAE, and 9 months following after TAE. Most of the patients, before TAE, are heterogeneously hyperechoic (45%), heterogeneous (25%), and hypoechoic with hyperechoic rim (14%). Following 3 months after the procedure, overall echogenicity of the lesions decreased on USG. Nearly 71.4% of lesions were found echogenic at 3-month FU. Following 9 months after the procedure, echogenicity again decreased. Most of the lesions, i.e., 92.8% became hypoechoic after 9 months following the procedure.

DISCUSSION

This study was designed to determine safety, feasibility, and efficacy of TAE and radiological features of giant hemangioma of liver. In this observational study, the total number of patients was 28 of which 19 were females and 9 were males, with female-to-male ratio of 2:1. The most common age group observed was 31-50 years, with a mean age of 42.10 years and more common in females with female-to-male ratio of approximately 2:1, which is in concordance with studies by Gandolfi *et al.*¹² and Ng *et al.*¹³

Twenty-eight patients underwent imaging investigations such as USG, CT scan, and MRI for the diagnosis of giant hemangioma. Then, fluoroscopic-guided hepatic artery embolization was done using transcatheter transfemoral approach after the patients gave written consent for the procedure and after thorough patient preparation was done as described previously in "materials and methods" section.

Table 4: Evaluation of change in the size of lesion at pre-TAE and 3-and 9-month FU on CECT

Statistical value	Right lobe		Left lobe	
	Pre-TAE-3-month FU	Pre-TAE-9-month FU	Pre-TAE-3-month FU	Pre-TAE-9-month FU
Mean \pm SD	1.49 \pm 1.22	2.56 \pm 1.53	0.66 \pm 0.79	1.08 \pm 1.61
t value/Z value	6.4279	8.8399	3.903	3.540
P value	<0.0001, HS	<0.0001, HS	0.0001, HS	0.0004, HS

CECT: Contrast-enhanced computed tomography, TAE: Transarterial embolization, HS: Highly significant, FU: Follow-up

Permanent embolizing materials, PVA particles, were used in all patients. The patients were also explained in their own language the type of procedure including risks and

complications which may arise after the procedure. Patients with normal parameters were included in the study and those patients with abnormal parameters were included after treating them for the same.

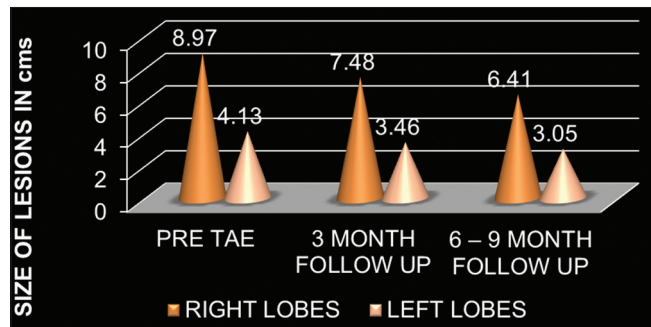


Chart 1: Size of lesions on the basis of computed tomography finding at pre-transarterial embolization and after 3- and 9-month follow-up

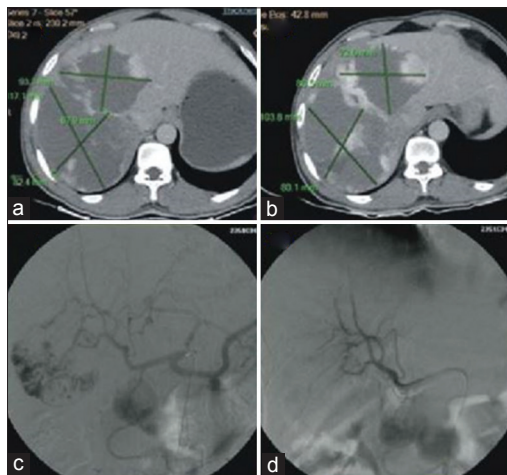


Figure 5: Pre-embolization portovenous phase image (a) Showing peripheral enhancement and (b) post-embolization image in the same patient showing reduction in the largest diameter and contrast opacification as compared to (a), (c) celiac angiogram with cotton wool appearance of hemangioma and post-embolization check angiogram image, (d) disappearance of contrast blush

Table 5: Comparison of size of lesions at pre-TAE and 3-and 9-month FU on ultrasound

Site of lesion	Pre-TAE	3-month FU	9-month FU
Right lobe	9.7±5.29	7.66±4.18	6.39±3.50
Left lobe	3.82±5.46	3.45±4.07	3.01±3.44

TAE: Transarterial embolization, FU: Follow-up

Table 6: Evaluation of change in the size of lesion at pre-TAE, 3-and 9-month FU on USG

Statistical value	Right lobe		Left lobe	
	Pre-TAE-3-month F/U	Pre-TAE-9-month F/U	Pre-TAE-3-month F/U	Pre-TAE-9-month F/U
Mean±SD	2.03±4.18	3.30±2.24	0.36±1.24	0.80±3.44
t value/Z value	5.6875	7.7877	2.558	2.920
P value	<0.0001, HS	<0.0001, HS	0.0105, S	0.0032, HS

USG: Ultrasound, TAE: Transarterial embolization, FU: Follow-up

A total of 28 procedures were done in this study. The patients were followed up for up to 9 months clinically, using USG and CT scans for statistical analysis.

TAE in giant hemangioma of liver as emphasized by studies in Table 8 can be concluded as follows:

1. Symptomatic improvement was documented in all patients after embolization with significant reduction in the mean size of the tumor on FU radiologic examinations.^{11,15}
2. The use of embolization for hepatic hemangiomas provides safe and effective treatment of the patient's symptoms, valuable in inoperable tumors and complicated cases while avoiding operative intervention, extended hospitalization, or postoperative recuperation.^{18,21,22}
3. However, Srivastava *et al.*,¹⁶ Mohan *et al.*,²³ and Tarazov and Polysalov²⁰ could not show any significant changes in tumor size after TAE performed on 8, 1, and 4 patients, respectively.
4. Granov *et al.*¹⁹ found that symptomatic relief occurred in 2 patients only, more over it got worsen in 4 of 14 asymptomatic patients, and on 1-year FU, reduction in tumor size was noted in only 1/3rd of patients.

Taking the above dilemma into considerations, we decided to evaluate the utility, adequacy, and efficacy of TAE in giant hemangioma of liver.

Clinical Presentation

In the present study, most of the patients were symptomatic (64.3%), presented with discomfort and fullness of abdomen (39.2%), abdominal pain (21.4%), and with jaundice (3.6%). Around 35.7% of patients presented incidentally, out of which 5 patients had hepatomegaly and palpable mass.

According to Gandolfi *et al.*,¹² eight of the 17 patients with giant hepatic hemangiomas were symptomatic (47%). Seven reported discomfort and feeling of fullness and one patient presented with jaundice. The other nine patients were

asymptomatic at the first examination, although five had clinically evident hepatomegaly, and in two, an abdominal mass was palpable.

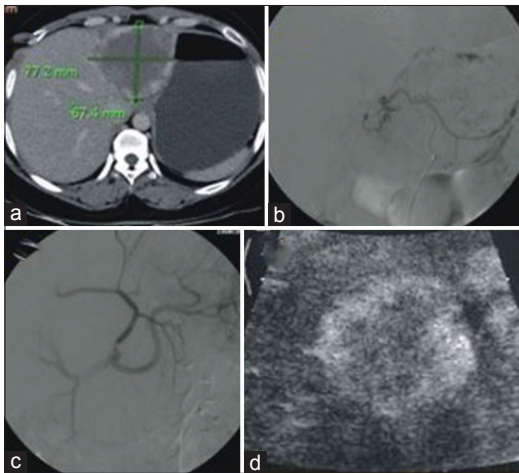


Figure 6: Contrast-enhanced computed tomography arteriportal-phase axial image (a) Showing giant hepatic hemangioma in the left lobe, pre-embolization celiac angiogram, (b) showing left hepatic artery arising from the left gastric artery, post-embolization image, (c) showing absence of blush and (d) 6-month post-embolization ultrasound follow-up image showing heterogeneous appearance with peripheral hyperechogenicity

Table 7: Comparison of appearance of lesion on ultrasound

Ultrasound appearance of lesion	Pre-TAE N=28 (%)	3-month FU N=28 (%)	9-month FU N=28 (%)
Heterogeneously hyperechoic	13 (45)	-	-
Heterogeneous	7 (25)	2 (7.1)	-
Hypoechoic with hyperechoic rim	4 (14)	-	-
Hyperechoic	2 (7.1)	6 (21.4)	-
Echogenic	2 (7.1)	20 (71.4)	2 (7.1)
Hypoechoic	-	-	26 (92.8)

TAE: Transarterial embolization, FU: Follow-up

In a study by Schwartz and Husser,²⁴ 19 out of 28 patients had significant abdominal pain (67%). In eight patients, hepatic mass was palpable.

In a study by Ho *et al.*,²⁵ 36 out of 61 patients were symptomatic (59%). The present study is comparable with the study of Schwartz and Husser and Ho *et al.*

The present study shows that lesions are solitary in 46% of cases and having predilection for right lobe (89%) which is comparable with a study done by Sun *et al.* as shown in Table 9.

We observed that most of cases are hyperechogenic in appearance (76%) which is comparable with the study of Gandolfi *et al.* as shown in Table 10.

According to Machado *et al.*,²⁶ Toro *et al.*,²⁷ and Sun *et al.*,¹¹ giant hemangioma appears as well-defined, heterogeneous, hyperechoic mass with posterior acoustic enhancement on posterior wall. Some lesions have hypoechoic center in comparison to peripheral rim. Color Doppler USG showed no-to-minimal flow in most of the hemangiomas. Some hemangiomas had unusual findings as cysts or calcifications within. Hemangiomas do not present with any hypoechoic halo around the lesion. These findings are comparable with the present study.

No significant complications were noted in the present study. Post-embolization syndrome in the form of fever and leukocytosis was relieved after symptomatic treatment. Abdominal distention and liver pain occurred in 14% patients, it may be due to embolization of tumor vessels, drug action, and ischemia. On long-term FU, abscess formation occurred in 1 patient.

Immediate complication rate was 46% in the present study which is comparable with a study done by Sun *et al.* as shown in Table 11.

Table 8: Various studies on TAE in giant hemangioma of liver

Authors	Year of study	Number of cases	Embolizing material
Zeng <i>et al.</i> ¹⁴	2004	98	Pingyangmycin-lipiodol emulsion
Firouznia <i>et al.</i> ¹⁵	2014	20	PVA particles (300-400 μ)
Srivastava <i>et al.</i> ¹⁶	2001	8	PVA particles or Gelfoam and steel coils
Sun <i>et al.</i> ¹¹	2015	27	Pingyangmycin with lipiodol
Althaus <i>et al.</i> ¹⁷	1996	2	PVA particles
Deutsch <i>et al.</i> ¹⁸	2001	3	-
Granov <i>et al.</i> ¹⁹	1999	25	-
Tarazov and Polysalov ²⁰	1993	4	-
Tarazov <i>et al.</i> ²¹	1990	3	-
Martin <i>et al.</i> ²²	1986	7	-
Mohan <i>et al.</i> ²³	2007	1	PVA particles
Present study	2015	28	PVA particles, Gelfoam

PVA: Polyvinyl alcohol, TAE: Transarterial embolization

Platelet Count

Giant hemangioma is believed to cause platelet sequestration within tumor resulting in hemorrhagic diathesis named as Kasaback–Merritt syndrome (consumptive coagulopathy).

Studies shown in Table 12 show significant increase in platelet count after treatment of giant hemangioma by any means which suggests that giant hemangioma is responsible for platelet sequestration. The present study shows significant rise in platelet count ($P = 0.0006$).

Srivastava *et al.*, Deutsch *et al.*, and Mohan *et al.* studied that TAE is a safe and effective therapy for hemangiomas, however no significant change in tumor size was noted.

Zeng *et al.*, Firouznia *et al.*, Sun *et al.*, and Panis *et al.* found significant reduction in tumor size of all patients and symptomatic relief in almost all patients.

In the present study, we found significant reduction in tumor size and symptomatic relief in all the 28 patients.

The present study is comparable with studies done by Firouznia *et al.* and Sun *et al.* as shown in Table 13.

CONCLUSIONS

1. In the prospective and retrospective study carried out on 28 patients, the detection rate of ultrasound and CT

Table 9: Studies on average number and size of hepatic hemangiomas

Authors/year	Number of cases	Single lesion (%)	Multiple lesion (%)	Number of cases (%)			Average size (cm)
				Right lobe	Left lobe	Both lobe	
Schwartz and Husser ²⁴ 1987	28	24 (85)	4 (15)	15 (67)	9 (46)	4 (15)	12.3
Gandolfi <i>et al.</i> ¹² 1991	123	93 (75)	30 (25)	-	-	-	<2 cm: 99 2-5 cm: 40>5 cm: 19
Ho <i>et al.</i> ²⁵ 2012	61	44 (72)	17 (28)	24 (57)	26 (60)	11 (18)	10±4.1
Sun <i>et al.</i> ¹¹ 2015	27	10 (37)	17 (63)	13 (96)	1 (51)	13 (48)	11.2±5.1
Present study	28	13 (46)	15 (53)	14 (89)	3 (50)	11 (39)	Right lobe-10.67 Left lobe-6.7

Table 10: USG features

Authors/year	Number of cases	USG appearance		
		Hyperechoic (%)	Hypoechoic (%)	Heterogeneous (%)
Gandolfi <i>et al.</i> ¹² 1991	123	84.8	1.8	13.4
Present study	28	21 (76)	3 (10)	4 (14)

USG: Ultrasound

Table 11: Incidence of post-procedural complications

Authors/year	Number of cases	Complications (cases)	Immediate complications					Long-term complications
			Fever	Pain	Leukocytosis	Distention	Puncture site hematoma	
Panis <i>et al.</i> ²⁸ 1993	1	1	1	1	-	-	-	Abscess
Vassiou <i>et al.</i> ²⁹ 2007	1	1	-	1	-	-	-	No
Mohan <i>et al.</i> ²³ 2007	1	1	1	1	-	-	-	No
Firouznia <i>et al.</i> ¹⁵ 2014	20	1	1	1	1	1	-	No
Sun <i>et al.</i> ¹¹ 2015	27	18 (66%)	12	5	-	6	-	No
Present study	28	13 (46%)	6	6	4	4	1	27-No 1-Abscess

Table 12: Platelet count

Authors/year	Number of cases	Pre-treatment platelet count	Treatment plan	Post-treatment platelet count
Longeville <i>et al.</i> ³⁰ 1997	1	46,000/mm ³	Orthotopic liver transplant	Normal
Hochwald and Blumgart ³¹ 2000	1	92,000/mm ³	Enucleation	Normal
Fung <i>et al.</i> ³² 2003	1	99,000/mm ³	TAE with PVA particles	151,000/mm ³
Aslan <i>et al.</i> ³³ 2009	1	20,000/mm ³	Enucleation	Normal
Present study	28	Mean-2,10,500/mm ³	TAE with PVA particles	Mean-2,33,678/mm ³

TAE: Transarterial embolization, USG: Ultrasound, PVA: Polyvinyl alcohol

Table 13: Post-TAE clinical and radiological FU

Authors/year	Number of cases	Pre-TAE mean size (cm)	Post-TAE mean size (cm)			P value	Symptomatic relief	Conclusion
			3 months	9 months	12 months			
Panis <i>et al.</i> ²⁸ 1993	1	17.5	12	-	12	-	Yes	*
Srivastava <i>et al.</i> ¹⁶ 2001	8	9.28±5.13	No significant change in size			-	Yes	**
Deutsch <i>et al.</i> ¹⁸ 2001	3	-	-	-	-	-	Yes	***
Zeng <i>et al.</i> ¹⁴ 2004	98	9.7±2.3	-	5.6±1.6	3.0±1.2	<0.01	Relief in all symptomatic 53 patients, and 2 patients with increased pain	****
Mohan <i>et al.</i> ²³ 2007	1	12.5	-	12.3	-	-	Yes	*****
Firouznia <i>et al.</i> ¹⁵ 2014	20	9.7	-	8.89	-	0.004	Yes in all cases	*****
Sun <i>et al.</i> ¹¹ 2015	27	11.24±5.08	8.95±4.33	7.6±3.9	-	<0.05	Yes in all cases	*****
Present study	28	Right lobe-8.9±4.9 Left lobe-4.1±4.8	Right lobe-7.4±4.3 Left lobe-3.4±4.1	Right lobe-6.4±3.6 Left lobe-3.0±3.4	- -	<0.0001 <0.0001	Yes in all patients	

*Alternative to major liver resection, preferred over hepatic artery ligation and radiotherapy, **Useful therapy in symptomatic hemangioma, ***Useful therapy in symptomatic hemangioma, ****TAE is effective and safe in treating all giant hemangiomas, *****Effective in symptomatic hemangioma, *****Safe and efficient for treating hemangiomas, however studies with larger sample size are required, *****TAE is safe and effective, and alternative to surgery. TAE: Transarterial embolization, FU: Follow-up

was 71.4% and 96.5%, respectively. Hence, USG and CT are good modalities for diagnosing giant hepatic hemangiomas.

- As there were good results in the form of symptomatic relief and reduction in the size of lesions, TAE is effective in the management of patients with giant hepatic hemangiomas.
- Thus, to conclude, TAE in giant hepatic hemangiomas is safe, feasible, efficient, minimally invasive with good patient acceptance, with minimal complications, and no mortality. Hence, transcatheter arterial embolization should be performed in the management of giant hepatic hemangiomas.

REFERENCES

- Bioulac-Sage P, Laumonier H, Laurent C, Blanc JF, Balabaud C. Benign and malignant vascular tumors of the liver in adults. *Semin Liver Dis* 2008;28:302-14.
- Ferraz AA, Sette MJ, Maia M, Lopes EP, Godoy MM, Petribi AT, *et al.* Liver transplant for the treatment of giant hepatic hemangioma. *Liver Transpl* 2004;10:1436-7.
- Meguro M, Soejima Y, Taketomi A, Ikegami T, Yamashita Y, Harada N, *et al.* Living donor liver transplantation in a patient with giant hepatic hemangioma complicated by Kasabach-Merritt syndrome: Report of a case. *Surg Today* 2008;38:463-8.
- Erdogan D, Busch OR, van Delden OM, Bennink RJ, ten Kate FJ, Gouma DJ, *et al.* Management of liver hemangiomas according to size and symptoms. *J Gastroenterol Hepatol* 2007;22:1953-8.
- Iwatsuki S, Todo S, Starzl TE. Excisional therapy for benign hepatic lesions. *Surg Gynecol Obstet* 1990;171:240-6.
- Hobbs KE. Hepatic hemangiomas. *World J Surg* 1990;14:468-71.
- Unal E, Francis F, Aquino A, Xu R, Morgan G, Teperman L. Liver transplant for mixed capillary-cavernous haemangioma masquerading as hepatocellular carcinoma in a patient with hepatocellular carcinoma. *Exp Clin Transplant Off J Middle East Soc Organ Transplant* 2011;9:344-8.
- Adam YG, Huvos AG, Fortner JG. Giant hemangiomas of the liver. *Ann Surg* 1970;172:239-45.
- Mungovan JA, Cronan JJ, Vacarro J. Hepatic cavernous hemangiomas: Lack of enlargement over time. *Radiology* 1994;191:111-3.
- Lehmann FS, Beglinger C, Schnabel K, Terracciano L. Progressive development of diffuse liver hemangiomatosis. *J Hepatol* 1999;30:951-4.
- Sun JH, Nie CH, Zhang YL, Zhou GH, Ai J, Zhou TY, *et al.* Transcatheter arterial embolization alone for giant hepatic hemangioma. *PLoS One* 2015;10:e0135158.
- Gandolfi L, Leo P, Solmi L, Vitelli E, Verros G, Colecchia A. Natural history of hepatic haemangiomas: Clinical and ultrasound study. *Gut* 1991;32:677-80.
- Ng WW, Cheung YS, Lee KF, Wong J, Yu SC, Lee PS, *et al.* Is regular follow-up scan for giant liver haemangioma necessary? *Hong Kong Med J* 2007;13:353-8.
- Zeng Q, Li Y, Chen Y, Ouyang Y, He X, Zhang H. Gigantic cavernous hemangioma of the liver treated by intra-arterial embolization with pingyangmycin-lipiodol emulsion: A multi-center study. *Cardiovasc Intervent Radiol* 2004;27:481-5.
- Firouznia K, Ghanaati H, Alavian SM, Nassiri Toosi M, Ebrahimi Daryani N, Jalali AH, *et al.* Management of liver hemangioma using transcatheter arterial embolization. *Hepat Mon* 2014;14:e25788.
- Srivastava DN, Gandhi D, Seith A, Pande GK, Sahni P. Transcatheter arterial embolization in the treatment of symptomatic cavernous hemangiomas of the liver: A prospective study. *Abdom Imaging* 2001;26:510-4.
- Althaus S, Ashdown B, Coldwell D, Helton WS, Freeny PC. Transcatheter arterial embolization of two symptomatic giant cavernous hemangiomas of the liver. *Cardiovasc Intervent Radiol* 1996;19:364-7.
- Deutsch GS, Yeh KA, Bates WB 3rd, Tannehill WB. Embolization for management of hepatic hemangiomas. *Am Surg* 2001;67:159-64.
- Granov AM, Tarazov PG, Polysalov VN. Arterial embolization in treatment of hepatic cavernous hemangioma. *Khirurgiia (Mosk)* 1999;13-7.
- Tarazov PG, Polysalov VN. Arterial embolization in unresectable cavernous hemangiomas of the liver. *Vestn Rentgenol Radiol* 1993;42-6.
- Tarazov PG, Polysalov VN, Ryzhkov VK. Embolization of the hepatic artery in hemangiomas of the liver. *Vopr Onkol* 1990;36:583-7.
- Martin B, Roche A, Radice L, Aguilar K, Kraiem C. Does arterial embolization have a role in the treatment of cavernous hemangioma of the liver in adults? *Presse Med* 1986;15:1073-6.

23. Mohan S, Gupta A, Verma A, Kathura MK, Baijal SS. Case report: Non-surgical management of a giant liver hemangioma. *Indian J Radiol Imaging* 2007;17:81.
24. Schwartz SI, Husser WC. Cavernous hemangioma of the liver. A single institution report of 16 resections. *Ann Surg* 1987;205:456-65.
25. Ho HY, Wu TH, Yu MC, Lee WC, Chao TC, Chen MF. Surgical management of giant hepatic hemangiomas: Complications and review of the literature. *Chang Gung Med J* 2012;35:70-8.
26. Machado MM, Rosa AC, Lemes MS, da Mota OM, da Silva OQ, Campoli PM, *et al.* Liver haemangiomas: Ultrasound and clinical features. *Radiol Bras* 2006;39:441-6.
27. Toro A, Mahfouz AE, Ardiri A, Malaguarnera M, Malaguarnera G, Loria F, *et al.* What is changing in indications and treatment of hepatic hemangiomas. A review. *Magn Reson Imaging* 2014;100:85-7.
28. Panis Y, Fagniez PL, Cherqui D, Roche A, Schaal JC, Jaeck D. Successful arterial embolisation of giant liver haemangioma. Report of a case with five-year computed tomography follow-up. *HPB Surg* 1993;7:141-6.
29. Vassiou K, Rountas H, Liakou P, Arvanitis D, Fezoulidis I, Tepetes K. Embolization of a giant hepatic hemangioma prior to urgent liver resection. Case report and review of the literature. *Cardiovasc Intervent Radiol* 2007;30:800-2.
30. Longeville JH, de la Hall P, Dolan P, Holt AW, Lillie PE, Williams JA, *et al.* Treatment of a giant haemangioma of the liver with Kasabach-Merritt syndrome by orthotopic liver transplant a case report. *HPB Surg* 1997;10:159-62.
31. Hochwald SN, Blumgart LH. Giant hepatic hemangioma with Kasabach-Merritt syndrome: Is the appropriate treatment enucleation or liver transplantation? *HPB Surg* 2000;11:413-9.
32. Fung EP, Luk WH, Loke TK, Chan JC. Kasabach-Merritt syndrome treated by transarterial embolisation of giant cavernous haemangioma. *J Hong Kong Coll Radiol* 2003;6:162-4.
33. Aslan A, Meyer Zu Vilsendorf A, Kleine M, Bredt M, Bektas H. Adult Kasabach-Merritt syndrome due to hepatic giant hemangioma. *Case Rep Gastroenterol* 2009;3:306-12.

How to cite this article: Gaur P, Umredkar AB, Anand A, Rathod J, Agrawal M. Role of Hepatic Artery Embolization in Giant Hemangioma of Liver. *Int J Sci Stud* 2017;5(1):40-49.

Source of Support: Nil, **Conflict of Interest:** None declared.