

Treatment of Displaced Supracondylar Fracture of Humerus in Children by Lateral Entry Pinning versus Cross Pinning

(Maj Gen) V P Pathania¹, Nishant Dubey², Sanjay Gupta³

¹Professor, Department of Orthopaedics, Shri Ram Murti Smarak Institute of Medical Sciences, Bhojipura, Bareilly, Uttar Pradesh, India,

²Post Graduate Student, Department of Orthopaedics, Shri Ram Murti Smarak Institute of Medical Sciences, Bhojipura, Bareilly, Uttar Pradesh, India, ³Professor, Department of Orthopaedics, Shri Ram Murti Smarak Institute of Medical Sciences, Bhojipura, Bareilly, Uttar Pradesh, India

Abstract

Introduction: Displaced supracondylar fractures of humerus are one of the most common fractures in pediatric age group with preferred treatment being close reduction with percutaneous K-wire fixation. This study compares whether lateral pin construct alone can provide same stability like cross (medial and lateral) pin fixation, and prevent iatrogenic ulnar nerve injury.

Materials and Methods: We evaluated 30 cases of supracondylar fractures of the humerus in children in which 15 were of lateral and 15 of cross pinning group from January 2014 to June 2015 with minimum 4 months follow-up period. Mean age was 7.3 years for both lateral and cross pinning group. We studied the surgical complications in both groups and also compared functional and radiological result of both groups.

Results: Patients were assessed by Flynn's criteria. Results were excellent in 66.7% and good in 33.3% of cross pinning group and for lateral pinning group, excellent in 73.3% and good in 26.6% cases which were not statistically significant ($P = 0.69$).

Conclusion: With the use of the specific techniques employed in this study, both lateral entry pin fixation and medial and lateral entry pin fixation are effective in the treatment of completely displaced (type III) extension supracondylar fractures of the humerus in children.

Key words: Children, Cross pinning, Lateral pinning, Supracondylar fractures humerus

INTRODUCTION

Supracondylar fractures of the humerus are the most common type of elbow fractures in children, accounting for 50-70% of all fractures about the elbow.

It is estimated that the extension-type represents approximately 96-98% of all pediatric supracondylar fractures of the humerus, whereas the flexion-type represents approximately 2-4%.¹

Decision to treat operatively depends on the quality of reduction, ability to maintain reduction, the degree of displacement, and fracture stability.

Many methods have been proposed for the treatment of supracondylar fractures of humerus in children:

1. Manipulative reduction and immobilization in a plaster cast with elbow flexed,
2. Axial skeletal traction on the ulna with the elbow flexed,
3. Dunlop's skin traction,
4. Closed reduction and percutaneous pinning and
5. Open reduction and internal fixation.²

Immobilization in a cast is generally accepted as the standard treatment for non-displaced fractures, but there is controversy as to the best treatment for displaced fractures.³ The routine non-operative management of type II and III supracondylar fracture of humerus with plaster cast after

Access this article online



www.ijss-sn.com

Month of Submission : 02-2016

Month of Peer Review : 03-2016

Month of Acceptance : 04-2016

Month of Publishing : 04-2016

Corresponding Author: Dr. Nishant Dubey, Department of Orthopaedics, Shri Ram Murti Smarak Institute of Medical Sciences, Bhojipura, Bareilly - 243 202, Uttar Pradesh, India. Phone: +91-9458705956. E-mail: drnishantdubey@gmail.com

closed reduction has reportedly been associated with a greater incidence of failure to obtain and maintain the fracture reduction and subsequent complication of malunion which led to the evolution of current techniques of percutaneous pinning.⁴

We conducted a study with the purpose to assess and compare the results of two methods of pinning - crossed pinning and lateral pinning - presently followed in the management of these difficult fractures.

MATERIALS AND METHODS

This study was conducted in Department of Orthopaedics at Shri Ram Murti Institute of Medical Sciences, Bareilly, Uttar Pradesh, India from January 2014 to June 2015. Institutional board reviews was done and permission obtained.

Inclusion Criteria

1. Age between 3 and 12 years and presenting within 2 weeks of injury
2. Closed fractures
3. Type II and III supracondylar fracture as per Gartland's Classification.

Exclusion Criteria

1. Open fractures
2. Floating elbow
3. Previous fracture in the same elbow.

In this study, supracondylar fracture of humerus was classified according to Gartland's classification.⁵

Type I: Undisplaced supracondylar fracture of the humerus

Type II: Displaced supracondylar fracture with intact posterior cortex

Type III: Displaced supracondylar fracture with no cortical contact

- a. Posteromedial
- b. Posterolateral.

A total of 30 patients were included with 15 in lateral pinning group and 15 in cross pinning group in the study. All patients underwent routine pre-operative investigations as required.

Technique

Immediately after the patient's arrival to the hospital a detailed clinical examination including a thorough neurovascular assessment was carried out. Standard anteroposterior and lateral radiographs of the involved elbow were taken, and the fracture type was noted. The cases were treated on an emergency basis with closed reduction and percutaneous pinning, under the guidance

of C-arm image intensifier.

General anesthesia was employed for all cases. The patient was positioned supine on the operating table with affected limb being placed on a side table or over the sterile draped C-arm image intensifier. Then, a step-wise closed manipulation was performed. Assessment of reduction was done under image intensifier by taking anteroposterior and lateral views; lateral view was taken by external rotation of shoulder. Maintenance of reduction was achieved by passing two crossed K-wires from both the medial and the lateral epicondyles (cross pinning) or by passing two K-wires from the lateral condyle in a divergent fashion (lateral pinning).

When crossed pinning was employed, the lateral pin was inserted first so that the medial pin can be placed with the elbow in less flexion to avoid ulnar nerve injury. Once the pins were in place, the elbow was extended and the adequacy of reduction was assessed with anteroposterior and lateral images. After leaving about 1 cm of the pins outside the skin, pins were bent and cut off and well-padded posterior above elbow slab was applied with elbow flexed to 90° or less as tolerated. Immediately in the post-operative period, the neurovascular status of the limb was assessed.

On 3rd/4th post-operative day slab was removed. The limb and wound and position of pins were inspected and a new well-fitted splint was reapplied. At 4 weeks, slab and pins were removed, and range of motion exercises were started in consultation with physiotherapist. Thereafter, the patient was regularly followed up at weekly interval of 2 weeks, 4 weeks, 6 weeks, monthly interval of 4 months, 6 months, 8 months, 10 months, and 12 months. At each review, patients were assessed clinically and radiologically. Finally, the functional outcome was assessed by Flynn's criteria (Table 1). The results were graded as excellent, good, fair or poor according to the range of motion and loss of carrying angle.

OBSERVATIONS AND RESULTS

The average age was 7.3 years (range 3-12 years) with a peak incidence in 5-8 years. Left side involvement was

Table 1: Flynn's criteria

Results	Rating	Cosmetic factor: Carrying angle loss (°)	Functional factor: Motion loss (°)
Satisfactory	Excellent	0-5	0-5
	Good	6-10	6-10
	Fair	11-15	11-15
Unsatisfactory	Poor	>15	>15

more as compared to right side. The most common mechanism of injury was fall on outstretched hand (96%). Postero-medial displacement (51.9%) of distal fragment was more common. The average hospital stay for patients was 4.6 days. The average follow-up duration for patients was of 10.5 months.

The average time for radiological union was 7 weeks. The difference of Baumann's angle between affected and unaffected final follow-up X-ray was due to improper reduction as well as secondary displacement. The maximum number of cases with loss of Baumann's angle of 5° was 40% in lateral pinning cases and 33% in cross pinning cases. The loss of Baumann's angle is due to secondary displacement with a maximum number of cases with loss of Baumann's angle of 2° was 46.7% in lateral pinning and 26.7% in cross pinning cases.

The average loss of carrying angle was 2.3° in lateral pinning group and 1.9° in cross pinning group which was statistically significant. The significantly higher change in carrying angle in lateral pinning group may be related to comparatively less stable construct with 2 lateral pins compared to 2 cross pins.

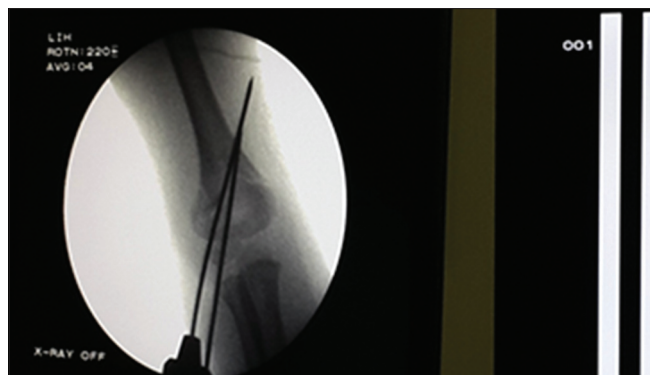


Figure 1: Lateral pinning

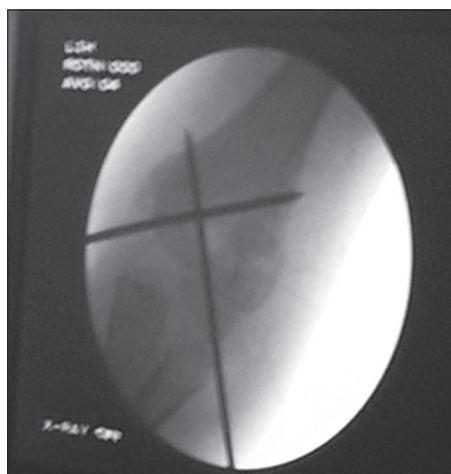


Figure 2: Cross pinning

The average loss of range of motion was 4.86° in cross pinning group and 4.93° in lateral pinning group which was not statistically significant. Functional outcome in terms of Flynn's criteria was excellent in 66.7% and good in 33.3% of cross pinning group and for lateral pinning group, excellent in 73.3% and good in 26.6% cases which was not statistically significant (0.69), but lateral pinning group definitely had higher number of excellent results (73.3%) as compared to cross pinning group (66.7%).

In terms of complications, pin tract infection was observed in 3 cases (10%). Temporary iatrogenic ulnar nerve injury was seen only in 1 case out of 13 and that too in the cross pinning group (Figures 1-4).

DISCUSSION

Supracondylar fractures of the humerus are the most common type of elbow fractures in children. It is a fracture that occurs at supracondylar area or metaphysis of distal humerus.⁵ Close reduction followed by two percutaneous Kirschner's wire fixation for supracondylar fracture of humerus in children offers simple, safe and affordable treatment option. Two configuration of placement of K-wires exists. One is lateral pinning and the other is cross pinning. Lots of controversies exist in orthopedics literature regarding the best modality of pin configuration.

Keeping these controversies in mind, we conducted a study comparing above two modalities of pin configuration in the management of displaced, closed supracondylar fracture of humerus in children. In this study, 30 children with type II and III supracondylar fractures of humerus who were treated with close reduction and percutaneous pinning (cross or lateral pinning) method were evaluated and compared according to fixed preset criteria.

In this study, the average age for supracondylar fracture of the humerus was 7.3 years (range 3-12 years) with a peak incidence in 5-8 years. The average incidence in other series, i.e., 7.0 in Ramsey and Griz,⁶ 6.4 in Nacht *et al.*⁷ The incidence in male children was 83% and 17% in females. The male predominance was also noted in series of Fowles and Kassab⁸ (89%) Nacht *et al.*⁷ (50%). Left sided supracondylar fracture of humerus has outnumbered right sided fracture in this study.

Other studies in which left side was commonly involved are Fowles and Kassab⁸ (57%), Nacht *et al.*⁷ (55%). The common mechanism of injury in our series was fall on an outstretched hand (96%) which is same as that in series by Mostafavi and Spero.⁹ and Bhuyan¹⁰ In our series, there was 51.9% incidence of posterior-medial and 48.1% incidence of posterior-lateral displacements. The other series also

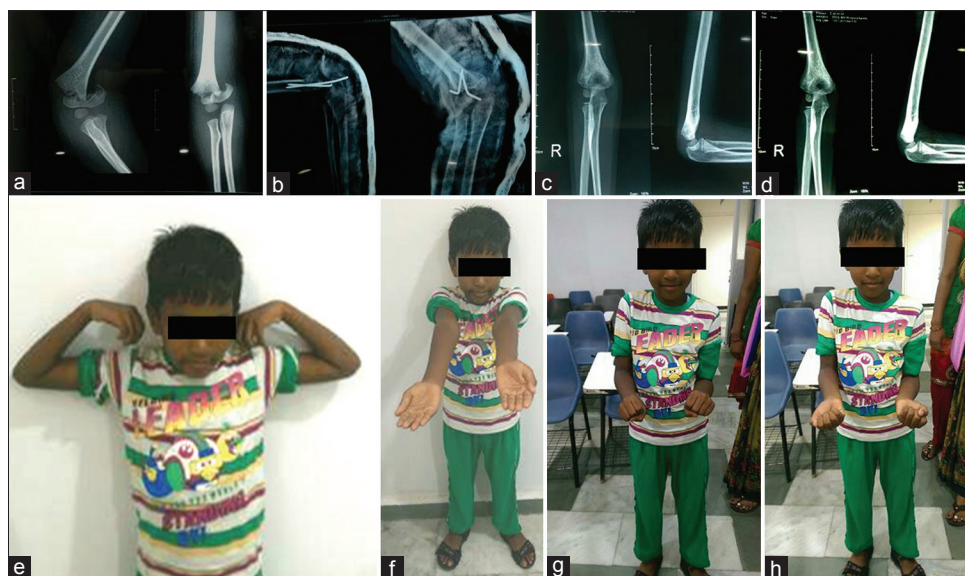

Figure 3: (a) Lateral pinning - pre-operative X-ray. (b) Immediate - post-operative X-ray. (c) At 4 weeks follow-up. (d) Final follow-up. (e) Clinical pictures (lateral pinning) - flexion. (f) Extension. (g) Pronation. (h) Supination

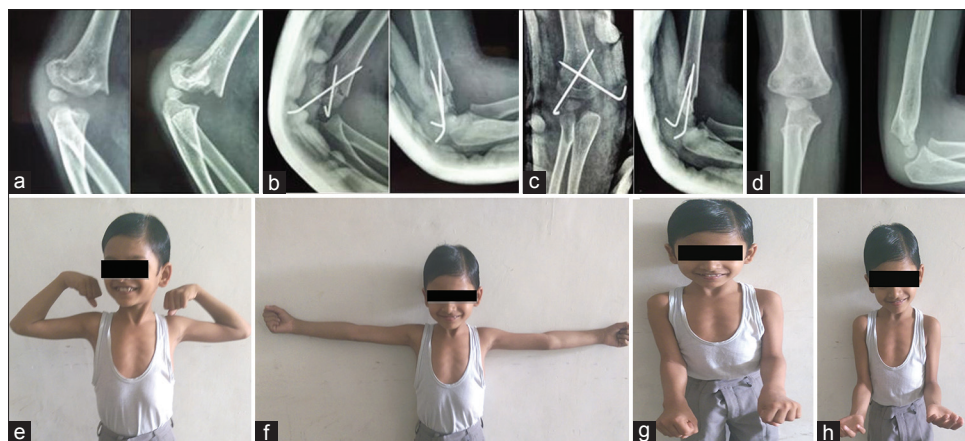


Figure 4: (a) Cross pinning - pre-operative X-ray. (b) Immediate - post-operative X-ray. (c) At 4 weeks follow-up. (d) Final follow-up. (e) Clinical pictures (cross pinning) - flexion. (f) Extension. (g) Pronation. (h) Supination

showed a higher rate of posterior-medial displacement: Aronson and Prager¹¹ (75%), Pirone *et al.*¹² (81%). The average hospital stay for a patient in our study was 4.6 days (range 2-6 days). The average hospital stay in other series were 3.4 days by Aronson and Prager,¹¹ 4.2 days by Nacht *et al.*⁷

The follow-up period for cases in our study ranged from 4 to 12 months with an average follow-up duration of 10.5 months. The average follow-up in other series were 8.93 in Foad *et al.*¹³ and 7.4 in Zamzam and Bakarman¹⁴ which are comparable and in series by Aronson and Prager.¹¹ was 17.2 months and Bhuyan¹⁰ was 4.6 years which are at high range and are not comparable.

In our study, the average radiological union was seen in 7 weeks ranging from 6 to 9 weeks. The average radiological union seen in other series were 7.6 weeks by Sudheendra

et al.,¹⁵ 6 weeks by Rijal and Pandey¹⁶ which are comparable to our study.

Functional outcome following the two types of pinning was evaluated according to Flynn's criteria. Sudheendra *et al.*¹⁵ in their study noted 82% excellent results and 18% good results in cross pinning case and 71% excellent results and 29% good results in lateral pinning case. Ariño *et al.*¹⁷ in their study noted 69.3% excellent, 15.3% good, 14.8% fair and 0.5% bad results with lateral pinning. Raffic *et al.*¹⁸ in their study found 72% excellent results and 28% good results with lateral pinning.

In our series, the functional outcome following cross pinning was excellent in 66.7% and good in 33.3% of cases, and lateral pinning showed 73.3% excellent and 26.6% good results with no poor results. The difference in functional outcome between the two groups was not

statistically significant (0.69). Pin tract infection occurred in 3 patients in our series (10%). In the series by Mostafavi and Spero,¹⁰ the incidence of pin tract infection was (5%) and (1%) in Pirone *et al.*¹² which was found less compared to our studies.

CONCLUSION

We conclude that although fixation of supracondylar humerus fracture of Gartland type II and III can be done by both ways either cross or lateral pinning but in view of ulnar nerve injury and extension lag which is more commonly associated with cross pinning, lateral pinning is comparatively safe and reliable for both types of supracondylar fractures of humerus in children. Hence, in our study, we found lateral pinning and cross pinning equally good in terms of safety and efficacy.

REFERENCES

1. Babal JC, Mehlman CT, Klein G. Nerve injuries associated with pediatric supracondylar humeral fractures: A meta-analysis. *J Pediatr Orthop* 2010;30:253-63.
2. Yadav UB, Singhal R, Tonk G, Aggarwal T, Verma AN. Crossed pin fixation in displaced supracondylar humerus fractures in children. *Indian J Orthop* 2004;38:166-9.
3. Mazda K, Boggione C, Fitoussi F, Penneçot GF. Systematic pinning of displaced extension-type supracondylar fractures of the humerus in children. A prospective study of 116 consecutive patients. *J Bone Joint Surg Br* 2001;83:888-93.
4. Sudheendra PR, Nazareth EL. A comparative study of outcome of percutaneous lateral and crossed pinning in the treatment of type III supracondylar fractures of humerus in children. *Sch J Appl Med Sci* 2014;23:959-62.
5. Attenborough CG. Remodeling of the humerus after supracondylar fractures in childhood. *J Bone Joint Surg Br* 1953;35:386-95.
6. Ramsey RH, Griz J. Immediate open reduction and internal fixation of severely displaced supracondylar fractures of the humerus in children. *Clin Orthop Relat Res* 1973;131-2.
7. Nacht JL, Ecker ML, Chung SM, Lotke PA, Das M. Supracondylar fractures of the humerus in children treated by closed reduction and percutaneous pinning. *Clin Orthop Relat Res* 1983;203-9.
8. Fowles JV, Kassab MT. Displaced supracondylar fractures of the elbow in children. A report on the fixation of extension and flexion fractures by two lateral percutaneous pins. *J Bone Joint Surg Br* 1974;56:490-500.
9. Mostafavi HR, Spero C. Crossed pin fixation of displaced supracondylar humerus fractures in children. *Clin Orthop Relat Res* 2000;56-61.
10. Bhuyan BK. Close reduction and percutaneous pinning in displaced supracondylar humerus fractures in children. *J Clin Orthop Trauma* 2012;3:89-93.
11. Aronson DD, Prager BI. Supracondylar fractures of the humerus in children. A modified technique for closed pinning. *Clin Orthop Relat Res* 1987;174-84.
12. Pirone AM, Graham HK, Krajchich JI. Management of displaced extension-type supracondylar fractures of the humerus in children. *J Bone Joint Surg Am* 1988;70:641-50.
13. Foead A, Penafort R, Saw A, Sengupta S. Comparison of two methods of percutaneous pin fixation in displaced supracondylar fractures of the humerus in children. *J Orthop Surg (Hong Kong)* 2004;12:76-82.
14. Zamzam MM, Bakarman KA. Treatment of displaced supracondylar humerus fractures among children: Cross pinning vs. Lateral pinning. *Int J Care Injured* 2008;10:1-9.
15. Rijal KP, Pandey BK. Supracondylar extension type III fractures of humerus in children: Percutaneous cross-pinning. *Kathmandu Univ Med J* 2006;4:465-9.
16. Ariño VL, Lluch EE, Ramirez AM, Ferrer J, Rodriguez L, Baixauli F. Percutaneous fixation of supracondylar fractures of the humerus in children. *J Bone Joint Surg Am* 1977;59:914-6.
17. Raffic M, Muhammed Fazil VV. Percutaneous K-wire fixation of supracondylar fractures in children. *J Evid Based Med Healthc* 2014;1:2349-562.

How to cite this article: Pathania VP, Dubey N, Gupta S. Treatment of Displaced Supracondylar Fracture of Humerus in Children by Lateral Entry Pinning versus Cross Pinning. *Int J Sci Stud* 2016;4(1):70-74.

Source of Support: Nil, **Conflict of Interest:** None declared.