

Evaluation of Graft Clarity Post-penetrating Keratoplasty

Nita Shanbhag¹, Priya Patil Cholera², N Sahana³, Lanin Chen⁴, T S Sujatha⁴

¹Professor and Head, Department of Ophthalmology, D. Y. Patil Medical College & Research Centre, Navi Mumbai, Maharashtra, India,

²Associate Professor, Department of Ophthalmology, D. Y. Patil Medical College & Research Centre, Navi Mumbai, Maharashtra, India,

³Senior Registrar, Department of Ophthalmology, D. Y. Patil Medical College & Research Centre, Navi Mumbai, Maharashtra, India,

⁴Post-graduate Student, Department of Ophthalmology, D. Y. Patil Medical College & Research Centre, Navi Mumbai, Maharashtra, India

Abstract

Introduction: Penetrating keratoplasty (PK) is the most commonly performed method of corneal transplantation. It is performed for central deep opacities in the visual axis, keratoconus, and disorders affecting the corneal endothelium resulting in cornea edema and loss of corneal clarity.

Materials and Methods: A prospective, clinical study was carried out at D. Y. Patil Medical College, Navi Mumbai, which included 50 patients who were planned to undergo a full thickness PK for various corneal pathologies. Pre-operative investigations and examinations were conducted and informed written consent was taken before the procedure. A full thickness PK was performed. Postoperative follow-up was done on day 1, day 7, day 28, monthly up to 3 months and 3 monthly up to 1 year. The post-operative visual acuity, clarity of the graft, and complications encountered were compared.

Results: Of the 50 patients included in the study, 23 patients underwent only PK surgery, 10 patients underwent the triple procedure (PK + cataract extraction + intraocular lens implantation), and 17 patients underwent PK with other procedures. On subsequent follow-up at day 28, there was a clear graft in 41 patients (82%). There was epithelial graft rejection in 1 patient (2%) of Steven Johnsons Syndrome. There was endothelial graft rejection in 2 patients (4%) of viral corneal ulcer and previous failed graft. There was glaucoma in 1 patient (2%). Severe astigmatism was noticed in 24 patients (48%). At the end of 1 year, we lost one patient to follow-up. Among the 49 patients, there was a clear graft in 35 patients (70%). There was glaucoma in 2 patient (4%). Severe astigmatism with a clear graft was noticed in 6 patients (12%). There was endothelial graft rejection in 10 patients (20%).

Conclusion: The short-term success and survival of corneal grafts in this part of the developing world are reasonably good. By taking care of the pre- and post-operative factors responsible for graft rejection, our study has validated the normally accepted facts regarding outcome and survival of corneal grafts. Age, gender, indications for surgery, corneal graft diameter, and intraoperative vitreous loss had no significant effects on the outcome.

Key words: Corneal opacity, Corneal transplantation, Corneal ulcer, Graft clarity, Graft rejection, Penetrating keratoplasty

INTRODUCTION

Penetrating keratoplasty (PK) is the most commonly performed method of corneal transplantation. It is performed for central deep opacities in the visual axis, keratoconus, and disorders affecting the corneal endothelium resulting in cornea edema and loss of corneal clarity. It scores over lamellar procedures due to their steep

learning curve and nonavailability of cut tissue at eye bank centers.¹⁻³

Visual loss in the cornea may be the result of edema, opacity, scarring or an irregular surface. PK can yield excellent visual acuity, but it is more prone to serious intraocular complications and a higher rate of rejection compared with the lamellar procedure. It is imperative to watch for signs of graft rejection or failure.⁴⁻¹⁰

MATERIALS AND METHODS

A prospective, clinical study was carried out at D. Y. Patil Medical College and Research Centre, Navi Mumbai, from January 2011 to December 2016.

Access this article online	
 www.ijss-sn.com	Month of Submission : 02-2017
	Month of Peer Review : 03-2017
	Month of Acceptance : 03-2017
	Month of Publishing : 04-2017

Corresponding Author: Dr. Lanin Chen, Department of Ophthalmology, D. Y. Patil Medical College & Research Centre, Nerul Sector 5, Navi Mumbai - 400 706, Maharashtra, India. Phone: +91-9819607663. E-mail: lanin_chen@hotmail.com

A total of 50 patients who were planned to undergo a full thickness PK for various corneal pathologies were included in the study.

Pre-operative evaluation was done which included the following:

1. Detailed history
2. Visual acuity on the Snellen's chart. Perception of light and projection of rays (PLPR) were accurately documented
3. Objective refraction including retinoscopy and automated refraction
4. Automated keratometry
5. Corneal topography by Keratron scout topographer
6. Ultrasound B-scan to rule out fundus pathology
7. Intraocular lens (IOL) power calculation wherever indicated
8. Applanation tonometry by Goldmann's tonometer or tonopen
9. Schirmer's test
10. Corneal sensitivity to rule out the previous herpes infection.

Inclusion Criteria

1. Pseudophakic bullous keratopathy
2. Macular/leucomatous corneal opacity involving the visual axis
3. Corneal dystrophies
4. Corneal degenerations
5. Epithelial ingrowth/fibrovascular downgrowth
6. Impending corneal perforation/descemetocoele/corneal perforation
7. Nonhealing corneal ulcer.

Exclusion Criteria

1. Nebular corneal opacity
2. Corneal opacity not involving the visual axis
3. Unfit for surgery due to systemic illness or debilitating diseases
4. Unwilling for consent/patient not compliant/unwilling for follow-up.

In situ, corneoscleral rim excision was done for all eye donations, and donor tissue was collected in M.K. medium with all aseptic precautions. Tissue evaluation was done by slit lamp observation and specular microscopy. Donor cornea of good endothelial cell count >2500 cells/cu.mm was obtained from the eye bank.

A full thickness PK under local/general anesthesia was done by the same surgeon on a quiet eye after a well-informed written consent.

Surgical Technique

Most surgeries were done under peribulbar anesthesia with 2 patients (under the age of 18 years) requiring general anesthesia.

Lid stitches were taken with silk suture, and the cornea was exposed. Eye speculum was avoided to prevent inadvertent pressure on the globe. Flieringa ring was used where indicated.

The donor cornea was trephined using manual corneal trephine of size 7.5, 8.0, 8.5, or 9.0 depending on the size of the corneal opacity and underlying corneal pathology.

The recipient cornea was trephined using manual corneal trephine of a size 0.5 mm smaller than the corneal trephine used to trephine the donor cornea. This discrepancy was to have a well formed anterior chamber (AC) to avoid peripheral anterior synechiae (PAS) in the angle leading to secondary glaucoma, inflammation, and vascularization.

The recipient diseased tissue was separated using corneoscleral scissors after trephination and initial entry with the trephine. A complete penetration of trephine was avoided to prevent injury to the iris and underlying lens.

The iris and lens (clear lens or IOL) were protected with the help of viscoelastic substance (VES) while cutting with scissor.

In cases of cataract, it was treated by extracapsular cataract extraction/posterior chamber IOL polymethylmethacrylate rigid implantation open-sky technique.

The donor cornea was placed on the defect immediately after removing the diseased recipient cornea, and interrupted sutures were taken with 10-0 monofilament nylon at 6, 12, 3, and 9 O'clock positions to prevent a scleral collapse with subsequent vitreous loss.

Thereafter, the entire graft was secured with 16 interrupted sutures with 10-0 interrupted monofilament nylon.

A patent peripheral button-hole iridectomy was done to prevent a postoperative pupillary block.

Before the last suture, an AC wash was given to remove the VES, and the angle was swept with an iris repositor to break any PAS.

AC was formed with an air bubble, and a well-formed AC depth was ensured.

Keratoscopic end-point following suturing was observed to minimize astigmatism.

A topical antibiotic eye drop, corticosteroid eye drop, and eye ointment atropine were instilled, and the eye was padded.

Postoperatively, the patients were started on the following:

1. Topical antibiotic drops - eye drop moxifloxacin 0.5% 4 times/day
2. Topical steroid drops - eye drop prednisolone acetate 1% 6 times/day which was tapered after 4 weeks with the introduction of cycloimmune 0.1%/tacrolimus 0.03% twice/day
3. Topical lubricant drops 4 times/day
4. Eye ointment atropine 1% twice/day
5. Topical antiglaucoma drops – B-blocker – eye drop timolol 0.5% twice/day
6. Oral broad spectrum antibiotic – ciprofloxacin 500 mg twice/day \times 5 days
7. Oral nonsteroidal anti-inflammatory drug – diclofenac sodium 50 mg twice/day \times 3 days
8. Oral corticosteroid – prednisolone 1 mg/kg \times 4 weeks and tapered to a maintenance dose of 10 mg over 6-8 weeks.

Additional treatment was added depending on the corneal pathology. This included,

- Antibacterial treatment with moxifloxacin 0.5% 6 times/day with Tobramycin 0.3% 6 times/day
- Topical acyclovir 3% eye ointment 5 times/day and oral acyclovir 800 mg 5 times/day \times 7 days tapered to 400 mg twice/day for 6 months, for cases of corneal ulcer of viral origin or patients with non-healing corneal ulcer with absent corneal sensations
- Topical amphotericin B eye drops 0.15% every 1 hourly for corneal ulcers of fungal origin.

A judicious judgment of tapering antimicrobial and introducing topical steroid to make a therapeutic PK into optical one if possible without reactivating infection in the graft.

In case of raised intraocular pressure (IOP), a trabeculectomy with mitomycin C was done before PK to avoid post-PK glaucoma. However, few cases underwent trabeculectomy with mitomycin C post-PK surgery due to raised IOP.

Combined procedures with cataract extraction, IOL implantation, IOL explantation, etc., were also included in the study.

Follow-up was done on day 1, day 7, and day 28. From then on the patient was evaluated every 3 months up to 1 year.

The following was examined at every follow-up:

1. Objective refraction
2. Best-corrected visual acuity
3. Keratometry
4. Corneal topography
5. Slit lamp examination
6. Intraocular pressure
7. Schirmer's test/tear film break-up time.

The graft clarity was evaluated based on slit lamp examination looking for the following:

1. Fresh keratic precipitates (KP)
2. Corneal edema
3. Descemet's folds
4. Pigments/blood stain on endothelium
5. Epithelial line
6. Subepithelial haze – Krachmer spots
7. Stromal haze
8. Linear stromal opacification – Khodadoust line.

Graft clarity was graded as Grade 4 if grafts were optically clear with excellent view of iris details, Grade 2-3 (borderline) if there was moderate to significant corneal haze with or without good view of iris details, and Grade 1-0 (failed) for opaque grafts with poor view of iris and anterior segment details.¹¹ Good visual improvement was defined as postoperative vision improvement \geq two lines on Snellen's compared with pre-operative vision, moderate as one line improvement, and No improvement if vision remained same or worsened.

Graft failure was defined as irreversible loss of optical clarity with the date of onset taken when the patient presented to cornea clinic with signs of irreversible rejection (for 3 months or more) or with failed graft.

RESULTS

The mean age of the patient was 48 years, with the oldest patient as 87 years and youngest patient as nine years. Of the 50 patients, 32 were female and 18 were male.

The most common indications (Graph 1) for surgery were corneal scarring (40%), bullous keratopathy (28%), non-healing corneal ulcer (16%), and others (16%) (Figures 1 and 2).

Of the 50 patients included in the study, 23 patients (46%) underwent only PK surgery, 10 patients (20%) underwent triple procedure (PK + cataract extraction + IOL implantation), and 6 patients (12%) underwent PK with other procedures such as IOL exchange, anterior vitrectomy, or secondary IOL implantation (Table 1).

Table 1: Procedure

Procedure	Number (%)
PK	23 (46)
PK+cataract extraction+IOL implantation	10 (20)
PK followed by cataract extraction+IOL implantation	3 (6)
Trabeculectomy followed by PK	6 (12)
PK followed by trabeculectomy	2 (4)
PK+other procedures	6 (12)

PK: Penetrating keratoplasty, IOL: Intraocular lens

Pre-operative visual acuity was worse than CF 2 m in all patients (100%), with only 8 patients (16%) having a visual acuity better than PLPR.

There was a vitreous loss in 1 patient during the PK procedure. A retropupillary iris claw was implanted in this patient after a neat anterior vitrectomy. Iatrogenic iris bleeding was seen in 3 patients. Positive intraocular pressure was experienced in 1 patient intra-operatively due to scleral prolapse. An immediate graft placement with 4 anchoring sutures averted a vitreous loss. May be a Flerringa ring could have avoided this.

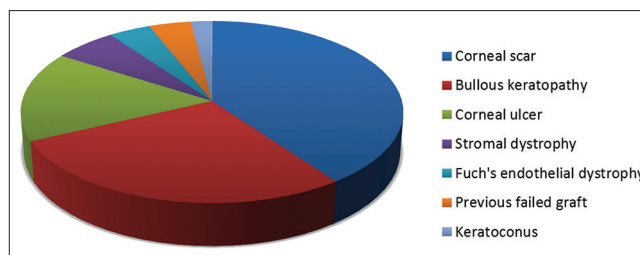
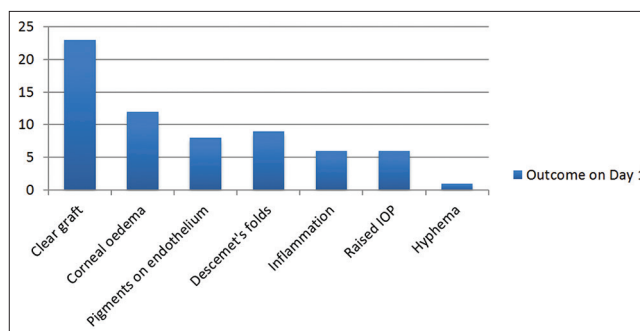
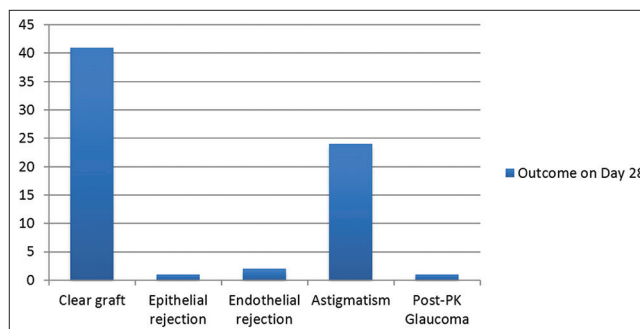
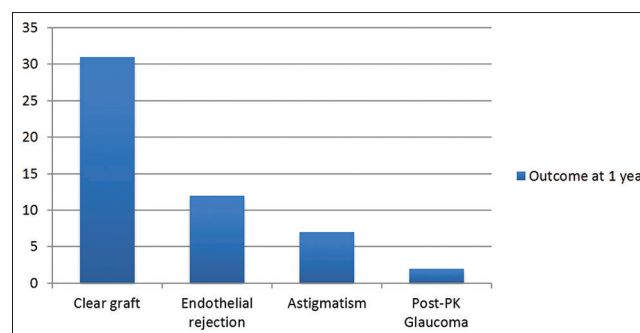
On post-operative day 1 (Graph 2), the graft remained clear in 23 patients (46%), corneal edema in 12 patients (24%), pigments on the endothelium in 8 patients (16%), hyphema in 1 patient (2%), and intraocular inflammation and raised IOP in 6 patients (12%) (Figure 3).

On subsequent follow-up at day 28 (Graph 3), there was a clear graft in 41 patients (82%). There was epithelial graft rejection in 1 patient (2%) of Steven–Johnsons syndrome. There was endothelial graft rejection in 2 patients (4%) of viral corneal ulcer and previous failed graft. There was glaucoma in 1 patient (2%). Severe astigmatism was noticed in 24 patients (48%).

Overall, grafts remained clear at follow-up visits. Glaucoma or postoperative glaucoma had no statistically significant effects on graft outcome as all patients susceptible to glaucoma underwent trabeculectomy with mitomycin C, and all patients were started on post-operative anti-glaucoma eye drops.

At the end of 1 year (Graph 4), one patient was lost to follow-up. Among the 49 patients, there was a clear graft in 35 patients (70%). There was glaucoma in 2 patients (4%). Severe astigmatism with a clear graft was noticed in 6 patients (12%). There was endothelial graft rejection in 10 patients (20%) (Figure 4).

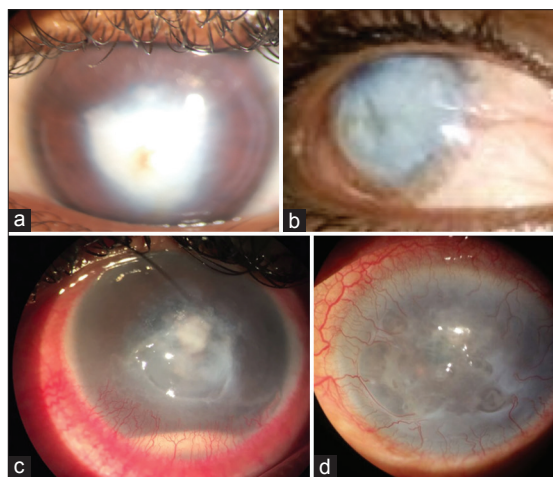
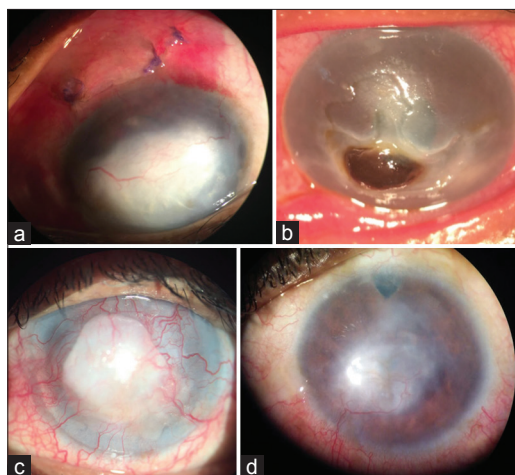
The post-operative visual acuity at the end of a 1-year follow-up was between 6/18 to 6/60 in 38% followed by better than 6/18 in 36% on the Snellen's chart (Table 2).

**Graph 1: Indications for surgery****Graph 2: Outcome on day 1****Graph 3: Outcome on day 28****Graph 4: Outcome at 1 year**

There is a variety of reasons for this. In our series, only one-half of our cases were good prognosis cases such as corneal dystrophies, keratoconus, etc. Few of our patients are high-risk cases, which are at increased immunological risk of graft rejection due to factors such as vascularized corneas, previous graft failure. Second, most of our corneal collection is through voluntary eye donations by home calls,

Table 2: Distribution of pre-operative visual acuity on Snellen's chart

Visual acuity on Snellen's chart	Number of patients (%)
>6/18	12 (24)
6/18-6/60	19 (38)
CF 5 m to CF 2 m	12 (24)
<CF 2 m	7 (14)

**Figure 1: Pre-operative indications****Figure 2: Pre-operative indications**

our donors being in the age group 60 years and above, with average quality of donor tissue and comparatively lower endothelial cell counts.^{12,13} Hospital Cornea Retrieval Programs more often give a higher yield and younger donor tissue. In addition, majority of our patients are illiterate with poor socioeconomic status. Hence, post-operative care and follow-up were a major challenge.

DISCUSSION

Corneal transplant surgery is the most commonly performed allograft and is said to be the most successful

solid organ transplants, with short-term survival rates (1 year) as high as 90%.¹⁴ However, the long-term success rate diminishes to 73% at 5 years, 60% at 10 years, and 46% at 15 years as reported in ACGR.¹⁵ Reports from various graft registries of the developed countries show the indications for surgery being mainly keratoconus, other corneal dystrophies, followed by aphakic and pseudophakic bullous keratopathies.^{2,3} However, the scenario in developing world is quite different. First, the patient profile and indications for surgery differ. According to a study done in Nepal, corneal scars following infectious keratitis, adherent leukomas, and corneal perforations were the major indications for surgery.¹⁶ A study done in India to analyze survival rate of corneal transplants in a large series shows survival rates at 1, 2, and 5 years for first-time grafts to be 79.6%, 68.7%, and 46.5%, respectively.¹⁷ They are different from the western studies essentially due to differences in patient profile, different indications for surgery, differences in methods of storage of corneas, and socioeconomic factors affecting health-care provision.

Graft failure is defined as irreversible loss of central graft clarity, irrespective of the visual acuity. Graft rejection was defined as presence of one or more of the following signs: Mild if there were 1-5 KPs, sub-epithelial infiltrates increased corneal thickness without increase in aqueous cells. Severe rejection if >5 KPs, inflammatory cells in the stroma (not due to infection), endothelial rejection line or increased thickness with aqueous cells.

Factors determining the clarity of graft can be categorized as:

- Poor endothelial count in the donor graft
- Indication of the graft
 - Therapeutic
 - Staining of the cornea
 - Herpes infection
 - Fibrovascular ingrowth
- Recipient corneal vascularization >180°
- Uncontrolled glaucoma
- Inflammation
- Cataract needing a combined procedure
- Ocular surface disorders
- Decreased corneal sensations
- Debilitating diseases
 - Uncontrolled diabetes mellitus
 - Tuberculosis
 - HIV
 - Collagen vascular disorders
- Vitreous loss with vitreous in AC.

The study was done in a tertiary care center wherein an eye bank exists. The tissue was collected with good

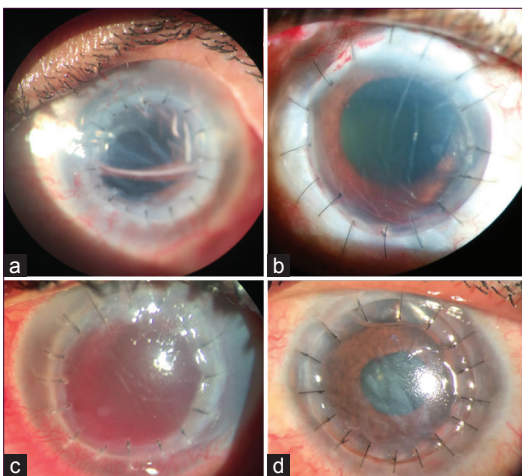


Figure 3: Diffuse slit lamp examination photograph on Day 1

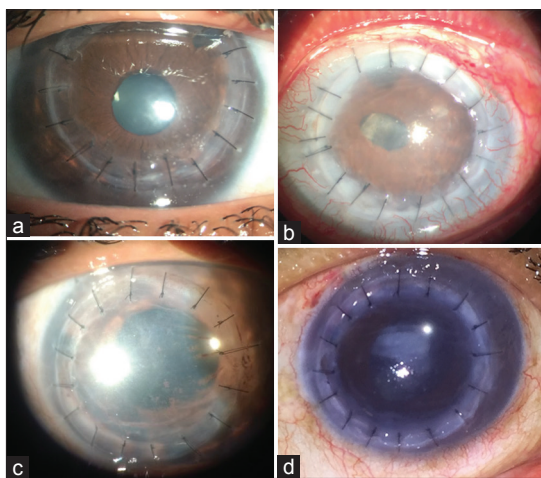


Figure 4: Diffuse slit lamp examination photograph at 1 year

endothelial cell count. The confounding factors such as dry eyes, glaucoma, inflammation, and vascularization were controlled rigidly to avoid any mishap. The steroids were tapered and immunosuppressants introduced to prevent steroid-related complications. A competent surgeon did the PK. Most of the factors contributing to graft failure were controlled. The factor contributing to graft rejection seemed to be non-compliance on the patient part of frequent follow-up and to putting so many drops in the eye over a long period. The second one seemed to be reactivation of herpes infection in the eye. The epithelial rejection was seen in the switch over from steroids to immunosuppressants. However, it was well controlled with reintroduction of steroids. Hence, the dictum to introduce both steroids as well as immunosuppressants and then slowly taper the steroids. Astigmatism was seen in all the patients. To reduce this, we introduced keratoscopic end-point during surgery. At 3 months removal of the steep suture if astigmatism $>4D$ and to continue this every 2 weeks till we got the astigmatism below $3D$. With this, the BCVA in a clear graft was almost always better than 6/12.

Suture infiltrate was avoided by removing loose suture at follow-up. If present then, they were treated with dilute betadine drops in addition to the regular treatment. With this protocol, we managed a graft survival rate 75% of over a period of 1 year.

There are several limitations to our study. We did not assess in details the effect of several donor tissue-related variables such as death to *in situ* excision time, preservation time, age of the donor, human leukocyte antigen matching, or ABO grouping of donor-recipient.

CONCLUSION

The short-term success and survival of corneal grafts in this part of the developing world are reasonably good. By taking care of the pre-operative and post-operative factors responsible for graft rejection, our study has validated the normally accepted facts regarding outcome and survival of corneal grafts. Age, gender, indications for surgery, corneal graft diameter, and intraoperative vitreous loss had no statistically significant effects on the PK outcome. Further improvements in eye banking facilities, adopting hospital cornea retrieval program to procure young donor corneas, and better patient counseling to ensure good follow-up are needed to improve long-term survival of corneal grafts.

REFERENCES

- McDonnell PJ, Enger C, Stark WJ, Stulting RD. Corneal thickness changes after high-risk penetrating keratoplasty. Collaborative corneal transplantation study group. *Arch Ophthalmol* 1993;111:1374-81.
- Cosar CB, Sridhar MS, Cohen EJ, Held EL, Alvim Pde T, Rapuano CJ, *et al.* Indications for penetrating keratoplasty and associated procedures, 1996-2000. *Cornea* 2002;21:148-51.
- Coster DJ, Williams KA. The impact of corneal allograft rejection on the long-term outcome of corneal transplantation. *Am J Ophthalmol* 2005;140:1112-22.
- Halberstadt M, Machens M, Gahlenbek KA, Böhne M, Garweg JG. The outcome of corneal grafting in patients with stromal keratitis of herpetic and non-herpetic origin. *Br J Ophthalmol* 2002;86:646-52.
- Ramamurthy S, Reddy JC, Vaddavalli PK, Ali MH, Garg P. Outcomes of Repeat Keratoplasty for Failed Therapeutic Keratoplasty. *Am J Ophthalmol* 2016;162:83-88.e2.
- Joshi SA, Jagdale SS, More PD, Deshpande M. Outcome of optical penetrating keratoplasties at a tertiary care eye institute in Western India. *Indian J Ophthalmol* 2012;60:15-21.
- Shi WY, Wang X, Xie LX. Clinical study on the endothelial immune rejection after penetrating keratoplasty. *Zhonghua Yan Ke Za Zhi* 2005;41:145-9.
- Abudou M, Wu T, Evans JR, Chen X. Immunosuppressants for the prophylaxis of corneal graft rejection after penetrating keratoplasty. *Cochrane Database Syst Rev* 2015;CD007603.
- Oto T, Ishiyama S, Hayashidera T, Mori Y, Nejima R, Miyata K, *et al.* Twelve-year follow-up of penetrating keratoplasty. *Jpn J Ophthalmol* 2016;61:131-6.
- Keane MC, Galettis RA, Mills RA, Coster DJ, Williams KA; for Contributors to the Australian Corneal Graft Registry. A comparison of endothelial and penetrating keratoplasty outcomes following failed penetrating keratoplasty: A registry study. *Br J Ophthalmol* 2016. pii: Bjophthalmol-2015-307792.

11. Sihota R, Sharma N, Panda A, Aggarwal HC, Singh R. Post-penetrating keratoplasty glaucoma: Risk factors, management and visual outcome. *Aust N Z J Ophthalmol* 1998;26:305-9.
12. Tan DT, Janardhanan P, Zhou H, Chan YH, Htoon HM, Ang LP, *et al.* Penetrating keratoplasty in Asian eyes: The Singapore corneal transplant study. *Ophthalmology* 2008;115:975-982.e1.
13. Bourne WM, Nelson LR, Hodge DO. Central corneal endothelial cell changes over a ten-year period. *Invest Ophthalmol Vis Sci* 1997;38:779-82.
14. Williams KA, Muehlberg SM, Lewis RF, Coster DJ. How successful is corneal transplantation? A report from the Australian corneal graft register. *Eye (Lond)* 1995;9:219-27.
15. Williams KA, Lowe M, Bartlett C, Kelly TL, Coster DJ; All contributors. Risk factors for human corneal graft failure within the Australian corneal graft registry. *Transplantation* 2008;86:1720-4.
16. Tabin GC, Gurung R, Paudyal G, Reddy HS, Hobbs CL, Wiedman MS, *et al.* Penetrating keratoplasty in Nepal. *Cornea* 2004;23:589-96.
17. Dandona L, Naduvilath TJ, Janarthanan M, Ragu K, Rao GN. Survival analysis and visual outcome in a large series of corneal transplants in India. *Br J Ophthalmol* 1997;81:726-31.

How to cite this article: Shanbhag N, Cholera PP, Sahana N, Chen L, Sujatha TS. Evaluation of Graft Clarity Post-Penetrating Keratoplasty. *Int J Sci Stud* 2017;5(1):90-96.

Source of Support: Nil, **Conflict of Interest:** None declared.