

# Comparison of Submucosal Diathermy and Partial Inferior Turbinectomy

M S Vishnu<sup>1</sup>, K B Rajamma<sup>2</sup>

<sup>1</sup>Resident, Department of ENT, Sree Gokulam Medical College & Research Foundation, Trivandrum, Kerala, India, <sup>2</sup>Professor and Head, Department of ENT, Sree Gokulam Medical College & Research Foundation, Trivandrum, Kerala, India

## Abstract

**Introduction:** Nasal obstruction is one among the most common presenting complaints of patients. The most common etiology for nasal obstruction is hypertrophy of the inferior turbinates due to allergic rhinitis or vasomotor rhinitis. The hypertrophy is almost always due to dilatation of the venous sinusoids resulting in swelling of the submucosal layer.

**Objectives:** To compare the results between submucosal diathermy (SMD) and partial inferior turbinectomy (PIT) in terms of post-operative bleeding, nasal crust formation, vestibular skin burn, pain, synechiae formation, and atrophic rhinitis.

**Materials and Methods:** A prospective observational study involving 60 patients with inferior turbinate hypertrophy was done at Sree Gokulam Medical College, TVM from January 2014 to June 2015. Patients were randomly divided into two groups; Group A, underwent SMD and Group B underwent PIT. Post-operative follow-up done at day 1, 1 week, 1 month and 3 months.

**Results:** Occurrence of post-operative reactionary hemorrhage on day 1 was 43.3% in PIT, whereas it was only 10% in SMD. Nasal crust formation was 6.7% in PIT at the end of 3 months while none who underwent SMD had crust formation at the end of 3 months. Vestibular skin burn was observed in 3.3% of SMD patients. 6.7% had nasal pain following PIT while none of the SMD patients had the same. Remote complications such as synechiae and atrophic rhinitis were not reported in either PIT or SMD during the assessment time period.

**Conclusion:** SMD is relatively safe and less invasive than PIT but its effectiveness compared to PIT is short lived. In the long run, PIT was found to be more effective.

**Key words:** Inferior turbinate hypertrophy, Partial inferior turbinectomy, Submucosal diathermy

## INTRODUCTION

One of the common presenting symptoms to ENT Department is a nasal obstruction, which can be due to deviated septum, nasal polyposis, hypertrophied inferior turbinate, vasomotor or perennial rhinitis. Inferior turbinate hypertrophy is a common entity which sometimes do not respond to medical treatment and requires surgery. A minimum of 13 different surgical techniques have been introduced which include

turbinectomy, laser cautery, silver nitrate cautery, electrocautery, submucosal resection with or without lateral displacement, cryotherapy.<sup>1</sup> There is no general agreement about the best modality of treatment. partial inferior turbinectomy (PIT) and submucosal diathermy (SMD) are two popular methods among the various techniques of inferior turbinate reduction. This study aims to compare the results between SMD and PIT in terms of post-operative bleeding, nasal crust formation, vestibular skin burn, pain, synechiae formation, and atrophic rhinitis.

## MATERIALS AND METHODS

A prospective observational study of 60 patients, who attended the ENT OPD with complaints of nasal obstruction due to inferior turbinate hypertrophy was

Access this article online



www.ijss-sn.com

Month of Submission : 02-2016  
 Month of Peer Review : 03-2016  
 Month of Acceptance : 03-2016  
 Month of Publishing : 04-2016

**Corresponding Author:** M S Vishnu, Department of ENT, Sree Gokulam Medical College & Research Foundation, Trivandrum, Kerala, India.  
 E-mail: dr.msvishnu@gmail.com

done, in the Department of ENT Sree Gokulam Medical College from January 2014 to June 2015. The patients were divided into two Groups A and B of 30 each using table of randomization. Group A patients SMD and Group B underwent PIT.

A thorough history and detailed examination of ear nose and throat were conducted by anterior rhinoscopy, diagnostic nasal endoscopy, and radiologically by sinus X-ray. Routine pre-operative investigations were done on every patient.

Size of inferior turbinate was classified into three grades:  
Grade 1: Normal size inferior turbinate, atrophic without any nasal obstruction  
Grade 2: Moderate sized inferior turbinate, touching the septum with nasal obstruction, not responding to local decongestant  
Grade 3: Large mulberry turbinate touching the septum with nasal obstruction, not responding to local decongestant.

The procedures were done for both Grades 2 and 3 patients.

Both procedures were done under general anesthesia, with the patient in reclining position and head end of the table raised. Nasal cavity was packed with two cotton pledgets soaked in oxymetazoline and adrenaline.

For SMD, after decongestion the diathermy needle was inserted into the anterior end of inferior turbinate, which was advanced submucosally till the posterior end of the inferior turbinate was reached. The needle was then withdrawn slightly and a current of 50 joules was applied in a triangular fashion at 3 points (superior, medial and inferior).

For PIT, the inferior turbinate was infiltrated with 2% xylocaine + adrenaline up to the posterior end. Using turbinectomy scissors, the medial one-third of the anterior end of the inferior turbinate was resected without any trauma to the bony inferior concha.

Following the procedure, anterior nasal packing was done with antibiotic ointment (soframycin + metrogyl). All patients were given parenteral antibiotics, analgesics, and nasal drops for 7-10 days postoperatively.

Post-operative follow-up was done on day 1 for assessing reactionary hemorrhage. Nasal crust formation was evaluated at 1 week, 1 month and 3 months postoperatively. Vestibular skin burn was assessed on day 1. Assessment of nasal pain was done on post-operative day 1 and day 7. Synechiae formation and atrophic rhinitis were evaluated at 1 month and 3 months.

## RESULTS

Out of the 60 patients recruited for the study, in Group A 12 were males and 18 were females. In Group B, 20 were males and 10 females, with mean age of 27.2 in Group A and 27.8 in Group B.

On the first post-operative day, reactionary hemorrhage was observed in 13 (43.3%) patients who underwent PIT, whereas only 3 (10%) patients who underwent SMD had the same (Figure 1).

Nasal crust formation evaluated at the end of the 1<sup>st</sup> week demonstrated crust formation in 46.7% of patients who underwent PIT and only in 16.7% of patients who underwent SMD. Follow-up at the end of 1 month revealed crust formation in 26.7% of PIT patients and only in 6.7% of SMD patients. Follow-up at the end of the 3<sup>rd</sup> month demonstrated crust formation in 6.7% of PIT patients whereas none of the patients who underwent SMD had crust formation (Figure 2).

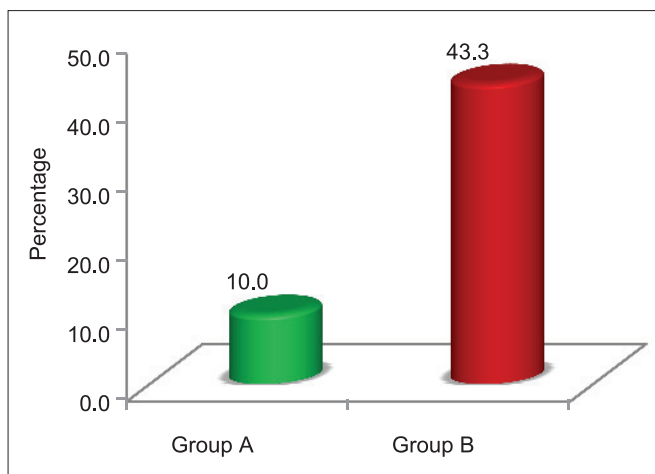
Vestibular skin burn assessed on post-operative day 1 was observed only in 1 (3.3%) patient who underwent SMD. As cautery was not used in PIT vestibular skin burn was not observed in Group B (Figure 3).

The nasal pain was present in 11 (36.7%) patients who underwent PIT and in 4 (13.3%) of patients who underwent SMD on day 1. At the end of the 1<sup>st</sup> week, 6.7% of PIT patients had mild nasal pain, whereas none of the patients who underwent SMD had the same (Figure 4).

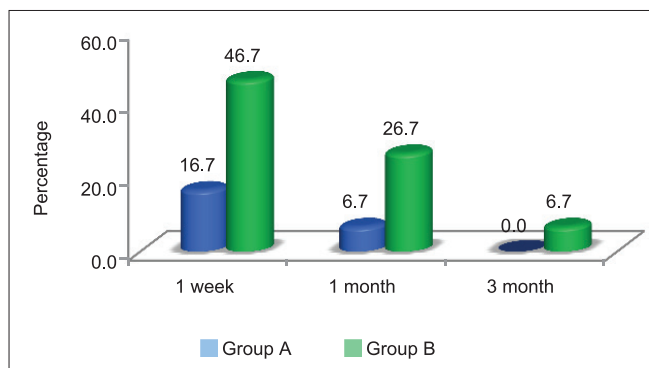
Synechiae formation and atrophic rhinitis were evaluated at 1 month and 3 months postoperatively and none of the patients in both groups had the same.

## DISCUSSION

Nasal obstruction is one among the most common presenting complaints of patients attending the ENT OPD. One of the most common etiology for nasal obstruction is hypertrophy of the inferior turbinates due to allergic rhinitis or vasomotor rhinitis.<sup>2</sup> The hypertrophy is almost always due to dilatation of the venous sinusoids resulting in swelling of the submucosal layer. The majority of the patients responds to antihistamines or local decongestants. Occasionally submucous fibrosis may render the turbinates incapable of decongestion and in such cases surgical management becomes necessary.<sup>3</sup> Even though multiple treatment options are available, there is considerable controversy over the merits of the various techniques.



**Figure 1: Comparison of reactionary hemorrhage (day 1) between both groups**

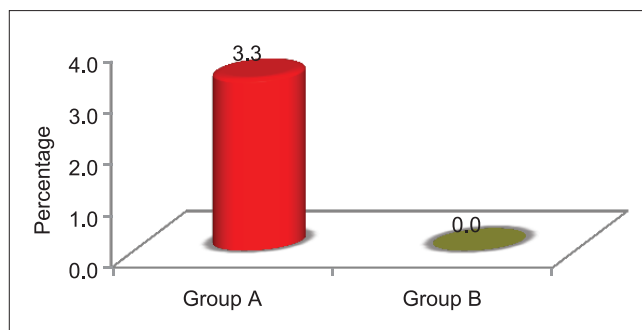


**Figure 2: Comparison of nasal crust formation of between two groups**

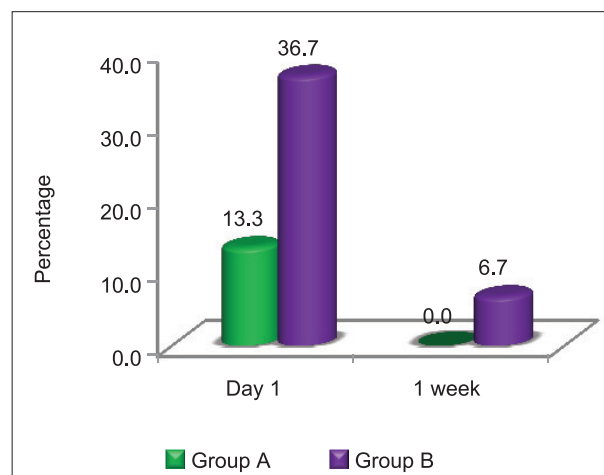
This study is done to evaluate and analyze the impact of partial turbinectomy and SMD on nasal obstruction and to compare the results of either procedures in respect of safety and efficacy. Anterior rhinoscopy and radiological investigations (X-ray PNS) were done. Rhinomanometry was not done due to lack of availability in our institute.

In a study conducted by Thahir *et al.*, bleeding was seen in patients who underwent PIT and anterior nasal packing was required for 48 h. In a study conducted by Imad *et al.*,<sup>4</sup> in 2010 it was found that 40% of patients who underwent PIT had moderate bleeding while only 3% who underwent SMD had minimal bleeding. The studies done by Al-Baldawi<sup>5</sup> revealed that the incidence of reactionary hemorrhage was 12.5% in patients who underwent PIT, whereas none of the patients who underwent SMD had a reactionary hemorrhage. In our study, the reactionary hemorrhage was evaluated on post-operative day 1 which was 43.3% in patients who underwent PIT. Only 10% of the patients who underwent SMD had developed reactionary hemorrhage.

The study conducted by Imad *et al.*,<sup>4</sup> in 2010 revealed that 20% of patients who underwent PIT had crusting at the



**Figure 3: Incidence of vestibular skin burn (post-operative day 1)**



**Figure 4: Comparison of nasal pain of both groups**

end of 2 weeks while none of the patients who underwent SMD had crusting. Incidence of crusting was also reported by Nousheen<sup>6</sup> in her study conducted in 2006. Maskel *et al.*, conducted a study in 2007 and reported that 29.5% of patients who underwent laser turbinectomy had crusting within first 2 weeks.<sup>7</sup> About 5% of those who underwent PIT had developed nasal crust formation and none of the patients who underwent SMD had developed nasal crust formation according to the study by Al-Baldawi.<sup>5</sup> In this study, the incidence of nasal crust formation was assessed at various time intervals in both groups. About 46.7% had developed nasal crust at the end of 1 week in patients who underwent PIT which was further reduced to 26.7% after 1 month. By the end of 3 months, only 6.7% of patients who underwent PIT had nasal crust formation. In those who underwent SMD, the incidence of nasal crust formation was 16.7% after 1 week which further reduced to 6.7% after 1 month. At the end of 3 months, none of the patients who underwent SMD had nasal crust formation.

According to study conducted by Al-Baldawi,<sup>5</sup> 2009 the incidence of vestibular skin burn in patients who underwent PIT was nil whereas those who underwent SMD 2.5% had skin burn. In our study the incidence of

vestibular skin burn was evaluated on post-operative day 1. None of the patients who underwent PIT had vestibular skin burn as no cautery was used, whereas 3.3% of patients who underwent SMD had developed vestibular skin burn which was mild.

According to study by Maskel *et al.*,<sup>7</sup> less pain was reported with laser inferior turbinectomy. In study conducted by Imad *et al.*,<sup>4</sup> in 2010, in Peshawar 32% of patient who underwent PIT had moderate pain whereas 44% of patients who underwent SMD had moderate pain. In a study conducted in Iraq by Al-Baldawi,<sup>5</sup> the occurrence of nasal pain and headache was 12.5% in those who underwent PIT and only 5% of patients who underwent SMD had developed a headache. According to study by Gomma *et al.*, incidence of nasal pain was less in SMD patients during 2 week and 1 month follow up, compared to patients who underwent PIT.<sup>8</sup> Our study also assessed the incidence of headache and nasal pain in both groups. At post-operative day 1 about 36.7% of patients who underwent PIT had headache and nasal pain which was further reduced to 6.7% at the end of 1 week. The incidence of headache and nasal pain in patients who underwent SMD was 13.3% at post-operative day 1 and none of the patients had headache and nasal pain at the end of 1 week.

Nasal synechiae/adhesions were not observed in both groups of patients who underwent PIT or SMD in a study conducted by Al-Baldawi<sup>5</sup> in 2009. The occurrence of synechiae formation was assessed in our study at 1 month and 3 months postoperatively. In those patients who underwent PIT at the end of 1 month and 3 months none had synechiae formation. Similar results also were observed in patients who underwent SMD.

Study done by Al-Baldawi,<sup>5</sup> 2009 revealed that none of the patients had atrophic rhinitis irrespective of the whether they underwent PIT/SMD. In our study, we also assessed the incidence of atrophic rhinitis in both groups at time intervals of 1 month and 3 months. Neither the patients

who underwent PIT nor those who underwent SMD had developed atrophic rhinitis at both time intervals.

## CONCLUSION

This study showed that the Reactionary hemorrhage was more in those who underwent PIT than in those who underwent SMD. Even though the incidence of nasal crust formation was more and was statistically significant during early follow ups in those who underwent PIT, at the end of 3 months it became insignificant. There was a statistically significant occurrence of headache and nasal pain in those who underwent PIT during early post-operative period, but this difference became insignificant when assessed later. Remote sequelae like atrophic rhinitis or nasal synechiae were not observed in any of these groups. Even though the incidence of short-term complications is more with PIT, in the long run it is found to be more effective than SMD.

## REFERENCES

1. Hol MK, Huizing EH. Treatment of inferior turbinate pathology: A review and critical evaluation of the different techniques. *Rhinology* 2000;38:157-66.
2. Okhaku A, Ogisi F. Submucosal diathermy in inferior turbinate hypertrophy: Review of 12 cases in Benin City. *Sahel Med J* 2015;18:71.
3. Anil HT, Mahjabeen B. Comparative study between partial inferior turbinectomy and submucosal diathermy in the management of inferior turbinate hypertrophy. *IJS* 2014;3:323-5.
4. Imad, Javed, Sanaullah. Comparison of submucosal diathermy with partial inferior turbinectomy: A fifty case study. *J Postgrad Med Inst Peshawar Pak* 2011;26:91-5.
5. Al-Baldawi MH. Management of inferior turbinate hypertrophy: A comparaytive study between partial inferior turbinectomy and submucosal diathermy. *Iraqi J Community Med* 2009;22:264-7.
6. Hashmi ZA, Bashir G, Shah SA. Tramadol hydrochloride versus diclofenac sodium for early post-operative pain control. *J Rawal Med Coll* December 2006;10:70-2.
7. Maskel S, Eze N, Patel P, Hosni A. Laser inferior turbinectomy under local anaesthetic: A well tolerated out-patient procedure. *J Laryngol Otol* 2007;121:957-61.
8. Gomaa MAn Abdel Nabi OG, Abdel Kerim ARA, Aly A. Comparative Study between Partial Surgical Inferior Turbinectomy and Sub-mucosal Diathermy of Inferior Turbinate for Treatment of Inferior Turbinate Hypertrophy. *Otolaryngology* 2015;2015:5-6.

**How to cite this article:** Vishnu MS, Rajamma KB. Comparison of Submucosal Diathermy and Partial Inferior Turbinectomy. *Int J Sci Stud* 2016;4(1):120-123.

**Source of Support:** Nil, **Conflict of Interest:** None declared.