

Incisal Show – A Decrease with an Increase in Lines of Life

S Padmasree¹, Bhanu Rekha¹, S Rajesh², A Ranukumari³

¹Post-graduate Student, Department of Prosthodontics and Implantology, Mahatma Gandhi Postgraduate Institute of Dental Sciences, Puducherry, India, ²Assistant Professor, Department of Prosthodontics and Implantology, Mahatma Gandhi Postgraduate Institute of Dental Sciences, Puducherry, India, ³Professor, Head of Department, Department of Prosthodontics and Implantology, Mahatma Gandhi Postgraduate Institute of Dental Sciences, Puducherry, India

Abstract

Introduction: Older subjects usually show less of their upper incisors and more of their lower incisors than younger subjects.

Objective: To determine upper and lower central incisor crowns visibility with variability in age and length of lips at rest in Pondicherry subjects.

Materials and Methods: A total of 96 random voluntary subjects were chosen and divided into 3 groups. Group 1, 20-40 years of age; Group 2, 41-60 years of age; Group 3, 61 years of age and older. Each group contained 32 subjects. The vertical display of the incisors was measured in millimeters from the midpoints of the incisal edges of the upper and lower central incisors to the borders of the upper and lower lips, respectively, by two methods – manual measurement using vernier caliper and the other using standardized photographic method.

Results: The mean maxillary incisor display of Group 1 was 3.33 mm, Group 2 was 2.83 mm, and Group 3 was 1.21 mm and that for mandibular central incisor visibility for Group 1 was 0.17 mm, Group 2 was 0.25 mm, and Group 3 was 1.63 mm. For an increase in lip length from 19 to 22 mm, there was an average decrease of maxillary incisal visibility by 0.2 mm.

Conclusions: There was a decrease in the maxillary and an increase in mandibular incisor visibility as the age progresses. Maxillary incisor visibility also decreased as there was an increase in the lip length. No significant difference was there according to sex.

Key words: Lip length, Mandibular incisal visibility, Maxillary incisal visibility, Photographs, Vernier caliper

INTRODUCTION

Facial appearance is an important factor in many cultures, and the mouth and teeth in particular are major factors determining our perceptions of emotion and facial attractiveness.¹ According to Sarver, the smile arc is defined as the relationship of the curvature of the incisal edges of the maxillary incisors and canines to the curvature of the lower lip in the posed smile. The ideal smile arc has the maxillary incisal edge curvature parallel

to the curvature of the lower lip. These factors are quite important in dentures. Tooth placement is very likely the greatest contributor to the denture look. The denture look is “that typical facial appearance common to most denture wearers.”^{2,3}

Pound advises placing the teeth back in the original position from which they arose. A great many others have accepted this philosophy, and it is widely advocated in the modern prosthodontic literature. Prothero, Nicholas, Sears, Landa, Schlosser and Gehl and Allen instructed to position the upper central incisor vertically so that 0-2 mm of the incisal edge is visible below the upper lip. However, an attempt to create a more youthful appearance will appear inharmonious with the skin and facial structures for variations in age and will produce a displacing factor in that the denture will be out of balance between the tongue and labial musculature.^{4,5}

Access this article online



www.ijss-sn.com

Month of Submission : 02-2016

Month of Peer Review : 03-2016

Month of Acceptance : 04-2016

Month of Publishing : 04-2016

Corresponding Author: Dr. S Padmasree, Department of Prosthodontics and Implantology, Mahatma Gandhi Postgraduate Institute of Dental Sciences, Puducherry, India. Phone: +91-9629536395. E-mail: divyapadmasree@gmail.com

Esthetics has become increasingly important in the practice of modern dentistry and is synonymous with a natural harmonious appearance. Esthetics or display zone according to Sachdeva *et al.* is composed of the size, shape, position, and color of the displayed tooth, gingival contour, buccal corridor, and framing of the lips. Lip position and the amount of tooth display during smile and speech are important in prosthodontics. Therefore, the study was done to evaluate the age-related changes of maxillary and mandibular incisor display related to upper lip length at rest.⁶

The aim of the study was to investigate the degree of visibility of maxillary and mandibular central incisor according to age and lip length. The objective was to study the incisal display and lip length.

- By direct manual methods using a vernier caliper (Figure 1).
- By photographs using J-ruler software (Figure 2).

MATERIALS AND METHODS

This study was conducted in the Department of Prosthodontics, Mahatma Gandhi Postgraduate Institute of Dental Sciences, Puducherry. A sample size of 96 was used for different age groups (Table 1).

Exclusion Criteria

- Missing anterior teeth
- Traumatized lips

Table 1: Sample size

Age group	Sample size
20-40 years	32
41-60 years	32
>60 years	32
Total sample size	96



Figure 1: Vernier caliper

- Extreme attrition
- Mobile or extruded anterior teeth
- Prosthetic anterior teeth replacements
- Uncooperative individuals.

Measurements of incisor display were obtained with the lips at rest and mandibular posture unstrained. The following procedure was used: Subjects were asked to sit in front of the examiner in an upright posture with their heads in the natural head position or the esthetic position. The natural head position is defined “as the position of the head in a standing up or an erect sitting individual, with his visual axis oriented horizontally.”⁷

The patients were then instructed to wet their lips with their tongues, open their mouths gently, swallow and articulate the word “Emma.” Each subject’s posture was checked twice to ensure that the lips were at rest and the teeth slightly apart. The amounts of upper and lower central incisor crowns displayed were then measured with a vernier caliper from the midpoints of the incisal edges of right upper central incisors to the lower border of the upper lip and from the midpoints of both lower central incisors to the upper border of the lower lip (Figures 3 and 4). When an incisor could not be seen, the measurement was considered to be zero.

For the photographic method, photographs were taken with the patient in the same position using a single lens reflex camera (Camera Details - Canon 5D Mark II of 24 pixel resolution and with a lens zoom of 24-105 mm using two photopro 23 photographic umbrella lights with 500 W) (Figure 5).

Methods of Standardization

- Distance from the camera to eye level of the patient is standardized to 5 ft
- All patients were made to sit with the natural head position



Figure 2: Photographic set up

- Camera lens aligned to patients' eye level
- Maxillary right central incisor midline (line drawn perpendicular to the incisal edge) is used as a reference for measurement (Figure 6).

During taking a photograph, a reference scale is placed at the level of the maxillary central incisor. A software (J-ruler)

is used. The zoom of the picture is adjusted to match a mm of the reference scale with a mm of the software ruler (Figure 7a and b). The software provides accurate measurement between two points.

Statistical Analysis

Paired *t*-test was done to compare manual and photographic methods.

One-way ANOVA test was done to analyze the relativity of the maxillary and mandibular incisor visibility to age.

RESULTS

Using a paired *t*-test, it was found that there was no significant difference in lip length, maxillary and the mandibular incisor visibility between two measures and indicating the existence of reliability. So, both the methods were used to measure the maxillary incisor visibility.

One-way ANOVA test results showed that the maxillary and the mandibular incisor visibility had a significant change according to age, i.e., the maxillary incisor visibility decreases by age and the mandibular incisor visibility

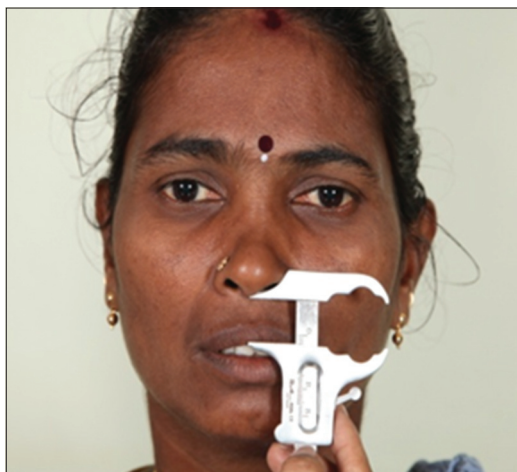

Figure 3: Lip length measurement



Figure 4: Incisal visibility measurement

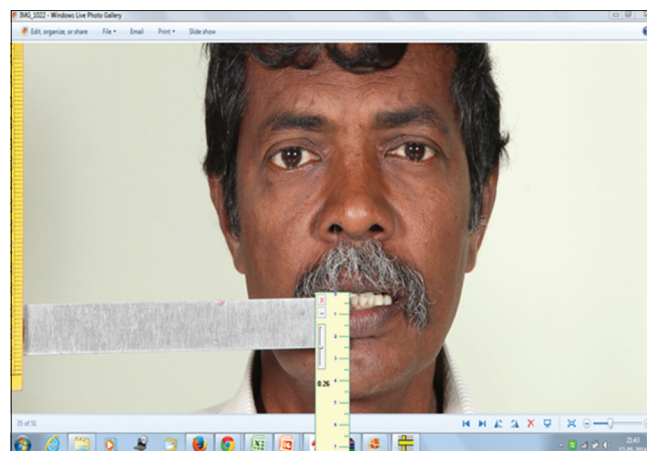
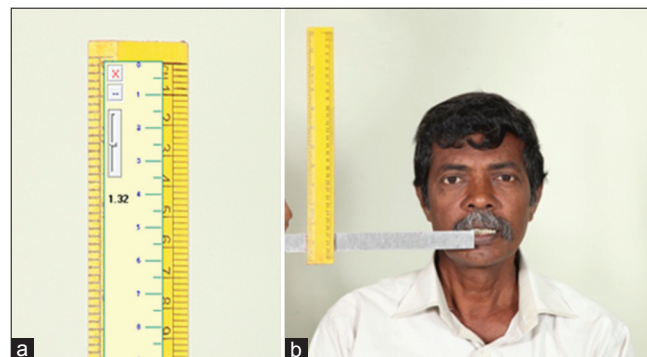

Figure 6: Incisal visibility measurement in the software



Figure 5: The photographic set up



Figures 7: (a and b) Zoomed view of measurement using software

increases by age (Tables 2 and 3). However, results show no significant difference between the incisor visibilities according to sex (Table 4).

DISCUSSIONS

According to the test results, there was no significant difference in lip length, maxillary and the mandibular incisor visibility between two measures (manual method and the photographic method) and indicating the existence of reliability.

The upper and lower incisor crowns visibility below and above the margins of the lips were measured. When the lips were at rest, the reduction of upper incisor display with age and an increase in the lower incisor display with age in both men and women was found. These findings may have important implications for prosthodontic treatment planning which tend to ignore long-term changes in the incisor - lip relationships. The incisor visibility given in complete dentures have to be modified according to age. If not, the dentures will end up in what is called the “denture look.”³

The display of the anterior teeth is relevant not only for dental esthetics but also for facial attractiveness. The shape, alignment, position, and display of the upper

central incisors determine a pleasant smile and should be considered when planning for complete dentures.

The positions of the incisal edges of the upper incisors relative to the relaxed lips are often used as a vertical reference point. The determination of the “relaxed lips position” is reproducible but not easily obtained for all patients or on some occasions.¹² Our findings on the age changes in the display of the upper and lower incisors and, in particular, the reduced display of the upper anterior teeth and increased display of lower anterior teeth with age, agree with previous studies. These results confirm previous reports by Dong *et al.* and de Motta *et al.* that young people display more of their upper incisors than older people. These changes were not determined by changes in the positions of the teeth but rather by age-related changes in the facial tissues and the effect of gravity on the lips. Elongation of the lips continues throughout life and exceeds the age-related increase in lower anterior face height. The positions of the lips also depend on factors such as lip length, lip type, and muscle tonus, but these factors were not assessed.^{8,9}

Graph 1 describes the maxillary and the mandibular incisor variation according to age and lip length. The X-axis denotes the increase in age, and the Y-axis denotes the incisor display. The graph shows the three ranges of lip length in three different colors. This indicates that as the lip length increases the incisor display of maxillary central incisor decreases for every age group. Such coordination is not found for mandibular incisor display. The overall graph shows that as the age increases the maxillary incisor display decreases and the mandibular incisor display increases.

The study results are in accordance with the results obtained by Vig and Brundo,³ who noted that there was a decrease in maxillary incisor exposure of about 3.41 mm

Table 2: Results of one-way ANOVA comparing maxillary incisor by age

Age	N	Mean	SD	F value	P value
21-40	32	3.33	1.11	13.43	0.0000
41-60	32	2.81	0.96		
>60	32	1.95	1.21		

P<0.05 - significant (F value is significant), the maxillary incisor visibility decreases by age, SD: Standard deviation

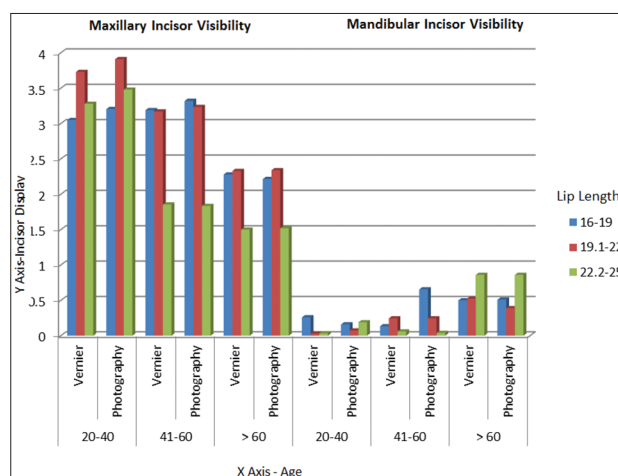
Table 3: Results of one-way ANOVA comparing mandibular incisor by age

Age	N	Mean	SD	F value	P value
21-40	32	0.17	0.42	13.46	0.0000
41-60	32	0.14	0.30		
>60	32	0.70	0.68		

P<0.05 - significant (F value is significant), the mandibular incisor visibility increases by age, SD: Standard deviation

Table 4: Incisor visibility according to sex

Sex/ Method	Maxillary incisor visibility		Mandibular incisor visibility	
	Vernier	Photography	Vernier	Photography
Female	2.76	2.86	0.29	0.31
Male	2.74	2.8	0.33	0.43



Graph 1: Comparing the maxillary and mandibular incisal visibility of three different age groups of patients with varying lip length

when compared with people of age group from 29 years to above 60 years. The findings of Dong *et al.*⁸ were that there was a maxillary incisor display of about 2.5 mm at rest and 2 mm at smile when people of 20-29 and above 60 years are compared.

Age-related changes in incisor display can be underestimated if the sample includes subjects from a narrow age band. Subjects between 20 and 60+ years were used. It is important that incisor display is appropriate for the age of the patient. The prosthodontic literature typically recommends that artificial teeth are set up so that 2 mm of the central incisor crowns is visible when the lips are at rest, but patients who want a more youthful appearance will often ask for more of their incisor crowns to be visible.¹⁰ When the display of the anterior teeth is more in older individuals, artificial look is provided. To increase a natural appearance for the patients of age above 60 years, the maxillary incisal visibility can be reduced and mandibular incisal visibility can be increased, thus aiding in a better esthetics for the elderly.

The limitations of this study include the manual errors in making the measurements. To minimize these errors, two techniques of measuring the visibility is followed and both the techniques are found to give the same results. The study helps as a guide to determine the positioning of the incisors in cervico incisal direction. Any guidelines regarding the labiolingual positioning are not provided.

CONCLUSIONS

1. With increasing age, both genders showed less of their upper incisors and more of their lower incisors
2. No significant difference in visibility according to gender
3. Significant decrease in visibility according to lip length.

The present study concludes that the range of central incisor visibility varies according to age and lip length, and average values cannot be used as a guide for all cases in clinical practice. The average mandibular incisor visibility increases from 0.1 to 0.58 mm as age increases and maxillary incisor visibility decreases to less than 2 from 3.5 mm as age increases.

This study would guide in proper positioning of the incisors considering the age and lip length of the patients. The consequences of incorrect positioning of the maxillary central incisors in relation to the maxillary lip line include both obvious esthetic consequences and other more subtle problems including improper plane of occlusion and occlusal vertical dimension. The result of the present study can be used as a reference according to age, sex, and lip length of the patients to correctly position the maxillary and the mandibular anterior teeth in complete denture, removable and fixed partial and implant supported prosthesis.^{11,13}

ACKNOWLEDGMENTS

The authors would like to thank Mr Raja Chozhan, MPR stills for his technical support.

REFERENCES

1. Rufenacht CR. Fundamentals of Esthetics. Chicago, IL: Quintessence Publication Co. Inc.; 1990. p. 73.
2. Frush JP, Fisher RD. How dentogenics interprets the personality factor. J Prosthet Dent 1965;67:441-9.
3. Al Wazzan KA. The visible portion of anterior teeth at rest. J Contemp Dent Pract 2004;5:53-62.
4. Vig RG, Brundo GC. The kinetics of anterior tooth display. J Prosthet Dent 1978;39:502-4.
5. Mack MR. Perspective of facial esthetics in dental treatment planning. J Prosthet Dent 1996;75:169-76.
6. Sachdeva K, Singla A, Mahajan V, Jaj HS, Negi A. Esthetic and smile characteristics at rest and during smiling. J Indian Orthod Soc 2012;46:17-25.
7. Silver C, Ferreira P. Frankfort plane vs. Natural head position in cephalometric diagnosis. Dent Med Probl 2003;40:129-34.
8. Dong JK, Jin TH, Cho HW, Oh SC. The esthetics of the smile: A review of some recent studies. Int J Prosthodont 1999;12:9-19.
9. da Motta AF, de Souza MM, Bolognese AM, Guerra CJ, Mucha JN. Display of the incisors as functions of age and gender. Aust Orthod J 2010;26:27-32.
10. Heartwell CM Jr, Rahn AO. Syllabus of Complete Denture. 4th ed. Philadelphia, Pennsylvania: Lea & Febiger; 1986.
11. Zarp GA, Bolender CL, Carlsson GE. Boucher's Prosthodontic Treatment for Edentulous Patients. 11th ed. St. Louis, Missouri: Mosby; 1997.
12. Patel JR, Prajapati P, Sethuraman R, Naveen YG. A comparative evaluation of effect of upper lip length, age and sex on amount of exposure of maxillary anterior teeth. J Contemp Dent Pract 2011;12:24-9.
13. Al-Hababeh R, Al-Shammout R, Al-Jabrah O, Al-Omari F. Tooth and gingival display in the anterior region at rest and during smiling of different age groups: A comparative study. J R Med Serv 2013;20:32.

How to cite this article: Padmasree S, Ranukumari A, Rajesh S. Incisal Show – A Decrease with an Increase in Lines of Life. Int J Sci Stud 2016;4(1):215-219.

Source of Support: Nil, **Conflict of Interest:** None declared.