

Minimally Invasive Endodontics a Promising Future Concept: A Review Article

Prithwish Mukherjee¹, Aditya Patel², M Chandak³, Rasika Kashikar¹

¹Post Graduate Student, Department of Conservative Dentistry and Endodontics, Sharad Pawar Dental College, Sawangi, Wardha, Maharashtra, India, ²Reader, Department of Conservative Dentistry and Endodontics, Sharad Pawar Dental College, Sawangi, Wardha, Maharashtra, India, ³Head, Department of Conservative Dentistry and Endodontics, Sawangi, Wardha, Maharashtra, India

Abstract

The primary aim of endodontic therapy is the long-term retention of a functional tooth by preventing or treating apical periodontitis. However, the outcome of the endodontic treatment is multifactorial such as the quality of the restoration and structural integrity of the tooth after root canal preparation. Dentists need to reassess and recalibrate the endodontic and restorative techniques to best suit the way that they practice today. At the same time, need to preserve essential tooth structure to routinely achieve a 50-year, not a 5-year, successful outcome. Contemporary research efforts are currently directed to better understanding dentin behavior and structure during aging and function. An alternative approach is to minimize structural changes during root canal therapy, which may result in a new strategy that can be labeled "minimally invasive endodontics (MIE)." MIE is desirable in the interest of the patient, and preserving tooth structure requires optical magnification aids (surgical microscope), ultrasonic-assisted preparation techniques, modern file systems, and in-depth knowledge of the tooth and root canal anatomy.

Key words: Concept, Minimally invasive endodontics, Principles, Various aspects of new concept

INTRODUCTION

The goals of successful endodontic treatments are to eliminate all organic substrates from the complex root canal system, and filling the root canal system. In the context of current endodontic development, for proper cleaning and shaping, for promoting the long-term health of supporting structure of a tooth well shape canal is needed.

Minimally invasive endodontics (MIE) is a concept of maximum preserve the healthy coronal, cervical and radicular tooth structure during the endodontic treatment. For success, the dentist must aware between conservation and elimination of tooth structure during endodontic procedure to fulfill the endodontic goals.

Dr. Herb Schilder, in 1974, precisely described the mechanical objectives for the preparation of a canal that,

when filled, would ensure the biological goals for long-term success. However, these objectives were published way before any proposal of the most contemporary concepts of minimally invasive dentistry and, more recently, MIE.

Predictability of success in endodontics is currently lie on preparing the access cavity, shaping, cleaning, and filling root canal systems. Going forward, the question that should be scientifically answered is, how conservatively can be prepared any given access cavity or root canal, and most importantly - still enable the root canal system to be both 3D cleaned and filled? Until, this question is answered by collaborative research, it would be better to continue to practice utilizing the most proven treatment concepts and techniques. There is an old saying, "Model success. Success leaves clues." Long-term endodontic treatment success must integrate respect for the concept of MIE while fulfilling treatment objectives by mechanically and biologically.

MIE refers to the minimally removal of dentin during the all three phases of a root canal procedure: (1) Coronal access preparation; (2) radicular apical preparation; and (3) flaring of the canal that connects the coronal to the apical preparations.¹ To achieve these dental surgeons must develop new skills and dexterity

Access this article online



www.ijss-sn.com

Month of Submission : 02-2017
Month of Peer Review : 03-2017
Month of Acceptance : 03-2017
Month of Publishing : 04-2017

Corresponding Author: Dr Prithwish Mukherjee, Sharad Pawar Dental College, Datta Meghe Institute of Medical Science, Wardha, Maharashtra, India. Phone: +91-7276772047. E-mail: dr.prithwish4u@gmail.com

to adapt a limited working environment during treating endodontic disease. These skills include working with new instruments, irrigants for cleaning and shaping the canal system and applying newer materials that increase the prognosis for restoring structure and retaining the natural dentition. Utilizing advanced imaging modalities and computer software for understanding the complexities of the root canal system, employing increased magnification, and lighting for visualizing the pulpal space.

However, currently, there are no developed protocols for MIE. The aim of this review is to illustrate the current status of non-surgical endodontic procedures and highlighting the conservation of tooth structure to enhance longevity after root canal treatment.

PRESERVING STRUCTURAL INTEGRITY

The remaining structural integrity of the tooth plays the key factor that determines prognosis as it relates to the future function of the tooth after restoration (Figure 1).^{1,2} The goal of all restorative procedures is maintaining strength and stiffness that resists structural deformation, especially in endodontics. Dentin is weakened unequally by any restorative material in our restorative procedures.³

Reeh *et al.*, in 1989, did a study to assess the stiffness of cusps when comparing conventional cavity preparations to endodontic access openings on bicuspid teeth. It was found that endodontic access openings by itself have only a small (5%) impact on tooth stiffness as opposed to any restorative preparation that removes the tooth's marginal ridges reducing cuspal stiffness by 63%, for example, a MOD preparation. The study identified that with each prepared surface approximately a 20% loss of tooth strength occurs. Marginal ridges are a key factor in retaining tooth strength as per above studies.⁴

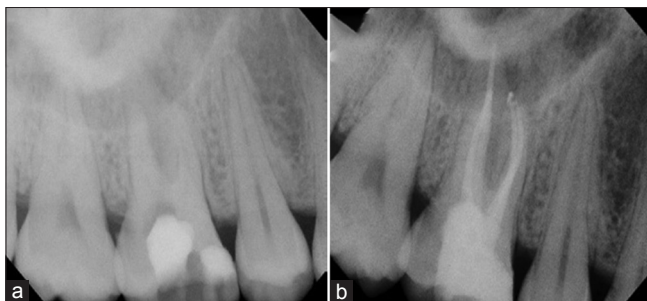


Figure 1: Undue dentin removal during access preparation in tooth 16, forever compromising tooth strength. (a) Pre-operative periapical radiograph; (b) composite build-up with fiber post in the palatal canal after completion of the root canal treatment in tooth 16 (British Dental Journal 2014;216(6))

There is a widely held clinical perception that endodontically treated teeth are more brittle and hence more likely to fracture. A study on animal that shows moisture loss of 9% after root canal treatment in dog's teeth gave support to this hypothesis.⁵ However, there are currently a number of studies in human teeth showing that the dentin properties of endodontically treated teeth do not differ in any meaningful way from vital dentin.⁶⁻⁸ Hence, the predominant reason that endodontically treated teeth are more prone to fracture due to the structural loss. Collectively, these studies show minimum dehydration effects due to pulpal removal and demonstrate biomechanical behaviors in strength and toughness testing that are similar to vital dentin.⁶⁻⁸

Recently, researchers have shown that the cause of fracture is multifactorial; loss of structure is not the only reason. Factors which can cause the dentinal fatigue resulting cracks are chemical factors such as irrigants and medicaments on dentin; the bacterial effect on the matrix of dentin; structural loss due to the effect of post and core restorations and the results of age changes in dentin.³ There is up to 50% reduction in the tensile and fatigue strength of coronal dentin in seniors (over 55 years) when compared to that of young adults. The resistance to propagation of fatigue cracks in dentin decreases with increasing patient age, and the incremental rate of crack extension is up to 100 times greater in seniors.^{7,8}

Importance of Dentin

Enamel is essentially a crystalline structure and is therefore naturally supported 100% by dentin. By contrast, dentin is a multilevel composite that can stand alone and acts ideally as a semi-rigid pipe.

When endodontically treated teeth fail under function, that outcome is determined primarily by two etiologies: (1) Degree of stress experienced by the tooth under load and (2) inherent biomechanical properties of the remaining structure responsible for resisting fracture. Among technical elements of root canal therapy, access preparation and post-preparation are most relevant in causing the tooth more susceptible to significant destabilisation.⁹ Biological success (i.e., no periradicular disease) and survivability of the tooth there are three essential aspects of clinical endodontics:

- Biological success is achieved by prevention or removal of the apical 3 mm to 4 mm of the canal microbes.
- With the minimal removal of original tissue in the coronal two-thirds of the root long-term survivability of the tooth is improved.
- Access to the root canal (both coronal and apical) is critical.

Unfortunately, only a few of long-term controlled clinical studies are available for understanding the relationship

between restoration, especially with posts, tooth fracture and the biomechanical behavior of restored dentin (Figure 2). The mechanical demands of human mastication create an endless number of impacting variables, and only those long-term clinical outcomes remain the gold standard for evidence.

Evidence are there that not only in endodontically treated tooth but also in normal tooth fracture can occur under physical loads. Chan *et al.* (1998) stated that all teeth, especially molars, can fracture without any endodontic treatment. When a fracture occurs in both the periodontal attachment and the bone adjacent to the fracture will affect. Once a fracture begins in the root, it leads to an accumulation of bacteria, food debris, cements, necrotic tissue which causes inflammation of a reactive periodontium. Yeh *et al.* suggested heavy masticatory forces as a cause for root fracture.¹⁰ Root fractures seem to be more prevalent in seniors and male populations; preexisting attrition is often a component of the condition.¹⁰

MINIMALLY INVASIVE ACCESS PREPARATION

The priority of effective endodontic therapy is to access, shape and clean the complex system in such a manner that will allow efficient and total filling of the root canal space while leaving the tooth with maximum strength to function successfully. The mechanical objective of access preparation is to physically penetrate, funnel, and unroof the pulp chamber. The biological and mechanical objective of access preparation and concept of MIE should coexist. Hence, the access preparation should not be too small or big. Too small access obstructs the view of the operator, and too big preparation unnecessary remove the vital tooth structure (Figure 3). In this era of enhanced lighting and magnification, as well as highly flexible rotary instruments, help to achieve the objective of access preparation with MIE concept.

Recently, maintaining the structural integrity of the pericervical area of the tooth (about four mm above and below the alveolar crest) has been emphasized (Figure 4).

Especially in molars of pericervical dentin (PCD) plays a critical role in the maintenance of their long term survivability and optimum function.⁴ The philosophy of minimal invasion is now discouraging the use of round burs and Gates-Glidden burs as these instruments commonly gouge the endodontic access and the coronal third of the root canal, especially around the PCD (Figure 4) Gouging of the access and coronal canal space must be avoided in order to preserve maximal

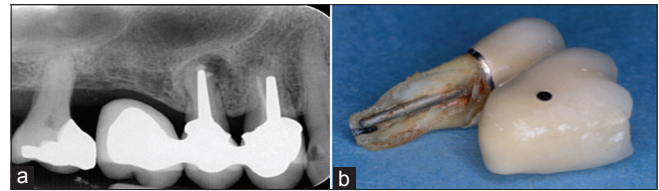


Figure 2: Vertical root fracture originating from post-preparation in tooth 15; (a) periapical radiograph after attempted apical surgery; (b) extracted tooth 15 after complete fracture. Note large and long post (British Dental Journal 2014;216(6))

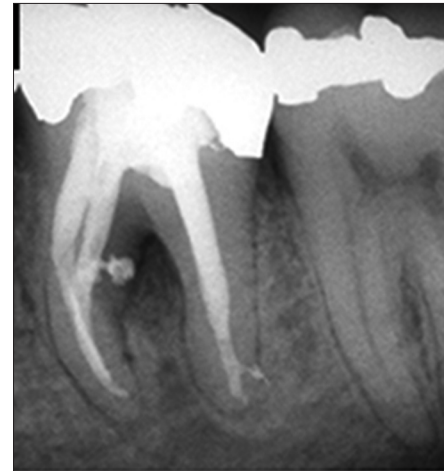


Figure 3: Wide preparation unnecessary thinning of root dentin

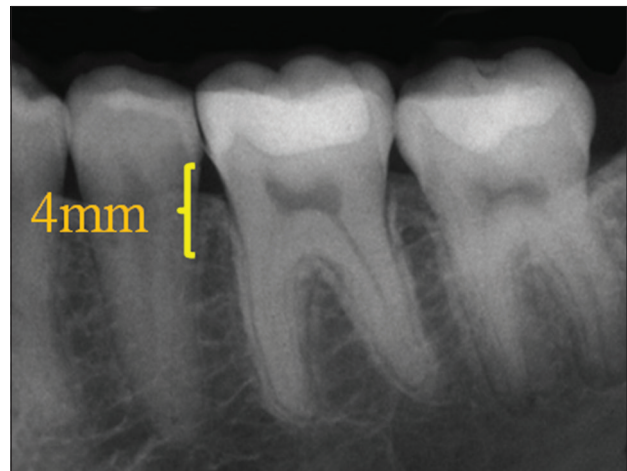


Figure 4: Pericervical area - Dentine near the alveolar crest 4 mm coronal to the crestal bone 4 mm apical to the crestal bone

resistance to structural flexure and ultimate failure.⁴ The key is banking of tooth structure and is age- and case-sensitive. For example, in the case of the importance of pericervical enamel, in the physiologically young molar, the cemento-enamel junction (CEJ) is an invaluable asset. More caries resistant are seen when margins of direct and indirect restorations placed on enamel than on dentin. For transition, the stress from crown to apex the CEJ is the most ideal vehicle. The practitioner ensures a more

viable and proven method to reinforce the endodontically treated tooth by directing the conservation of dentin and protecting dentin above and below the PCD. No man-made material or technique can compensate for tooth structure lost in those key areas.

SHAPING THE ROOT CANAL SPACE

Root canals are sometimes depicted as smooth hollow tubes that are more or less tapered in shape. However, in reality, they are often asymmetrical or oval in cross-section, they branch, dilacerate and divide and the canal walls show concavities and convexities.¹¹ Basically, it is a complex anatomical system. The goal of biomechanical instrumentation, the completed root canal shapes need to withstand the internal compressive forces of obturation; provide sufficient resistance form to contain softened and compressible filling materials and retain enough strength for mastication.

The big, aggressive canal-flaring concept is officially over. Endodontic design should be biomimetic and extremely conservative as: (1) the tooth will be stronger and (2) there is insufficient evidence that big shapes provide a better seal and thus fewer endodontic failures.^{6,7}

In a series of morphometric measurements on anterior and posterior teeth, Kerekes and Tronstad *et al.* in 1977, found a wide range of measurements at the apical constriction of all teeth. The true horizontal diameters are necessary to clean the terminus of root canal, Jou *et al.*¹² coined the term “working width” which is the critical need to understand the horizontal dimension of apical size and its clinical implication in cleaning the apical terminus. This creates two separate philosophies for practitioners, each focused on its own set of evidence-based protocols supporting a position on how to clean these apical diameters and ultimately shape the root.

Nowadays, there are two general trends in contemporary endodontic practice amongst the clinicians. Enhanced apical instrumentation and larger apical diameters with a minimal taper in the canal shape leads to weakening of the root structure as there is loss of apical dentin and a loss of control over the obturation component of treatment. Hence, now a number of practitioners advocate smaller apical preparations, continuous taper, and a preparation. This kind of preparation promotes resistance form, a tight apical seal and a conservative approach to creating sufficient shape for adequate disinfection. Smaller apical sizes preserve root dentin. This kind of arguments is strategy and technique-driven, often supported by several student outcomes. The impetus for smaller apical sizes has

been directed at the disinfection and obturation phase of endodontic therapy.¹³⁻¹⁵

On the other side, there is a significant number of literature presents in support of larger apical canal diameters are important to shape the apical canal wall, flush debris, allow deeper irrigation to the terminus and decrease remaining bacterial contamination in the system.¹⁶⁻¹⁸ Studies vary on which size diameter will accomplish maximum cleaning. New researches have shown that minimal sizes can accomplish this task of elimination of bacteria as adequately as larger diameters.^{19,20} It is clear from the evidence is that it is not possible that any apical preparation technique will render the terminus entirely free of bacterial contamination in an infected canal by the using of any schools of thought. Structural considerations in biomechanical preparation are very important and arguable.

Weine *et al.*²¹ and others have described and elucidated the structural damage and preparation errors such as transportation, ledging, apical perforation, and loss of the original canal position that can occur while shaping root canals with stainless steel instruments to large sizes. These shaping errors often lead to loss of working length and damage to the apical terminus leading to weakening of the root structure at its most fragile levels.

The use of super-elastic rotary and nickel-titanium instruments offers less straightening and better-centered preparations compared to traditional stainless steel instruments in preparing the wide range of anatomical variability seen in teeth (Figure 5).^{22,23}

CONSIDERATIONS IN MIE

The microbiologic etiology of endodontic disease is a key element of the overall treatment strategy. To achieve disinfection in any minimally invasive approach is a challenge. However, *in vitro* microbiological studies do not provide a definitive answer of required preparation size for antimicrobial efficacy. A large clinical data set does not support any association between apical healing or retention of a root canal-treated tooth with particular canal shape.²⁴

Current cleaning and shaping methods appear to be failed to remove all bio-burden from the root canal system. Therefore, search for techniques to enhance irrigation efficacy continues. The possibilities for physical means that enable enhanced disinfection vary from sonic or ultrasonic or other activation up to and including laser activation.^{25,26}

An *in vitro* study by Krishan *et al.* using a combined microcomputed tomography and load-to-failure approach.²⁷

Found that with minimal access cavity designed premolars shaping was not impacted, and load to failure was significantly higher for teeth. Till now as all the model of MIE access preparations are *in vitro*, so studies needed for the clinical implication of such preparation.

In current years, several investigations have illustrated microcracks in extracted teeth induced by various rotary shaping procedures in preparation of canal.²⁸ However, it is not clear that if such cracks are generated *in vivo*. It may be reasonable to lessen additional loads on a structurally weakened root by developing instruments that reduce vibration and rotational stresses during intracanal procedures. Micro-computed tomography studies showed that due to compacted hard tissue debris into unshaped canal make them potentially inaccessible to irrigation.²⁹ As the idea of MIE has been recently promoted, there is a scarcity of independent evaluations for such a strategy. It is likely future root canal preparation techniques will have to focus on balancing disinfection capacity and iatrogenic damage with enhanced debridement and disinfection.

RESTORATION STRATEGIES FOR MAXIMUM PROTECTION AND MINIMAL INVASION

A successful endo treatment needs a good post-endo restoration. Reviews of evidence surrounding the restoration of endodontically treated teeth, preservation of intact coronal and radicular tooth structure, especially maintaining the pericervical structure for allowing a substantial “ferrule effect,” is considered to be crucial for the optimal biomechanical behavior of restored teeth. The presence of a 1.5-2 mm ferrule has a positive effect on fracture resistance of endodontically treated teeth.³⁰⁻³³

Restorative materials should almost always be sacrificed before tooth structure. Teeth with a ferrule of one mm of vertical tooth structure doubled the resistance to fracture when compared with teeth restored without a ferrule.²⁹ Even an incomplete ferrule is considered a better option than a complete lack of ferrule if the clinical situation does not permit a circumferential ferrule. It concluded that an adequate ferrule is required for the long-term of an endodontically treated tooth.

Severely damaged teeth with little or no coronal structure, to provide space for a ferrule, should consider orthodontic extrusion rather than surgical crown lengthening. More tooth structure has been preserved by this approach and ensures a more favorable biomechanical behavior of remaining dentin structures.

Final cavosurface outline extension at the finish appointment hinges on the existing restorative, and the restorative plan. If abundant highly bondable substrate like etchable porcelain or enamel is available, and a bondable restorative material such as a composite resin is planned, the cavosurface should be Cala Lillied (Figure 6), or properly beveled on those areas. If the bondability of the substrate is of low, or a bond cannot be established between the substrate and restorative material, a butt joint or 70-90° interface at the cavosurface should be the objective. On multiple visit cases in which an unbonded temporary restoration is placed, the cavosurface should be maintained at 70-90° until the completion visit.

The nominal use of posts in endodontically treated teeth support minimally invasive therapy. In the past decade, use of post discouraged due to unnecessary loss of root dentine. Based on the evidence, it is clear that the retaining tooth structure is more valuable than the use of a post. The long-term success of endodontic treatment has always been dependent on the restorative treatment. A restored tooth should be structurally sound, and the sealed state of the root canal system should be maintained. Most of

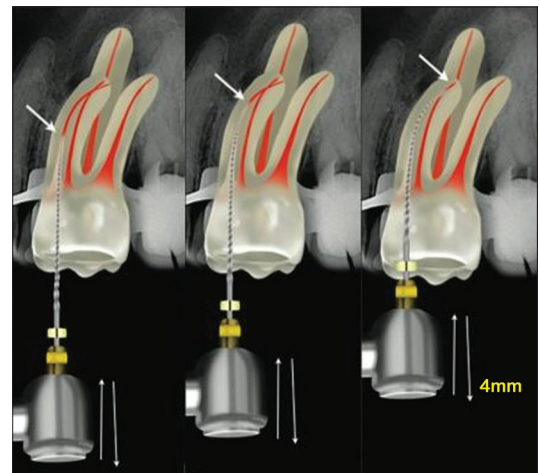


Figure 5: Use of nickel titanium instrument

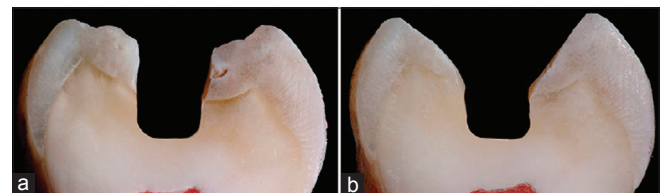


Figure 6: (a and b) Traditional parallel-sided access (left), compared with the Cala Lilly enamel preparation (right). Left - Unfavorable C factor and poor enamel rod engagement are typically present when removing old amalgam or composite restorations or with traditional endodontic access of 90° to the occlusal table. Right - The enamel is cut back at 45° with the Cala Lilly shape (David Clark, John Khademi. Molar endodontic access and dentin conservation. Dent Clin N Am 2010;54:249-273)

the endodontically treated teeth today are restored with adhesive materials.

Conventional thought has been that posts do not “reinforce” the root. Early restorative protocols considered this true for metal posts, but there are now growing evidence that bonded fiber posts can be placed with no removal of dentin structure, may protect the root and make it more resistant to fracture. Fiber-reinforced resin posts were introduced to provide more elastic support to the core. The reduced stress transfer to tooth structure lowered the root fracture. In addition, posts made of materials with a modulus of elasticity similar to dentin were considered more resilient; able to absorb similar impact forces and distribute the forces of mastication in a more protective manner to remaining dentin than stiffer metallic posts.³⁴ It may be premature to describe adhesive technology as “reinforcing” or “root strengthening” but in terms of distributing forces throughout the remaining dentin structure it may certainly be deemed “protective.”

CONCLUSION

The loss of a tooth in spite of successful endodontic therapy can invariably be attributed to one or more predictable explanation. Often these sequelae can clinically avoidable and the result of an approach to therapy that is far more invasive than required to cure the causes of apical periodontitis. These outcomes include.¹⁸

Poor access cavity design and execution:

- Iatrogenic or procedural mishap weakening pericervical integrity
- Instrumentation errors such as ledging, perforation, transportation from center
- Recontamination due to coronal leakage of the pulpal space
- Crown and root fracture.

As practitioners of dentistry, poor outcomes in the course of endodontic treatment should encourage reflection on the careful practice of endodontics that safeguards against undesired events. Our responsibility as experts is to protect patients from iatrogenic harm. This responsibility is fulfilled when we as a professional can give advanced and sophisticated therapies in a controlled and safe manner with preservation of the tooth as an overriding priority in all aspects of our treatments.

MIE are in the interest of the patient, and preserving tooth structure requires optical magnification aids (surgical microscope), ultrasonic-assisted preparation techniques, modern file systems, and in-depth knowledge of the tooth

and root canal anatomy. However, as yet there is no clear evidence concerning the impact of MIE on the success rate.

REFERENCES

1. Tang W, Wu Y, Smales RJ. Identifying and reducing risks for potential fractures in endodontically treated teeth. *J Endod* 2010;36:609-17.
2. Nagasiri R, Chitmongkolsuk S. Long-term survival of endodontically treated molars without crown coverage: A retrospective cohort study. *J Prosthet Dent* 2005;93:164-70.
3. Kishen A. Mechanisms and risk factors for fracture predilection in endodontically treated teeth. *Endod Top* 2006;13:57-83.
4. Reeh ES, Messer HH, Douglas WH. Reduction in tooth stiffness as a result of endodontic and restorative procedures. *J Endod* 1989;15:512-6.
5. Helfer AR, Melnick S, Schilder H. Determination of the moisture content of vital and pulpless teeth. *Oral Surg Oral Med Oral Pathol* 1972;34:661-70.
6. Sedgley CM, Messer HH. Are endodontically treated teeth more brittle? *J Endod* 1992;18:332-5.
7. Huang TJ, Schilder H, Nathanson D. Effects of moisture content and endodontic treatment on some mechanical properties of human dentin. *J Endod* 1992;18:209-15.
8. Nazari A, Bajaj D, Zhang D, Romberg E, Arola D. Aging and the reduction in fracture toughness of human dentin. *J Mech Behav Biomed Mater* 2009;2:550-9.
9. Lang H, Korkmaz Y, Schneider K, Raab WH. Impact of endodontic treatments on the rigidity of the root. *J Dent Res* 2006;85:364-8.
10. Yeh CJ. Fatigue root fracture: A spontaneous root fracture in non-endodontically treated teeth. *Br Dent J* 1997;182:261-6.
11. Wu MK, Dummer PM, Wesselink PR. Consequences of and strategies to deal with residual post-treatment root canal infection. *Int Endod J* 2006;39:343-56.
12. Jou YT, Karabucak B, Levin J, Liu D. Endodontic working width: Current concepts and techniques. *Dent Clin North Am* 2004;48:323-35.
13. Buchanan LS. The standardized-taper root canal preparation - Part 1. Concepts for variably tapered shaping instruments. *Int Endod J* 2000;33:516-29.
14. Buchanan LS. The standardized-taper root canal preparation - Part 2. GT file selection and safe handpiece-driven file use. *Int Endod J* 2001;34:63-71.
15. Ruddle CJ. Cleaning and shaping the root canal system. In: Cohen S, Burns RC, editors. *Pathways of the Pulp*. 8th ed. St. Louis: Mosby; 2002. p. 231-91.
16. Chow TW. Mechanical effectiveness of root canal irrigation. *J Endod* 1983;9:475-9.
17. Siqueira JF Jr, Lima KC, Magalhães FA, Lopes HP, de Uzeda M. Mechanical reduction of the bacterial population in the root canal by three instrumentation techniques. *J Endod* 1999;25:332-5.
18. Dalton BC, Orstavik D, Phillips C, Pettiette M, Trope M. Bacterial reduction with nickel-titanium rotary instrumentation. *J Endod* 1998;24:763-7.
19. Yared GM, Dagher FE. Influence of apical enlargement on bacterial infection during treatment of apical periodontitis. *J Endod* 1994;20:535-7.
20. Ørstavik D, Qvist V, Stoltze K. A multivariate analysis of the outcome of endodontic treatment. *Eur J Oral Sci* 2004;112:224-30.
21. Weine FS, Kelly RF, Lio PJ. The effect of preparation procedures on original canal shape and on apical foramen shape. *J Endod* 1975;1:255-62.
22. Walia HM, Brantley WA, Gerstein H. An initial investigation of the bending and torsional properties of Nitinol root canal files. *J Endod* 1988;14:346-51.
23. Peters OA, Laib A, Rüegsegger P, Barbakow F. Three-dimensional analysis of root canal geometry by high-resolution computed tomography. *J Dent Res* 2000;79:1405-9.
24. Ng YL, Mann V, Gulabivala K. A prospective study of the factors affecting outcomes of non-surgical root canal treatment: Part 2: Tooth survival. *Int Endod J* 2011;44:610-25.
25. Klyn SL, Kirkpatrick TC, Rutledge RE. *In vitro* comparisons of debris removal of the endoactivator system, the F file, ultrasonic irrigation, and NaOCl irrigation alone after hand-rotary instrumentation in human mandibular molars. *J Endod* 2010;36:1367-71.
26. Peters OA, Bardsley S, Fong J, Pandher G, Divito E. Disinfection of root canals with photon-initiated photoacoustic streaming. *J Endod*

- 2011;37:1008-12.
27. Krishan R, Paqué F, Dao T, Kishen A, Friedman S. Root canal instrumentation performed through conservative endodontic access: A micro-CT assessment in incisors, premolars and molars [OR66]. J Endod 2013;39:e18.
28. Bürklein S, Tsotsis P, Schäfer E. Incidence of dentinal defects after root canal preparation: Reciprocating versus rotary instrumentation. J Endod 2013;39:501-4.
29. Paqué F, Boessler C, Zehnder M. Accumulated hard tissue debris levels in mesial roots of mandibular molars after sequential irrigation steps. Int Endod J 2011;44:148-53.
30. Juloski J, Radovic I, Goracci C, Vulicevic ZR, Ferrari M. Ferrule effect: A literature review. J Endod 2012;38:11-9.
31. Sorensen JA, Martinoff JT. Intracoronar reinforcement and coronal coverage: A study of endodontically treated teeth. J Prosthet Dent 1984;51:780-4.
32. Ross IF. Fracture susceptibility of endodontically treated teeth. J Endod 1980;6:560-5.
33. Barkhordar RA, Radke R, Abbasi J. Effect of metal collars on resistance of endodontically treated teeth to root fracture. J Prosthet Dent 1989;61:676-8.
34. Sterzenbach G, Franke A, Naumann M. Rigid versus flexible dentine-like endodontic posts - Clinical testing of a biomechanical concept: Seven-year results of a randomized controlled clinical pilot trial on endodontically treated abutment teeth with severe hard tissue loss. J Endod 2012;38:1557-63.

How to cite this article: Mukherjee P, Patel A, Chandak M, Kashikar R. Minimally Invasive Endodontics a Promising Future Concept: A Review Article. Int J Sci Stud 2017;5(1):245-251.

Source of Support: Nil, **Conflict of Interest:** None declared.