

Kimura's Disease: A Rare Cause of Local Lymphadenopathy

Havle Abhay¹,
Shedje Swapna²,
Thakare Darshan³,
Jain Vishal⁴,
Purohit Gautam⁴

¹Professor and Head, Department of ENT, Krishna Institute of Medical Sciences University, Karad, Maharashtra, India, ²Assistant Professor, Department of Anatomy, Krishna Institute of Medical Sciences University, Karad, Maharashtra, India, ³Department of ENT, KIMSU, Karad, Maharashtra, India, ⁴Postgraduate Student, Department of ENT, Krishna Institute of Medical Sciences University, Karad, Maharashtra, India

Corresponding Author: Dr. Havle Abhay D, Department of ENT, Krishna Institute of Medical Sciences University, Karad - 415 110, Maharashtra, India. Phone: +91-9423263164. Tel.: 2164-241555. Fax: 2164-241070. E-mail: entpubkimsu@gmail.com

Abstract

Kimura's disease is a rare chronic inflammatory disorder of unknown etiology, primarily seen in young Asian males, especially in Chinese and Japanese, though rare in Indians. The disease is characterized by a triad of painless cervical adenopathy or subcutaneous masses in the head or neck region, blood and tissue eosinophilia, and markedly elevated serum immunoglobulin E levels. Although it may mimic a neoplastic process, the disease is slowly progressive benign condition leading to difficulty in making the correct diagnosis. Early diagnosis of Kimura's disease may spare the patient from potentially harmful and unnecessary invasive diagnostic procedures. We report a case of Kimura's disease in a young Indian male presenting with bilateral postauricular swellings with review of the literature.

Keywords: Eosinophilic lymphogranuloma, Glomerulonephritis, Immunoglobulin E, Kimura, Subcutaneous nodules

INTRODUCTION

The first known report of Kimura disease was from China in 1937, when Kimm and Szeto who termed it as the "eosinophilic hyperplastic lymphogranuloma."¹ It received its current name in 1948, when Kimura *et al.* noted a change in the surrounding blood vessels and referred to it as unusual granulation combined with hyperplastic changes in lymphoid tissue.² Although it may mimic a neoplastic process, it is a rare benign idiopathic chronic inflammatory disorder. It is characterized by a triad of painless unilateral cervical adenopathy or painless subcutaneous masses in the head or neck region, blood and tissue eosinophilia, and markedly elevated serum immunoglobulin E (IgE) levels.

The disease is endemic to Asians (especially in China and Japan),²⁻⁴ but rare in India, with about 200 reported cases worldwide since its histopathological diagnosis. Non-Asian cases also have same histopathological features. There is marked male predominance with M:F ratio 3.5-7:1. Peak age incidence is in third decade. Treatment options such as complete surgical excision, steroids, radiotherapy, etc. are tried with variable responses. Recurrence is common with all the modalities of treatment.

CASE REPORT

An 18-year-old Indian male presented with the complaints of swelling behind both ears, which was gradually increasing in size since 2 years. Except the local pruritus, he had no additional complaint related to the swellings or any constitutional symptoms. Physical examination revealed two distinct palpable masses at the both postauricular areas, which were non-fluctuant, firm, soft, rubbery, non-tender, freely mobile and of about 4 cm × 3 cm size (right > left) (Figure 1). The rest of the general physical as well as systemic examinations were normal.

Peripheral blood smear showed 13% eosinophils with absolute eosinophil count of 1140/mm.³ Computed tomography (CT) scan temporal bone were performed to assess the extent and any intracranial extension of the lesion. Chest radiograph was within normal limits. A tuberculosis skin test (purified protein derivative skin test) was negative.

A simultaneous excisional biopsy and histopathological examination of the both postauricular lesions was made. Histopathology showed eosinophilic infiltration and vascular proliferation (Figures 2 and 3) and a prominent

vascularity within the extranodal soft tissues associated with lymphoid hyperplasia and sheets of eosinophils. The associated lymph nodes showed florid follicular hyperplasia, with focal eosinophilic microabscess formation within the paracortex and interfollicular region. Several germinal centers showed disruption by large aggregates and sheets of eosinophils. All these features suggested the diagnosis of Kimura's lymphadenopathy.

Accordingly, serum IgE levels were estimated which showed marked rise >3000.00 KIU/ml (normal range:

0-150 KIU/ml), thus further supported the diagnosis. Assessment of renal function was normal, and there was no evidence of proteinuria. Based on the clinical, histopathological and specific laboratory findings, the final diagnosis of Kimura's disease was made.

The treatment with oral prednisolone was started at a dose of 40 mg/day for the initial period of 1 week, and subsequently tapered every week by 10 mg/day over period of the next 4 weeks.

After 1 week of treatment, eosinophilia was decreased significantly and became well within normal limits in 2 weeks. IgE levels fell to 140 KIU/ml gradually. There was no local recurrence at the 24 months follow-up.

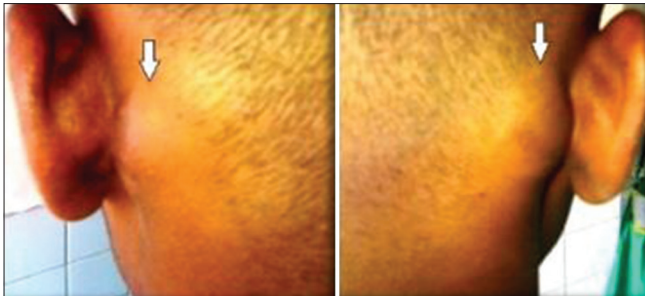


Figure 1: Clinical photographs of postaural swellings

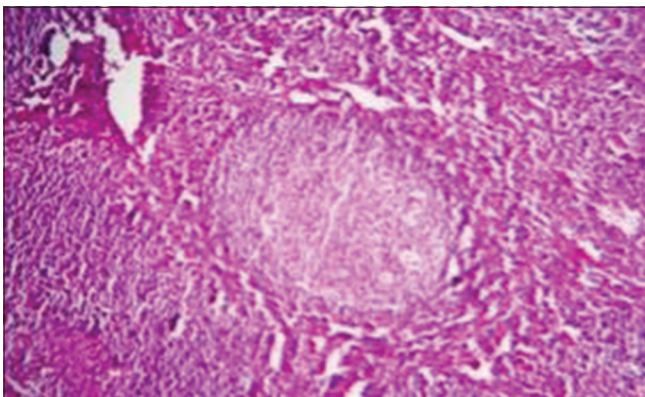


Figure 2: x100 microphotograph of the excision biopsy specimen showing a lymph node with florid germinal centre paracortical eosinophilic infiltrates, eosinophilic microabscess

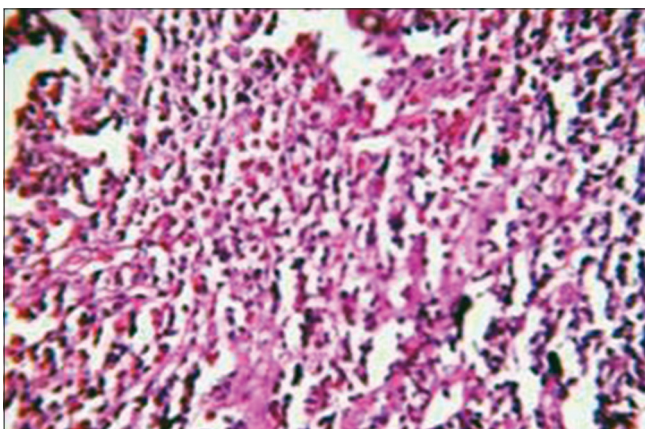


Figure 3: x400 microphotograph of the same, showing paracortical eosinophilic infiltrates

DISCUSSION

The disease typically presents with insidious onset of painless subcutaneous masses or adenopathy in the head and neck region⁴ with the occasional pruritus of the overlying skin.^{5,6} The disease usually involves subcutaneous tissues, lymph nodes (periauricular, axillary, and inguinal), parotid and submandibular salivary glands, and rarely, oral mucosa.^{4,7}

The clinical course of Kimura's disease is generally benign and self-limited. Most patients have a prolonged course with slow enlargement of the masses. Occasional spontaneous resolution is known. These lesions do not have any malignant potential. Kimura's disease may be complicated by renal involvement. In cases of renal involvement, nephrotic syndrome is the commonest presentation,⁸ proteinuria may occur in 12-16% of cases.⁸ A wide spectrum of histologic lesions has been described⁹ wherein extra membranous glomerulonephritis is found in up to 60% of patients.

In our case, there is normal renal function and no evidence of proteinuria.

The exact cause and pathogenesis of Kimura's disease is unclear, although it might be a self-limited allergic or autoimmune response triggered by an unknown persistent antigenic stimulus. Peripheral eosinophilia and the presence of eosinophils in the inflammatory infiltrate suggest that Kimura's Disease may be a hypersensitivity reaction. None of these theories has been substantiated till date.

Immunohistochemical studies have shown marked proliferation of human leukocyte antigen-DR CD4 cells¹⁰ which release eosinophilotropic cytokines (interleukin-4 [IL-4], IL-5,¹¹ and IL-13)⁶ which in turn may precipitate the

high serum IgE and eosinophilia.¹² This suggests that these cytokines may have a role in the pathogenesis.

Immunoperoxidase studies show IgE reticular network in germinal centers and IgE coated non-degranulated mast cells.⁴

The pathology of Kimura's disease is characterized by prominent germinal centers in involved lymph nodes containing cellular, vascular, and fibrous components.^{13,8} The cellular component consists of dense eosinophilic infiltrates in a background of abundant lymphocytes and plasma cells, eosinophilic microabscesses with central necrosis. The histopathological features of Kimura's disease are typical and allow its differentiation from other diseases that present similarly.

As the clinicians and pathologists may be unfamiliar with clinical and pathological presentation of this rare condition, the diagnosis of Kimura's disease can be difficult one. Therefore, the laboratory tests become essential in making correct diagnosis. The differential leukocytic count (DLC) almost always reveals peripheral eosinophilia (98%) and elevated serum IgE levels are seen in patients with Kimura disease.² The number of eosinophils on DLC can be closely correlated to the sizes of the neck masses.

Imaging studies such as CT and magnetic resonance imaging (MRI) are useful only in delineating the extent of the disease. Findings of intense contrast enhancement on CT scan and high T1- and T2-weighted signal intensities on MRI in parotid glands and lymph nodes have been described.¹⁴

The diagnosis is made by histopathological examination of excisional biopsy of the lesion.

Patients with Kimura's disease are often extensively evaluated for other serious disorders, including neoplasia (e.g., acute non-lymphocytic leukemia and Hodgkin disease and follicular lymphoma). Kimura's disease can mimic other disorders such as Mikulicz's disease, eosinophilic granuloma, malignancies and salivary gland tumors. Other differential diagnoses include angiolymphoid hyperplasia with eosinophilia,¹⁵ cylindroma, dermatofibrosarcoma protuberans, Kaposi sarcoma, and pyogenic granuloma (lobular capillary hemangioma).

There is no consensus on the management of Kimura's disease. Various treatment modalities have been tried with variable success.

At initial presentation, surgical biopsy is the most frequent diagnostic procedure performed. For the localized

disease, complete surgical excision of the lesion(s) may be curative. Recurrences have been reported, particularly after incomplete removal. Localized initial regrowth can often be managed with repeat surgical excision.

The goals of pharmacotherapy of Kimura's disease are to reduce morbidity, prevent complications and observation for the recurrence. Observation is acceptable if the Kimura's disease lesions are neither symptomatic nor disfiguring.

The pharmacotherapy of Kimura's disease has mainly involved the use of oral corticosteroids for an adequate period and tapered off gradually. The abrupt termination of steroid therapy often results in a relapse. Systemic steroids may be indicated infrequent relapses or cases complicated by nephrotic syndrome. The chronic steroid therapy poses its additional risks. Intralesional steroids (eg, triamcinolone acetonide) can shrink the nodules, but seldom result in the cure.

Radiotherapy has occasionally been used to treat recurrent, persistent or refractory cases to surgical and medical therapy, recalcitrant and large lesions, young patients or when surgery is not feasible. However, regrowth of the lesion is common after discontinuing such treatment.

Cyclosporine,¹⁰ oral pentoxifylline, all trans-retinoic acid with prednisone,¹⁰ imatinib have been tried in the treatment for Kimura's disease with variable responses. Cetrizine is suitable for the treatment of the pruritus associated with these lesions.

It is also thought that the inhibition of eosinophils may be the key in treatment of Kimura's disease, rather than other cells with regards to the lesions of the skin.

The choice of treatment modalities should be individual. Recurrence is common with all the modalities of treatment.

CONCLUSION

The present case reiterates that Kimura's disease may cause chronic neck masses in young male patients and highlights the need for increased awareness of this clinical entity in clinicians and pathologists to avoid unnecessary and potentially invasive investigations, such as bone marrow aspiration/biopsy and radiological imaging. A suspicion of this condition may be maintained, especially in the presence of slowly progressive swellings or any lymphadenopathy with concomitant eosinophilia or high-IgE levels. All such cases must be looked for and investigated for correct diagnosis and treatment.

ACKNOWLEDGMENT

We are grateful to Department of Pathology for the help and contribution in endeavor.

REFERENCES

1. Kimm HT, Szeto C. Eosinophilic hyperplastic lymphogranuloma, comparison with Mikulicz's disease. *Proc Chin Med Soc* 1937;1:329.
2. Kimura T, Yoshimura S, Ishikaura E. Unusual granulation combined with hyperplastic changes of lymphatic tissue. *Trans Soc Pathol Jpn* 1948;37:179-80.
3. Irish JC, Kain K, Keystone JS, Gullane PJ, Dardick I. Kimura's disease: An unusual cause of head and neck masses. *J Otolaryngol* 1994;23:88-91.
4. Kuo TT, Shih LY, Chan HL. Kimura's disease. Involvement of regional lymph nodes and distinction from angiolymphoid hyperplasia with eosinophilia. *Am J Surg Pathol* 1988;12:843-54.
5. Tsukadaira A, Kitano K, Okubo Y, Horie S, Ito M, Momose T, *et al.* A case of pathophysiologic study in Kimura's disease: Measurement of cytokines and surface analysis of eosinophils. *Ann Allergy Asthma Immunol* 1998;81:423-7.
6. Tavernier J, Plaetinck G, Guisez Y, van der Heyden J, Kips J, Peleman R, *et al.* The role of interleukin 5 in the production and function of eosinophils. In: Whetton AD, Gordon J, editors. *Blood Cell Biochemistry*. New York, NY: Plenum Press; 1996. p. 321-61.
7. Katagiri K, Itami S, Hatano Y, Yamaguchi T, Takayasu S. *In vivo* expression of IL-4, IL-5, IL-13 and IFN-gamma mRNAs in peripheral blood mononuclear cells and effect of cyclosporin A in a patient with Kimura's disease. *Br J Dermatol* 1997;137:972-7.
8. Som PM, Biller HF. Kimura disease involving parotid gland and cervical nodes: CT and MR findings. *J Comput Assist Tomogr* 1992;16:320-2.
9. Chow LT, Yuen RW, Tsui WM, Ma TK, Chow WH, Chan SK. Cytologic features of Kimura's disease in fine-needle aspirates. A study of eight cases. *Am J Clin Pathol* 1994;102:316-21.
10. Googe PB, Harris NL, Mihm MC Jr. Kimura's disease and angiolymphoid hyperplasia with eosinophilia: Two distinct histopathological entities. *J Cutan Pathol* 1987;14:263-71.
11. Olsen TG, Helwig EB. Angiolymphoid hyperplasia with eosinophilia. A clinicopathologic study of 116 patients. *J Am Acad Dermatol* 1985;12:781-96.
12. Day TA, Abreo F, Hoajsoe DK, Aarstad RF, Stucker FJ. Treatment of Kimura's disease: A therapeutic enigma. *Otolaryngol Head Neck Surg* 1995;112:333-7.
13. Zhang C, Hu J, Feng Z, Jin T. Kimura's disease presenting as the middle mediastinal mass. *Ann Thorac Surg* 2009;87:314-6.
14. Ben-Chetrit E, Amir G, Shalit M. Cetirizine: An effective agent in Kimura's disease. *Arthritis Rheum* 2005;53:117-8.
15. Sun QF, Xu DZ, Pan SH, Ding JG, Xue ZQ, Miao CS, *et al.* Kimura disease: Review of the literature. *Intern Med J* 2008;38:668-72.

How to cite this article: Abhay H, Swapna S, Darshan T, Vishal J, Gautam P. Kimura's Disease: A Rare Cause of Local Lymphadenopathy. *Int J Sci Stud* 2014;2(5):122-125.

Source of Support: Nil, **Conflict of Interest:** None declared.