

A Rare Case of Domperidone Induced Oculogyric Crisis in Young Female

C Charanya¹,
A M Raja²,
Siddharam Janti²,
Adnan Matheen¹,
R Pandurangan³

¹Postgraduate Student, Department of Ophthalmology, Chettinad Hospitals and Research Institute, Chennai, Tamil Nadu, India, ²Assistant Professor, Department of Ophthalmology, Chettinad Hospitals and Research Institute, Chennai, Tamil Nadu, India, ³Professor and Head, Department of Ophthalmology, Chettinad Hospitals and Research Institute, Chennai, Tamil Nadu, India

Corresponding Author: Dr. C Charanya, A 401 Urbanville Velachery Main Road, Velachery, Chennai - 600 042, Tamil Nadu, India. E-mail: charanyachendilnathan@gmail.com

Abstract

Domperidone being a commonly used drug causing oculogyric crisis (OGC) is a rare entity. OGC is type of the dystonic reaction due to certain drugs. It is the most common of the ocular dystonic reactions (which include blepharospasm, periorbital twitches, and protracted staring episodes). A 32-year-old female came to ophthalmology outpatient clinic with the complaints of inability to move both eyes since afternoon associated with neck rigidity, anxiety and difficulty in breathing. She had a history of acute gastroenteritis for past 1 day and was treated with tablet ciprofloxacin (500 mg twice daily) tablet domperidone (10 mg twice daily) and tablet pantoprazole (40 mg twice daily) on the same day morning and developed the above eye problems in 3 h. All routine investigations and imaging were normal and in doubt of acute dystonic reaction was treated with intravenous diphenhydramine 25 mg BD and she recovered in 2 h we came to the diagnosis of OGC due to domperidone.

Keywords: Domperidone, Dystonia, Oculogyric crisis

INTRODUCTION

Oculogyric crisis (OGC) is an acute dystonic reaction of the ocular muscles characterized by bilateral dystonic elevation of visual gaze lasting from seconds to hours. This reaction is most commonly explained as an adverse reaction to drugs such as anti-emetics, anti-psychotics, anti-depressants, anti-epileptics, and anti-malarials.¹ It is important to be able to recognize this ocular side-effect because, without a thorough patient history, symptoms can be confused with other diseases such as versive seizures, paroxysmal tonic upward gaze, and encephalopathy. OGC makes up 6%.² In anti-emetics metachlorpromide induced OGC is common, but domperidone induced OGC is a rare entity, and there are no reports in literature search.

CASE REPORT

A 32-year-old female came to ophthalmology outpatient clinic with complaints of inability to move both eyes since afternoon associated with neck rigidity, anxiety and difficulty in breathing (Figure 1). She was not having diplopia, fever and seizures and was not a known diabetic or hypertensive. She had acute gastroenteritis

for past 1 day and was treated with tablet ciprofloxacin (500 mg twice daily) tablet domperidone (10 mg twice daily) and tablet pantoprazole (40 mg twice daily) on the same day morning and developed the above eye problems in 3 h. On examination, she was conscious, oriented, agitated and had difficulty in breathing. Vitals were normal. General examination showed that both eyes were hypertrophic, and all the extraocular movements were restricted. Anterior segment examination was normal. Pupils were reacting to both direct and indirect light reflex and fundus was normal. Neck rigidity was present. Motor and sensory system was normal. Routine blood investigations and Serum electrolytes were normal. Computed tomography brain was taken and was found to be normal. Patient was admitted in intensive care unit for observation because of the difficulty in breathing and doubt of acute dystonic reaction was treated with intravenous (IV) diphenhydramine 25 mg BD and she recovered in 2 h (Figures 2-4).

DISCUSSION

Dystonic reactions are reversibly extrapyramidal effects that may occur after administration of certain drugs,

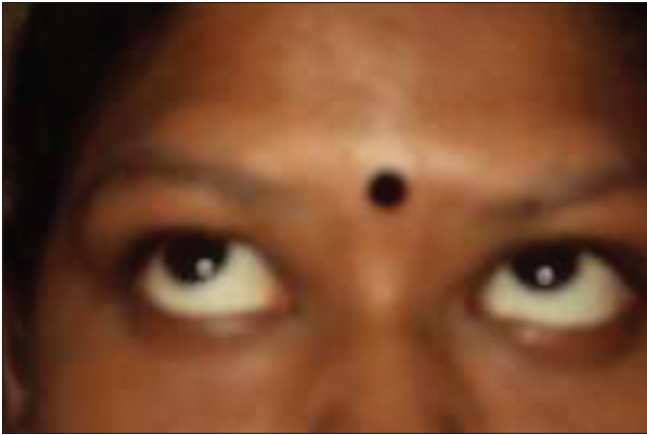

Figure 1: Patients eyes are hypertrophic on primary gaze

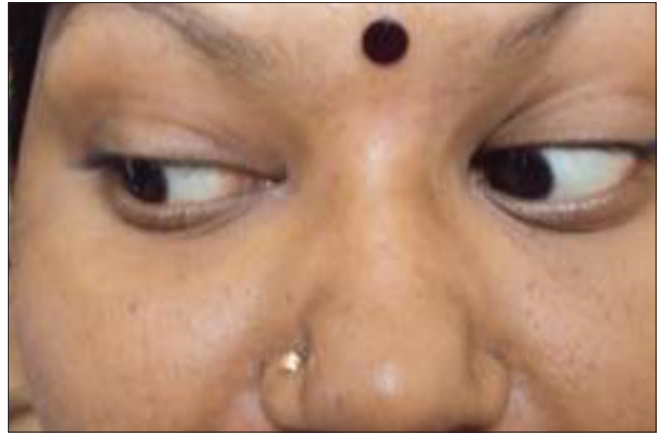

Figure 3: After treatment right eye abduction and left eye adduction present

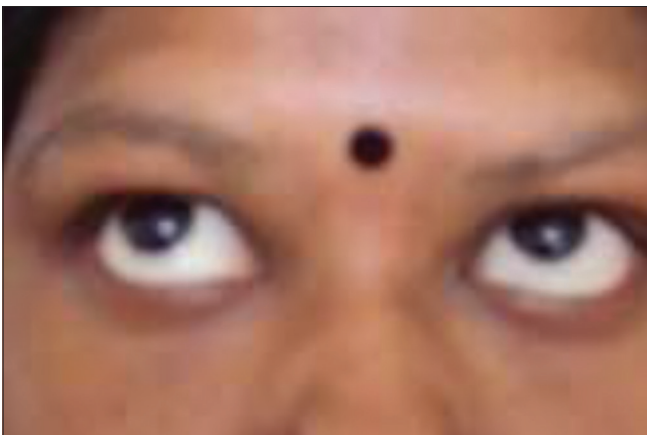


Figure 2: All extra-ocular movements restricted

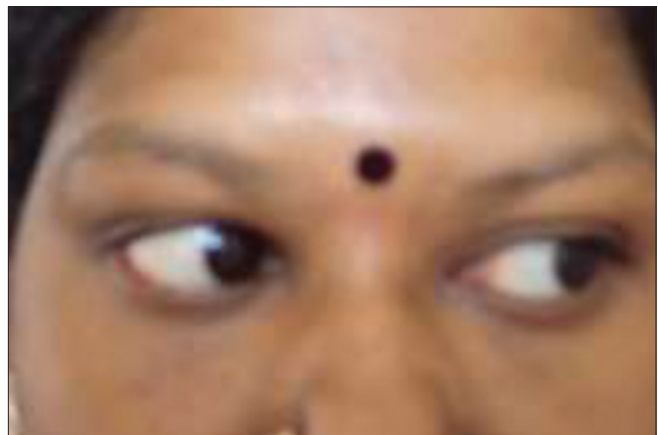

Figure 4: After treatment right eye adduction and left eye abduction present

and they may begin immediately or be delayed.³ Features of dystonic reactions are intermittent spasmodic or sustained involuntary contractions of the face muscles, pelvis, trunk, extremities, neck or sometimes and even the larynx.⁴ Dystonic reactions even though are not life threatening but it causes stress to the patient and the family. Mechanism of dystonic reactions in many drugs is by nigrostriatal dopamine D2 receptor blockade, which in turn causes an excess of striatal cholinergic output. High-potency D2 receptor antagonists mostly will produce an acute dystonic reaction.⁵ As there is diminished numbers of D2 receptors in old age there is less risk of dystonia in elderly age.⁶ Dystonia is more common in younger females, but the reason is unclear. Dystonic reactions usually occur shortly after initiation of drug; 50% occur within 48 h and 90% usually occur within 5 days of treatment.⁷ Acute dystonia can be misdiagnosed and confused with encephalitis, complex partial seizures, tetanus, strychnine poisoning and hypocalcemic tetany so careful history eliciting is important.⁸ People with family history of dystonia, recent use of cocaine or alcohol,

treatment with a potent dopamine D2 receptor antagonist are at more risk.⁹

Characteristic of OGC is sustained upward elevation of visual gaze of both eyes with neck hyperextension. Causes of OGC include usage of medications like neuroleptics, metoclopramide carbamazepine, lithium, levodopa, amantadine, chloroquine. Brain stem lesion and head trauma leading to OGC have also been reported.¹⁰ Clinical features of OGC include Involuntary, sustained deviation of the eyes, extension of the neck, restlessness, agitation, behavioral disturbances, transient psychotic episodes visual hallucination and auditory hallucination is also seen in some people.¹¹

Treatment in the acute phase involves reassurance and treatment with cogent in (IV or myocardial infarction) and/or benadryl (diphenhydramine) and/or diazepam or lorazepam. Maintenance therapy with oral forms of the above medications or amantadine are indicated in more

chronic recurrent cases.¹² On re-exposure to the drug chances of symptoms occurring again are high.

CONCLUSION

This case is presented because the incidence of domperidone causing OGC is rare, and domperidone is a common drug which we are using in day-to-day practice. As young doctors, we should be careful before prescribing any drug and ask about drug allergy and take a detailed history asking what medications the patients are on without a thorough history, symptoms can be confused with other diseases, such as partial epileptic seizure with versive movements and eye movement tics. It is necessary for ophthalmologists and general physician to be aware of these side effects and diagnose this early and avoid the trouble for the patient of going through detailed neurological examinations and investigations.

ACKNOWLEDGEMENT

Dr. B. Chendilnathan, Neurosurgeon for providing his valuable guidance and opinion in this case.

REFERENCES

1. Fahn S. The varied clinical expressions of dystonia. *Neurol Clin* 1984;2:541-54.
2. Christodoulou C, Kalaitzi C. Antipsychotic drug-induced acute laryngeal dystonia: Two case reports and a mini review. *J Psychopharmacol* 2005;19:307-11.
3. Marsden CD, Jenner P. The pathophysiology of extrapyramidal side-effects of neuroleptic drugs. *Psychol Med* 1980;10:55-72.
4. Volkow ND, Gur RC, Wang GJ, Fowler JS, Moberg PJ, Ding YS, *et al.* Association between decline in brain dopamine activity with age and cognitive and motor impairment in healthy individuals. *Am J Psychiatry* 1998;155:344-9.
5. Incecik F, Hergüner MO, Özcan K, Altunbasak S. Albendazole-induced dystonic reaction: A case report. *Turk J Pediatr* 2011;53:709-10.
6. Elliott ES, Marken PA, Ruehler VL. Clozapine-associated extrapyramidal reaction. *Ann Pharmacother* 2000;34:615-8.
7. Edwards M, Koo MW, Tse RK. Oculogyric crisis after metoclopramide therapy. *Optom Vis Sci* 1989;66:179-80.
8. Miller LG, Jankovic J. Metoclopramide-induced movement disorders. Clinical findings with a review of the literature. *Arch Intern Med* 1989;149:2486-92.
9. Roberge RJ. Antiemetic-related dystonic reaction unmasked by removal of a scopolamine transdermal patch. *J Emerg Med* 2006;30:299-302.
10. Schumock GT, Martinez E. Acute oculogyric crisis after administration of prochlorperazine. *South Med J* 1991;84:407-8.
11. Walker M, Samii A. Chronic severe dystonia after single exposure to antiemetics. *Am J Emerg Med* 2006;24:125-7.
12. Praharaj SK, Jana AK, Sarkar S, Sinha VK. Olanzapine-induced tardive oculogyric crisis. *J Clin Psychopharmacol* 2009;29:604-6.

How to cite this article: Charanya C, Raja AM, Janti S, Matheen A, Pandurangan R. A Rare Case of Domperidone Induced Oculogyric Crisis in Young Female. *Int J Sci Stud* 2014;2(5):126-128.

Source of Support: Nil, **Conflict of Interest:** None declared.