

Variations in the Shape of Coronoid Process of Indian Adult Dry Human Mandibles

B Lalitha¹, N S Sridevi²

¹Assistant Professor, Department of Anatomy, Deccan College of Medical Sciences, Hyderabad, Telangana, India, ²Associate Professor, Department of Anatomy, Sri Devaraj Urs Medical College, Kolar, Karnataka, India

Abstract

Background: The coronoid process is an excellent bone graft donor in reconstructive surgeries of various craniomaxillofacial deformities. It can also be used as anthropological marker to assess different populations and races.

Materials and Methods: It is a cross-sectional study consisting of 73 dry adult human mandibles. Variations in the shapes were observed, and the photographs were taken.

Results: Three shapes - triangular, hook, and round were observed. Triangular shape was predominant and hook shape was least common. In females, a round shape was the most prevalent. Bilateral symmetry was observed in 73.9%.

Conclusion: The knowledge of the variations in the shapes of coronoid process is helpful while dealing with the conditions such as zygomatico coronoid ankylosis, coronoid hyperplasia, and coronoid bone grafts.

Key words: Coronoid process, Mandible, Variations

INTRODUCTION

The coronoid process of the mandible projects upward and slightly forward as a triangular plate of bone. Its margins and medial surface give attachment to temporalis muscle.¹ The meaning of coronoid process (Greek-Korone) is crown which is a beak-like projection flattened from side to side at the anterosuperior aspect of ramus of the mandible.² Most of the standard textbooks describe coronoid process as flat, triangular process of mandible. Literature shows the variations in the shapes of coronoid process is classified into 3 types as hook, triangular, and rounded.³⁻⁶ The coronoid process can also be used as an anthropological marker in the determination of race.⁷ Clinically, it is important as it is a membranous bone which can be removed intraorally without any functional deficiency and facial disfigurement for reconstruction of orbital floor deformities, alveolar defects, paranasal sinus augmentation, non-union fractures

of mandible, osseous defect reconstruction, and other repairing procedures in craniomaxillofacial surgeries.⁸ This study aims to determine the shapes of coronoid process in relation to gender of Indian adult dry mandibles.

MATERIALS AND METHODS

This study is a cross-sectional study with the sample of 73 dry adult human mandibles (44 Male, 29 Female) consisting of 146 (73 right and 73 left) coronoid processes of mandibles. Damaged mandibles at coronoid process were excluded from the study. Sex of the mandible is determined using metric and nonmetric analysis. Bigonial and bicondylar width, flexion on the posterior surface of mandible, chin shape, and gonial eversion were considered in the sex determination (Figure 1). To control for inter-examiner and intra-examiner reliability, all the observations were performed by a single examiner.

OBSERVATIONS AND RESULTS

Three types of coronoid processes were observed.

- Hooked - Tip pointing backward
- Triangular - Tip pointing straight upward
- Rounded - Rounded tip

Access this article online



www.ijss-sn.com

Month of Submission : 06-2016
Month of Peer Review : 07-2016
Month of Acceptance : 08-2016
Month of Publishing : 08-2016

Corresponding Author: Dr. N S Sridevi, Department of Anatomy, Sri Devaraj Urs Medical College, Kolar, Karnataka, India.
Phone: +91-09741243683. E-mail: lalitha.anat@gmail.com

Hook shape was observed in 25 (17.12%) sides (Figure 2), triangular shape in 80 (54.7%) sides (Figure 3), and rounded in 41 (28.08%) sides (Figures 4 and 5).

In this study, 73.9% mandibles were showing bilateral symmetry and only 26.02% of mandibles were showing difference in the shapes in both sides (Table 1).

The triangular shape is predominant in males (68.18%) and rounded in females (39.65%). Hook shape is least common type in both male and females (Table 2, Figure 6).

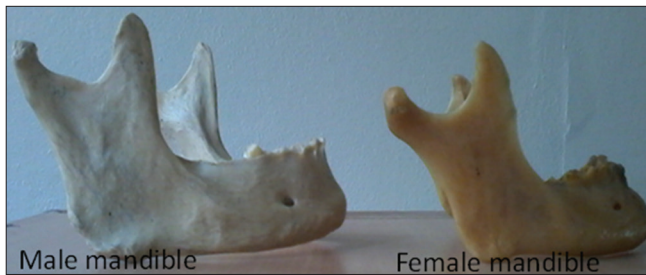

Figure 1: Male and female mandibles




Figure 2: Hooked coronoid process

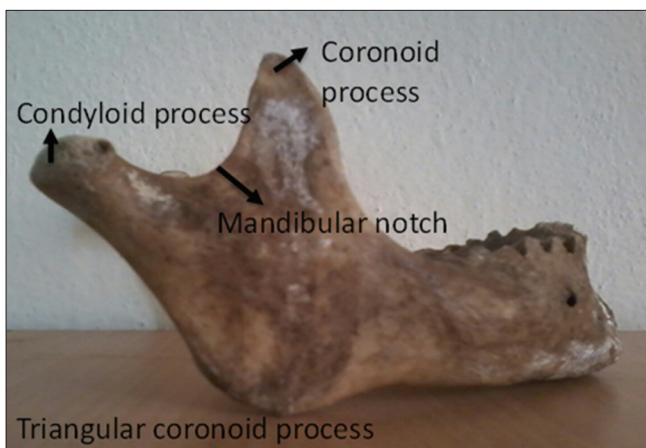


Figure 3: Triangular coronoid process

DISCUSSION

The variation in mandibular morphology of mammals reflects specialisations for different diets. Omnivorous and carnivorous mammals possess large mandibular coronoid processes, while herbivorous mammals possess smaller coronoid processes. This is correlated with the relative size of the temporalis muscle that forms an attachment to the coronoid process. The role of this muscle attachment in the development of the variation of the coronoid process is unclear. Anthwal *et al.* have done mouse knockout studies and demonstrated the initiation and growth of the coronoid process depends on two independent processes, with

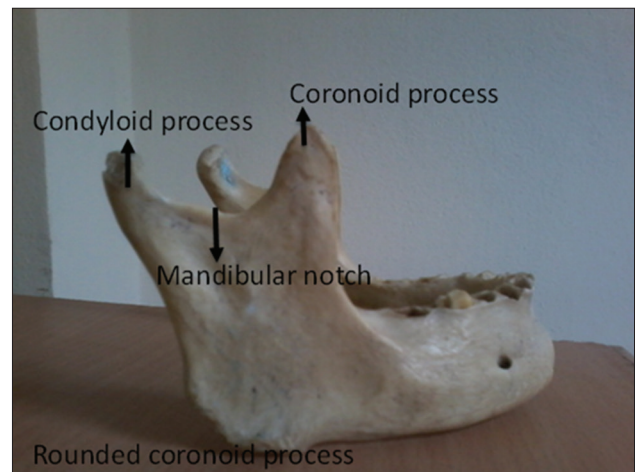


Figure 4: Rounded coronoid process

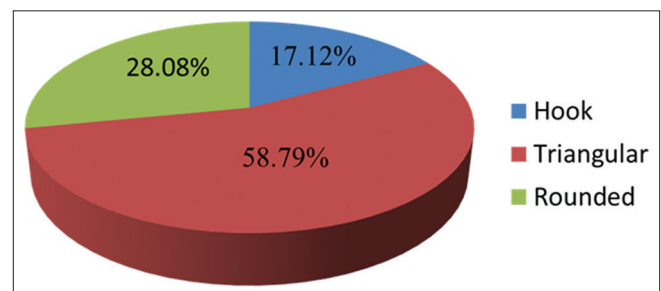


Figure 5: Pie chart showing the distribution of various shapes of coronoid process in adult human mandibles

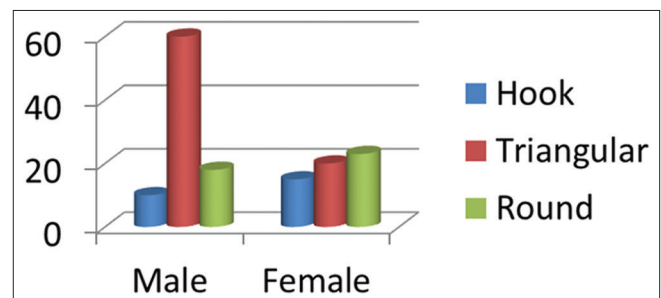


Figure 6: Bar diagram showing gender wise distribution of various types of coronoid process in adult human mandibles

Table 1: Distribution of various shapes of coronoid process in adult human mandibles

Type	Male				Female			
	Right	Left	Bilateral	Total	Right	Left	Bilateral	Total
Hook	2	4	2	10	2	1	6	15
Triangular	4	4	26	60	2	2	8	20
Rounded	10	0	4	18	5	2	8	23

Table 2: Gender difference observed in the shape of coronoid process

Gender/type	Hook	Triangular	Rounded
Male (n=88) (%)	10 (11.36)	60 (68.18)	18 (20.45)
Female (n=58) (%)	15 (25.86)	20 (34.48)	23 (39.65)

Table 3: Comparison of various studies on the shapes of coronoid process

Types of coronoid process	Triangular (%)	Hook (%)	Rounded (%)
Isaac (2001)	49	27.4	23.6
Akram Hossain <i>et al.</i> (2011)	29.65	45	25.35
Vipul <i>et al.</i> (2011)	54.17	24.58	21.25
Pradhan <i>et al.</i> (2014)	46.73	17.93	35.3
Present study (2015)	58.79	17.12	28.08

Table 4: Comparison of the variations in the shapes of coronoid process in relation to gender with other studies

Types of coronoid process	Triangular (%)		Hook (%)		Rounded (%)	
	Male	Female	Male	Female	Male	Female
Isaac (2001)	46.5	53.5	30	22.8	23.5	23.6
Hossain <i>et al.</i> (2011)	27.27	35.37	44.95	45.12	27.78	19.51
Vipul <i>et al.</i> (2011)	56	51.11	21.33	21.11	22.66	27.77
Pradhan <i>et al.</i> (2014)	45.83	47.72	21.87	13.63	32.29	38.63
Present study (2015)	68.18	34.48	11.36	25.86	20.45	39.65

initiation being intrinsic to the ossifying bone and growth dependent on the extrinsic effect of muscle attachment. A necessary component of the intrinsic patterning is identified as the paired domain transcription factor Pax9. He also demonstrated that Sox9 plays a role independent of chondrogenesis in the growth of the coronoid process in response to muscle interaction.⁹

The data of this study were compared with other studies. Table 3 shows the comparison of various studies on the shapes of the coronoid process.

Hook shape was highly prevalent in Bangladeshi population, whereas triangular is prevalent in Indians of different regions. Hook shape is least common in all the regions of India including this study. In this study, the order of prevalence from highest to lowest is triangular, rounded and hook which is similar with Pradhan *et al.*, and not matching with Isaac *et al.*, Vipul *et al.*, and Akram *et al.*^{6,10,11}

This study shows rounded shape is prevalent in females. Whereas other studies show triangular shape most prevalent in females. Akram *et al.* found hook shape as most prevalent in females of Bangladesh population (Table 4).⁶

CONCLUSION

The proper knowledge on the morphological shapes of coronoid process is useful for maxillofacial surgeons as it is used in reconstructions of orbital floor deformities, oro maxilla facial defects, and paranasal augmentation. Along with the other features of the skull these could be used as an anthropological marker to assess different populations and races.

REFERENCES

1. Standring S. Skeletal system. In: William PL, Bannister LH, Barry MM, Collins P, Dussek IE, Fergusson MW, editors. Gray's Anatomy: The

- Anatomical Basis of Medicine and Surgery. 40th ed. New York: Churchill Living Stone; 2008. p. 532.
2. Pradhan S, Bara DP, Patra S, Nayak S, Mohapatra C. Anatomical study of various shapes of mandibular coronoid process in relation to gender and age. *J Dent Med Sci* 2014;13:09-14.
 3. Sudha R, Chandrasekaran S, Aruna N. Study of morphological variations in the shapes of coronoid process of mandible in South Indian population. *IJCRR* 2013;5:84-90.
 4. Tapas S. Morphological variations of coronoid process in dry adult human mandibles. *Indian J Basic Appl Med Res* 2014;3:401-5.
 5. Nirmale VK, Mane UW, Sukre SB, Diwan CV. Morphological features of human mandible. *Int J Recent Trends Sci Technol* 2012;3:38-43.
 6. Hossain SM, Hossain SM, Banna FA. Variations in the shape of the coronoid process in the adult human mandible. *Bangladesh J Anat* 2011;9:75-8.
 7. Berry AC. Factors affecting the incidence of non-metrical skeletal variants. *J Anat* 1975;120:519-35.
 8. Mintz SM, Ettinger A, Schmamel T, Gleason MJ. Contralateral coronoid process bone grafts for orbital floor reconstruction: An anatomic and clinical study. *J Oral Maxillofac Surg* 1998;56:1140-4.
 9. Anthwal N, Peters H, Tucker AS. Species-specific modifications of mandible shape reveal independent mechanisms for growth and initiation of the coronoid. *Evodevo* 2015;6:35.
 10. Isaac B, Holla SJ. Variations in the shape of the coronoid Process in the adult human mandible. *J Anat Soc India* 2001;50:137-9.
 11. Prajapati VP. Variations in the morphological appearance of the coronoid process of human mandible. *Natl J Med Res* 2011;1:64-6.

How to cite this article: Lalitha B, Sridevi NS. Variations in the Shape of Coronoid Process of Indian Adult Dry Human Mandibles. *Int J Sci Stud* 2016;4(5):22-25.

Source of Support: Nil, **Conflict of Interest:** None declared.