

Role of Ultrasound as a Diagnostic Tool in Superficial Facial Space Infections

M Khaja Khalid Nawaz

Postgraduate Student, Department of Oral and Maxillofacial Surgery, Rajah Muthiah Dental College and Hospital, Annamalai University, Chidambaram, Tamil Nadu, India

Abstract

Background: The purpose of this study is to show the role of ultrasound as a diagnostic tool for superficial facial space infections. Plain radiographs, computed tomography (CT), magnetic resonance imaging (MRI) are valuable diagnostic aids. However, the CT scan and MRI are both expensive. Also, the CT scans expose the patient to relatively large doses of radiation and MRI is time - consuming and not suitable for every patient.

Materials and Methods: The study consists of 10 patients. Aspiration of pus was positive in 8 patients. In these cases, pus evacuation was the prime consideration. Incision and drainage has been planned under local anesthesia and other two patients were given appropriate antibiotic and anti-inflammatory drugs.

Results: In all the cases, the spread of infection was odontogenic in nature. Ultrasound was accurate in assuming the exact location, an extent of spread, presence of pus collection, and the ultrasound imaging were concordant with the other radiological investigations.

Conclusion: Ultrasonography is a safe investigatory and an inexpensive method in diagnosing superficial facial space infections.

Key words: Computed tomography, Magnetic resonance imaging, Ultrasonography

INTRODUCTION

Dental disease is the underlying cause of most of inflammatory swellings which occurs either in or around the jaws. Inflammation may commence at either the root apices or gingival margins of erupted teeth, or in the soft tissues which surround and overlie the crown of an unerupted or partially erupted tooth.¹⁻³ Inflammation around the apices of tooth root may result in the formation of pus. The pus tracks along the line of least resistance and perforates the bone at the site where it is thinnest and weakest and involves the surrounding soft tissues. Once the infection enters the tissues it may resolve, become localized or spread. These infections may range from superficial to deep neck

infections. The infections generally spread by following the path of least resistance through connective tissues and along facial planes. The infections spread to a site, distant to its origin, causing considerable morbidity and occasionally death.^{4,5}

Certain microorganisms produce spreading factors and spreading infections whilst others produce localizing factors and localizing infection.⁶ Thus, some Streptococci produce hyaluronidase, an enzyme which dissolves the intercellular cement substance and fibrinolysin which breaks down fibrin.^{7,8} The presence of these substances in the tissues will facilitate the spread of inflammatory process, some Staphylococci produce a substance called coagulase, which produces fibrin from plasma, which tends to localize the inflammatory lesion.¹ In cases of acute odontogenic infection, the oral and maxillofacial surgeon needs to know whether the inflammatory process is in a stage of abscess formation, requiring primary evacuation of pus and administration of antibiotics or a cellulitis that can generally be treated with antibiotics alone. It is often difficult to diagnose the stage of infection and to define its exact anatomic location. Plain

Access this article online



www.ijss-sn.com

Month of Submission : 06-2015
Month of Peer Review : 07-2015
Month of Acceptance : 07-2015
Month of Publishing : 08-2015

Corresponding Author: Dr. M Khaja Khalid Nawaz, New No - 11, Old No - 1/197, Lakshmanamudaliar Street, Sainathapuram, Vellore - 632 001, Tamil Nadu, India. Phone: +91 9952654408. E-mail: khalidnawazm@yahoo.com

radiographs, computed tomography (CT), magnetic resonance imaging (MRI) are valuable diagnostic aids. However, the CT scan and MRI are both expensive.⁹⁻¹² Also, the CT scans expose the patient to relatively large doses of radiation and MRI is time-consuming and not suitable for every patient.

An alternative diagnostic tool that is widely available, relatively inexpensive and non-invasive is ultrasonography (USG). High-resolution USG has recently been shown to be an effective tool to confirm pre-operatively any fluid collection or abscess in superficial facial spaces.¹³⁻¹⁸

In diagnostic ultrasound, highfrequency sound waves are transmitted into the body by a transducer and echoes from tissue interface are detected and displayed on a screen.⁵ The transducers are designed to produce longitudinal waves, hence, only those waves can pass through tissues get reflected, audio frequency of a sound wave is 20 KHz. Anything below this is called infrasonic and above this is ultrasound. Medical ultrasound uses the frequency of 1-15 MHz. The transducer has a special property called piezoelectric effect; they can convert sound waves into electrical waves and vice versa.

All body tissues except bone behave like liquids and, therefore, they all transmit sound at about some velocity, a velocity of 1540 m/sec is used as an average for body tissues. No echoes are returned by fluids and thus USG is very sensitive in detecting tissue fluid collection. Unlike radiography and MRI, adverse effects of USG are not yet been reported.¹⁹⁻²³

Aims

The aim of this study is to introduce inexpensive, non-invasive, non-radiation investigations in the diagnosis of superficial facial space infection.

Objectives

- To introduce a safe investigation method in diagnosing superficial facial space infections
- To find out an inexpensive method of investigation in superficial facial space infections
- To find out an alternative modality in the investigation to reduce the radiation exposure as in the case of radiographs, CT, and MRI
- To find out the difference between abscess and cellulitis
- To evaluate the extension of the swelling by using USG
- To subject the inflammatory swellings of the maxillofacial region with USG examination before a medical or surgical intervention
- To evaluate the usefulness of USG findings in the management of superficial facial space infections.

MATERIALS AND METHODS

The study was done in division of oral and maxillofacial surgery, Rajah Muthiah Dental College and Hospital, Annamalai University, Tamil Nadu, India. The study consists of 10 patients suffering from acute odontogenic infections of superficial facial spaces.

Inclusion Criteria

- Patients were of all age groups
- Patients are of both sexes
- Patients who were suffering from unilateral inflammatory swelling in the maxillofacial region of odontogenic origin.

Exclusion Criteria

- Patients with non-inflammatory swellings like soft tissue and bony cyst, tumors, and developmental anomalies
- The contralateral side of the patient with pathologies and variations most likely to show USG changes were excluded from the study
- Patients with parotid swellings were excluded from the study.

Patient Assessment

A proforma with a detailed history comprising of patient's demographic data, medical history was taken. A thorough clinical and radiological examination to locate the focus of infections should be done for all the patients, and then they were subjected to USG examination. Those agreeing to take part in the study will be asked to sign an informed consent form.

Ultrasound Examination

An ultrasound examination will be performed using a diagnostic ultrasound machine.⁹ The ultrasound probes will be covered with a disposable film for control of infection and then covered with a layer of ultrasound gel.¹¹ The probe will be positioned outside the mouth on the skin overlying the swelling. The position of the probe will be changed several times to obtain an adequate number of transverse scans (axial plane) and longitudinal scans (sagittal plane) to define the extent of the lesion. All the lesions will be measured in 3 planes; anteroposterior, superoinferior and mesiodistal and dimensions will be recorded. Color Doppler will be applied to the images to visualize the arteries and veins.¹³ No echoes are returned by fluids and thus USG is very sensitive in detecting fluid collection.

A tentative differential diagnosis will be based on the following principles:

1. Cellulitis: A poorly defined hypoechoic area, showing the scanty collection of fluids

2. Abscess: A hypoechoic area was showing diffuse margins filled with fluid and with no evidence of internal vascularization on color Doppler examination.

Procedure for USG Examination done in our Hospital

Position of patient

All examinations should be performed with the patient in the supine position.

Transducer used

A 10 MHz linear array probe and ultrasound transmission gel was used as a coupling agent. The transducer was directly applied over the skin, covering the suspected area in transverse and axial sections to determine the presence or absence of the fluid collection; if dimensions of the abscess cavity were present, depth from the skin surface up to the center of cavity and amount of collection were recorded.²¹

If ultrasound images showed no collection and only thickness of subcutaneous tissue and muscle involved were increased, then the diagnosis was made as cellulitis. In such cases, conservative management was of prime consideration. Any foci of infection if present were removed and patients were kept on supportive care to help their own body defenses in combating the infection.

When a collection was identified, diagnosis was made as an abscess. Dimensions of abscess cavity, amount of pus collected and depth of the center of abscess cavity from the skin surface were recorded.²³ Pus evacuation was then the prime consideration either by needle aspiration or by incision and drainage.

Methods

The study was successfully done in 10 patients. Aspiration of pus was positive in 8 patients. In these cases, pus evacuation was the prime consideration. Incision and drainage was done under left ventricular in these patients and other two patients were given appropriate antibiotic and anti-inflammatory drugs.

The ultrasound machine used in this study is Siemens and frequency was 10 MHZ (Table 1).

Case 1

USG findings: A well-defined hypoechoic foci of size 37 mm × 8 mm × 5 mm was seen below the body of the mandible in the superficial plane.

USG diagnosis: Abscess

Aspiration: Positive

Diagnosis: Right sub-mandibular space infection

Treatment done: Incision and drainage followed by extraction of the affected tooth (Figure 1 and 2).

Case 2

USG findings: A poorly defined hypoechoic foci with thickening of subcutaneous tissue was seen in the right buccal space region.

USG diagnosis: Cellulitis

Aspiration: Negative

Diagnosis: Cellulitis

Treatment done: Extraction of the affected teeth followed by medical management by antibiotic therapy (Figure 3 and 4).

RESULTS

In all the cases, the spread of infection was odontogenic in nature. Ultrasound was accurate in assuming the exact location of the infection, extent of spread, presence of pus collection,²¹ and the ultrasound imaging were concordant with the other radiological investigations. The usual ultrasound scan examination took <10 min, and none of the patients found the procedure painful or uncomfortable. We can conclude that USG is an inexpensive and non-invasive diagnostic technique that should be used to supplement clinical examination in patients with superficial facial space infection.

USG is valuable in diagnostic as well as therapeutic help in the management of superficial facial space infections.²⁸ Sometimes clinical diagnosis alone is difficult to differentiate between cellulitis and abscess; in such cases USG provides accurate imaging of the superficial structures of head and neck region, delimited medially by a bony skeleton. Compared to clinical examination, ultrasound is much superior in defining the exact location of abscess because of its real-time processing. Out of 10 cases, 8 cases were diagnosed ultrasonographically as abscess and 2 cases were diagnosed as cellulitis.

Graph 1 depicts the number of patients and it suggests male patients are more prone for infections rather than females.

Graph 2 depicts the USG findings; it was easier in differentiating between abscess and cellulitis.

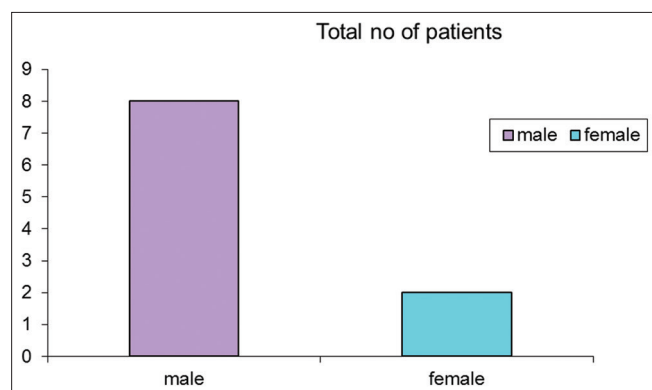
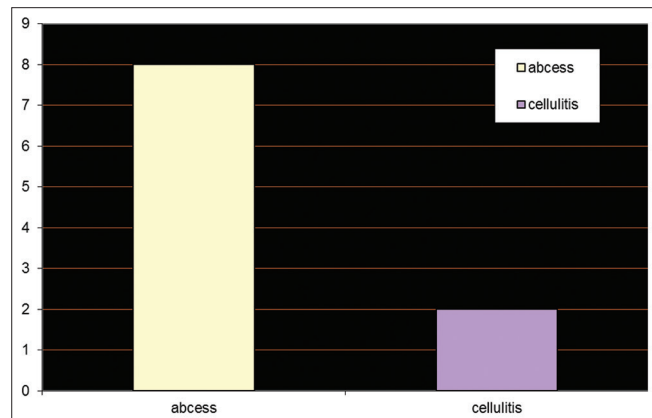
DISCUSSION

Odontogenic infections are one of the major sources of facial space infections in the head and neck region. The examination of inflammatory facial swellings is

Table 1: Total number of patients - 10

| Name | Age/sex | Investigations | Diagnosis | Treatment done | GA/LA |
|--------------|---------|----------------|------------|--|-------|
| Ananth | 22/M | USG | Abscess | Incision and drainage | LA |
| Vairam | 45/F | USG | Abscess | Incision and drainage | LA |
| Sachin | 14/M | USG | Abscess | Incision and drainage | LA |
| Govindarajan | 60/M | USG | Cellulitis | Conservative management by antibiotics | |
| Paneerselvam | 30/M | USG | Abscess | Incision and drainage | LA |
| Prabakaran | 43/M | USG | Abscess | Incision and drainage | LA |
| Rani | 45/F | USG | Abscess | Incision and drainage | LA |
| Thirumurugan | 14/M | USG | Abscess | Incision and drainage | LA |
| Arumugam | 26/M | USG | Abscess | Incision and drainage | LA |
| Velmurugan | 50/M | USG | Cellulitis | Conservative management by antibiotics | |

USG: Ultrasonography, LA: Left ventricular

**Graph 1: Total no of patients****Graph 2: Ultrasonographic findings**

largely restricted to clinical techniques of evaluation, such as inspection and palpation. However, because of the complicated anatomic structure of the head and neck, facial space infections are often difficult to be determined by clinical examinations alone. Techniques such as USG, CT, and MRI have revolutionized the field of diagnostic radiology.²⁴⁻²⁹ These powerful diagnostic tools have minimized the therapeutic dilemma for Dental surgeons. CT scanning and MRI are effective in diagnosing inflammatory conditions. The choice between these two techniques usually depends on the anatomic area involved. However, both techniques are expensive and

radio-invasive procedure. USG has several advantages over other modalities as it is harmless, uses no ionizing radiation, is widely available, easy-to-use, non-radio-invasive, inexpensive and unaffected by metal artifacts such as dental restorations.²⁹⁻³² It can be performed without heavy sedation.²³ Ultrasound causes no health problems.

Sonography was introduced in the medical field in the early 1950's. The steady development and upgrading of the ultrasound equipment has helped the medical field and now in oral and maxillofacial surgery as well.³³ In diagnostic ultrasound, high frequency sound waves are transmitted into the body by a transducer and echoes from tissue interface are detected and displayed on a screen. The transducers are designed to produce longitudinal waves, hence only those waves can pass through tissues and get reflected. Audio frequency of a sound wave is 20 KHz. Anything below this is called infrasonic and above this is ultrasound. Medical ultrasound uses the frequency of 1-15 MHz (2.5, 3.5, 7.5 and 10 MHz). The transducer has a special property called piezoelectric effect, i.e., they can convert sound waves into electrical waves and *vice versa*. USG examination of the inflammatory swelling was performed in cases of facial space infections. If ultrasound images showed no collection and only thickness of subcutaneous tissue and muscle involved were increased, then the diagnosis was made as cellulitis. When collection was identified, diagnosis was made as abscess. Dimensions of abscess cavity, amount of pus collected, and depth of the center of the abscess cavity from the skin surface were recorded. Pus evacuation was then the prime consideration either by needle aspiration or by incision and drainage.

Rega *et al.*,¹ conducted a study on microbiology and antibiotic sensitivities of head and Neck space infections of odontogenic origin and concluded that the bacteria were found to be 63.5% Gram-positive. Gram-positive cocci were isolated in 57.7% of specimens and Gram-negative rods were isolated in 33.0%. The most common bacteria isolated were Viridians streptococci, Staphylococci, and Peptostreptococcus.

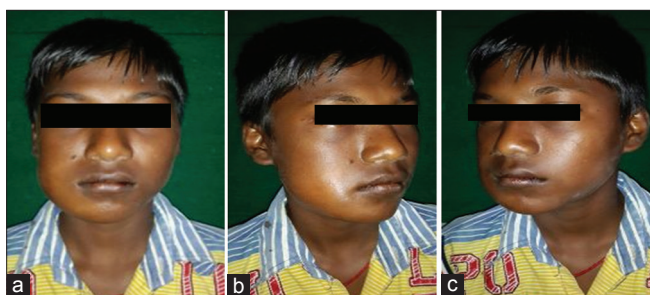

Figure 1: Ultrasonography

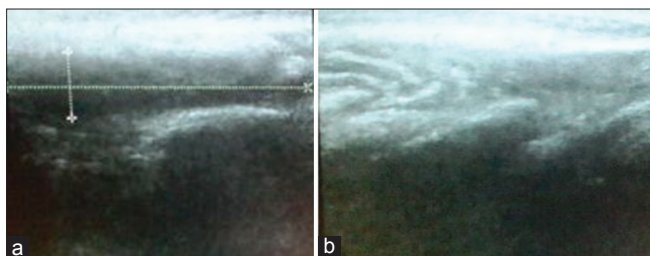


Figure 2: (a) Affected side, (b) Contralateral side

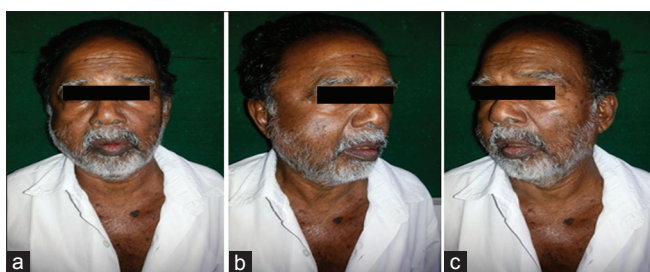

Figure 3: Ultrasonography (b) Contralateral side

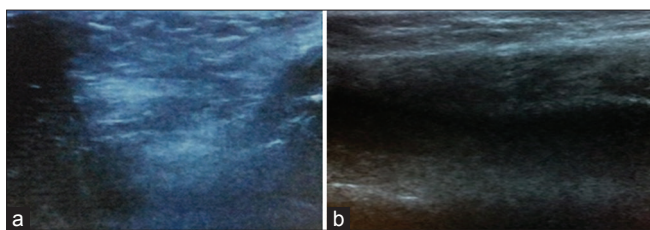


Figure 4: (a) Affected side, (b) Contralateral side

Chandak *et al.*,⁴ showed, out of 35 cases, 30 swellings were finally diagnosed as inflammatory swellings due to odontogenic origin by carrying out USG and surgical interventional investigations. Clinically diagnosed abscess cases shows highest percentage (60%) followed by edema cases (24%) and cellulitis (16%). USG diagnosed pre abscess cases shows highest percentage (60%) followed by edema cases (24%), cellulitis (8%) and abscess (8%). In 56% cases aspiration was positive and in 44 % aspiration was negative. Results showed that USG can be considered to be a valuable addition in diagnosis of inflammatory swellings of odontogenic origin. It can also demonstrate the stages of infections thus influencing the therapeutic

options of antibiotic and or anti-inflammatory medications and surgical drainage.

Baurmash *et al.*,⁹ conducted a study on 50 patients, with facial space infections involving the buccal and submandibular spaces. There was no parotid abscess included because of the difficulty of diagnosing the stage of infections. In our study, parotid swellings have been excluded which correlates with the study done by Baurmash *et al.*,⁹ whose management can be difficult and destructive because of density of parotid-masseteric fascia, the underlying gland parenchyma, and the proximity of the facial nerve.

Kesse *et al.*,¹⁷ described the technique of ultrasound guide the core biopsy in sum of 54 patients who presented with palpable lesions of parotid gland. Initial diagnostic ultrasound confirmed the presence of focal palpable lesions and identified additional Unpalpable lesions in seven patients. Core biopsy was 100 % accurate in differentiating benign and malignant disease. The diagnosis was accurate in 27 out of 28 patients who were subsequently operated. About 26 patients avoided an unnecessary surgical procedure. In our study, a total number of 10 patients with odontogenic origin of inflammatory swellings were included. The age of patients who participated in the study ranged from 10 to 50 years and there were 7 males and 3 females in the study. The condition of the subjects was diagnosed clinically. After clinical examination patient underwent USG investigation.

Bassiony and Yang *et al.*,²⁰ conducted a study on exploration of USG in assessment of facial space spread of odontogenic infections. The aim of this study was to explore the capability of USG as an alternative imaging modality to MRI in detection of facial space spread of odontogenic infections. The study consists of 42 facial spaces in 16 subjects, clinically diagnosed as odontogenic infections were included in this study. The results were confirmed by MRI and microbiological tests. USG demonstrated 32 of 42 involved facial spaces. There were 100% argument between USG and MRI on 32 superficial facial spaces, including 13 buccal, 10 submandibular, 5 canine, 2 sub-masseteric, and 2 sub lingual space involvements. USG was able to stage infection starting from edematous change to cellulitis to complete abscess formation. The results show that USG could be considered to be an effective method in detecting and staging spread of odontogenic infections to the superficial facial spaces. However, it might be difficult to detect deep facial space involvements.

Mallorie *et al.*,²³ conducted a study on 43 patients in which ultrasound had been used to look for evidence of pus collection. The management and treatment outcome of these patients were reviewed and data analyzed. 36 of

43 patients had their swelling incised in theatre and in 92% of these cases. USG and clinical findings corresponded, of the seven not taken to the theatre, four were USG negative and three were USG positive; in all seven cases the swelling resolved with antimicrobial therapy. Sensitivity and specificity of USG imaging to identify pus collections were high, 96% and 82% respectively. The evidence of this study indicates that USG is a very reliable diagnostic tool in the diagnosis of a collection as well as providing evidence that small collections of pus can resolve without surgical drainage.

Praveen *et al.*,²⁸ conducted a study on 25 patients with facial space infection in maxillofacial region were subjected to USG examination following a detailed clinical and radiological examination. Ultrasound guided needle aspiration was performed. Based on the findings, patients diagnosed with abscess were subjected to incision and drainage and those with cellulitis were subjected to medical line of treatment.

Oeppen *et al.*,²⁹ studied an overview of the use of ultrasound for facial space infection. Ultrasound is a relatively inexpensive, non-invasive, and readily available technique that is well tolerated by patients. It is particularly useful in the examination of superficial structures where the use of a high frequency linear probe (7.5-12 MHz) produces high definition multi-planar images. The spatial resolution achieved is superior to other methods of cross-sectional imaging.

Rahman and Hamimah *et al.*³⁰ conducted a study on clinical patterns of oro-facial infections. A total of 409 patients were included in this study. There were 258 (63.1%) males and 151 (36.9%) females. The incidence of oro-facial infections was highest in males rather than females.

A study was performed in 1987 by Siegert *et al.*³¹ in which USG scan was done for 394 patients. Of these 87% of patients had soft tissue Swellings due to odontogenic infections. The other swellings originated from a non-odontogenic region. Siegert *et al.*³¹ divided USG images into four different classes. Edema (4%), cellulitis (30%), preabscess (5%) and abscess (51%). Siegert stated that the sensitivity for diagnosing an abscess was the same for the clinical (93%) and the USG (95%) examinations. However, when only the specific diagnosis of abscess was considered, USG seemed to be slightly higher (82%) in sensitivity than the clinical diagnosis (69%). In the diagnosis of inflammatory swellings, USG seemed to be superior to the clinical diagnosis.

Kothrashetti *et al.*,³² conducted a study on 25 patients with facial space infections in maxillofacial region of odontogenic origin.

Topazian *et al.*³³ conducted a study on the etiology of the facial space infections and came to a conclusion that dental caries is the underlying cause of most of inflammatory swellings which occurs either in or around the jaws.

CONCLUSION

This study was conducted in the division of oral and maxillofacial surgery, Rajah Muthiah Institute of Health Science, Annamalai University.

Ten cases of superficial facial space infections were chosen in the age group of 10-80 years. USG was done to detect the spread of infection, extent of infection and presence of any pus collection and to diagnose whether the inflammatory swelling is abscess or cellulitis.

Based on the study, following conclusions were made:

- USG is a safe investigation method in diagnosing superficial facial space infections
- USG is an inexpensive method of investigation in superficial facial space infections
- USG is an alternative modality of investigation method to reduce the radiation exposure as in case of radiographs and CT
- USG helps in diagnosing whether the inflammatory swelling is abscess or cellulitis
- USG helps to evaluate the extension of the swelling
- USG helps to subject the inflammatory swellings of the maxillofacial region before medical or surgical intervention
- USG findings help to evaluate the usefulness in the management of superficial facial space infections
- USG is an easier method of investigation, as in case of not able to position the patient, especially with cervical spine injury and pregnant women
- USG is an effective method of investigation in diagnosis of superficial facial space infections.

ACKNOWLEDGMENTS

Author would like to thank professor, Dr. P. Srinivasan who helped him and supported author during the tenure of the study.

REFERENCES

1. Rega AJ, Aziz SR, Ziccardi VB. Microbiology and antibiotic sensitivities of head and neck space infections of odontogenic origin. *J Oral Maxillofac Surg* 2006;64:1377-80.
2. Hall A, Girkin JM. A review of potential new diagnostic modalities for caries lesions. *Journal of Dental Research* 2004;83(suppl 1), C89-C94.
3. Kaneoya A, Hasegawa S, Tanaka Y, Omura K. Quantitative analysis of

- invasive front in tongue cancer using ultrasonograph. *J Oral Maxillofac Surg* 2009;67:40-6.
4. Chandak R, Degwekar S, Bhowte RR, Motwani M, Banode P, Chandak M, *et al.* An evaluation of ultrasonography in the diagnosis of head and neck swellings. *J Oral Maxillofac Res* 2010;40:213-21.
5. Cotti E. Basic principle of ultrasound real time imaging. MI: Mosby Elsevier; 2011.
6. Cotti E, Campisi G. Advanced radiographic techniques for the detection of lesions in bone. *Endod Top* 2004;7:52-72.
7. Al-Belasy FA. Ultrasound guided drainage of submassetric space abscesses. *J Oral Maxillofac Surg* 2005;63:36-41.
8. Gillicher D, Krimmel M, Reinert S. The roles of intraoperative ultrasonography in zygomatic complex fracture repair. *Int J Oral Maxillofac Surg* 2006;35:224-30.
9. Baurmash HD. The use of ultrasonography in the diagnosis of facial abscess. *J Oral Maxillofac Surg* 1999;57:635-6.
10. Yusa H, Yoshida H, Ueno E, Onizawa K, Yanagawa T. Ultrasound guided surgical drainage of face and neck abscesses. *Int J Oral Maxillofac Surg* 2002;31:327-9.
11. Wilson IR. Introduction to ultrasonography in oral and maxillofacial surgery. *Oral Surg Oral Med Oral Pathol* 1985;59:235-41.
12. Wilson IR. Evaluation of ultrasonographic examination of head and neck regions as related to oral and maxillofacial surgery. *Oral Surg Oral Med Oral Path* 1989;67:242-8.
13. Olsen J, Papadaki M, Troulis M, Kaban LB, O'Neill MJ, Donoff B. Using ultrasound to visualize the lingual nerve. *J Oral Maxillofac Surg* 2007;65:2300-7.
14. Jimenez Y, Bagan JV, Murillo J, Poveda R. Odontogenic infections, Complications and Systemic manifestations. *Med Oral Patol Oral Cir Bucal* 2004;9:143-7.
15. Breeze J, Andi A, Williams MD. The use of fine needle core biopsy under ultrasound guidance in diagnosis of parotid mass. *Br J Oral Maxillofac Surg* 2008;47:78-80.
16. Breeze J, Williams MD, Howlett DC. Ultrasound guided localization during the excision of an impalpable branchial cyst. *Br J Oral Maxillofac Surg* 2008;46:686-7.
17. Mukai-Higashihori K, Baba Y, Tetsumura A, Tsuji M, Ishizaki T, Higashihori N, *et al.* Ultrasonographic assessment of new bone formation in maxillary distraction osteogenesis. *J Oral Maxillofac Surg* 2008;66:1750-3.
18. Kesse KW, Manjaly G, Violaris N, Howlett DC. Ultrasound guided biopsy in evaluation of focal lesions and diffuse swelling of parotid gland. *Br J Oral Maxillofac Surg* 2002;25:384-8.
19. Lauria L, Curi MM, Chammas MC, Pinto DS, Torloni H. Ultrasonography evaluation of bony lesions of the jaw. *Oral Surg Oral Med Oral Pathol Oral Radiol Endod* 1996;82:351-7.
20. Bassiony M, Yang J, Abdel-Monem TM, Elmogy S, Elnagdy M. Exploration of ultrasonography in assessment of facial space spread of odontogenic infections. *Oral Surg Oral Med Oral Radio Endod* 2009;107:861-9.
21. Mallorie CN, Jones SD, Drage NA, Shepherd J. The reliability of ultrasound in the identification of pus collections in head and neck swellings. *Int J Oral Maxillofac Surg* 2012;41:252-5.
22. Kodama M, Khanal A, Habu M, Iwanaga K, Yoshioka I, Tanaka T, *et al.* Ultrasonography for intraoperative determination of tumor thickness and resection margins in tongue carcinomas. *J Oral Maxillofac Surg* 2010;68:1746-52.
23. Peleg M, Heyman Z, Ardekian L, Taicher S. The use of ultrasonography as a diagnostic tool for superficial fascial space infections. *J Oral Maxillofac Surg* 1998;36:1129-31.
24. Balki M. Physics of ultrasound and image interpretation. *Soc Obstet Anaesth Perinatol* 2010;4:12-6.
25. Wakasugi-Sato N, Kodama M, Matsuo K, Yamamoto N, Oda M, Ishikawa A, *et al.* Advanced clinical usefulness of ultrasonography for diseases in oral and maxillofacial regions. *Int J Dent* 2010;2010:639382.
26. Mahabob N, Senthil KB. The role of ultrasound in dentistry. *JIADS* 2010;1:44-5.
27. Pfeiffer J, Ridder GJ. Diagnostic value of ultrasound guided core needle biopsy in patients with salivary gland masses. *Int J Oral Maxillofac Surg* 2002;41:437-43.
28. Praveen K, Umarani M, Kotrashetti S, Baliga S. Evaluation of ultrasonography as a diagnostic tool in maxillofacial space infections. *J Oral Maxillofac Res* 2011;2:e4.
29. Oeppen RS, Gibson D, Brennan PA. An update on the use of ultrasound imaging in oral and maxillofacial surgery. *Br J Oral Maxillofac Surg* 2010;48:412-8.
30. Rahman ZA, Hamimah H, Bunyarit SS. Clinical patterns of Oro-facial infections. *Ann Dent Univ Malaya* 2005;12:18-23.
31. Siegert R. The use of ultrasound in inflammatory soft tissue swellings of oral and maxillofacial regions as well as the neck. *J Oral Maxillofac Surg* 1987;45:842-6.
32. Kothrashetti S, Pandey PK, Umarani M, Baliga S. Evaluation of USG in facial space infections in maxillofacial region of odontogenic origin. *J Oral Maxillofac Res* 2011;2:e4.
33. Topazian RG, Goldberg MH, editors. Management of Infections of the Oral and Maxillofacial Regions. Philadelphia: WB Saunders Company; 1981.

How to cite this article: Nawaz MK. Role of Ultrasound as a Diagnostic Tool in Superficial Facial Space Infections. *Int J Sci Stud* 2015;3(5):41-47.

Source of Support: Nil, **Conflict of Interest:** None declared.