

# Role of Intra-operative Cytology in the Diagnosis of Ovarian Neoplasm's

Renu Jain<sup>1</sup>, Vibhor Jain<sup>2</sup>, Shyomali Dutta<sup>3</sup>, Seema Awasthi<sup>4</sup>, Sanjeev Kumar Jain<sup>5</sup>

<sup>1</sup>Assistant Professor, Department of Pathology, Teerthanker Mahaveer Medical College and Research Centre, Moradabad, Uttar Pradesh, India, <sup>2</sup>Consultant, National Program Officer HBS, Moradabad, Uttar Pradesh, India, <sup>3</sup>Professor & Head, Department of Pathology, Teerthanker Mahaveer Medical College and Research Centre, Moradabad, Uttar Pradesh, India, <sup>4</sup>Professor, Department of Pathology, Teerthanker Mahaveer Medical College and Research Centre, Moradabad, Uttar Pradesh, India, <sup>5</sup>Professor, Department of Anatomy, Teerthanker Mahaveer Medical College and Research Centre, Moradabad, Uttar Pradesh, India

## Abstract

**Background:** Intraoperative cytology (IOC) has been widely used nowadays for establishing an early diagnosis of ovarian neoplasms. It is a simple, inexpensive and a rapid diagnostic test which can be performed in a short duration of time. We organized a study to compare the diagnostic utility of IOC with the histopathological examination (gold standard technique) in ovarian benign and malignant neoplasms.

**Materials and Methods:** We conducted a prospective study on 68 suspected ovarian neoplasms and samples were collected using touch, imprint, scrape or crush technique. The samples were fixed by 95% ethyl alcohol and stained with hematoxylin and eosin stain. An experienced cytopathologist diagnosed and interpreted the cytology slides of ovarian neoplasm and correlated the histopathological diagnosis with cytological interpretation. Based on the data the sensitivity, specificity, positive predictive value, negative predictive value, and diagnostic accuracy were determined.

**Results:** Among the 68 cases, the standard histopathological diagnosis confirmed 24 as benign, 6 as borderline and 38 as malignant lesions. The diagnostic concordance between cytological and histopathological study was observed in 65 of the 68 cases. We observed a satisfactory diagnostic accuracy of the intraoperative imprint cytology (95.60%) in our study. The sensitivity, specificity, positive predictive value, negative predictive value, and diagnostic accuracy were 97.7, 91.37, 95.56, 95.65, and 95.60% respectively in our study.

**Conclusion:** The diagnostic utility of cytological examination for ovarian masses is really appreciable on comparison with the histological diagnosis.

**Key words:** Cytological diagnosis, Histopathological diagnosis, Ovarian neoplasm

## INTRODUCTION

Ovarian tumors are classified on the basis of their microscopic findings. The macroscopic features of the different ovarian cancers possess very much similarity.<sup>1</sup> Therefore, histopathologic findings helps in not only making a definitive diagnosis of the ovarian neoplasms but also helps in proper planning and management of the tumors.

Intraoperative cytology (IOC) is performed by taking imprint smears from the cancerous tissue and establishing an early diagnosis at the operation site.<sup>2</sup> In the past, frozen section was used traditionally but now imprint cytology has been proved to be an acceptable and easily reproducible technique as it is performed on other body organs also.<sup>3-7</sup> IOC is easy to perform, inexpensive, less tissue traumatic, and preservation of cell details.<sup>8</sup> IOC has also helped surgeons to establish the diagnosis at the operating site and after examining the cellular details of the tumor, they can plan proper marginal resection accordingly.

The diagnosis of ovarian neoplasms by Fine needle aspiration cytology (FNAC) is difficult to establish as the ovaries are a deep, structured organ and it causes difficulty for the needle to access the tumor site.<sup>9</sup> However, the

Access this article online



www.ijss-sn.com

**Month of Submission :** 06-2015  
**Month of Peer Review :** 07-2015  
**Month of Acceptance :** 07-2015  
**Month of Publishing :** 08-2015

**Corresponding Author:** Sanjeev Kumar Jain, Professor, Department of Anatomy, Teerthanker Mahaveer Medical College and Research Centre, Moradabad, Uttar Pradesh, India. Phone: +91-9997168754. E-mail: drskjain2005@rediffmail.com

imaging technique is required to make the pre-operative diagnosis by FNAC of ovarian tumours.<sup>10</sup> Moreover, excessive needling of the neoplastic tissue leads to spilling and seeding of the cancerous cells to the peritoneum.<sup>9</sup> But, IOC enables a prompt diagnosis without the fear of tumor dissemination.

The diagnosis of ovarian tumors by histopathological examination has been established as the gold standard technique. Based on the above advantageous role of IOC and limited literature availability of this technique for establishing the diagnosis of ovarian tumors, we planned to formulate a study comparing the diagnostic correlation of ovarian tumors between imprint cytology and histopathology.

### MATERIALS AND METHODS

We conducted a prospective study on 68 suspected ovarian neoplasms in Department of Pathology Teerthanker Mahaveer Medical College and Research Centre, Moradabad, India from January 2014 to December 2014. We included all the samples for our study which are solid/cystic-solid in consistency. Preoperatively, samples were collected using touch, imprint, scrape or crush technique. We employed touch and imprint technique most common whereby, the glass slide was touched with various representative areas. The samples from lesions of somewhat harder consistency were taken by scrape method. While performing scrape method, the tissue was scraped by the edge of one slide and smeared on another slide. The friable lesions were crushed and smeared gently between the two slides. The samples were fixed by 95% ethyl alcohol and stained with hematoxylin and eosin stain. Mucin was demonstrated by using Periodic-acid Schiff's or Alcian Blue stain. An experienced cytopathologist diagnosed and interpreted the cytology slides of ovarian neoplasm under the heads of types, pattern, and morphology of cells.

Since, histopathological diagnosis is considered as a gold standard of diagnosing the type of ovarian neoplasm, so we correlated the histopathological diagnosis with cytological interpretation.

### Statistical Analysis

The benign tumors were taken as negative control and malignant/borderline tumors as a positive control. True positives were cytology/histology positive tumors; true negatives were cytology/histology negative tumors; false positives histology negative and cytology positives; false negative was histology positive and cytology negative cases. The cases where pathologist felt difficulty in establishing a diagnosis were labeled as inconclusive. Statistical analysis

of data was performed by using SPSS version 20 software. Based on above parameters, positive predictive value, negative predictive value, and diagnostic accuracy were determined together with 95% confidence interval (CI).

### RESULTS

We successfully enrolled 68 cases, in our study. The cellularity and morphology of the cell structures were found to be better preserved with imprint/scrape smears. The age of the patients varied between 12 and 64 years, the mean age being 44 years. Among the 68 cases, the standard histopathological diagnosis confirmed 24 as benign, 6 as borderline and 38 as malignant lesions (Figures 1 and 2). Table 1 reveals the diagnostic concordance between cytological and histopathological study in 65 of the 68 cases. We observed prompt results by using hematoxylin and eosin staining technique. The better cytological and nuclear details were observed within 2 min.

We observed a satisfactory diagnostic accuracy of the intraoperative imprint cytology (95.60%) in our study. However, the imprint cytology does not correlated with 4.40% cases with the histological diagnosis. One case of mucinous cystadenoma on imprint cytology was diagnosed as a borderline mucinous tumor on histology, thus giving

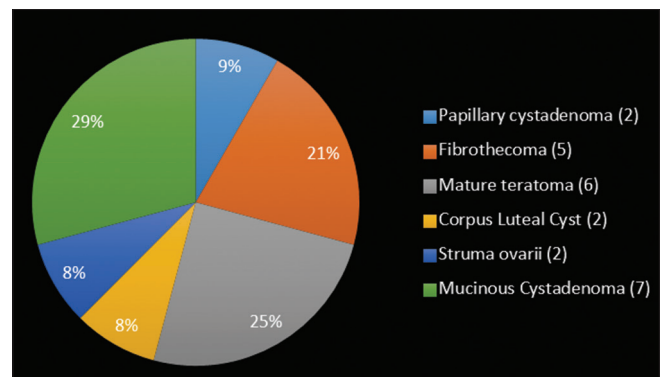


Figure 1: Benign ovarian tumors

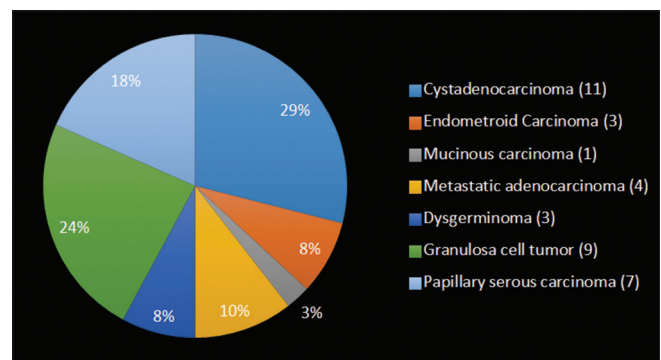


Figure 2: Malignant ovarian tumors

**Table 1: Cyto-histopathological correlation of ovarian neoplasms**

Cytological diagnosis	Number of cases	Histopathological diagnosis	Correlation (%)
Papillary cystadenoma	2	Papillary cystadenoma	2/2 (100)
Fibrothecoma	5	Fibrothecoma	5/5 (100)
Cystadenocarcinoma	11	Cystadenocarcinoma	11/11 (100)
Endometrioid Carcinoma	3	Endometrioid Carcinoma	3/3 (100)
Borderline mucinous tumor (5) mucinous cystadenoma (1) [FN]*	6	Borderline mucinous tumor	5/6 (83.3)
Mucinous carcinoma	1	Mucinous carcinoma	1/1 (100)
Mucinous Cystadenoma (5) borderline mucinous tumour (2) [FP]*	7	Mucinous cystadenoma	5/7 (71.4)
Metastatic adenocarcinoma	4	Metastatic adenocarcinoma	4/4 (100)
Dysgerminoma	3	Dysgerminoma	3/3 (100)
Granulosa cell tumor	9	Granulosa cell tumor	9/9 (100)
Mature teratoma	6	Mature teratoma	6/6 (100)
Papillary serous carcinoma	7	Papillary serous carcinoma	7/7 (100)
Corpus luteal cyst	2	Corpus luteal cyst	2 (100)
Struma ovarii	2	Struma ovarii	2 (100)
Total	68		65/68 (95.6)

\*FN: False negative, \*FP: False positive

one false negative case in our study. Moreover, two cases of mucinous cystadenoma were misdiagnosed as a borderline Mucinous tumor on cytological examination. This implies the two false positive cases.

Based on the above data, we derived the following parameters;

- Sensitivity: True positive/true positive + false negative = 97.7% (87.98% - 99.9%, 95% CI).
- Specificity: True negative/false positive + true negative = 91.37% (73.00% - 98.97%, 95% CI)
- Positive predictive value: True positive/true positive + false positive = 95.56% (84.85% - 99.46%, 95% CI)
- Negative predictive value: true negative/false negative + true negative = 95.65% (78.05% - 99.89%, 95% CI)
- Diagnostic accuracy: 65/68 = 95.60%.

## DISCUSSION

The intraoperative cytological examination was first introduced by Dudgeon and Patrick in 1927.<sup>11</sup> Since, then it has gained wide applicability and importance around the globe. By the help of this method, smears can be taken and examined and the diagnosis and management of various tumors can be made within a short period of time. We had performed Hematoxylin and Eosin staining and we were able to diagnose the smears in 2 min. Our findings were supported by Mair *et al.*<sup>5</sup> who also performed IOC within the same time frame of 2 min. Shahid *et al.*<sup>8</sup> further supported our study by performing IOC within 2 min and 23 s. However, Eltabbakh *et al.*<sup>12</sup> had taken 13 min for the same. Although, frozen section had been considered a gold standard for making diagnosis of ovarian malignant tumors but because of ovarian tumors large size, different pathological patterns, and more time consuming, it has been gradually replaced by IOC.<sup>13</sup>

Of all the 68 cases observed, 24 were non-neoplastic lesions. Out of these 24 benign tumors, we observed most of the cases (7) of mucinous cystadenoma on histological examination. On cytological examination, two cases were misdiagnosed as a borderline mucinous tumor. Our findings were supported by Shahid *et al.*<sup>8</sup> who also found one false positive case while examining mucinous cystadenoma. This result was found, as we observed very minimal nuclear atypia with increased nuclear: cytoplasmic ratio. One case of Borderline mucinous tumor was misdiagnosed as mucinous cystadenoma on cytological examination. However, we were able to interpret mucinous carcinoma on both cytological and histological examination accurately.

In our study, we were able to diagnose papillary benign and malignant tumors accurately on both cytological and histopathological examinations. Our study was also supported by Vijayakumar<sup>14</sup> who demonstrated 100% correlation between cyto-/histological findings of papillary cystadenoma and papillary cystadenocarcinoma.

On examining the germ cell tumors, 9 cases of granulosa cell tumors, 3 cases of dysgerminoma and 6 cases of mature teratoma was accurately diagnosed by cytological examination. Our findings were supported by Shahid *et al.*<sup>8</sup> and Khunamornpong and Siriaunkgul<sup>15</sup>, who also found 100% diagnostic accuracy of cytological examination in detecting germ cell tumors. In our study, endometrioid carcinoma was observed to be cytologically similar to serous tumours but we had successfully correlated our three cases of endometrioid carcinoma.

The sensitivity, specificity, positive predictive value, negative predictive value and diagnostic accuracy were 97.7, 91.37, 95.56, 95.65 and 95.60%, respectively in our study. Shahid *et al.*<sup>8</sup> in their cytological and histological ovarian tumours correlated study observed sensitivity, specificity and

diagnostic accuracy of 95.8, 96.0 and 95.8% respectively. However, they did not observe the positive and negative predictive values in their study. They also observed 2% of the results as inconclusive, however, no inconclusive results were observed in our cases. In a study conducted by Nagai *et al.*<sup>16</sup> between malignant/borderline/benign ovarian tumours they observed the sensitivity, specificity and diagnostic accuracy as 89.5, 90.3 and 83.6% respectively. Ganjei<sup>10</sup> compared the benign and malignant ovarian cysts by aspiration cytology and observed the sensitivity (75%), specificity (100%) and diagnostic overall accuracy (96%) in their study. Kjellgren *et al.*<sup>17</sup> observed a sensitivity, specificity and diagnostic accuracy of 90, 85, and 93-95% in their study on ovarian tumours by fine needle aspiration biopsy.

The frozen section had been considered as a gold standard for establishing the diagnosis of ovarian neoplasms. One of our limitations in our study is that we should have compared frozen section with IOC smears. But a recent meta-analysis of 18 studies compared the sensitivity and specificity of ovarian neoplasms between frozen section and histopathology and observed similar observations as ours.<sup>18</sup> Other limitation of IOC is that it is difficult to make a proper diagnosis of ovarian tumours with borderline malignant potential and in such cases we advocate that the diagnosis should be relied upon the histopathological findings.

## CONCLUSION

From our study, we conclude that the diagnostic accuracy of cytological examination of ovarian masses is really appreciable. Moreover, in a developing country like ours where the facility of frozen section techniques is not available, cytological examination plays a key role in making an early and accurate diagnosis. IOC is a simple, rapid, inexpensive, and easy to perform the procedure and thus helpful in making an early preliminary diagnosis of ovarian tumors thereby helpful in the timely start of patient treatment.

## REFERENCES

1. Chen VW, Ruiz B, Killeen JL, Coté TR, Wu XC, Correa CN. Pathology and classification of ovarian tumors. *Cancer* 2003;97:2631-42.
2. Jaafar H. Intra-operative frozen section consultation: Concepts, applications and limitations. *Malays J Med Sci* 2006;13:4-12.
3. Suen KC, Wood WS, Syed AA, Quenville NF, Clement PB. Role of imprint cytology in intraoperative diagnosis: Value and limitations. *J Clin Pathol* 1978;31:328-37.
4. Kontozoglou TE, Cramer HM. The advantages of intraoperative cytology. Analysis of 215 smears and review of the literature. *Acta Cytol* 1991;35:154-64.
5. Mair S, Lash RH, Suskin D, Mendelsohn G. Intraoperative surgical specimen evaluation: Frozen section analysis, cytologic examination, or both? A comparative study of 206 cases. *Am J Clin Pathol* 1991;96:8-14.
6. Clarke MR, Landreneau RJ, Borochoviz D. Intraoperative imprint cytology for evaluation of mediastinal lymphadenopathy. *Ann Thorac Surg* 1994;57:1206-10.
7. Rahman K, Asif Siddiqui F, Zaheer S, Sherwani MK, Shahid M, Sherwani RK. Intraoperative cytology: Role in bone lesions. *Diagn Cytopathol* 2010;38:639-44.
8. Shahid M, Zaheer S, Mubeen A, Rahman K, Sherwani RK. The role of intraoperative cytology in the diagnostic evaluation of ovarian neoplasms. *Acta Cytol* 2012;56:467-73.
9. Uguz A, Ersoz C, Bolat F, Gokdemir A, Vardar MA. Fine needle aspiration cytology of ovarian lesions. *Acta Cytol* 2005;49:144-8.
10. Ganjei P. Fine-needle aspiration cytology of the ovary. *Clin Lab Med* 1995;15:705-26.
11. Dudgeon LS, Patrick CV. A new method for rapid microscopical diagnosis of tumors: With an account of 200 cases so examined. *Br J Surg* 1927;15:250-26.
12. Eltabbakh GH, Trask CE. Scrape cytology for intraoperative evaluation of lymph nodes in gynecologic cancer. *Obstet Gynecol* 2000;95:67-71.
13. O'Hanlan KA. Principles of surgical management of ovarian carcinomas. *Pathology (Phila)* 1993;1:477-89.
14. Vijayakumar A. The diagnostic utility of intraoperative cytology in the management of ovarian tumours. *J Clin Diagn Res* 2013;7:1047-50.
15. Khunamornpong S, Siriaunkgul S. Scrape cytology of the ovaries: Potential role in intraoperative consultation of ovarian lesions. *Diagn Cytopathol* 2003;28:250-7.
16. Nagai Y, Tanaka N, Horiuchi F, Ohki S, Seki K, Sekiya S. Diagnostic accuracy of intraoperative imprint cytology in ovarian epithelial tumors. *Int J Gynaecol Obstet* 2001;72:159-64.
17. Kjellgren O, Angström T, Bergman F, Wiklund DE. Fine-needle aspiration biopsy in diagnosis, and classification of ovarian carcinoma. *Cancer* 1971;28:967-76.
18. Geomini P, Bremer G, Kruitwagen R, Mol BW. Diagnostic accuracy of frozen section diagnosis of the adnexal mass: A metaanalysis. *Gynecol Oncol* 2005;96:1-9.

**How to cite this article:** Jain R, Jain V, Dutta S, Awasthi S, Jain SK. Role of Intra-operative Cytology in the Diagnosis of Ovarian Neoplasm's. *Int J Sci Stud* 2015;3(5):72-75.

**Source of Support:** Nil, **Conflict of Interest:** None declared.