Print ISSN: 2321-6379
Online ISSN: 2321-595X
DOI: 10.17354/ijss/2017/398

Original Article

Post Punch Graft Appearance of Repigmentation Time in Stable Vitiligo: A Retrospective Study

Muthukumaran Rajaram[1], Sudha Alagarsamy[2], Subashini Sundarapandiyan[2]

[1]Associate Professor, Department of Dermatology, Government Theni Medical College, Theni, Tamil Nadu, India, [2]Assistant Professor, Department of Dermatology, Government Theni Medical College, Theni, Tamil Nadu, India

Abstract

Introduction: Vitiligo, characterized by depigmented macules is a common disorder with a high psychosocial impact, particularly in darker skins. Surgical methods become important in cases where medical therapy fails to cause repigmentation. The basic principle of surgical treatment is autologous grafting of viable melanocytes from pigmented donor skin to recipient vitiliginous areas. Punch skin graft it is a simple, safe, inexpensive, and quickly responding technique.

Materials and Methods: A retrospective study was conducted in 25 cases of punch skin grafts in stable vitiligo. Age, sex, type of vitiligo, distribution of lesions in various regions of body, and appearance of repigmentation (AOR) time in weeks were analyzed. The study was conducted in the Department of Dermatology, Theni Medical College, Theni, from the data collected from the records of the patients.

Results: A total number of 272 grafts were placed over 15 various regions of body in 25 cases of stable vitiligo patients. The AOR time was quicker in mucosal followed by segmental, focal, and acrofacial vitiligo and was quicker in lips, infraclavicular, and parasternal areas followed by other areas.

Discussion: In our study, we noticed the AOR time is 3.9 weeks (29 days), in parallel with the national and international studies. The sun exposed and highly vascular areas such as lips, nose, scalp, cheek, maxillary area, mandibular, upper interscapular area, and infraclavicular area got the onset pigments very quick when compared to sun hidden and less vascular areas.

Key words: Appearance of repigmentation time, Punch skin graft, Stable vitiligo

INTRODUCTION

Vitiligo is a common depigmenting disorder, characterized clinically by milky white macules and histologically by an absence of functional melanocytes in the affected area. It causes severe cosmetic distress, particularly in darkly pigmented skins and is also associated with a great social stigma. It has a profound psychological impact and greatly affects the quality of life.[1] In 1947, Haxthausen transplanted thin split thickness skin grafts from normal to vitiliginous skin in three cases, to study the pathogenesis of the disease.[2,3] In 1964, Behl from India was the first to describe the surgical treatment of vitiligo in a large series of 107 patients with thin Thiersch grafts.[4,5] Falabella described the suction blister technique for repigmentation of vitiligo in 1971, and later the miniature punch grafting technique in 1978.[6] The basic principle of all surgical methods is transfer of melanocytes from uninvolved skin into a stable leukoderma lesion, where they grow into, and function as, effective epidermal melanin units. "Donor dominance" principle states that, when a graft from normal skin is transplanted to an affected site, the transposed grafted area maintains its integrity and characteristics, independent of the recipient site. When a normal pigmented donor auto punch graft is transplanted onto a depigmented stable vitiligo area, it dominates, and the melanocytes in the mini grafts not only continue to produce melanin but also migrate into the adjacent depigmented epidermis; seen clinically as initial perigraft pigmentation.[7] Various grafting methods have been described including tissue grafts and cellular grafts. Still, in this era of cellular grafts, punch skin

Access this article online

IJSS
www.ijss-sn.com

Month of Submission : 06-2017
Month of Peer Review : 07-2017
Month of Acceptance : 08-2017
Month of Publishing : 08-2017

Corresponding Author: Dr. R Muthukumaran, Department of Dermatology, Government Theni Medical College, Theni, Tamil Nadu, India. E-mail: muthu64@yahoo.com

graft stands the best for the reason that it is a simple, safe, inexpensive, quickly responding technique with high success rate of repigmentation with no concerns of tumorigenic potentials of some techniques, whereas cellular grafts are expensive, time-consuming and having tumorigenic potentials of some techniques with advantage of smaller donor tissue covering larger recipient area.[8]

MATERIALS AND METHODS

A retrospective study was conducted in 25 cases of punch skin grafts in stable vitiligo. The cases done by the author were collected with case records, and photographs and results were analyzed in the point of age, sex, type of vitiligo, distribution of lesions in various regions of the body, and appearance of repigmentation (AOR) time. The study was conducted in the Department of Dermatology, Theni Medical College, Theni, Tamil Nadu.

A selection criterion was followed while selecting the cases for punch skin graft procedure.

1. "Stable vitiligo" which is stationary and without the development of new lesions in the past 2 years.
2. Patients in whom the lesions were not improving in spite of long medical management.
3. Patients with no history of Koebner phenomenon in the lesions.
4. Patients who do not have keloidal tendency.
5. Patients with no history of bleeding diathesis.

Out of 25 cases of stable vitiligo, 9 were male and 16 were female. Young females were more in the below 20 years age group. Lowest age was 12 years and the upper limit was 50 years (Table 1). On evaluating the types of vitiligo, 15 cases were focal vitiligo, 6 cases were segmental vitiligo, 2 cases were mucosal vitiligo, and 2 cases were acrofacial type (Table 2). The cases which had underwent the following methodology were selected for the study.

Cases were selected according to the selection criteria. Vitiligo lesions of more than 2 years duration with no new depigmentary lesions were considered as "Stable vitiligo." The patients having a history of Koebnerization, Keloidal tendency, or bleeding diathesis were excluded from selection. Punch graft kit consisted of 2,2.5 mm punches, graft holding curved forceps, Double curved "S" shaped scissors, graft taking forceps, spreader, stainless steel bowel for harvested grafts, normal saline, framycetin tulle dressing, 1% lignocaine, disposable needle and syringe, cotton, gauge, plaster, and autoclavable aluminum container. 2.5 mm punches are used in donor area and rotated down to the depth of the upper dermis, and required grafts were harvested from the donor area. 2 mm punches are rotated down to mid dermis approximately 1-1.5 mm in depth, and the achromic grafts are taken and discarded. The normal skin grafts already stored were transferred to these punched sites with the assurance of dermal side down by assessing the glistening surface. Spreader is used to spread the grafts. Firm pressure with moist gauze was applied to achieve homeostasis and for a snug fit. Dressing was done with a double layer of framycetin tulle, gauze, and plaster.

Photographs were taken prior and soon after the procedure with grafts *in situ* and periodically after every 15 days for 2 months and there after every 1 month till the end of 1 year. Patients were requested to report the time of AOR in each case and were recorded in region wise manner and mean was calculated (Table 3).

RESULTS

A total number of 272 grafts were placed over 15 various regions of the body in 25 cases of stable vitiligo patients. Few grafts were displaced from the recipient sites due to trauma during dressing. Otherwise, all the grafts were well taken. In our study, regarding the AOR time, it was quicker in mucosal followed by segmental, focal, and acrofacial vitiligo. Moreover, the AOR time was quicker in lips (2 weeks), followed by upper interscapular area, nose, (2.5 weeks), infraclavicular (3 weeks), (Figures 1-7), parasternal area (3 weeks), cheek (3.5 weeks), maxillary area (3.5 weeks), medial malleolus (4.5 weeks), scalp (4 weeks), forehead (4 weeks), and mandibular area (4 weeks dorsum of hand [4 weeks], fingers [4 weeks], and leg [4 weeks]). The overall mean was calculated as 3.9 weeks that is 27 days (Table 3).

Table 1: Age and sex distribution

Age group (year)	10-20 years		21-30 years		31-40 years		41-50 years	
	Male	Female	Male	Female	Male	Female	Male	Female
Focal	1	7	2	1	-	3	-	1
Segmental	1	-	2	2	-	1	-	-
Mucosal	1	-	-	-	-	-	1	-
Acrofacial	1	1	-	-	-	-	-	-
Total	4	8	4	3	0	4	1	1

Table 2: Type of vitiligo

Type of vitiligo	Number of cases
Focal	15
Segmental	6
Mucosal	2
Acrofacial	2
Total	25

Table 3: Distribution of region and AOR time in weeks

Site of vitiligo	AOR in weeks
Scalp	4
Forehead	4
Nose	3
Cheek	3.5
Maxillary area	3.5
Mandibular area	4
Lip	2
Infraclavicular area	3
Upper interscapular area	2.5
Parasternal area	3
Lumbar	5
Dorsum of hand	4
Fingers	4
Leg	4
Medial malleolus	4.5

Mean = 3.9 weeks (27 days). AOR: Appearance of repigmentation

Figure 1: Before punch skin graft infraclavicular

Figure 2: 8 days after grafting

Figure 3: Closure view after 8 days

Figure 4: Infraclavicular punch grafts after 21 days (3 weeks)

DISCUSSION

The onset of repigmentation (AOR) time was noted and explained by so many authors. Falabella while treating segmental vitiligo observed gradual repigmentation around each autologous mini grafts and ultimate coalescence after 2-3 months. In stable leukoderma, he noticed gradual repigmentation until coalescence in 3-4 months.[9] The first specific mention about AOR time came in 1989 when Falabella observed pigment spread about 1 month after surgery, and full repigmentation in 3-6 months.[10] Among the Indian authors, savant depicted uniform perigraft melanin pigment by 1-1.5 months, in his study.[11] Lahari and Sengupta noticed the AOR time as 21.6 days that is 3.1 weeks.[12,13] In our study, we noticed the AOR time as

Figure 5: Closure view infraclavicular punch graft after 21 days (3 weeks)

Figure 6: Infraclavicular punch grafts after 3 months

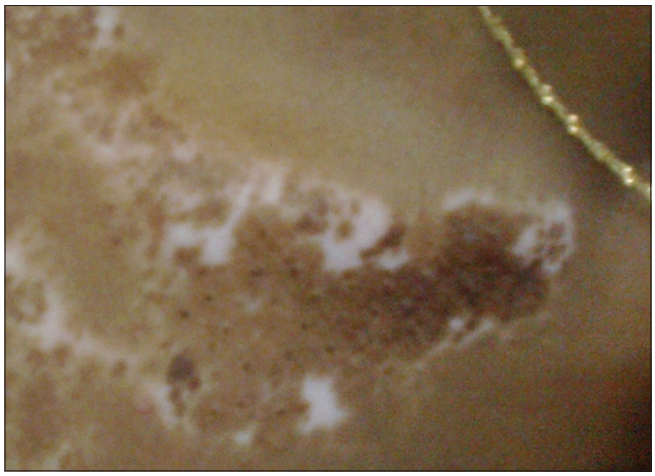

Figure 7: Closure view infraclavicular punch after 3 months

3.9 weeks (29 days) which is little higher than the study conducted by Lahari and Sengupta and near the value of Falabella.[10,12,13] Sun exposed areas such as lips, nose, scalp, cheek, maxillary area, mandibular, upper interscapular area, and infraclavicular area got the onset pigments very quick when compared to the sun hidden areas such as lumbar, leg and leg medial malleolus areas. Highly vascularized, non glabrous (hairy) areas such as parasternal area, supraclavicular area, scalp, lips, cheek, and fore head areas got the repigmentation quick when compared to nonhairy and less vascular areas like leg and ends of long bones area like lower leg (medial malleolus).

CONCLUSION

Punch skin graft technique stands the best for the reason that it is a simple, safe, inexpensive, quickly responding office procedure with high success rate of repigmentation and no concerns of tumorigenic potentials of some techniques. Finally, being an extended biopsy technique, no special training is required. The onset of repigmentation time depends not only on the stability of vitiligo but also on the vascularity of the area of depigmentation and the presence of sun exposure in the area.

REFERENCES

1. Parsad D, Dogra S, Kanwar AJ. Quality of life in patients with vitiligo. Health Qual Life Outcomes 2003;1:58.
2. Falabella R. History and chronology of development of surgical therapies for vitiligo. In: Gupta S, Olsson MS, Kanwar AJ, Ortonne JP, editors. Surgical Management of Vitiligo. 1st ed. Massachusetts, USA: Blackwell Publishing; 2007. p. 41-8.
3. Savant SS. Surgical therapy of vitiligo: Current status. Indian J Dermatol Venereol Leprol 2005;71:307-10.
4. Behl PN. Treatment of vitiligo with homologous thin Thiersch grafts. Curr Med Pract 1964;8:218-21.
5. Falabella R. Epidermal grafting. An original technique and its application in achromic and granulating areas. Arch Dermatol 1971;104:592-600.
6. Falabella R. Repigmentation of leukoderma by minigrafts of normally pigmented, autologus skin. J Dermatol Surg Oncol 1978;4:916-9.
7. Savant SS. Minature punch grafting. In: Savanth SS, Shah RA, Gore D, editors. Text Bool and Atlas of Dermatosurgery and Cosmetology. 1st ed. Mumbai, India: ASCAD Publishers; 1998. p. 235-6.
8. Mysore V, Salim T. Cellular grafts in management of leucoderma. Indian J Dermatol 2009;54:142-9.
9. Falabella R. Repigmentation of segmental vitiligo by autologous minigrafting. J Am Acad Dermatol1983;9:514-21.
10. Falabella R. Grafting and transplantation of melanocytes for repigmenting vitiligo and other types of leukoderma. Int J Dermatol 1989;28:363-9.
11. Savanth SS. Autologous miniature punch skin grafting in stable vitiligo. Indian J Dermatol Venereol Leprol 1992;58:310-4.
12. Lahari K, Sengupta SR. A region wise comparative study of the extent of post punch surgical repigmentation in cutaneous achromia. Indian J Dermatol Venereol Leprol 1998;64:173-5.
13. Lahari K, Sengupta SR. A region wise comparative study of post punch graft appearance of repigmentation: AOR time in cutaneous achromia. Indian J Dermatol 1998;43:13-5.

How to cite this article: Rajaram M, Alagarsamy S, Sundarapandiyan S. Post Punch Graft Appearance of Repigmentation Time in Stable Vitiligo: A Retrospective Study. Int J Sci Stud 2017;5(5):81-84.

Source of Support: Nil, **Conflict of Interest:** None declared.