

Anthropometry: A Comparative Study of Right and Left Sided Foramen Ovale, Jugular Foramen and Carotid Canal

Mohammad Muzammil Ahmed¹, Mohammed Jeelani², Arshiya Tarnum³

¹Assistant Professor, Department of Anatomy, Navodaya Medical College, Raichur, Karnataka, India, ²Tutor, Department of Physiology, Employees State Insurance Corporation Medical College, Gulbarga, Karnataka, India, ³Junior Resident, Department of Paediatrics, Employees State Insurance Corporation Medical College, Gulbarga, Karnataka, India

Abstract

Introduction: The sphenoid bone contains numerous foramina and fissures, which accommodate several vessels and nerves. One of these is the foramen ovale. Normally the foramen ovale is located in the greater wing of the sphenoid bone, posterior and lateral to the foramen rotundum, the jugular foramen (JF) is formed by the edge of the occipital bone forming the jugular notch, and the petrous temporal bone is excavated to form jugular fossa, carotid canal is the passage way in the temporal bone. The canal starts on the inferior surface of the temporal bone at the external opening of the carotid canal also called as the carotid foramen.

Materials and Methods: In this study, the distance of the foramen ovale, JF and external opening of the carotid from the midline, the anteroposterior diameter, the transverse diameter and the area of the foramina were measured.

Observation and Results: When compared to right and left sides for the individual foramen showed no statistical significance. The mean combined area (CA) of the foramen ovale was found to be 35.5 mm² and 22.4 mm² in males and females, respectively. The mean CA for JF was 170.89 mm² and 125.5 mm² in males and females, respectively, and the mean CA for the carotid canal was 59.55 mm² and 43.25 mm² in males and females, respectively. The CA of the foramen ovale and external opening of the carotid canal were used to find the limiting points (LP). The LP is 47.5 mm² and 31 mm² for foramen ovale and external opening of the carotid canal. The skulls are having CA lesser than the LP were classified as female skulls. Of the 100 skulls studied 83 skulls were classified as male skulls, 12 skulls were classified as female skulls and the remaining 5 skulls had overlapping values of the LP, and therefore, unclassified.

Conclusion: The need for familiarity with the detailed Anatomy of the foramina under study and their variations are very much essential in microsurgical techniques as many extracranial and intracranial lesions including intrinsic anomalies may affect the foramina.

Key words: Carotid canal, Foramen ovale, Jugular foramen, Morphometry, Skull base foramina

INTRODUCTION

The sphenoid bone contains numerous foramina and fissures, which accommodate several vessels and nerves. One of these is the foramen ovale, which serves as a

passage for the mandibular nerve, accessory meningeal artery and the lesser petrosal nerve. Normally, the foramen ovale is located in the greater wing of the sphenoid bone, posterior and lateral to the foramen rotundum.^{1,2}

The foramen ovale is important in functional cranial anatomy and neurosurgeries as it enables access to the trigeminal nerve.

It is situated in the transition zone between intracranial and extracranial structures. Therefore, it is used for various invasive surgical, as well as diagnostic procedures. Electroencephalographic analysis of seizure by an electrode

Access this article online



www.ijss-sn.com

Month of Submission : 06-2015

Month of Peer Review : 07-2015

Month of Acceptance : 07-2015

Month of Publishing : 08-2015

Corresponding Author: Dr. Mohammad Muzammil Ahmed, H. No. 5 - 810, Chota Roza, Darga Road, Gulbarga - 585 104, Karnataka, India. Phone: +91-09739306075. E-mail: drmuz12@gmail.com

placed at foramen ovale is done. Foramen ovale electrode technique provided good neurophysiological information in a candidate for selective amygdalohippocampectomy.

The jugular foramen (JF) is formed by the edge of the occipital bone forming the jugular notch, and the petrous temporal bone is excavated to form jugular fossa, which accommodates the superior bulb of internal jugular vein. The JF may be partially or completely divided into three compartments by small spicules of bone.

The anteromedial compartment transmits inferior petrosal sinus and meningeal branch of ascending pharyngeal artery, middle compartment contains tympanic branch of glossopharyngeal nerve (Jacobson's nerve), the auricular branch of Vagus nerve (Arnold's nerve) and eleventh cranial nerves (CN) and the cochlear aqueduct.³ Although the large posterolateral compartment transmits the sigmoid sinus on its way to become the jugular vein and meningeal branch of occipital artery.⁴

Different pathologic conditions involve the JF and may result in the lower CN deficits. The lower CN deficits leading to dysphagia, breathing difficulty, hoarseness, and pneumonia due to aspiration are potential dangerous problems. Understanding the relationship of the compartments of JF to the lower CN, and its measurements are essential if neural preservation is desired.

The carotid canal is the passage way in the temporal bone through which the internal carotid artery enters the middle cranial fossa from the neck. The canal starts on the inferior surface of the temporal bone at the external opening of the carotid canal also called as the carotid foramen. The canal ascends at first vertically, and then, making a bend, runs horizontally forward and medially. The canal opens in the lateral wall of foramen lacerum.

The carotid canal transmits the internal carotid artery along with the carotid plexus of nerves into the cranium, sympathetic to the head from superior cervical ganglion also pass through the carotid canal.

The carotid canal is considered as an important landmark by the neurosurgeons as the canal is most vital and easily visualized structure on magnetic resonance imaging angiography and digital subtraction angiography.

The detailed knowledge of the normal and variant position of the carotid canal is important for radiologists, neurosurgeons, and anatomists as identification of the skull base anatomy is of great importance in cases of aneurysms and clival tumors.

MATERIALS AND METHODS

A total of 100 adult human skulls were collected. The samples for the study were collected randomly independent of the sex and origin of the skull. The skulls were collected from the bone bank of department of anatomy, Navodaya Medical College, Raichur and from the students of Navodaya Medical College Raichur, Navodaya Dental College, Raichur and Khaja Bandanawaz Institute of Medical Sciences, Gulbarga.

After collection of the skulls sample randomly, sex of the skull is determined based on the non-metrical parameters, these skulls were further assessed with the metrical parameters using vernier calipers. The non-metrical parameters⁵ taken were size and overall architecture of the skull, zygomatic bone presenting marginal tubercle in the posterior of the frontal process and ridges on its lower edge in males, size and ridges of the mastoid process, roughness in the occipital bone. According to the non-metrical parameters 84 skulls were male skulls, and 16 skulls were female skulls.

Only fully ossified adult skulls were included in the present study. Skulls are showing wear and tear, any fracture or pathology was excluded.

Parameters taken under Study are

1. Distance of the foramina from the midline
2. Number of foramina on right and left side
3. Diameters of the foramina. Anteroposterior diameter and transverse diameter
4. Area of the foramina
5. Male and female sexing of the skull by morphometrical analysis of the foramina.

Observations

The foramen ovale, JF, and external opening of the carotid canal of 100 skulls are studied and observed on the right and left sides. The following observations were made.

- Position of the foramen: The distance of the medial edge of the foramen from the median plane were observed and compared to both sides
- Number of the foramen: The number of foramen on both sides was observed and compared, any bony growths around the margins of the foramen due to ossified ligaments or any septations dividing the foramen into the compartments as in case of JF were also studied
- Diameters of the foramen: The anteroposterior diameter and the transverse diameter of the foramen were observed and compared to both sides
- Area of the foramen (A): The area of the foramen was calculated using the formula $A = \frac{\pi \times APD \times TD}{4}$, the areas of both the foramina were compared

- Combined area (CA) is calculated by adding areas of the foramina of both sides, which is used further to determine the sex of the skull.

For the above-mentioned parameters the range, mean, and standard deviation (SD) of the measurements are calculated. The means of both sides are compared statistically using “t” test. The identification point (IP) for the CA is calculated from the range of CA of each foramen, the demarcating points (DP) are determined from the calculated range,⁶ and from the DP the limiting point (LP) is determined by multiple trial and error method.⁷ These values are calculated to determine the sex of the skull.

Position of the foramen: As seen in Figure 1, it is observed that the mean of the distance of foramen ovale are 22.98 mm on the right side and 22.79 mm on the left side. The comparison of the position of the foramina on right and left sides showed no statistical significance ($P > 0.05$). The mean of the position of JF is 23.9 mm on the right side and 24.04 mm on left side JF. The comparison of the position of JF on the right and left sides showed no statistical significance ($P > 0.05$), and the mean of the distance of the external opening of carotid canal is 26.14 mm on the right side and 26.02 mm on left side.

The comparison of the position of the external opening of the carotid canal on right and left sides showed no statistical significance ($P > 0.05$).

Number of foramen: As seen in Figures 2 and 3, it is observed that with each of the 100 skulls only 1 foramen ovale is present on the right side and 1 foramen ovale on the left side, with no duplication of the foramina on either side, 1 JF is present in 96 skulls on the right side and 92 skulls on the left side, whereas, 91 skulls showed a single JF on both sides. 2 jugular foramina are observed in 1 skull only on the right side, and 2 jugular foramina are observed in 5 skulls only on the left side, whereas 3 skulls showed doubled jugular foramina on both sides and 1 carotid canal is present on the right side and 1 carotid canal on the left side, with no duplication of the external opening of the carotid canal on either side.

Anteroposterior diameter of the foramen: As seen in Figure 4, it is observed that the range of the anteroposterior diameter of foramen ovale is 3-7.5 mm on the right side and 2-7 mm on the left side, with a mean of 5.255 mm on the right side and 4.84 mm on the left side. The comparison of the anteroposterior diameter of the foramen ovale on the right and left sides is found to be statistically significant ($P < 0.05$), with a diameter of the right side being greater than the left side. JF is 6-13.5 mm on the right side and 5-10 mm on the left side, with a mean of 9.885 mm on the

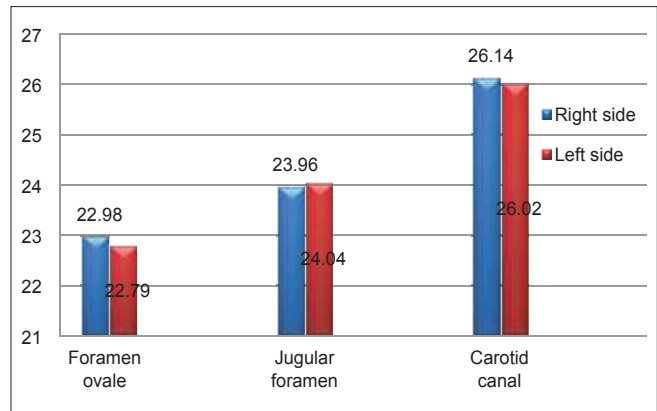


Figure 1: Position of the foramen from the midline

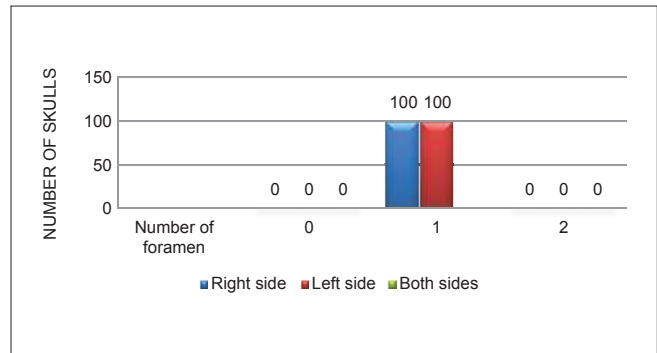


Figure 2: Number of foramen ovale and carotid canal opening on the right and the left sides

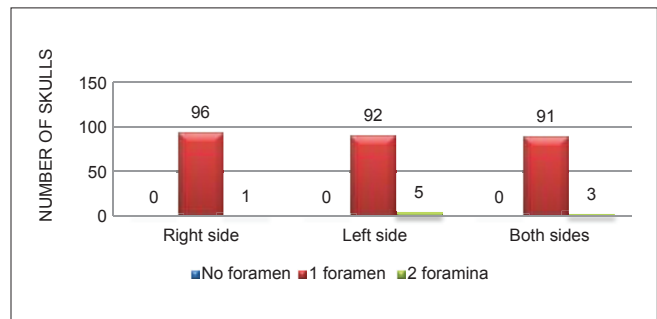


Figure 3: Number of jugular foramen on the right and the left sides

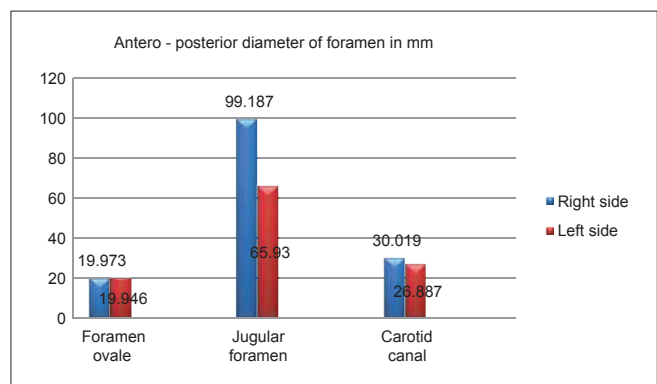


Figure 4: Comparison of anteroposterior diameters of foramen ovale, jugular foramen, and carotid canal on the right and the left sides

right side and 7.475 mm on the left side. The comparison of anteroposterior diameter of JF on the right and left sides is found to be statistically very highly significant ($P < 0.001$), with diameter of right side being greater than left side and external opening of carotid canal is 5-8.5 mm on the right side and 5-8 mm on the left side, with a mean of 6.795 mm on the right side and 6.285 mm on the left side. The comparison of anteroposterior diameter of the external opening of carotid canal on right and left sides is found to be statistically highly significant ($P < 0.001$), with diameter of the right side being greater than the left side.

Transverse diameter of the foramen: As seen in Figure 5, it is observed that the range of the transverse diameter of foramen ovale is 2-6 mm on the right side and 3.5-7 mm on the left side, with a mean of 4.87 mm on the right side and 5.185 mm on the left side. The comparison of the transverse diameter of foramen ovale on the right and the left sides is found to be statistically significant ($P < 0.05$), with a diameter of the right side being greater than the left side. The range of the transverse diameter of JF is 9-16 mm on the right side and 8.5-14 mm on the left side, with a mean of 14.665 mm on the right side and 14.39 mm on the left side. The comparison of transverse diameter of foramen ovale on the right and the left sides is found to be statistically very highly significant ($P < 0.001$), with diameter of the right side being greater than the left side, and the range of the transverse diameter of carotid canal is 4-7.5 mm on the right side and 4-7 mm on the left side, with a mean of 5.54 mm on the right side and 5.27 mm on the left side. The comparison of transverse diameter of external opening of carotid canal on the right and the left sides is found to be statistically significant ($P < 0.05$), with diameter of the right side being greater than the left side.

Area of the foramen: As seen in Figure 6, it is observed that the mean area of foramen ovale is 19.993 mm² on the right side and 19.946 mm² on the left side. The comparison of the area of foramen ovale on the right and the left sides is found to be statistically not significant ($P > 0.05$). The mean area of JF is 99.187 mm² on the right side and 65.93 mm² on the left side. The comparison of area of JF on the right and the left sides is found to be statistically highly significant ($P < 0.01$), with the area of the right JF greater than the left JF, and the mean area of external opening of carotid canal is 30.0193 mm² on the right side and 26.887 mm² on the left side. The comparison of the area of external opening of the carotid canal on the right is greater than the left carotid canal.

CA of the foramen: CA of the foramen is compared and is used to determine the sex of the skull. In the present study, to determine the sex of the skull, the CA of the foramen ovale, as seen in Table 1 and external opening

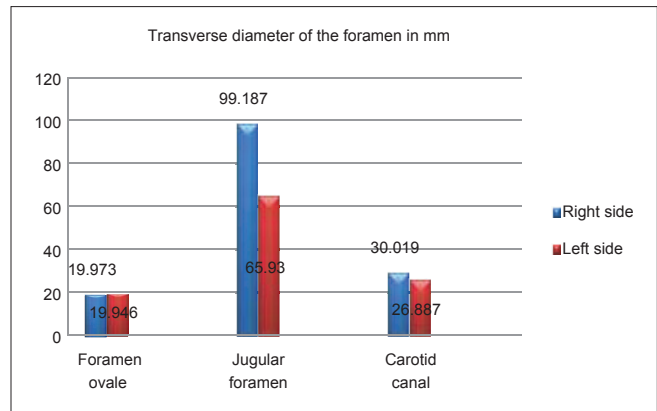


Figure 5: Comparison of transverse diameter of foramen ovale, jugular foramen, and carotid canal on the right and the left sides

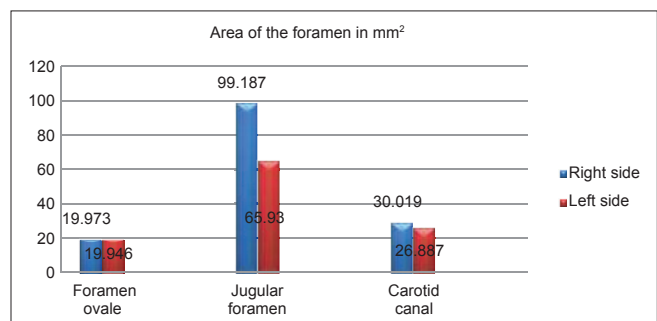


Figure 6: Comparison of area of foramen ovale, jugular foramen, and carotid canal on the right and the left sides

of the carotid canal, as seen in Table 2, are used. The CA are used to determine the LP, the skulls having CA greater than the LP are classified as male skulls and skulls with CA lesser than the LP are classified as female skulls. As seen in Table 1, the CA of foramen ovale with male range are 34.5-56.4 mm² and female range 14-31.6 mm², values 34.5 mm², and 31.6 mm² were the IP, for females and males, respectively. Any skull with CA reading less 34.5 mm² is regarded as a female skull and >31.6 mm² is regarded as the male skull. Alternatively stated, for CA of each foramen, if the measurement is conducted on the skulls of known sex was in range of 34.5-56.4 mm² for male skulls, then any skull of unknown sex with a value of the CA of the foramen <34.5 mm² is considered as female and thus 34.5 mm² is regarded as IP of female skulls. Similarly, if for female skulls of known sex, the measurement ranged between 14.0 and 31.6 mm² then any skull of unknown sex showing the measurement of the CA of the foramen >31.6 mm² is regarded as male skull. 31.6 mm² is regarded as IP for males. Mean and standards deviations are calculated for each range of the CA of the foramina for both the sexes. The male calculated range is 28.67-42.327 mm² and female calculated range is 3.092-41.708 mm², 28.67 mm², and 41.708 mm² are chosen as DP,^{6,8,9} for females and males, respectively. Skulls with

measurements $<28.67 \text{ mm}^2$ are identified as female skulls and $>41.708 \text{ mm}^2$ as male skulls. Although IP and DP can identify sex accurately, only 15-20% of skulls can be sexed based on these, as most of the remaining skulls show the measurements in the overlapping neutral zone. Therefore, an LP is chosen in this study using multiple trial and error method. The LP is an absolute value found within both male and female ranges of the CA. It is so chosen that the vast number of male skulls showed values greater than it and bulk of female skulls showed values lesser than the chosen LP. Hence, as compared to IP and DP, the percentage of skulls that could be identified are far larger with LP.¹⁰ Female skulls showed values lesser than the chosen LP. Hence, as compared to IP and DP, the percentage of skulls that could be identified are far larger with LP.¹⁰ In case of foramen ovale the LP is 31 mm^2 .

In the present study, with external opening of carotid canal, as seen in Table 2, CA with male range are $43.1\text{-}93.9 \text{ mm}^2$ and female range $39.2\text{-}49.6 \text{ mm}^2$, values 43.1 mm^2 and 49.6 mm^2 were the IP, for females and males, respectively. Any skull with CA reading less 43.1 mm^2 is regarded as a female skull and $>49.6 \text{ mm}^2$ is regarded as the male skull. Alternatively stated, for CA of each foramen, if measurement is conducted on the skulls of the known sex were in range of $43.1\text{-}93.9 \text{ mm}^2$ for male skulls, then any skull of unknown sex with a value of the CA of the foramen $<43.1 \text{ mm}^2$ is considered as female, and thus, 43.1 mm^2 is regarded as IP of female skulls. Similarly, if for female skulls of known sex, the measurement ranged between 39.2 and 49.6 mm^2 , then any skull of unknown sex showing the measurement of the CA of the foramen

$>49.6 \text{ mm}^2$ is regarded as male skull 49.6 mm^2 is regarded as IP for males.

The male calculated range is $21.75\text{-}97.35 \text{ mm}^2$ and female calculated range is $31.32\text{-}55.18 \text{ mm}^2$, 21.75 mm^2 , and 55.18 mm^2 are chosen as DP,^{6,8,9} for females and males, respectively. Skulls with measurements $<21.75 \text{ mm}^2$ are identified as female skulls and $>55.18 \text{ mm}^2$ as male skulls. Although IP and DP can identify sex accurately, only 15-20% of skulls can be sexed based on these, as most of the remaining skulls show the measurements in the overlapping neutral zone. Therefore, an LP is chosen in this study using multiple trial and error method. The LP is an absolute value found within both male and female ranges of the CA. It is so chosen that a vast number of male skulls showed values greater than it and bulk of female skulls showed values lesser than the chosen LP. Hence, as compared to IP and DP, the percentage of skulls that could be identified is far larger with LP.¹⁰

In case of external opening of the carotid canal the LP is 47.5 mm^2 .

The LP (47.5 mm^2) of the carotid canal and LP (31 mm^2) of foramen ovale combined are further utilized for the determining the sex of the given skull.

As seen in Table 3 and Figure 7, 83% of skulls were classified as male skull, and 12% of skulls were classified as female skulls, and the remaining 5% of the skulls were unclassified.

Table 1 shows the range, mean, calculated range. DP, SD, IP, and LP for determining the sex of the skull by using CA of foramen ovale.

Table 2 shows the range, mean, calculated range. DP, SD, IP, and LP for determining the sex of the skull by using CA of external opening of the carotid canal.

Table 3 shows the sexing of the skulls based on the CA of foramen ovale and CA of external opening of the carotid canal.

Table 1: Foramen ovale CA in mm^2

Details of measurement	Male	Female
Range	34.5-56.4	14-31.6
Mean	35.5	22.4
SD	± 6.827	± 6.43
IP	>31.6	<34.5
Calculated range mean ± 3 SD	28.67-42.32	3.09-41.7
DP	41.7	28.67
LP	>31	<31

CA: Combined area, IP: Identification point, SD: Standard deviation, DP: Demarcating points, LP: Limiting points

Table 2: Carotid canal CA in mm^2

Details of measurement	Male	Female
Range	43.1-93.9	39.2-49.6
Mean	59.55	43.25
SD	± 12.6	± 3.97
IP	>49.6	<43.1
Calculated range mean ± 3 SD	21.75-97.35	31.32-55.18
DP	55.18	21.75
LP	>47.5	<47.5

IP: Identification point, DP: Demarcating points, LP: Limiting points, CA: Combined area, SD: Standard deviation

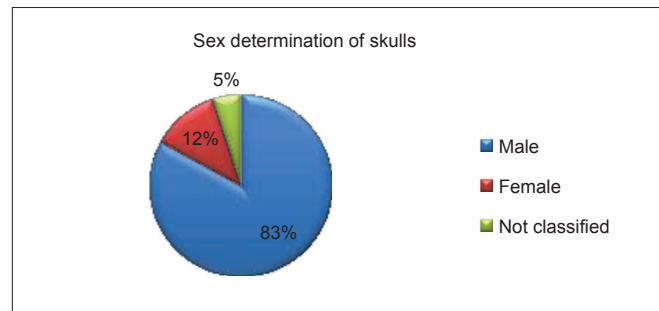


Figure 7: Sex determination of skulls by metrical parameters

DISCUSSION

The present study is compared with other studies. As seen in Table 4, the position of foramen ovale is in the range of 20-27 mm on the right side and 20-29 mm on the left side, the mean were 22.98 mm on the right side and 22.79 mm on the left side foramen ovale. The comparison of the position of foramina on the right and the left sides showed no statistical significance ($P > 0.05$). These findings correlate with a study done by Lang *et al.*¹⁰ and Sharma and Garud.¹¹ The position of external opening of the carotid canal, as seen in Table 5 is in the range of 20-30 mm on the right side and 20-29 mm on the left side, the mean were 26.14 mm on the right side and 26.02 mm on the left side foramen. The comparison of the position of foramina on the right and the left sides showed no statistical significance. $t = 0.30$ and $P > 0.05$. The present study values correlate with study done by Sharma and Garud.¹¹

As seen in Table 6, 1 JF is present in 96 skulls on the right side and 92 skulls on the left side, whereas, 91 skulls showed a single JF on both sides. Two jugular foramina are observed in 1 skull only on the right side, and 2 jugular foramina are observed in 5 skulls only on the left side, whereas, 3 skulls showed doubled jugular foramina on both sides. The present study correlates with the study done by Sturrock.¹²

In the present study, as seen in Table 7, the range of the area of foramen ovale is 8.6-28.2 mm² on the right side and 5.4-30.2 mm² on the left side, with a mean of 19.993 mm² on the right side and 19.946 mm² on the left side. In this studies were done by Somesh *et al.*¹⁴ the mean area of foramen ovale was calculated as 30.808 ± 7.545 mm² and 31.310 ± 8.262 mm² on the right side and the left sides. As seen in Table 8, the range of the area of JF is 44.7-166.3 mm² on the right side and 35.3-102 mm² on the left side, with a mean of 99.187 mm² on the right side and 65.93 mm² on the left side. This study demonstrated a statistically significant asymmetry in the areas of right and left sided JF, with the area of the right foramina being more than the left foramen. Wysocki *et al.*¹⁵ reported the surface area of the jugular foramina in males, left side as 51.11 mm² ranging from 21 to 126.2 mm², and on the right side as 57.53 mm², with a range of 12.5-94.9 mm². In females, the surface area on the left side as 53.83 mm², with a range of 15.8-1122.7 mm² and on the right side as 59.84 mm² with a range of 40.5-221.1 mm². The present study correlated with the study done by the author. As of external opening of the carotid canal, as seen in Table 9, the CA of external opening of the carotid canal is 59.55 mm² in males and 43.25 mm² in females.

The present study shows the mean distance of the foramen ovale on the right and the left side from the midline. It

Table 3: Sex determination using metrical parameters LPs of foramen ovale and external opening of carotid canal

Sex	Number of skulls	Percentage
Male	83	83
Female	12	12
Not classified	5	5

LPs: Limiting points

Table 4: Comparison of findings of the present study of the distance of foramen ovale from the midline with the other studies

Foramen ovale	Distance of the foramen from midline mean (mm)	
	Right side	Left side
Investigators		
Lang <i>et al.</i> ¹⁰	20.9	22.5
Sharma and Garud ¹¹	22.13	21.71
Present study	22.98	22.79

Table 5: Comparison distance of the medial edge of the carotid canal with the other studies

Carotid canal	Position of the carotid canal from midline mean (mm)	
	Right side	Left side
Investigators		
Sharma and Garud ¹¹	25.31	24.88
Present study	26.14	26.02

Table 6: Comparing number of JF (septations) with the other study

JF	Percentage of skulls showing septations in JF (%)		
	Right side	Left side	Both sides
Investigators			
Sturrock ¹²	1.3	10.9	3.2
Hussain <i>et al.</i> ¹³	20.8	21	0
Present study	1	5	3

JF: Jugular foramen

Table 7: Comparing area of foramen ovale with other studies

Foramen ovale	Area of the foramen mean (mm ²)	
	Right side	Left side
Investigators		
Somesh <i>et al.</i> ¹⁴	30.808	31.310
Present study	19.973	19.946

Table 8: Comparing area of the JF with the other studies

JF	Area of the foramen, mean (mm ²)	
	Right side	Left side
Investigators		
Wysocki <i>et al.</i> ¹⁵	57.53	51.11
Present study	99.187	68.93

JF: Jugular foramen

Table 9: Comparing CA of the carotid canal with other studies

Carotid canal	CA of carotid canal (mm ²)	
	Males	Females
Investigators		
Chimalgi <i>et al.</i> ⁷	38.51	29.28
Present study	59.55	43.25

CA: Combined area

is seen that the mean distance of foramen ovale from the midline is found to be 22.8 mm on the right side and 22.79 mm on the left side.

The distance of the medial edge of Carotid canal in the present study is found to be 26.14 mm on the right side and 26.02 mm on the left side.

The number of jugular foramen showing the presence of septations or bony spurs, in the present study was around 1% on the right side, 5% on the left sided foramen and 3% on both sided foramina.

The mean area of foramen ovale in the present study is found to be 19.973 mm² on the right side and 19.946 mm² on the left side foramen.

The mean area of jugular foramen in the present study is found to be 99.187 mm² on the right side and 68.93 mm² on the left side.

The mean CA of carotid canal in the present study is found to be 59.55 mm² in males and 43.25 mm² in females.

The CA of the foramina under study is calculated to determine the sex of the skull; it is calculated by adding the area of the right side and the left side foramen.

The CA used in the study is the CA of foramen ovale and external opening of the carotid canal. A LP is determined in the study for foramen ovale and carotid canal, which is used combined to differentiate male skulls from female skulls, in the present study the LP are 31 mm² for foramen ovale and 41.5 mm² for carotid canal. The skulls differentiated using these CA are 83% male skulls and 12% female skulls, however, the remaining 5% of the skulls cannot be differentiated because the CA of both foramina (foramen ovale and carotid canal) are overlapping with each other for male and female values.

CONCLUSION

The need for familiarity with the detailed anatomy of the foramina under study and their variations are very much essential in microsurgical techniques as many extracranial and intracranial lesions including intrinsic anomalies may affect the foramina. Pathological processes affecting the foramina include paragangliomas, schwannomas, metastatic lesions, and infiltrative inflammatory processes from surrounding structures such as the middle ear. Surgical resection is the treatment of choice in the majority of these cases. Advances in microsurgical techniques have made possible the removal of advanced lesions of the foramina, which were once assumed inoperable. A neurosurgeon becomes bolder in approaching the region with the anatomical and variational knowledge of these foramina.

REFERENCES

1. Kuta AJ, Laine FJ. Imaging the sphenoid bone and basiocciput: Anatomic considerations. *Semin Ultrasound CT MR* 1993;14:146-59.
2. Williams PL, Bannister LH, Berry MM, Collin P, Dyson M, Dussek JE, *et al.* Gray's Anatomy. 38th ed. New York: Churchill Livingstone; 2000.
3. Katsuta T, Rhoton AL Jr, Matsushima T. The jugular foramen: Microsurgical anatomy and operative approaches. *Neurosurgery* 1997;41:149-201.
4. Romanes GJ, editor. Bones, the skull. In: *Cunningham's Text Book of Anatomy*. 11th ed. London: Oxford University Press; 1972. p. 112.
5. Suazo GI, Zavando MD, Smith RL. Evaluating accuracy and precision in morphologic traits for sexual dimorphism in malnutrition human skulls a comparative study. *Int J Morphol* 2008;26:877-81.
6. Jit I, Singh S. The sexing of the adult clavicles. *Indian J Med Res* 1966;54:551-71.
7. Chimalgi M, Kulkarni Y, Sant SM. Sexing of skull by new metrical parameters in West India. *J Anat Soc India* 2007;56:28-32.
8. Singh SK, Raju PB. Identification of sex from the hip bone- demarcating points. *J Anat Soc India* 1977;26:111-7.
9. Raju PB, Singh S, Padmanabhan R. Sex determination and sacrum. *J Anat Soc India* 1980;30:13-5.
10. Lang J, Maier R, Schafhauser O. Postnatal enlargement of the foramina rotundum, ovale et spinosum and their topographical changes. *Anat Anz* 1984;156:351-87.
11. Sharma NA, Garud RS. Morphometric evaluation and a report on the aberrations of the foramina in the intermediate region of the human cranial base: A study of an Indian population. *Eur J Anat* 2011;15:140-9.
12. Sturrock RR. Variations in the structure of the jugular foramen of the human skull. *J Anat* 1988;160:227-30.
13. Hussain SS, Mavishetter GF, Thomas ST, Prasanna LC, Murlidhar P. A morphometric study of the jugular foramen in human adult skulls of South India. *J Biomed Sci Res* 2010;2:240-3.
14. Somesh MS, Sridevi HB, Prabhu LV, Swamy MS, Krishnamurthy A, Murlimanju BV, *et al.* A morphometric study of foramen ovale. *Turk Neurosurg* 2011;21:378-83.
15. Wysocki J, Reymond J, Skarzynski H, Wróbel B. The size of selected human skull foramina in relation to skull capacity. *Folia Morphol (Warsz)* 2006;65:301-8.

How to cite this article: Ahmed MM, Jeelani M, Tarnum A. Anthropometry: A Comparative Study of Right and Left Sided Foramen Ovale, Jugular Foramen and Carotid Canal. *Int J Sci Stud* 2015;3(5):88-94.

Source of Support: Nil, **Conflict of Interest:** None declared.