Original Article

DOI: 10.17354/ijss/2015/355

# Enthesophytes and Tubercles of the Calcaneum: An Anatomical and Clinical Understanding of the Relationship between Calcaneal Spurs and Plantar Heel Pain

**Ajay Kumar Mahto[1], Saif Omar[2]**

[1]Professor, Department of Orthopaedics, Katihar Medical College, Katihar, Bihar, India, [2]Associate Professor, Department of Anatomy, Katihar Medical College, Katihar, Bihar, India

## Abstract

**Background:** Calcaneus is the largest of all the bones that constitute the skeleton of the foot. It is also the largest tarsal bone and plays a pivotal role in weight transmission, weight bearing, gait, and posture. In professions involving long durations of standing and in disorders such as obesity there may be growth of abnormal bone tissue at the site of tendinous attachments known as enthesophytes or spurs. Radiologically these spurs may differ from the naked eye and clinical examinations. The apices of these spurs are often embedded in the plantar fascia of the foot.

**Aim:** The aim of the present study was to observe the enthesophytes and tubercles of dry adult human calcanei.

**Materials and Methods:** One hundred dry adult human intact calcanei were obtained from the four different medical colleges in the state of Bihar and observed in detail. Bones were of unknown, age and sex and were supposedly from cadavers of Bihar origin.

**Results:** The incidence of calcaneal spurs was reported to be 22% with laterality of 14 and 8 in right and left sides, respectively. Our findings have been compared with those of other researchers. Medial tubercle was larger than lateral tubercle, and all enthesophytes were observed to be originating from the medial tubercle only.

**Conclusion:** Calcaneal enthesophytes or spurs may be related to the nature of work or orthopedic pathology. Probable other factors that may increase the incidence of spur formation are uncontrolled weight gain, advancing age, and constant use of uncomfortable footwear.

**Key words:** Calcaneus, Enthesophytes, Pain, Spurs, Tubercles

## INTRODUCTION

The foot extends from the point of the heel to the roots of the toes. Superior and inferior surfaces of the foot are referred to as dorsum and plantar, respectively. The foot is divided into tarsus and metatarsus. The tarsus is the posterior half formed by the tarsal bones, which are arranged in two rows. The proximal row consists of talus and calcaneus, whereas the distal row consists of cuboid, navicular, and cuneiform. The largest of the tarsals, the calcaneus forms an irregular block of bone.[1] It is also referred to as heel bone and forms a major component of the skeleton of the hindfoot and prominence of the heel.[2] The calcaneus is the longest, strongest, and largest of all the tarsal bones.[3] It is the first bone in the foot to ossify and is also the most frequently injured tarsal bone. It transmits the weight of the body to the ground. This bone also provides leverage for the action of the posterior calf muscles attached to its broader and non-articular posterior surface.[4] Very rarely, the calcaneum may also present itself with a set of accessory bones.[5,6] Being irregularly cuboidal in shape,

Access this article online

IJSS

www.ijss-sn.com

Month of Submission : 06-2015
Month of Peer Review : 07-2015
Month of Acceptance : 07-2015
Month of Publishing : 08-2015

**Corresponding Author:** Dr. Saif Omar, Department of Anatomy, Katihar Medical College, Katihar - 854 105, Bihar, India.
Phone: +91-9431229999. E-mail: drsaifomar@gmail.com

it presents six surfaces and a shelf-like bony projection the sustentaculum tali which as the name implies sustains the head of the talus and also bears the greatest weight per area. The calcaneus bears four tubercles, anterior, lateral, and medial which are present on the inferior or plantar surface and a small peroneal tubercle on the lateral surface. Occasionally, an enthesophyte has been observed growing anteriorly along the calcaneal tuberosity along the entire width of the bone. Plantar fasciitis is the most common cause of plantar heel pain. Clinically, the etiology and pathophysiology of enthesophyte formation in calcaneum has not yet been clearly understood. In spite of different treatment modalities of a heel spur, the association of incidence of calcaneal spur with clinical and functional parameters in nonconclusive. It has been suggested that longitudinal traction or vertical compression may be the causative factors. Enthesophyte formation usually occurs at the site of ligamentous and tendinous insertions into the bone. An enthesophyte tends to grow in the direction of natural pull of ligaments and tendons involved.[7] The lateral and medial tubercles of calcaneus provide sites for the origin of muscles of the various layers of the sole. The medial tubercle gives origin to abductor hallucis, flexor digitorum brevis, and abductor digiti minimi. The lateral tubercle gives origin to abductor digiti minimi and lateral head of flexor digitorum accessorius. The anterior tubercle provides attachment to the short plantar ligament, and the long plantar ligament is attached to the rough strip between the three tubercles. The peroneal tubercle lies between the tendons of peroneus brevis above and peroneus longus below. Variations in the gross morphology of the calcaneus have been reported in the literature with reference to sex, race, and occupation; but there are few citable references regarding the observation on tubercles and incidence of calcaneal enthesophytes. The most enthesophytes are encountered radiographically or clinically during surgical procedures, but our study focuses on observing the incidence of enthesophytes in dry bone by naked eye examination.

## MATERIALS AND METHODS

One hundred dry intact adult human calcanei were observed in details for enthesophytes. The bones were supposedly of Bihar origin. Sex of the bone was not taken into consideration. Specimens that showed signs of damage or previous fracture were discarded from the study. Naked eye examination of all the bones was performed, and incidence of spurs was recorded. Handheld magnifying lens was used for observing the peroneal tubercle (Figures 1-4).




**Figure 1: Plantar surface of a normal calcaneus showing the normal morphology of three tubercles (A) anterior (M) medial (L) lateral. The medial tubercle is larger than all other tubercles. Concavity present between the three tubercles in a normal calcaneus is smooth. Peroneal tubercle is not shown in this figure**

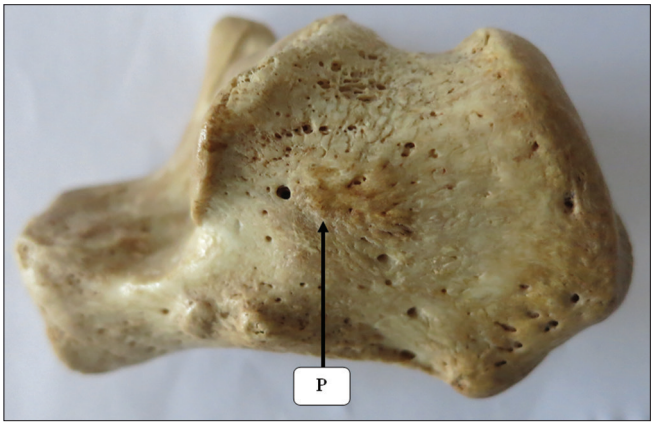


**Figure 2: Lateral surface of a normal calcaneus showing the normal morphology of the peroneal tubercle (P). Concavities present both above and below the tubercle are for the tendons of peroneus brevis and peroneus longus, respectively**

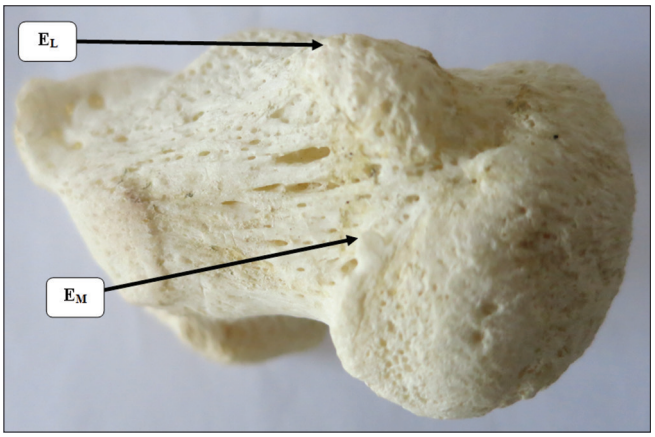


**Figure 3: Specimen of calcaneus showing small enthesophytes arising from both lateral and medial tubercles. $E_M$ and $E_L$ denote the enthesophytes arising from the medial and lateral tubercles, respectively**

### Inclusion Criteria

- Bones belonging to cadavers of Bihar origin
- Bones with intact gross morphology and tubercles
- Bones belonging to adult
- Bone which were available in pairs.

### Exclusion Criteria

- Bones which were unpaired
- Bones with abnormal morphology and tubercles
- Bones belonging to children
- Bones which showed signs of previous fracture.

### Observation

Of 100 calcanei observed ($n$ = 100) enthesophytes were observed in 22 specimens. All the specimens studied presented with four tubercles. Medial tubercles were larger in all specimens. The total incidence in this study was 22% out of which fourteen were on the right side, and eight were on the left side, respectively (Tables 1-4).

Figure 5 shows the incidence of enthesophytes in the present study.

Figure 6 shows a pictorial representation of laterality of incidence of enthesophytes in the present study. On the right side, enthesophytes were observed in 14 out of 22 calcanei. On the left side, enthesophytes were observed in 8 out of 22 calcanei.

**Table 1: Incidence of enthesophytes in this study**

| Total number of calcanei observed | Incidence of enthesophytes |
|---|---|
| $n$=100 | 22% |

**Table 2: Number of tubercles in each calcaneus observed**

| Total number of calcanei observed | Tubercles present in each calcaneus |
|---|---|
| $n$=100 | A/P/L/M |

A: Anterior, P: Peroneal, L: Lateral, M: Medial

**Table 3: Largest of all the tubercles in each calcaneus observed**

| Total number of calcanei observed | Largest tubercle |
|---|---|
| $n$=100 | Medial tubercle |

**Table 4: Incidence of laterality of enthesophytes in this study**

| Incidence of enthesophytes | Laterality of incidence |
|---|---|
| 22% | R=14/22 (64%) and L=08/22 (36%) |

## DISCUSSION

Enthesophytes were observed in 22 out of 100 bones examined in this study. In this study, we observed that there was no spur formation from either of the anterior, lateral, and peroneal tubercles of any specimen. Only in three specimens, we observed enthesophytes originating

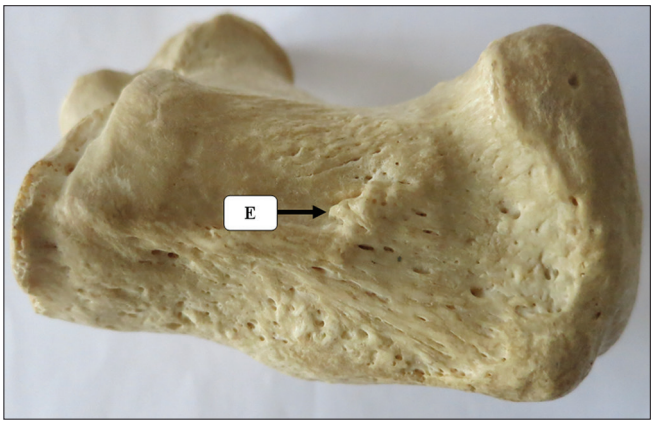


**Figure 4: Specimen of calcaneus showing an enthesophyte arising from the concavity of the plantar surface of the anterior, medial, and lateral tubercles. Location of the enthesophyte is indicated in figure by an arrow (E)**

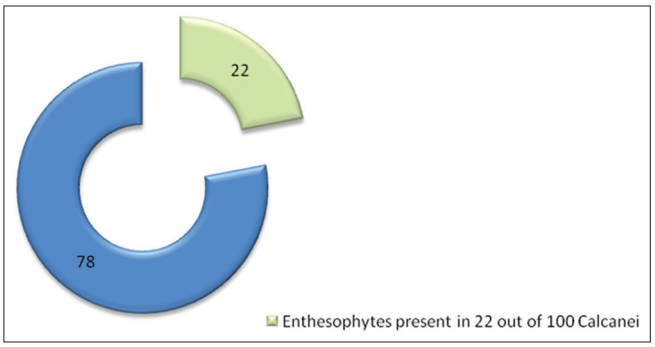


**Figure 5: Incidence of enthesophytes. Enthesophytes were observed in 22 out of 100 calcanei studied with an incidence of 22%**

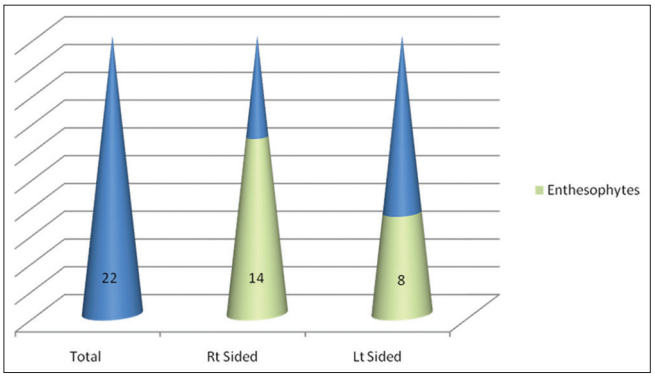


**Figure 6: Pictorial representation of laterality of incidence of enthesophytes**

**Table 5: Comparison of incidence of calcaneal enthesophytes in different studies**

| Researcher | Year | Sample size (*n*) | Incidence (%) |
|---|---|---|---|
| Resnick[14] | 1977 | Not available | 22 |
| Prichasuk and Subhadrabandhu[15] | 1994 | Not available | 15.5 |
| Riepert[16] | 1995 | Not available | 15.7 |
| Menz *et al*. | 2008 | 216 | 55.1 |
| Perumal | 2013 | 218 | 56 |
| Kullar *et al*. | 2013 | 200 | 26.5 |
| Omar | 2015 | 100 | 22 |

from both medial and lateral tubercles. These findings have been pictorially represented in Figures 1 and 2. Such enthesophytes may occur on the plantar surface of the bone due to deposition of calcium salts and on the fibrous tissue attached to the tubercles. Many such related studies have highlighted this occurrence of enthesophyte formation based on radiological data of the western population. The formation of spurs was due to compression force exerted on the bone due to weight bearing.[8] Irrespective of their origin calcaneal spurs result in heel pain and interfere with daily activities. Calcaneal spurs have also been reported in young individuals.[9] Intra-articular incongruity, varus and valgus misalignment of the heel, widened heel due to lateral bulge, shorter heel height, decreased ankle dorsiflexion, and elevated Achilles tendon insertion leading to weakening of the gastrocnemius-soleus complex can result in enthesophyte formation in the calcaneus. The attachment of the plantar fascia to the calcaneus may become ossified, or a similar spur may occur related to the insertion of the tendo Achilles. Spurs are usually seen in the middle age or later and are usually asymptomatic.[10] All enthesophytes observed had a hook or semi-hook like appearance from the lateral aspect. It could be due to an increased axial load or obesity.[11] Calcaneal enthesophytes appear to be multifactorial in origin and in our study it is evident that all enthesophytes are extending from the medial tubercle. A detailed analysis of patterns of anterior talar articular facets in a series of 401 Indian calcanei revealed four types. Type I (67%) showed one continuous facet on the sustentaculum extending to the distomedial calcaneal corner; Type II (26%) presented two facets, one sustentacular and one distal calcaneal; Type III (5%) only a single sustentacular facet; and Type IV (2%) showed confluent anterior and posterior facets.[12] In this study, the incidence of calcaneal enthesophytes was lower than Menz *et al*.,[13] Anand[8] and Kullar *et al*.[2] gender may be a cofactor leading to heel pain.[2] We have compared to our findings with those of previous researchers in Table 5. A higher frequency of calcaneal spur formation in individuals with abductor digiti minimi has also been reported.[5] As sex and age of the bones were not considered it was not possible to comment on the gender and age group having higher or lower incidence of calcaneal enthesophytes. A further study with these parameters may be performed in the future. Our findings shall serve as a guide for podiatrists with who deal with calcaneal enthesophytes.

## CONCLUSION

Calcaneal enthesophytes are bony outgrowths of the calcaneus that are common findings on radiographic examinations of the foot and ankle. Such outgrowths can extend on the whole extent of the calcaneus. Anatomical knowledge of calcaneal enthesophytes is clinically relevant as these spurs affect the normal alignment of the calcaneus. Misalignments lead to instability and are a frequent cause of heel pain. Enthesophyte formation usually occurs in the medial tubercle of calcaneum and is probably due to biomechanical reasons. The factors that aggravate the incidence of spurs are increasing weight, obesity, advancing age, and concurrent orthopedic diseases. Ethnic and developmental variations must also be considered. Theoretically, calcaneal enthesophytes may be an adaptive response to vertical compression of the heel. Regular wearing of uncomfortable or improper footwear can also be a causative factor.

## REFERENCES


1. Rosse C. Hollinshead's Textbook of Anatomy. 5th ed. Philadelphia: Lippincott-Raven; 1997. p. 345.
2. Kullar JS, Randhawa GK, Kullar KK. A study of calcaneal enthesophytes (spurs) in Indian population. Int J Appl Basic Med Res 2014;4:S13-6.
3. Snell RS. Bones of the foot: Clinical Anatomy for Medical Students. 6th ed. Philadelphia: Lippincott Williams & Wilkins; 1993. p. 551-2.
4. Chakraborty N. Fundamentals of Human Anatomy. Kolkata: New Central Book Agency; 1994. p. 309.
5. Chundru U, Liebeskind A, Seidelmann F, Fogel J, Franklin P, Beltran J. Plantar fasciitis and calcaneal spur formation are associated with abductor digiti minimi atrophy on MRI of the foot. Skeletal Radiol 2008;37:505-10.
6. Perumal A. Morphometric study of spur formation in dry adult human calcaneae. Int J Curr Res Rev 2013;5:92-6.
7. Rogers J, Shepstone L, Dieppe P. Bone formers: Osteophyte and enthesophyte formation are positively associated. Ann Rheum Dis 1997;56:85-90.
8. Anand A. Morphometric study of spur formation in dry adult human calcaneae. Int J Curr Res Rev 2013;5:92-6.
9. Reeves B. Development of an OS calcaneal spur in a boy between the ages of 10 and 14 years. Ann Rheum Dis 1965;24:66-7.
10. Decker GA. Lee McGregor's Synopsis of Surgical Anatomy. 12th ed. Bombay: Wright-Varghese; 1986. p. 546.
11. Jakob C. Association of calcaneal spurs with above average body weight. Texas A&M Health Science Center, College of Medicine, Temple, TX.
12. Standring S. Gray's Anatomy: The Anatomical Basis of Clinical Practice. 40th ed. Spain: Churchill Livingstone Elsevier; 2008. p. 1437.
13. Menz HB, Zammit GV, Landorf KB, Munteanu SE. Plantar calcaneal spurs in older people: Longitudinal traction or vertical compression? J Foot Ankle Res 2008;1:7.
14. Resnick D. Calcaneal abnormalities in articular disorders. Radiology 1977;125:355-66.

15. Prichasuk S, Subhadrabandhu T. The relationship of pes planus and calcaneal spur to plantar heel pain. Clin Orthop Relat Res 1994:192-6.
16. Riepert T, Drechsler T, Schild H, Nafe B, Mattern R. Estimation of sex on the basis of radiographs of the calcaneus. Forensic Sci Int 1996;77:133-40.

**How to cite this article:** Mahto AK, Omar S. Enthesophytes and Tubercles of the Calcaneum: An Anatomical and Clinical Understanding of the Relationship between Calcaneal Spurs and Plantar Heel Pain. Int J Sci Stud 2015;3(5):99-103.

**Source of Support:** Nil, **Conflict of Interest:** None declared.