

Comparative Study on Combination of Microdermabrasion with 35% Glycolic Acid Peel versus 35% Glycolic Acid Peel Alone for Facial Melanoses of Indian Skin Types

Mamatha P¹, K Hanumanthayya²

¹Senior Resident, Vydehi Institute of Medical Sciences & Research Center, Bengaluru, Karnataka, India, ²Professor and Head, Department of Dermatology, Vydehi Institute of Medical Sciences & Research Center, Bengaluru, Karnataka, India

Abstract

Background: Facial melanoses (FM) include a group of disorders where hyperpigmentation is predominantly present on the face and neck and are a common presentation in Indian patients. The treatment includes skin lightening agents, chemical peeling, dermabrasion, and lasers. They are used either alone or in combination.

Objective: The objective of the study was to compare the therapeutic effect of combined microdermabrasion (MDA) and 35% glycolic acid peel (GA Peel) versus 35% GAP for FM.

Materials and Methods: This study was carried out in 40 patients with FM aged 18 years above, divided into two, 20 patients each. The patients were recruited from those attending the outpatient Department of Dermatology. Detailed history and clinical examinations were done. Pigmentation was assessed by extent of involvement, depth and photography taken. Pregnant females were excluded from the study. The Group I patients were treated by MDA followed by 35% GAP and Group II patients were treated with 35% GAP alone.

Results: Our results revealed a significant decrease in the pigmentation in Group I compared to Group II.

Conclusions: As per the present study, MDA is more efficacious to decrease pigmentation when combined with GA 35% peel for epidermal melasma, post-inflammatory following acne and photodamage in three sittings. However, long-term studies are required to document complete resolution of FM with combination procedural treatments.

Key words: Chemical peels, Facial melanoses, Glycolic acid peel, Melasma, Microdermabrasion

INTRODUCTION

Facial melanoses (FM) include a group of disorders with multifactorial etiology where diffuse or patchy hyperpigmentation present on the face and neck and is commoner in older woman.¹ Hyperpigmentary skin disorders may be broadly classified into two groups – Epidermal and dermal depending on the location of the pigment.

Epidermal hyperpigmentation is characterized by brown pigmentation exclusively due to melanin pigment. Dermal pigmentation characterized by blue pigmentation or ceruloderma may be either due to melanin or non-melanin pigment.²

The etiopathogenesis³ of hyperpigmentation varies according to the etiology. Dermal hyperpigmentation is usually due to damage to the dermo-epidermal junction, resulting in pigment incontinence and deposits of melanophages in the upper dermis.

Epidermal pigmentation is caused by increased melanization in the melanocytes. The causes of facial pigmentation can be genetic or acquired. Genetic causes include ephelides, lentigines, nevus of ota, pigmentary demarcation lines, periorbital melanosis, and dyschromatosis.

Access this article online



www.ijss-sn.com

Month of Submission : 06-2015
Month of Peer Review : 07-2015
Month of Acceptance : 07-2015
Month of Publishing : 08-2015

Corresponding Author: Dr. Mamatha P, Department of Dermatology, Vydehi Institute of Medical Sciences & Research Center, No 82, EPIP Area, Nellurhalli (Post), Whitefield, Bengaluru - 560 066, Karnataka, India. Phone: +91-9035357921. E-mail: drmamathapappala@yahoo.com

Acquired causes of FM include melasma, lichen planus pigmentosus (LPP), Riehl's melanosis, erythema dyschromicum perstans (EDP) and post-inflammatory melasma (chloasma).

Melasma (Chloasma)

Melasma is derived from Greek word melas (black) while chloasma is derived from the word chloazein (green), and since the pigmentation is brown black, melasma is the preferred term.⁵

The exact etiology of melasma is not known but several factors have been implicated. Ultraviolet (UV) radiation (UVA and UVB) and visible light cause peroxidation of lipids in cellular membranes, leading to generation of free radicals, which stimulate melanogenesis. Elevated levels of estrogens and progesterone (as occurring in pregnancy) are important. Melasma also develops with estrogen and progesterone containing pills used for prostatic cancer.⁶ Melasma begins as well as worsens during pregnancy as also after profound emotional stress. Genetic factors, drugs, and cosmetics are commonly implicated.

Melasma is characterized by symmetrical hyperpigmented macules (Figure 1a), which may be blotchy, irregular, arcuate, or polycyclic and rarely have a linear or a starburst distribution.

The face is the most common site affected though rarely the pigmentation may extend on to V of the neck or may be confined to the forearms. On the face, three patterns of melasma are recognized:

- Centofacial: The most frequent (63%) pattern, with pigmentation on cheeks, forehead, upper lip, nose, and chin
- Malar: Constituting 21%, with pigmentation present only on cheeks and nose
- Mandibular: The least common (16%), with pigmentation on ramus of the mandible.

Treatment is difficult, prolonged and recurrences are common.

Lichen Planus Pigmentosus (LPP)

Though the exact etiology of LPP is not known, cosmetics including fragrances, hair dyes, and mustard oil have been incriminated.⁷

LPP is characterized by generally asymptomatic (sometimes itchy), diffuse (less frequently reticular, blotchy, or perifollicular) hyperpigmented dark brown to slate gray to black macules (Figure 2a) present mostly on the exposed areas and flexures. The lesions lack the erythematous border of EDP. Histopathology is typical of lichen planus (pigmentary incontinence and lymphocytic infiltrate seen).

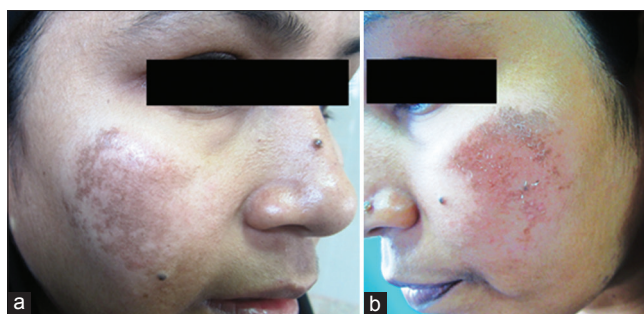


Figure 1: (a) Melasma, (b) melasma after microdermabrasion with 35% glycolic acid peel - Erythema and scaling are noticed

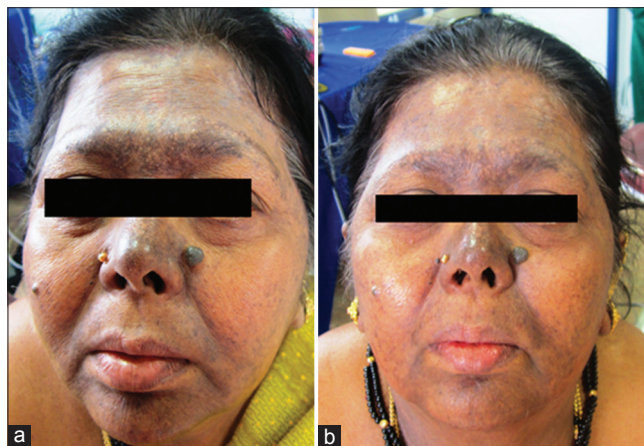


Figure 2: (a) Lichenplanus pigmentosus (LPP), (b) LPP after treatment with microdermabrasion with 35% glycolic acid peel

Riehl's Melanosis (RM) (Pigmented Cosmetic/Contact Dermatitis [CD])

RM is probably a pigmented CD to antigens present in cosmetics and textiles with anecdotal reports of airborne CD to musk ambrette and other plants.^{8,9}

RM is characterized by diffuse/patchy/rarely reticular pigmentation, often with satellite perifollicular pigmented macules and scaly follicular hyperkeratosis. Pigmentation is brown seen on lateral cheeks and sides of the neck with relative sparing of shaded areas.

Erythema Dyschromicum Perstans (Ashy Dermatitis of Ramirez, EDP)^{10,11}

It is an acquired asymptomatic idiopathic, macular, ashy gray or blue pigmented macules with raised reddish margins present on the face, trunk, and limbs. Some consider EDP as a variant of macular lichen planus.

Post-inflammatory

Post-inflammatory hyperpigmentation is a frequent occurrence following any inflammatory reaction, particularly in dark skin individuals. The various causes are Trauma, allergic disorders (Figure 3a), infections, sun exposure (Figure 4a), drug eruptions, inflammatory diseases, and therapeutic interventions.

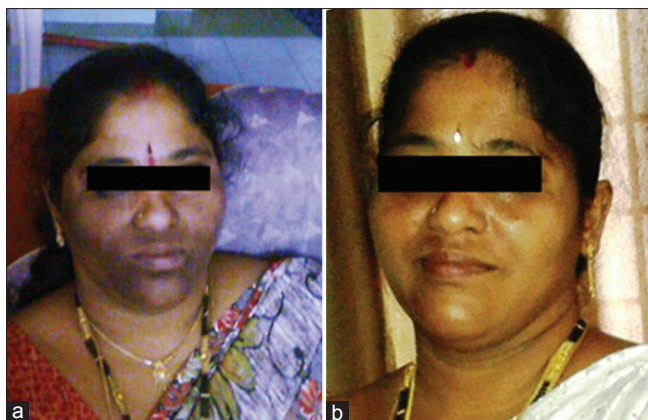

Figure 3: (a) Post-inflammatory pigmentation, (b) post-inflammatory pigmentation after treatment with 35% glycolic acid peel

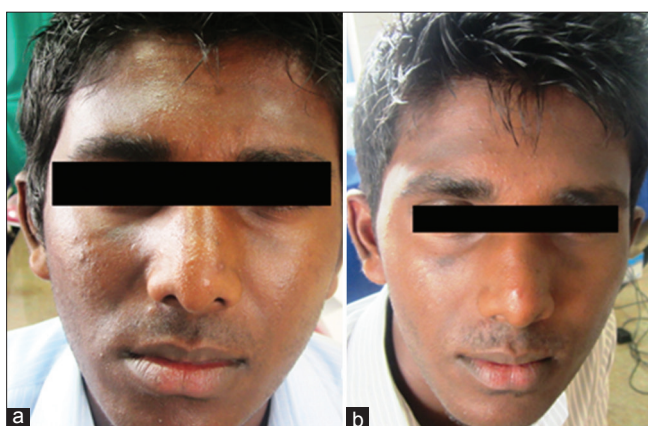

Figure 4: (a) Post-inflammatory pigmentation following acne, (b) post-inflammatory pigmentation following acne after treatment with 35% glycolic acid peel

Clinically the pigmented macules are discrete but have hazy, feathered margins roughly corresponding to the configuration of the inflammatory lesion.²

The treatment of FM¹² includes removal of aggravating factors, vigorous photoprotection and some form of active pigment reduction either with topical agents or physical modes of treatment. Topical agents include hydroquinone (HQ), which is the most common used agent, often in combination with retinoic acid, corticosteroids, azelaic acid, kojic acid, and glycolic acid (GA). Physical modes of treatment include chemical peels, dermabrasion, and lasers.

Epidermal melasma responds best, and patients who continue topical therapy after the peel, maintain improvement better than those who do not.¹³ Medium depth peels should be performed with great caution, especially in dark-skinned patients, and deep peels are not recommended for Indian skin because of high risk of prolonged or permanent pigmentary changes.¹⁴

Objective of Study

The objective of the study was to compare the therapeutic effect of combined microdermabrasion (MDA) and 35% GA peel (GAP) versus 35% GAP for FM.

MATERIALS AND METHODS

This study was carried out in 40 patients with FM aged 18 years above, divided into two groups, 20 patients each (Table 1). The patients were recruited from those attending the outpatient Department of Dermatology. Detailed history and clinical examinations were done. Pigmentation was assessed by extent of involvement, depth and photography taken. Pregnant females are excluded from the study (Table 2).

The Group I patients (Table 1) were treated by MDA followed by 35% GAP and Group II patients (Table 1) were treated with 35% GAP alone.

Procedure

The participants in both groups were primed 2 weeks before the procedure with a triple regimen (HQ, tretinoin, corticosteroid) or glyco 6 night time and sunscreen day time. Two days prior to the procedure, the patients of both groups are advised to stop night creams.

Table 1: The detailed statistics of the patients for the both the groups with respect to age and sex

Description	Group I (20 patients)		Group II (20 patients)	
	Number of patients	%	Number of patients	%
Sex				
Males	8	40	10	50
Females	12	60	10	50
Age group				
18-25 years	7	30	6	30
26-35 years	6	30	8	40
36-45 years	6	35	4	20
46-60 years	1	05	2	10

Table 2: Etiology of facial melanoses of participating groups

Description	Group I (20 patients)		Group II (20 patients)	
	Number of patients	%	Number of patients	%
Melasma	12	70	8	40
Epidermal	5		3	
Mixed	7		5	
Post-inflammatory	8	30	12	60
LPP	1		-	
Acne	4		10	
Photo-melanoses	3		2	

LPP: Lichenplanus pigmentosus

Group I Patients - Treatment***Combination of MDA followed by 35% GAP***

After cleaning and degreasing with alcohol, MDA was done on the pigmented areas. Later the aluminum oxide crystals are removed with gauze and then 35% GAP is applied. After 3-5 min, the peel is neutralized with water or peel neutralizer depending on the skin sensitivity. Then the participants were applied mild corticosteroid creams for 2 days and sunscreens continued. Night creams followed after 2 days.

Procedure done every 2-3 weeks for 12 weeks. At the end of 12 weeks, results and side effects were noted.

Group II Patients - Treatment***35% GAP***

After cleaning and degreasing with alcohol on the pigmented areas, 35% GAP is applied. After 3-5 min, the peel is neutralized with water or peel neutralizer depending on the skin sensitivity. Then the participants were applied mild corticosteroid creams for 2 days and sunscreens continued. Night creams followed after 2 days. Procedure done every 2-3 weeks for 12 weeks. At the end of 12 weeks, results and side effects were noted.

The patients were strictly instructed to follow the post procedure treatment including the application of sunscreens and night creams.

RESULTS

On the basis of patients and observer assessment changes were noted by visual inspection and with woods lamp during each sitting. The final results were recorded through photographs and knowing the total satisfaction. The abstract of results are tabulated at Table 3.

DISCUSSIONS

Facial Melanoses, most commonly caused by melasma, other conditions being post-inflammatory due to acne, photodamage and LPP (Table 2).

The observations made during the study are post-inflammatory pigmentation following acne is more common in 18-30 years age group, photomelanoses occurred most commonly in males, melasma commonly seen in 30-45 years age group, LPP commonly noticed in females, melasma of recent onset regressed after two sittings (2 patients), males have predominantly epidermal melasma - 80% reduction seen in epidermal melasma after three sittings, Only 40-50% reduction noted in mixed melasma at the end of 3 months (Figure 1b),

complete resolution not seen, 50% reduction seen for LPP (Figure 2b), photomelanosis regressed after two sittings (Figure 4b), 60% reduction is seen in post-inflammatory pigmentation following acne at the end of 3 months. Post-inflammatory pigmentation following CD resolved completely after two sittings with 35% GAP (Figure 3b), short contact time is noticed after application of peel following MDA. With 35% glycolic peel alone only 25-50% reduction is seen at the end of 3 months, patients satisfaction is more with MDA with 35% glycolic peel (Table 3, Figure 2b).

FM causes cosmetic disfigurement with significant emotional impact. Its treatment includes removal of provoking factors, vigorous photo protection, and some form of active pigment reduction either with topical agents or physical modes of treatment. There is no universally effective specific therapy - existing agents have varying degrees of efficacy and relapses are frequent. In our present study, MDA is combined with 35% GAP gives significant results. The findings were based on the visual observation (Table 3).

MDA is an FDA approved process first introduced in 1985 and is a popular method used to treat scars, acne and other cosmetic-dermatologic conditions like pigmentation.¹⁵ MDA, popularly known as body polishing,¹⁶ is a simple and safe, office cosmetic procedure. In this procedure, aluminum oxide crystals are blown onto the face and then vacuumed off, using a single handpiece. MDA peels the stratum corneum thereby forming channels for deeper penetration of chemicals. Local side effects are uncommon and transient but include pain, burning, photosensitivity, diffuse hyperpigmentation (Table 4).

GA is a superficial peeling agent that is made from sugar cane. It is often considered the most active and beneficial of the alpha-hydroxy-acids. At higher concentrations it causes epidermolysis, decreases melanin production by direct inhibition of tyrosinase, it also acts as a humectant.¹²

Both procedures are easy to perform and manual control is possible. The results with hydroxy acids are time

Table 3: Results of participating groups

Brief description	Group I (total 20 patients) (MDA+GAP35)	Group II (total 20 patients) (GAP35)
Improvement %		
0-25	2 patients	5 patients
26-50	9 patients	11 patients
50-75	7 patients	4 patients
100	2 patients	0 patients

MDA: Microdermabrasion, GAP35: Glycolic acid peel 35%

Table 4: Side effects noticed in participating groups

Side effects	Group I (total 20 patients) (MDA+GAP35)	Group II (total 20 patients) (GAP35)
Burning	Noticed in all patients	12 patients
Erythema	Noticed in all patients	15 patients
Swelling	Noticed in all patients	-
PIH	6 patients	4 patients
Scaling	12 patients	-
Complication encountered with significant scaling (Figure 5)	1 patient	-

MDA: Microdermabrasion, GAP35: Glycolic acid peel 35%, PIH: Post-inflammatory hyperpigmentation

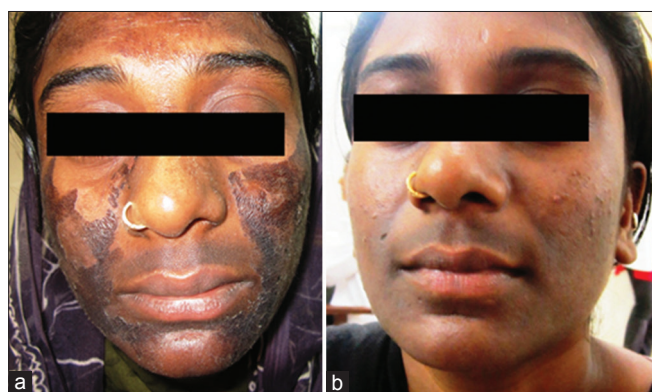

Figure 5: (a) Complication encountered during microdermabrasion with 35% glycolic acid peel (scaling and pigmentation), (b) post-treatment with mild steroids and moisturizers – (after 4 days)

dependent.¹⁷ Appearance of erythema is the end point of neutralization of the peel. The most common observed side effect in our study is intense burning, erythema followed by pigmentation which are usually transient.

The post peel reactive hyperpigmentation, scaling, and erythema can be tackled by judicious use of mild topical steroids for 2 days and continuation of sunscreens (Figure 5a and b). MDA is safer when compared to mechanical dermabrasion. Scarring and hypopigmentation are rare with MDA. The pigment clearance achieved should be maintained by regular use of sunscreens.

In a study by Kunachak *et al.*¹⁸ from Thailand 533 patients with resistant melasma were treated by mechanical dermabrasion, they achieved 97% clearance for the follow-up period of 5 years. They observed complications such as hypertrophic scars and permanent hypopigmentation.

According to study by Grover and Reddu,¹⁹ New Delhi GAP is useful especially in superficial scarring and melasma, moderately successful in acne patients with no response in dermal pigmentation.

According to study by Rashmi Kumari and Thappa D.M., JIPMER²⁰ found 20-35% GAP and 10-20% TCA peel are found to be equally effective for epidermal and mixed melasma.

In our study, combining MDA with GA 35% found to be effective for epidermal melasma, solar melanoses and post-inflammatory pigmentation for acne with mixed results for dermal melasma (Table 3).

CONCLUSION

FM is a disfiguring and disturbing cosmetic disability. Melasma, post-inflammatory hyperpigmentation, are most common. In the present study, MDA is more efficacious to decrease pigmentation when combined with GA 35% peel for epidermal melasma, post-inflammatory following acne and photodamage in three sittings. However, long-term studies are required to document complete resolution of FM with combination procedural treatment.

REFERENCES

- Bleehen SS, Anstey AV. In: Burns T, Breathnach S, Cox N, Griffiths C, editors. Disorders of Skin Colour in Rook's Text Book of Dermatology. 7th ed. Oxford: Blackwell Science; 2004. p. 39.39-39.42.
- Valia RG, Vallia AR. Pigmentary Disorders in IADVL Text Book of Dermatology. 3rd ed., Vol. I, Ch. 25. Mumbai: Bhalani Publishing House; 2008. p. 760-87.
- Ortonne JP, Bahadoran P. Hypomelanoses and hyper-melanoses. In: Freedberg IM, editor. Fitzpatrick's Dermatology in General Medicine. 6th ed. New York: McGraw-Hill; 2003. p. 819-25.
- Khanna N, Rasool S. Review article: Facial melanoses: Indian perspective. Indian J Dermatol Venereol Leprol 2011;77:552-64.
- Bandyopadhyay D. Topical treatment of melasma. Indian J Dermatol 2009;54:3039.
- Grimes PE, Yamada N, Bhawan J. Light microscopic, immunohistochemical, and ultrastructural alterations in patients with melasma. Am J Dermatopathol 2005;27:96-101.
- Bhutani LK, Bedi TR, Pandhi RK, Nayak NC. Lichen planus pigmentosus. Dermatologica 1974;149:43-50.
- Pires MC, Manoel Silva dos Reis V, Mitelmann R, Moreira F. Pigmented contact dermatitis due to *Plathymenia foliosa* dust. Contact Dermatitis 1999;40:339.
- Nath AK, Thappa DM. Kumkum-induced dermatitis: An analysis of 46 cases. Clin Exp Dermatol 2007;32:385-7.
- Novick NL, Phelps R. Erythema dyschromicum perstans. Int J Dermatol 1985;24:630-3.
- Convit J, Kerdel-Vegas F, Rodriguez G. Erythema dyschromicum perstans: A hitherto undescribed skin disease. J Invest Dermatol 1961;6:457-62.
- Khunger N, Sachdev M. Practical Manual of Cosmetic Dermatology and Surgery. New Delhi, India: Mehata Publications; 2010.
- Lawrence N, Cox SE, Brody HJ. Treatment of melasma with Jessner's solution versus glycolic acid: A comparison of clinical efficacy and evaluation of the predictive ability of Wood's light examination. J Am Acad Dermatol 1997;36:589-93.
- Khunger N, IADVL Task Force. Standard guidelines of care for chemical peels. Indian J Dermatol Venereol Leprol 2008;74:S5-12.
- Gill HS, Andrews SN, Sakthivel SK, Fedanov A, Williams IR, Garber DA, *et al.* Selective removal of stratum corneum by microdermabrasion to increase skin permeability. Eur J Pharm Sci 2009;38:95-103.
- Savant SS. Text Book of Dermatotomy and Cosmetology. 2nd ed. Mumbai, India: ASCAD Publications; 2008.

17. Kalla G, Garg A, Kachhawa D. Chemical peeling: Glycolic acid versus trichloroacetic acid in melisma. *Indian J Dermatol Venereol Leprol* 2001;67:82-4.
18. Kunachak S, Leelaudomlipi P, Wongwaisayawan S. Dermabrasion: A curative treatment for melasma. *Aesthetic Plast Surg* 2001;25:114-7.
19. Grover C, Reddu BS. The therapeutic value of glycolic acid peels in dermatology. *Indian J Dermatol Venereol Leprol* 2003;69:148-50.
20. Kumari R, Thappa DM. Comparative study of trichloroacetic acid versus glycolic acid chemical peels in the treatment of melasma. *Indian J Dermatol Venereol Leprol* 2010;76:447.

How to cite this article: Mamatha P, Hanumanthayya K. Comparative Study on Combination of Microdermabrasion with 35% Glycolic Acid Peel versus 35% Glycolic Acid Peel Alone for Facial Melanoses of Indian Skin Types. *Int J Sci Stud* 2015;3(5):112-117.

Source of Support: Nil, **Conflict of Interest:** None declared.