Print ISSN: 2321-6379
Online ISSN: 2321-595X
DOI: 10.17354/ijss/2016/644

Case Report

Pericardial Effusion in a Patient with Hypothyroidism Successfully Treated Without Pericardiocentesis

Aparna Patange, Ajinkya Bahulekar, Piyush Prajapati, Saurabh Gandhi, Monika Chouhan

Department of General Medicine, Krishna Institute of Medical Sciences, Karad, Maharashtra, India

Abstract

Hypothyroidism presenting with pericardial effusion is commonly seen. Complete resolution of effusion without pericardiocentesis after thyroid hormone supplement is not reported in literature. We are reporting a case of 70-year-old female presented with breathlessness. She was diagnosed to have moderate pericardial effusion secondary to hypothyroidism. Her symptoms and pericardial effusion completely resolved after 1 month therapy of thyroid hormone without pericardiocentesis. Her QRS voltages on electrocardiogram improved with thyroid hormone supplement. There is no recurrence of symptoms and pericardial effusion after follow-up of 1 year.

Key words: Hypothyroidism, Pericardiocentesis, Pericardial effusion, QRS voltages, Thyroid hormone supplement

INTRODUCTION

Hypothyroidism is the most common pathological hormone deficiency.[1] It is more common in women and its incidence increases with age. Common signs and symptoms of hypothyroidism include lethargy, cold intolerance, weight gain, constipation, dry skin, alopecia, hoarse voice, pedal edema weight gain, bradycardia and psychomotor retardation.[2,3] We are reporting a case of elderly female who presented with moderate pericardial effusion, the later turned to be secondary to hypothyroidism. Patient was treated with 100 mcg of thyroxine supplement after which pericardial effusion was resolved completely over a period of 1-month, evidenced by follow-up two-dimensional (2D) echocardiogram (ECHO) and Doppler study.

CASE REPORT

A 70-year-old elderly female presented on August 24, 2015, with a history of breathlessness on exertion, bilateral lower limb swelling, and hoarseness of voice of 15 days duration. Initially, she had dyspnea on heavy work which later progressed to dyspnea on routine work. On examination, she was conscious oriented, obeying verbal commands. Pulse was 60/min blood pressure - 120/80 mm of Hg, On auscultation heart sounds were muffled, ankle reflexes were delayed bilaterally, SpO_2 was 98 % without O_2, electrocardiogram (ECG) showed low voltage complexes, chest radiogram showed marked cardiomegaly, arterial blood gas was normal, and 2D ECHO showed moderate pericardial effusion with no signs of cardiac tamponade.

All routine tests are done to rule out the cause of pericardial effusion. Keeping in mind her symptoms and signs and low voltages in ECG, thyroid function tests (TFTs) are also done and they found to be grossly abnormal which included T3 – 30 ng/dl, T4 - 2.0 μg/dl, and thyroid-stimulating hormone (TSH) - more than 40 mIU/L. which was indicative of hypothyroidism. The patient was put on tablet levothyroxine 100 μg OD. Patient felt symptomatically better and was discharged from hospital on August 31, 2015. Repeat 2D ECHO done on follow-up on October 07, 2015, suggestive of normal size cardiac chambers, no pericardial effusion with good left ventricle systolic function. TFT done after 3 months of discharge showing T3 - 140 ng/dl, T4 - 10.1 μg/dl, and TSH - 5.6 mIU/L. The patient is coming to follow-up and fine till now a

Access this article online

www.ijss-sn.com

Month of Submission : 10-2016
Month of Peer Review : 11-2016
Month of Acceptance : 11-2016
Month of Publishing : 12-2016

Corresponding Author: Dr. Piyush Prajapati, Department of General Medicine, Krishna Institute of Medical Sciences, Karad, Maharashtra, India. E-mail : prajapatipiyush786@gmail.com

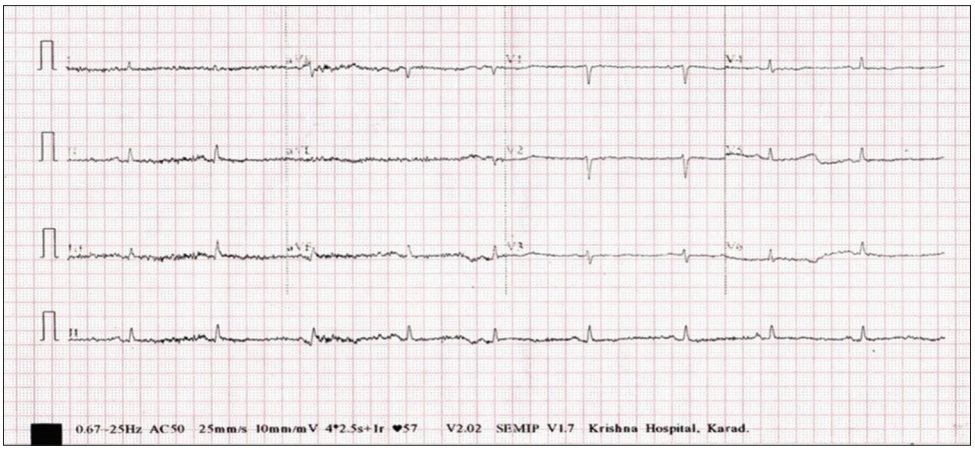

Figure 1: Electrocardiogram on admission

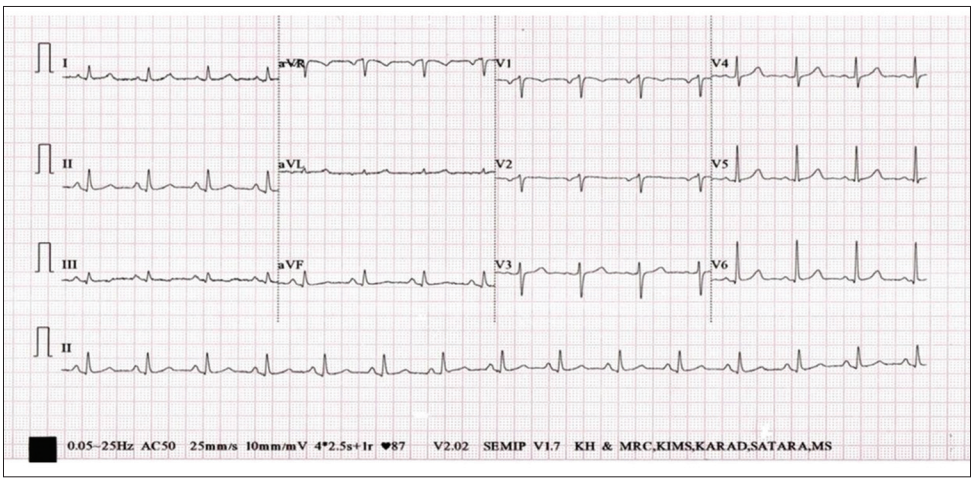

Figure 2: Electrocardiogram on discharge (with improved voltages)

Table 1: Improvement in thyroid function

TFT	August 25, 2015	November 25, 2015
T3	30	140
T4	2.0	10.1
TSH	>40	5.6

TSH: Thyroid-stimulating hormone, TFT: Thyroid function tests

follow-up 2D ECHO done after 1 year on August 27, 2016, which is also normal with no pericardial effusion (Table 1 and Figures 1-5).

DISCUSSION

Any defect in hypothalamic-pituitary-thyroid axis may result in the development of hypothyroidism. Hypothyroidism is associated with some cardiovascular findings such as increased systemic vascular resistance, decreased cardiac contractility, decreased cardiac output, atherosclerosis, coronary artery disease, and pericardial effusion. Pericardial effusion can be detected in 25% of hypothyroid patients.[4] Hypothyroidism leads to decreased synthesis of albumin. Increased permeability of capillaries results in loss of albumin in intravascular compartments through increased transcapillary escape rate of albumin, eventually leading to reduced plasma volume. Thus, the consequent increase in concentration of albumin in extravascular compartment causes increased interstitial fluid volume and impaired lymphatic drainage.[5,6]

Normally, there is 10-50 ml of fluid present between visceral and parietal layers of pericardium, which is produced by pericardium through ultrafiltration of plasma. The above-mentioned pathological mechanisms cause an increase in the volume of the pericardial fluid leading to moderate to severe pericardial effusion. As in our patient, the moderate to severe pericardial effusion can be completely cured without pericardiocentesis only with thyroid hormone supplement. Because of insidious and nonspecific characteristics of the signs and symptoms of hypothyroidism along with rare occurrence of moderate to severe pericardial effusion in some patients, the possibilities of hypothyroidism may be overlooked in the differential

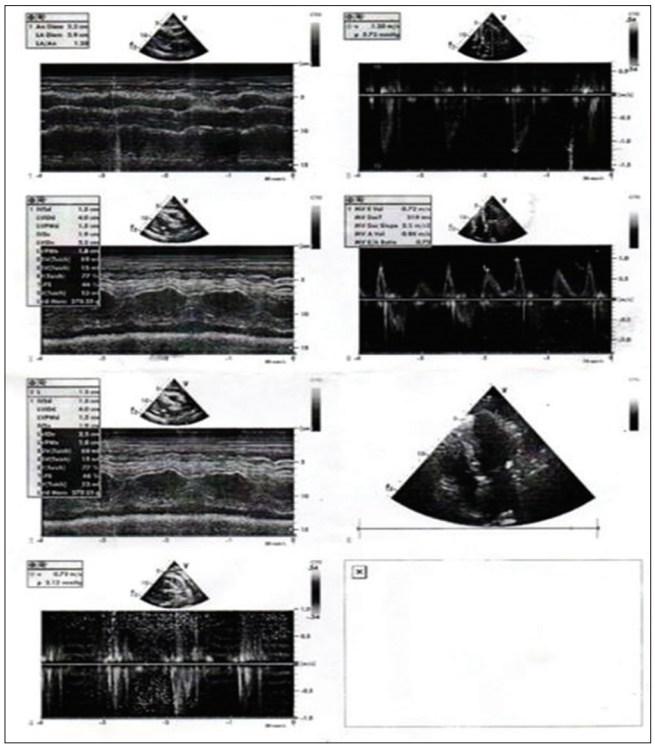

Figure 3: Two-dimensional echocardiogram on admission

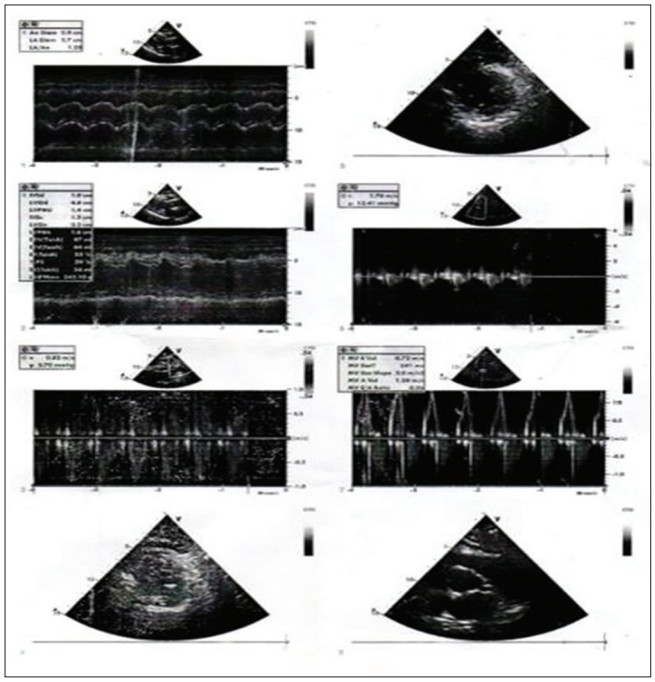

Figure 4: Two-dimensional echocardiogram on discharge

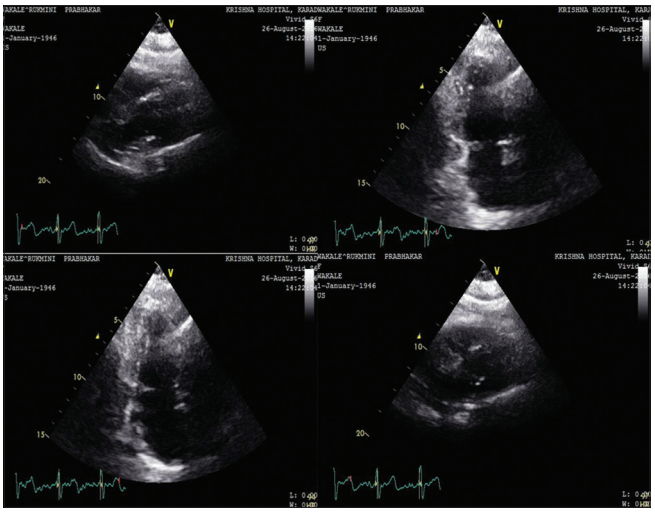

Figure 5: Two-dimensional echocardiogram later after 1 year (On August 26, 2016) – S/O No pericardial effusion with good left ventricle function

diagnosis of moderate to severe pericardial effusion. As hypothyroidism is treatable cause of moderate to severe pericardial effusion the diagnosis must be established and treatment should be promptly started.[7] In patients with unexplained pericardial effusion, TFTs and ECHO should always be performed. After obtaining euthyroid status with treatment, pericardial effusion slowly disappears, preventing unnecessary pericardiocentesis in these patients.[8]

REFERENCES

1. Roberts CG, Ladenson PW. Hypothyroidism. Lancet 2004 6;363:793-803.
2. Wiersinga WM. Hypothyroidism and myxoedema coma. In: De Groot LJ, editor. Endocrinology Adult and Pediatric. 6th ed. Philadelphia: Saunders; 2010. p. 1607-22.
3. Larsen PR, Davies TF. Hypothyroidism and thyroiditis. In: Larsen PR, Kronenberg HM, Melmed S, Polonsky KS, editors. Williams Textbook of Endocrinology. 10th ed. Philadelphia, Pennsylvania: Saunders; 2003. p. 423-55.
4. Kahaly GJ, Dillmann WH. Thyroid hormone action in the heart. Endocr Rev 2005;26:704-28.
5. Hollenberg M, Dougherty J. Lymph flow and 131-I-albumin resorption from pericardial effusions in man. Am J Cardiol 1969;24:514-22.
6. Sachdev Y, Hall R. Effusions into body cavities in hypothyroidism. Lancet 1975 8;1:564-6.
7. Ekka M, Ali I, Aggarwal P, Jamshed N. Cardiac tamponade as initial presenting feature of primary hypothyroidism in the ED. Am J Emerg Med 2014;32:683.e1-3.
8. Omura Y, Ugi S, Sugimoto T, Nishio Y, Maegawa H, Kashiwagi A. Massive pericardial effusion secondary to Hashimoto's disease. Eur J Intern Med 2007;18:438-40.

How to cite this article: Patange A, Bahulekar A, Prajapati P, Gandhi S, Chouhan M. Pericardial Effusion in a Patient with Hypothyroidism Successfully Treated Without Pericardiocentesis. Int J Sci Stud 2016;4(9):187-189.

Source of Support: Nil, **Conflict of Interest:** None declared.