

# Orbital Reconstruction of a Severely Contracted Socket Using Autogenous Derma-Fat Graft: A Case Report

HR Padmini<sup>1</sup>, Venita Juliet Noronha<sup>2</sup>

<sup>1</sup>Professor & Head, Department of Ophthalmology, Adichunchanagiri Institute of Medical Sciences, Mandya, Karnataka, India, <sup>2</sup>Post-graduate, Department of Ophthalmology, Adichunchanagiri Institute of Medical Sciences, Mandya, Karnataka, India

## Abstract

Severely contracted sockets pose a problem to all oculoplastic surgeons. All sockets have a tendency to contract after enucleation or evisceration, and the etiologies are varied. Earlier methods employed to correct were use of mucous membrane and skin grafting. Derma-fat graft (DFG) supplies orbital volume, eliminates the risk of implant extrusion, preserves the existing conjunctiva and advances it into the fornices. This case report describes the management of DFG in an 18 years old for the management of a severely contracted socket. Post-operatively after the reconstruction, a prosthetic eye was kept, which was well-accepted.

**Keywords:** Anophthalmos, Artificial eye, Orbital implants

## INTRODUCTION

Anophthalmic eye and contracted socket pose a problem to all ophthalmologists. There are several etiologies resulting in contracted socket and varies from infections like endophthalmitis and panophthalmitis, tumors like retinoblastoma, scarring of conjunctiva, especially after chemical injuries, improper or not using artificial eye etc.<sup>1</sup>

Autogenous derma-fat grafts (DFG) can be used as primary as well as secondary orbital implant to recreate a socket and volume augmentation and hence that a prosthetic implant can be kept.<sup>2</sup> There is a variety of artificial implants available nowadays but the significance of autogenous grafts should not be discounted as the rate of complications is significantly lower. This case report describes a case of an 18-year-old who underwent enucleation for a phthisical eye following penetrating eye

injury and underwent orbital reconstruction with DFG and a prosthetic eye implantation.

## CASE REPORT

An 18-year-old girl presented with a phthisical left eye with a contracted socket following penetrating ocular injury at the age of 14 years. She had undergone placement of artificial left eye over her existing phthisical eye, but got rejected 2 months prior to presentation. Examination revealed an unaided snellen visual acuity of 6/60-6/6 in the right eye with refraction correction of -2.5D Sph and no light perception in the left eye. Anterior segment and fundus examination of the right eye were unremarkable. Examination of the left eye showed phthisical eye (Figures 1 and 2).

After obtaining informed consent, the girl underwent socket reconstruction with gluteal DFG under general anesthesia. As the first step, the phthisical eye was enucleated and hemostasis was obtained (Figure 3).

The graft was obtained from the left gluteal region. A 20 mm × 20 mm area of dermis with underlying fat was harvested (Figure 4). The gluteal wound was closed with interrupted 4-0 vicryl sutures. The epidermis was stripped

Access this article online



Website:  
[www.ijss-sn.com](http://www.ijss-sn.com)

## Corresponding Author:

Dr. Venita Juliet Noronha, Department of Ophthalmology, Adichunchanagiri Institute of Medical Sciences, Mandya, Karnataka - 571 448, India.  
E-mail: [venitajuliet@gmail.com](mailto:venitajuliet@gmail.com)

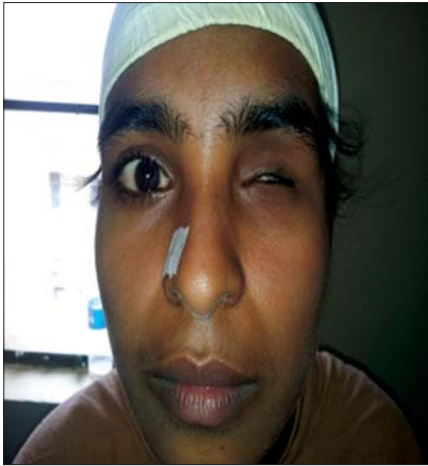

Figure 1: Left phthisical eye

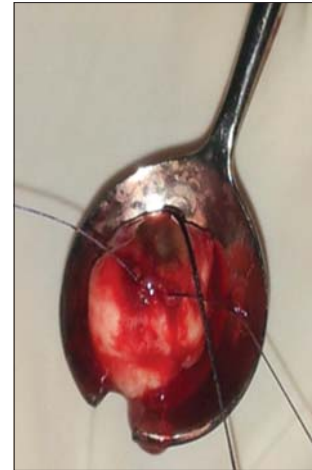


Figure 3: Enucleated left eye

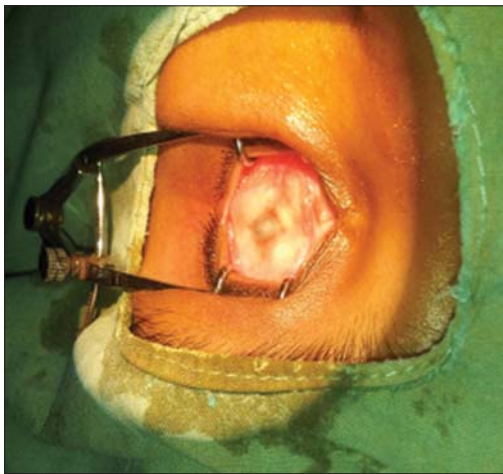

Figure 2: Pre-operative picture

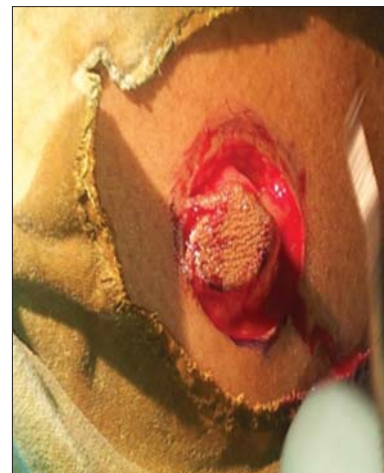

Figure 4: Derma-fat being taken from gluteal region

off from the graft. The DFG was then inserted into the orbital socket cavity with the dermis layer anteriorly, and the fatty side posteriorly oriented. The extraocular muscles and conjunctiva were sutured into the border of the DFG using 6-0 vicryl sutures for the former and 5-0 interrupted vicryl sutures for the latter (Figure 5). After instillation of antibiotic eye drops, the eye was patched with a light pressure pad.

The extraocular muscles and conjunctiva was sutured into the border of the dermis fat graft using 6-0 vicryl sutures for the former and 5-0 interrupted vicryl sutures for the latter.

On the 1<sup>st</sup> post-operative day, examination showed the graft tissue well apposed with the host tissue. Thus, the patient was discharged with instructions to use antibiotic eye drops. When seen in the clinic a month later, the DFG was well integrated with the orbital tissue. The graft-host junction was healthy, with epithelialization of the surface of the graft. There was no evidence of necrosis or infection.

After 6 weeks of the primary surgery a prosthetic eye was implanted (Figures 6 and 7).

## DISCUSSION

The first use of DFG was by Smith and Petrelli in 1978.<sup>3</sup> It can be used as primary implant after enucleation or as a secondary implant following rejection of artificial implants.

DFG as the name suggests is composed of dermis and subcutaneous fat. The epidermis is stripped off from the graft. The dermis is retained as it supposedly enhances graft vascularization and decrease the incidence of fat atrophy. Most common sites, which are used to harvest the graft is the gluteal area, but other areas such as the abdomen, hip, inner thigh and the periumbilical region can be used.

The most important factor pertaining to the acceptance of the graft is the vascular supply of the orbit. Thus, in case of compromised vascular supply, such as after severe trauma,

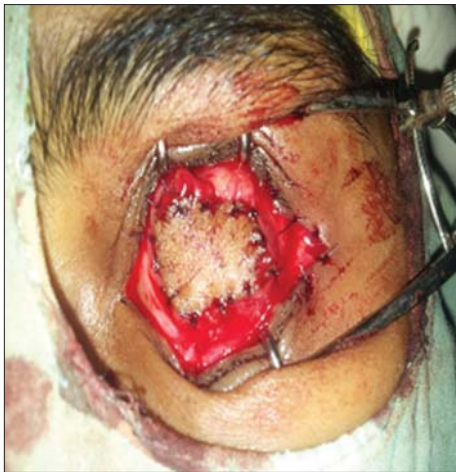

Figure 5: Graft implanted into the socket



Figure 6: Different sizes of artificial eye



Figure 7: Prosthetic eye in situ

chemical burns, irradiation, systemic vascular disease, etc. it is contra-indicated. Other factors to minimize the complications

**Table 1: Indications and contra-indications of autogenous grafts**

Indications	Contra-indications
Primary implantation after post enucleation, post evisceration	Severely contracted socket
Secondary implantation post irradiation	Compromised orbital vascular supply
	Multiple orbital surgeries

are to avoid the following: Excessive cautery of the graft bed, use of oversized grafts, excessive handling of the graft and excessive pressure on the graft following implantation. Indications and contra-indications are in Table 1.<sup>4</sup>

DFG helps not only to replace lost orbital volume but also preserves the conjunctival surface area. This is achieved by partially covering the implanted dermis with conjunctiva and leaving an exposed area of dermis similar to the diameter of the cornea. Normal fornix depth is also maintained.

Complications are usually minor. They include hematoma, infection, central graft ulceration, granulomas, fat atrophy, and volume loss. Most complications can be avoided by employing the careful surgical techniques. The problems associated with the management of ophthalmic sockets such as implant extrusion, implant migration and conjunctival shrinkage resulting in contracted sockets are more commonly seen with the traditional methods of reconstruction.<sup>5</sup>

## CONCLUSION

DFG after primary enucleation demonstrates a good maintenance of orbital soft tissue volume and periorbital symmetry. There are very little complications encountered. Autogenous implants are effective in maintaining orbital volume while preserving the fornices and conserving the conjunctiva. It is associated with low morbidity and a satisfactory cosmetic result.

## REFERENCES

1. Krishna G. Contracted sockets--I (aetiology and types). *Indian J Ophthalmol* 1980;28:117-20.
2. Smith B, Bosniak S, Nesi F, Lisman R. Dermis-fat orbital implantation: 118 cases. *Ophthalmic Surg* 1983;14:941-3.
3. Smith B, Petrelli R. Dermis-fat graft as a movable implant within the muscle cone. *Am J Ophthalmol* 1978;85:62-6.
4. Al-Mujaini A, Ganesh A, Al-Zuhaibi S. Autogenous dermis-fat orbital implant for anophthalmic socket. *Sultan Qaboos Univ Med J* 2007;7:145-8.
5. Betharia SM, Patil ND. Dermis fat grafting in contracted socket. *Indian J Ophthalmol* 1988;36:110-2.

**How to cite this article:** Padmini HR, Noronha VJ. Orbital reconstruction of a severely contracted socket using autogenous dermaf fat graft: A case report. *Int J Sci Stud* 2014;2(9):109-111.

**Source of Support:** Nil, **Conflict of Interest:** None declared