

# Meckel's Diverticulum and its Presentations: A Case Series

Korumilli Ramesh Kumar<sup>1</sup>, B Ananda Rama Rao<sup>2</sup>, D Murali Krishna<sup>3</sup>, K Ashok Kumar Raju<sup>3</sup>, P Phaniteja<sup>4</sup>

<sup>1</sup>Professor and Head, Department of General Surgery, SVS Medical College, Mahabubnagar, Telangana, India, <sup>2</sup>Professor, Department of General Surgery, SVS Medical College, Mahabubnagar, Telangana, India, <sup>3</sup>Post-graduate, Department of General Surgery, SVS Medical College, Mahabubnagar, Telangana, India

## Abstract

Meckel's diverticulum is a common congenital abnormality of gastrointestinal tract, resulting from an incomplete obliteration of the vitelline duct during the 5<sup>th</sup> week of the gestation. It may generally remain silent and asymptomatic but life threatening complications like perforation and intestinal obstruction can occur sometimes, making it important to know its detailed anatomy and pathophysiology. The most common complications of Meckel's diverticulum are perforation, intestinal obstruction, hemorrhage, acute diverticulitis, etc. We are presenting six cases of Meckel's diverticulum with varied presentations during a span of 1 year in our institution. One case presented as intestinal obstruction, two with perforation, one case of incidental Meckel's diverticulum, one case of diverticulitis and one double Meckel's diverticulum.

**Key words:** Capsule endoscopy, Diverticulitis, Intestinal obstruction, Volvulus

## INTRODUCTION

Meckel's diverticulum was described by Fabricius Hildanus in 1598.<sup>1</sup> It represents the patent intestinal end of the vitello intestinal duct. It possesses all three coats of intestine. In 20% of the cases the mucosa contains heterotopic gastric, colonic, or pancreatic tissue. The various anomalies include, a fibrous band from distal ileum to the anterior abdominal wall, an umbilical-intestinal fistula, a mucosa lined cyst, or sometimes an umbilical sinus of these the commonest anomaly is Meckel Diverticulum. It presents in 2% of the population at a ratio of three male to one female. Its usual location is 30-60 cm from ileocaecal valve. The presence of this heterotopic tissue may lead to other complications like hemorrhage, chronic peptic ulceration, and perforation. It generally remains silent but it may present with life threatening complications like intestinal obstruction, perforation, hemorrhage,<sup>2</sup> etc. These complications present with nonspecific symptoms

which mimic common gastrointestinal disorders<sup>3</sup> like appendicitis, making diagnostic difficulty. Most of the cases are diagnosed intraoperatively. Meckel's diverticulum is a true diverticulum containing all layers; it is usually situated on antimesenteric border, approximately seen in 2% of population.<sup>4</sup> Meckel's diverticulum is usually lined by intestinal mucosa, sometimes it may be lined by heterotopic gastric or pancreatic tissue and less commonly colonic or endometrial or hepatobiliary tissue.<sup>4</sup> Meckel's diverticulum is a remnant of vitello intestinal duct. Normally vitelline duct regresses by the 5<sup>th</sup>-7<sup>th</sup> week of gestation; if it fails to regress it may result in Meckel's diverticulum or a fibrous band attaching the distal ileum to abdominal wall or a fistula or umbilical sinus.<sup>4</sup> Most patients are asymptomatic and the life time risk of the developing complications is 4-6%.<sup>5</sup> Hemorrhage is the most common complication in adults and the second most in children;<sup>6</sup> it is due to presence of heterotopic gastric or pancreatic mucosa causing ulceration of adjacent ileal mucosa. Obstruction due to Meckel's diverticulum is the most common complication in children and second most common complication in adults.<sup>6</sup> Obstruction is due to volvulus or intussusception or Littre's hernia or adhesion and kinking or due to stricture secondary to chronic diverticulitis.<sup>4,7</sup> Complications of Meckel's diverticulum include hemorrhage, obstruction, diverticulitis and perforation and technetium 99 m pertechnetate scan

### Access this article online



www.ijss-sn.com

**Month of Submission :** 10-2015  
**Month of Peer Review :** 11-2015  
**Month of Acceptance :** 12-2015  
**Month of Publishing :** 12-2015

**Corresponding Author:** Dr. Korumilli Ramesh Kumar, Plot 70, Gruhalaxmi Colony, Old Kakaguda, Secunderabad - 500 015, Telangana, India. Phone: +91-9885044904. E-mail: rameshkorumilli@gmail.com

is used for diagnosis which is highly sensitive and specific in both pediatric and adult population.<sup>7,8</sup> Other diagnostic modalities include capsule endoscopy and angiography. If conservative methods fail to control hemorrhage diverticulectomy or ileal segment resection with end to end anastomosis are done perforation is due to diverticulitis or ulceration due to heterotopic mucosa or rarely due to foreign body (like fish bone, chicken bone, etc.). Treatment of perforation is segmental resection with end to end anastomosis. Pathophysiology of diverticulitis is similar to that of acute appendicitis, with inflammation secondary to stasis (due to fecolith or parasites or foreign body) and bacterial infection.<sup>8,9</sup> It may also result from heterotopic mucosa. Usually, treatment is diverticulectomy.

We are herewith reporting six cases of Meckel's diverticulum with varied presentations in 1 year. During our emergency surgeries one case presented as intestinal obstruction because of fibrous band from Meckel's diverticulum to base of appendix. The second case presented with picture of peritonitis which showed a perforated Meckel's diverticulum. Third case presented with intestinal obstruction with a recto sigmoid tumor where a double Meckel's diverticulum was found. Fourth case an incidental Meckel's diverticulum seen during an emergency laparoscopic appendectomy procedure. Another case was presented as acute appendicitis where Meckel's diverticulum was found. One more case presented as peritonitis with hypotension in which an ileal perforation and also a perforated Meckel's diverticulum was found.

## CASE REPORT

### Case 1

A 26-year-old male patient presented to emergency with complaints of abdominal pain, distension of abdomen of 3 days duration and bilious vomiting for 1 day. On examination vitals were stable, abdominal distension present with increased bowel sounds. A clinical diagnosis of intestinal obstruction was made, confirmed by plain X-ray and ultrasound abdomen. Diagnosis of small bowel obstruction was made, on laparotomy distended ileal loops with volvulus of ileal loop over a fibrous band extending from tip of Meckel's diverticulum to base of umbilicus (Figure 1). Volvulus was undone and fibrous band excised. Meckel's diverticulum was left unresected as it was having wide base. Post-operative period was uneventful.

### Case 2

A 40-year-old female presented to emergency with history of pain abdomen for 1 day, distension of abdomen

for 1 day. On examination, patient had hypotension. Per abdomen diffuse tenderness present with guarding and rigidity. Clinical diagnosis of peritonitis secondary to perforation of a hollow viscus was made. After resuscitation X-ray erect abdomen and ultrasound was done which confirmed clinical diagnosis. Patient was posted for laparotomy there was a perforated Meckel's diverticulum. Resection of segment of ileum including diverticulum with end to end anastomosis was done. Post-operative period was uneventful.

### Case 3

A 50-year-old male presented to emergency with distension of abdomen for 2 days, not passing stools for 2 days, vomiting for 1 day. On examination, vitals were stable. Per abdomen distension of abdomen present with no palpable masses with increased bowel sounds, on digital rectal examination - rectum was empty with no fecal staining and palpable masses. Clinical diagnosis of obstruction was made, confirmed by X-ray erect

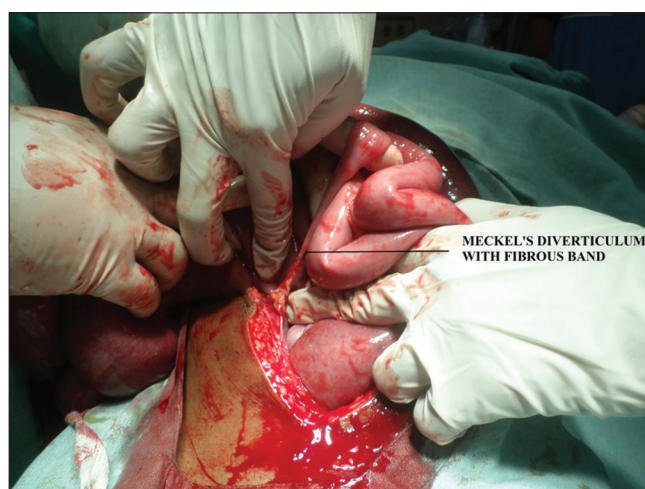

Figure 1: Meckels Diverticulum with Fibrous Band

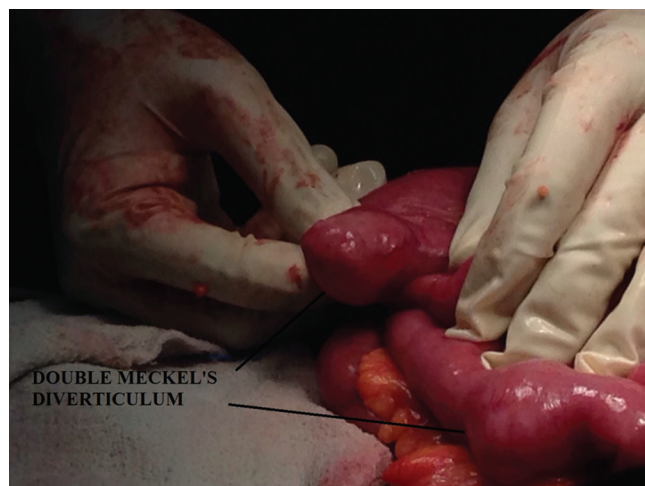

Figure 2: Double Meckels Diverticulum

abdomen and ultrasound abdomen. Patient was posted for laparotomy, intra-operatively there was a growth at recto sigmoid junction for which resection and end colostomy was done. Incidentally during exploration we noticed double Meckel's diverticulum (Figure 2) with wide mouth, which were left unresected.

#### Case 4

A 15-year-old male presented to emergency with complaints of pain abdomen for 1 day. On examination vitals were within normal limits per abdomen there was tenderness at McBurney's point with rebound tenderness. Diagnosis of acute appendicitis was made patient was posted for laparoscopic appendectomy; along with inflamed appendix incidentally we noticed Meckel's diverticulum with wide mouth. Appendectomy was done and Meckel's diverticulum left unresected.

#### Case 5

An 18-year-old female presented to emergency with complaints of pain abdomen for 1 day, vomiting for 1 day. On examination there was tenderness noted in McBurney's point with rebound tenderness. Diagnosis of acute appendicitis was made, planned for open appendectomy. Appendix was normal and on exploration of ileum we noticed Meckel's diverticulum with inflamed tip (Figure 3). Diverticulectomy was done. Post-operative period was uneventful.

#### Case 6

A 45-year-old female presented to emergency with complaints of pain abdomen and distension of abdomen for 2 days, distension of abdomen for 1 day, anuria for 12 h. Patient had history of fever 15 days prior to pain abdomen which subsided with medication. On examination patient had hypotension, there was distension of abdomen with guarding and rigidity with diffuse tenderness with absent bowel sounds. Clinical

diagnosis of hollow viscus perforation was made, diagnosis was confirmed by X-ray erect abdomen and ultrasound abdomen. After initial resuscitation, Patient was posted for laparotomy and intra-operatively we noticed perforated Meckel's diverticulum and also an ileal perforation 5 cm distal to diverticulum (Figure 4). Resection and anastomosis of ileum (including the diverticulum) was done. Post-operative period was uneventful. Histopathology of resected specimen did not show any evidence suggestive of tuberculosis or typhoid.

## DISCUSSION

Pre-operative diagnosis is rare in uncomplicated cases, and the diverticulum is usually observed incidentally, during other procedures for various reasons.<sup>10</sup> "Rule of two" is characteristic for Meckel's diverticulum, which includes the prevalence in 2% of the population; it is usually diagnosed under the age of two; it is in two-inches size and 2 cm diameter, two feet proximal to the ileocaecal valve, twice frequent in men, and symptomatic in 2% of the patients.<sup>10,11</sup>

Double Meckel's diverticulum is a rare condition, and the first study was reported by Emre *et al.* Although pre-operative diagnosis may be compelling, and the most frequent used modalities are a computerized tomography, technetium-99 m pertechnetate. Scintigraphy, and double-balloon enteroscopy, which is superior to the others,<sup>12</sup> scintigraphy has the capability of observing ectopic gastric mucosa but may have false positive and negative results at high rates.<sup>10</sup>

The management of symptomatic Meckel's diverticulum comprises surgical resection. A wedge resection of the Meckel's diverticulum is generally carried out, and occasionally some ileum is resected by end-to-end anastomosis diverticulectomy for Meckel's diverticulum found incidentally has been criticized. The results of surgical excision are generally excellent. Among the patients operated on for complications of Meckel's diverticulum, the cumulative incidence of early post-operative complications was 12%, including mainly wound infection (3%), prolonged ileus (3%), and anastomotic

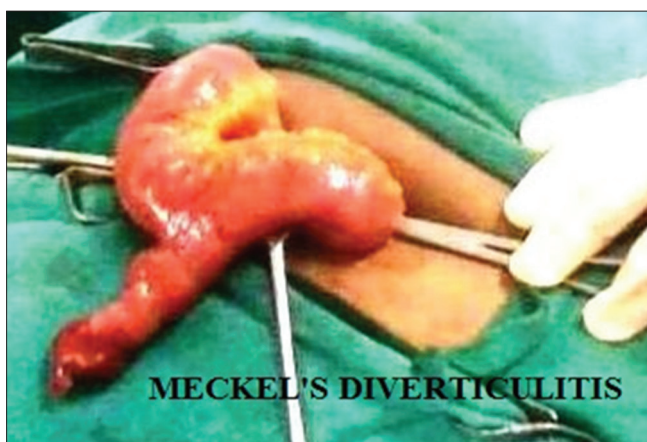

Figure 3: Meckels Diverticulitis

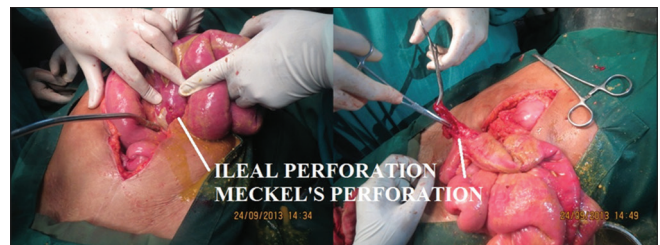


Figure 4: Ileal Perforation & Meckels perforation



leak (2%). The mortality rate was 1.5%. The cumulative incidence of late post-operative complications during a 20 years follow-up was 7%. Incidental diverticulectomies are safer, with an overall rate of morbidity of 2% and a mortality of 1%.<sup>13</sup> Due to the difficulty of diagnosing a pathologic Meckel's diverticulum pre-operatively, many surgeons recommend prophylactic diverticulectomy in those found incidentally[14]. This recommendation is based on lower morbidity rates when compared to the resection of pathologic diverticula.<sup>14</sup>

## CONCLUSION

The present study of six cases of Meckel's diverticulum with varied presentations highlights its importance in many aspects. It is difficult to make a pre-operative clinical diagnosis and most of the times it is an intra-operative diagnosis. In suspected appendicitis during surgery, exploration of small bowel should be done to rule out Meckel's diverticulum, especially when the appendix appears normal. One case revealed ileal and also Meckel's diverticulum perforation which is very uncommon to come across such a presentation.

The optimum management of an asymptomatic Meckel's diverticulum discovered at laparotomy for a separate indication remains unclear. A recent review shows the risk of post-operative complications are higher the following resection than leaving the diverticulum *in situ*.<sup>15</sup>

## REFERENCES

1. Jay GD 3<sup>rd</sup>, Margulis RR, McGraw AB, Northrip RR. Meckel's diverticulum; a survey of one hundred and three cases. Arch Surg 1950;61:158-69.
2. Kuwajerwala NK, Silva YJ. Meckels diverticulum. eMed J 2002;3:7.
3. Yahchouchy EK, Marano AF, Etienne JC, Fingerhut AL. Meckel's diverticulum. J Am Coll Surg. 2001;192:658-62.
4. Tavakkoli A, Ashley SW, Zinner MJ. Small intestine. In: Brunicaudi FC, editor. Schwartz's Principles of Surgery. 10<sup>th</sup> ed. McGraw Hill: Newyork; 2015. p. 1163-5.
5. Raymond P. Adjunctive procedure in intestinal surgery. Mastery of Surgery. 5<sup>th</sup> ed. Wolters Kulwer Health/Lippincott Williams & Wilkins :Philadelphia; 2007. p. 1392-3.
6. Peranteau WH, Smink DS. Appendix, Meckel's and other Small Bowel Diverticula: Maingot's Abdominal Operations. 12<sup>th</sup> ed. New York: McGraw Hill Professional; 2013. p. 643-4.
7. Horn F, Trnka J, Simicková M, Duchaj B, Makaiová I. Symptomatic Meckel's diverticulum in children. Rozhl Chir 2007;86:480-2.
8. Sagar J, Kumar V, Shah DK. Meckel's diverticulum: A systematic review. J R Soc Med 2006;99:501-5.
9. Chirdan LB, Yusufu LM, Ameh EA, Shehu SM. Meckel's diverticulitis due to *Taenia saginata*: Case report. East Afr Med J 2001;78:107-8.
10. Altaf A, Aref H. A case report: Cecal volvulus caused by Meckel's diverticulum. Int J Surg Case Rep 2014;5:1200-2.
11. Murruste M, Rajaste G, Kase K. Torsion of Meckel's diverticulum as a cause of small bowel obstruction: A case report. World J Gastrointest Surg 2014;6:204-7.
12. Papparella A, Nino F, Noviello C, Marte A, Parmeggiani P, Martino A, *et al.* Laparoscopic approach to Meckel's diverticulum. World J Gastroenterol 2014;20:8173-8.
13. Cartenese C, Petitti T, Marineli E, Pignatelli A, Maetingnetti D, Zuccarino M. Ferrozzi: Intestinal obstruction caused by torsed gangrenous Meckel's diverticulum encircling ileum. World J Gastrointest Surg 2001;27:106-9.
14. Seth A, Seth J. Axial torsion as a rare and unusual complication of a Meckel's diverticulum: A case report and review of the literature. J Med Case Rep 2011;5:118.
15. Zani A, Eaton S, Rees CM, Pierro A. Incidentally detected Meckel diverticulum: To resect or not to respect? Ann Surg 2008;247:276-81.

**How to cite this article:** Kumar KR, Rao BAR, Krishna DM, Raju KAK, Phaniteja P. Meckel's Diverticulum and its Presentations: A Case Series. Int J Sci Stud 2015;3(9):173-176.

**Source of Support:** Nil, **Conflict of Interest:** None declared.