Print ISSN: 2321-6379
Online ISSN: 2321-595X
DOI: 10.17354/ijss/2016/616

Original Article

Histopathology of Skin Adnexal Tumors - A Two Year Retrospective Study at a Tertiary Care Hospital

Muktanjalee Deka[1], Sukrita Bhattacharjee[2]

[1]Associate Professor, Department of Pathology, Gauhati Medical College and Hospital, Guwahati, Assam, India, [2]Postgraduate Trainee, Department of Pathology, Gauhati Medical College and Hospital, Guwahati, Assam, India

Abstract

Introduction: Skin adnexal neoplasms are rare neoplasms which differentiate toward or arise from the skin adnexa, *viz*., hair follicles, sweat glands or sebaceous glands. They present diagnostic difficulties because of their wide variations on histopathology. Benign adnexal neoplasms are more common than malignant lesions. Histopathology is the gold standard.

Aim: The aim of this study was analysis of skin adnexal tumors in our institution with respect to age, sex, location, histopathology, and incidence.

Materials and Methods: All cases of skin adnexal tumors for May 2014-June 2016 were retrieved from department registries and analyzed.

Results: A total of 23 cases were included. Majority of the tumors were benign (73.91%) and of hair follicle origin (34.78%). Incidence was found to be higher in females compared to males (male: female=1:3.53) with maximum cases in the age group 41-50 years (34.78%) and the head and neck region was the most common location (56.52%). Nodular hidradenoma was the most common benign tumor overall (4/17). Sebaceous carcinoma comprised the bulk of the malignant tumors (2/6). Others were eccrine spiradenocarcinoma, malignant proliferating pilar tumor, malignant proliferating trichilemmal tumor, and malignant nodular hidradenoma. Overall incidence of skin adnexal tumors was found to be 0.25%.

Conclusion: Skin adnexal tumors are relatively rare neoplasms. Benign tumors are more common than malignant lesions. Histopathology is essential to confirm the diagnosis.

Key words: Histopathology, Malignant eccrine spiradenoma, Skin adnexal tumors

INTRODUCTION

Skin adnexal tumors present a wide spectrum of morphology, which often defies precise classification making them one of the most challenging areas of pathology. They have been correctly termed by Cotton as "troublesome tumors" due to the difficulty in classifying them on clinical basis alone.[1] The histogenesis of mixed adnexal tumors is still uncertain and origin from pluripotent stem cells within epidermis is suggested.[2] They can occur as single-lineage neoplasms or may show overlapping morphological features of different lineages such as hair follicles, sebaceous glands, eccrine, and apocrine glands.[3,4] Diagnosis of these tumors is difficult because of their wide spectrum and variants, their rarity, differentiation along two or more adnexal lines and their complicated nomenclature. Most skin adnexal tumors are benign and cured by simple excision, however, their malignant counterparts are rare, locally aggressive with propensity for nodal and distant metastasis having poor clinical outcome. Diagnosis of these malignant tumors becomes doubly important with a view towards treatment and prognosis.[3] Histopathology is the gold standard of diagnosis with immunohistochemistry playing a limited role. Our study is a retrospective analysis of skin adnexal tumors with respect to their anatomical location, age and sex of the individuals affected, their

Access this article online

www.ijss-sn.com

Month of Submission : 10-2016
Month of Peer Review : 11-2016
Month of Acceptance : 11-2016
Month of Publishing : 12-2016

Corresponding Author: Dr. Sukrita Bhattacharjee, Department of Pathology, Gauhati Medical College and Hospital, Guwahati, Assam, India. E-mail: skrtbhttchry@gmail.com

histopathological features and to determine their incidence in our institution over a period of 2 years.

MATERIALS AND METHODS

The study was a hospital-based retrospective study conducted in the Department of Pathology, Gauhati Medical College and Hospital from May 2014 to June 2016. All cases of skin adnexal tumors diagnosed during this period were included. The clinical details were obtained from accompanying requisition forms and department registries. The slides and blocks were retrieved from the archives and analyzed. The slides were stained using routine Hematoxylin and eosin staining and confirmed with special stains where required.

RESULTS

A total of 23 skin adnexal tumors were diagnosed during the study period out of 9303 cases of surgical pathology reported. The incidence of skin adnexal tumors was found to be 0.25%. There were 6 males (26.08%) and 17 females (73.92%) with a male: female ratio of 1:3.53. Of the 23 cases documented, 17 were benign (73.92%) and 6 were malignant (26.08%). The age distribution is shown in Figure 1. The maximum cases were in the age group of 41-50 years (34.78%). With respect to anatomical location, the head and neck region was found to be the most common (78.26%) with predominance in the scalp (56.52%). The anatomical locations are shown in Table 1.

The tumors were further divided into hair follicle, sebaceous, eccrine, and apocrine gland differentiation. The most common tumors were of hair follicle origin - 10 (43.48%) (Table 2). The most common benign tumor was nodular hidradenoma (4/17) followed by pilomatrixoma and trichilemmal cyst (3/17 each). The frequency and percentage of the different skin adnexal tumors, benign and malignant are shown in Tables 3 and 4. Malignant adnexal tumors were rare with only 6 cases in our study out of which 2 were sebaceous carcinoma making it the most common type and one case each of eccrine spiradenocarcinoma, malignant nodular hidradenoma, malignant proliferating pilar tumor, and malignant trichilemmal tumor.

DISCUSSION

Adnexal tumors of the skin are rare neoplasms which show differentiation toward pilar, sebaceous, eccrine or apocrine structures. They are believed to originate from pluripotent stem cells in epidermal niches and a single tumor can show more than one line of differentiation.[2]

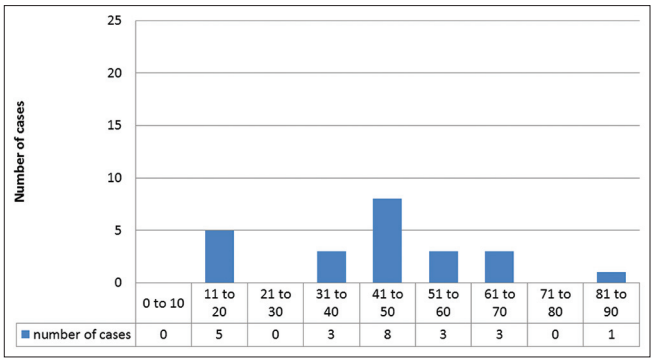

Figure 1: Distribution of cases based on age

Table 1: Distribution of cases based on anatomical locations

Anatomical location	Number of cases (%)
1. Head and neck	18 (78.26)
Scalp	13 (56.52)
Forehead	1 (4.35)
Eyelid	2 (8.70)
Cheek	1 (4.35)
Chin	1 (4.35)
2. Trunk	1 (4.35)
3. Lower limb	2 (8.69)
4. Upper limb	1 (4.35)
5. Perianal region	1 (4.35)
Total	23 (100)

Table 2: Distribution of tumors based on differentiation

Differentiation of appendageal tumors	Total number (%)
Hair follicle	10 (43.48)
Sebaceous gland	4 (17.39)
Eccrine gland	7 (30.44)
Apocrine gland	2 (8.69
Total	23 (100)

Table 3: Benign skin adnexal tumors with frequency

Appendageal tumors	Benign tumor types	Number of cases (%)
Hair follicle	Pilomatrixoma	3 (17.65)
	Trichilemmal cyst	3 (17.65)
	Trichofolliculoma	2 (11.76)
Sebaceous	Naevus sebaceous	2 (11.76)
Eccrine	Nodular hidradenoma	4 (23.51)
	Chondroid syringoma	1 (5.89)
Apocrine	Apocrine hidrocystoma	1 (5.89)
	Hidradenoma papilliferum	1 (5.89)
Total		17 (100)

Skin adnexal tumors have a wide range of age distribution. Sharma *et al.*[5] found the maximum cases in the age group of 51-60 years whereas Radhika *et al.*[6] reported the third decade to be the most common. In our study, the maximum

cases were in the age group of 41-50 years (34.78%) which coincides with the findings of Vani *et al.*[7] (21.56%).

Male:female ratio was reported to be 1.07:1 by Sharma *et al.*[5] In our study, the male: female ratio was found to be 1:3.53 which was in concordance with Vani *et al.*, Nair and Saha *et al.* who reported a male: female ratio of 1:1.68, 1:2.3, and 1: 1.88, respectively.[7-9]

Sharma *et al.*, Radhika *et al.*, and Vani *et al.* observed that head and neck region was the most common site of occurrence, which was also noted in our study (78.26%).[5-7]

The incidence of skin adnexal tumors in our study was found to be 0.25%. This is similar to observations by Samaila (0.9%)[10] and Jindal and Patel (0.37%).[11]

The incidence of benign adnexal tumors is more compared to malignant tumors. We found 73.92% benign and 26.08% malignant cases in our study. This coincided with the findings of Sharma *et al.*, Radhika *et al.*, Vani *et al.*, and Samaila who reported 77.14%, 80.36%, 74.50%, and 88.5% benign and 29.63%, 19.64%, 25.49%, and 11.5% malignant lesions, respectively.[5-7,10]

In our study, tumors of hair follicular origin were the most common (43.48%) of which pilomatrixoma and trichilemmal cyst were maximum in number (3 cases each). This coincides with the findings of Kant *et al.*[12] and Jayalakshmi and Looi[13] who found hair follicular tumors to be 64.29% and 63.4% of skin adnexal tumors but is in contrast to the findings of Sharma *et al.*, Vani *et al.*, and Nair who found tumors of sweat gland origin to be the most common.[5,7,8]

The most common benign tumor overall was nodular hidradenoma (4/17 cases) which is similar to the observations of Sharma *et al.*, Radhika *et al.*, and Vani *et al.*[5-7]

Pilomatrixoma was the second most common benign tumor (3 cases) with microscopy showing biphasic pattern of keratinized ghost cells and basaloid cells. One of the cases showed giant cell reaction and calcium deposition (Figure 2).

We found 2 cases of trichofolliculoma, one in the chin and other in the cheek. Both revealed microscopic features of dilated hair follicle arising from surface epithelium with numerous secondary hair follicles arising from it. Numerous sebaceous gland cells were found embedded in the walls of the secondary hair follicles (Figure 3).

Chondroid syringoma or mixed tumor of the skin is a rare cutaneous adnexal neoplasm mostly reported as isolated case reports.[14] It may be either apocrine or eccrine in nature. On microscopy, we found small nests, cords, and monolayered tubules of epithelial cells in a chondromyxoid stroma in the dermis which was used to classify it as eccrine neoplasm (Figure 4).

Malignant adnexal tumors are rare.[2-4] We found 6 malignant adnexal tumors in our study, of which sebaceous carcinoma

Table 4: Malignant skin adnexal tumors with frequency

Appendageal tumors	Malignant tumor types	Number of cases (%)
Hair follicle	Malignant proliferating trichilemmal cyst	1 (16.67)
	Malignant proliferating pilar tumor	1 (16.67)
Sebaceous	Sebaceous carcinoma	2 (33.33)
Eccrine	Eccrine spiradenocarcinoma	1 (16.67)
	Malignant eccrine hidradenoma	1 (16.67)
Apocrine	-	0 (0)
Total		6 (100)

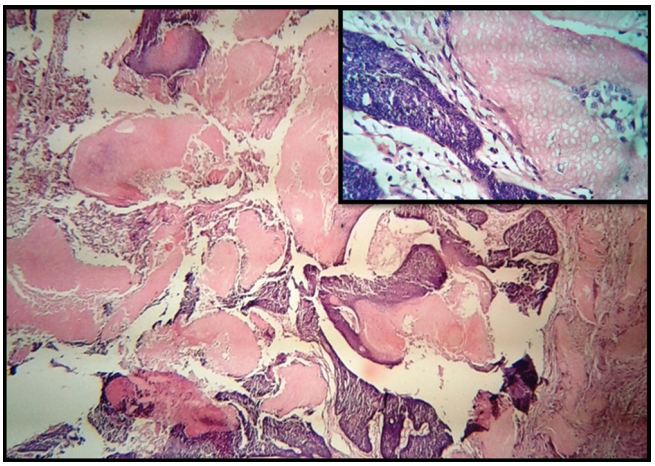

Figure 2: Pilomatrixoma showing basaloid and ghost cells (H & E, ×10). Inset (H & E, ×40)

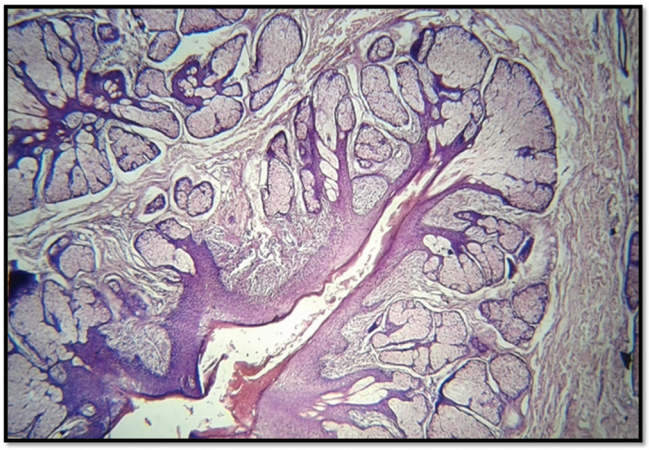

Figure 3: Trichofolliculoma showing dilated hair follicle with numerous secondary follicles (H & E, ×10)

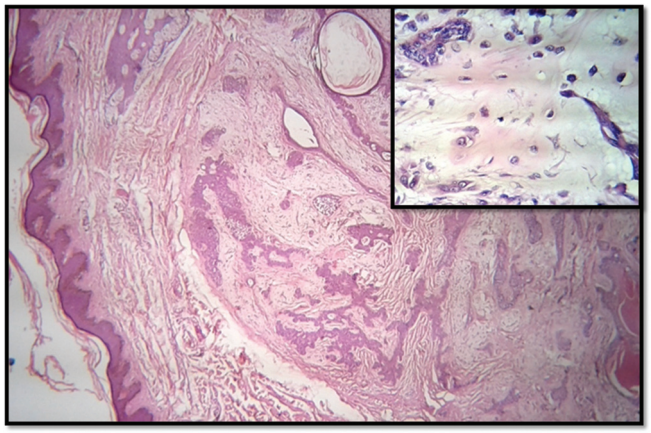

Figure 4: Chondroid syringoma with epithelial cords and nest in dermis (H & E, ×10). Inset (H & E, ×40) showing chondromyxoid stroma

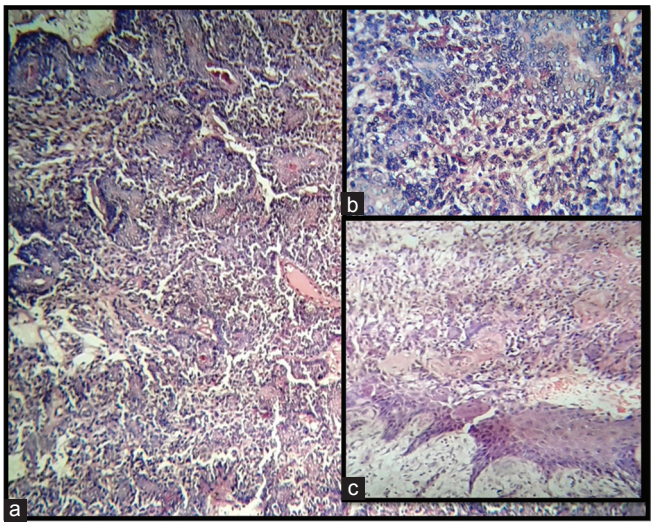

Figure 5: Eccrine spiradenocarcinoma. (a) Benign spiradenoma with dual population of cells (H & E, ×10). (b) Areas of malignant transformation (H & E, ×40). (c) Area of squamous differentiation (H & E, ×10)

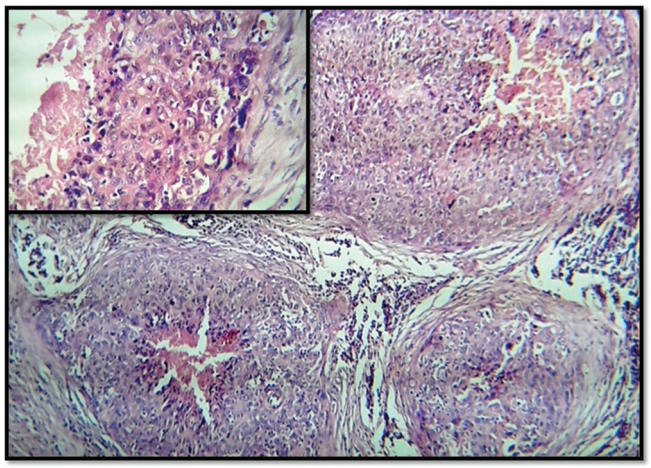

Figure 6: Malignant proliferating pilar tumor showing squamous lobules with abrupt keratinization (H & E, ×10). Inset (H & E, ×40) abnormal mitotic figures

was found to be the most common. Sebaceous carcinoma has been divided into ocular and extraocular varieties.[15] The 2 cases we reported were both of the ocular variety, found as upper eyelid masses. One case was in a 86-year-old female and the other in a 68-year-old female.

Eccrine spiradenocarcinoma is a very rare tumor with few cases reported worldwide.[16,17] It usually arises from a benign spiradenoma. We reported a case of eccrine spiradenocarcinoma in a 45-year-old female who presented with ulceration and bleeding in a long-standing back swelling. On microscopy, we found benign spiradenoma component with well-defined nodules composed of small dark cells in periphery and large pale cells in the center along with areas of malignant change showing loss of dual cell population, hyperchromatic nuclei, pleomorphism, prominent nucleoli, and mitosis. There were also areas of malignant squamous and spindle cell differentiation (Figure 5).

Malignant proliferating pilar tumor is a rare tumor of hair follicle origin with 39 cases reported in English literature.[18] We diagnosed a case of malignant proliferating pilar tumor in a 45-year-old female presenting with a scalp lesion clinically diagnosed as a granuloma. On microscopy, we found lobules of squamous epithelium with abrupt pilar keratinization and foci of calcification. There was marked cytological atypia and stromal invasion with the presence of numerous abnormal mitotic figures (Figure 6).

CONCLUSION

Skin adnexal tumors are rare neoplasms which are difficult to diagnose clinically. There is a dearth of literature concerning skin adnexal tumors. The incidence in our study is 0.25% which highlights the rarity of these tumors. The incidence of benign tumors is more compared to malignant ones. Skin adnexal tumors can occur anywhere in the body but head and neck region is found to be the most common location. The most common are benign tumors of hair follicle origin and sebaceous carcinoma is the most common of the malignant cases. Histopathology is the gold standard for diagnosis of these tumors.

REFERENCES

1. Cotton D. Troublesome tumours 1: Adnexal tumours of the skin. J Clin Pathol 1991;44:543-8.
2. Stewart CA, Novoa RA, Seykora JT. Tumors of epidermal appendages. In: Elder DE, Elenitsas R, Johnson BL, Murphy GF, editors. Lever's Histopathology of the Skin. 11th ed. Philadelphia, PA, USA: Lippincott Williams & Wilkins; 2014. p. 1718-841.
3. Alsaad KO, Obaidat NA, Ghazarian D. Skin adnexal neoplasms – Part 1: An approach to tumours of the pilosebaceous unit. J Clin Pathol 2007;60:129-44.

4. Obaidat NA, Alsaad KO, Ghazarian D. Skin adnexal neoplasms – Part 2: An approach to tumours of cutaneous sweat glands. J Clin Pathol 2007;60:145-59.
5. Sharma A, Paricharak DG, Nigam JS, Rewri S, Soni PB, Omhare A, *et al*. Histopathological study of skin adnexal tumours - Institutional study in South India. J Skin Cancer 2014;2014:4.
6. Radhika K, Phaneendra BV, Rukmangadha N, Reddy MK. A study of biopsy confirmed skin adnexal tumours: Experience at a tertiary care teaching hospital. J Clin Sci Res 2013;2:132-8.
7. Vani D, Ashwini NS, Sandhya M, Dayananada TR, Bharathi M. A 5 year histopathological study of skin adnexal tumors at a tertiary care hospital. IOSR J Dent Med Sci 2015;14(4):1-5.
8. Nair PS. A clinicopathologic study of skin appendageal tumors. Indian J Dermatol Venereol Leprol 2008;74:550.
9. Saha A, Das NK, Gharami RC, Chowdhury SN, Datta PK. A clinico-histopathological study of appendageal skin tumors affecting head and neck region in patients attending the dermatology OPD of a tertiary care centre in Eastern India. Indian J Dermatol 2011;56:33-6.
10. Samaila MO. Adnexal skin tumors in Zaria, Nigeria. Ann Afr Med 2008;7:6-10.
11. Jindal U, Patel R. Study of adnexal tumors of skin: A three year study of 25 cases. Internet J Pathol 2012;13:3.
12. Kanth GK, Vijayasree V, Madhavi M, Rao TS, Narayana VS. A histopathological spectrum of skin adnexal tumors. IOSR J Dent Med Sci 2015;14:90-2.
13. Jayalakshmi P, Looi LM. Cutaneous adnexal neoplasms in biopsy specimens processed in the Department of Pathology, University of Malaya. Ann Acad Med Singapore 1996;25:522-5.
14. Kazakov DV, Kacerovska D, Hantschke M, Zelger B, Kutzner H, Requena L, *et al*. Cutaneous mixed tumor, eccrine variant: A clinicopathologic and immunohistochemical study of 50 cases, with emphasis on unusual histopathologic features. Am J Dermatopathol 2011;33:557-68.
15. Crowson AN, Magro CM, Mihm MC. Malignant adnexal neoplasms. Mod Pathol 2006;19 Suppl 2:S93-126.
16. Ishikawa M, Nakanishi Y, Yamazaki N, Yamamoto A. Malignant eccrine spiradenoma: A case report and review of the literature. Dermatol Surg 2001;27:67-70.
17. Granter SR, Seeger K, Calonje E, Busam K, McKee PH. Malignant eccrine spiradenoma (spiradenocarcinoma): A clinicopathologic study of 12 cases. Am J Dermatopathol 2000;22:97-103.
18. Garg PK, Dangi A, Khurana N, Hadke NS. Malignant proliferating trichilemmal cyst: A case report with review of literature. Malays J Pathol 2009;31:71-6.

How to cite this article: Deka M, Bhattacharjee S. Histopathology of Skin Adnexal Tumors - A Two Year Retrospective Study at a Tertiary Care Hospital. Int J Sci Stud 2016;4(9):61-65.

Source of Support: Nil, **Conflict of Interest:** None declared.