

Fallopian Tube Prolapse: An Unusual Complication of Surgical Drainage Site

Muthuramu Poovathi, Ethirajan Kalarani

Department of Obstetrics and Gynaecology, Thanjavur Medical College, Thanjavur, Tamil Nadu, India

Abstract

The fallopian tube prolapse after hysterectomy is a rare occurrence. Cases of prolapse of the fallopian tube into the vaginal vault after vaginal hysterectomy have been reported. The prolapse of the fallopian tube via the surgical drainage site is a very rare occurrence. Surgical drains have been used in clinical practice for a long time, but their use is not without complication. A 40-year-old multigravida was admitted with grade 3 abruptio placenta. Lower segment caesarean section was done and subsequently proceeded with subtotal hysterectomy in view of the atonic uterus not responding to conservative medical and surgical measures. The drainage tube was removed on the 3rd post-operative day and prolapsed reddish fallopian tube was noticed at the drain site. By presenting this case report, we aim to reduce such complications in future. Drains are used to drain body fluids in certain circumstances but do not prevent infection or promote wound healing. Drainage tubes are not a substitute to a good surgical technique.

Key words: Fallopian tube prolapse, herniation, drainage site

INTRODUCTION

Drains inserted after surgery to drain accumulated fluid content sometimes become the focus of infection, such as blood and pus. They do not promote wound healing or prevent infection. In current clinical practice, their use is restricted by good surgical techniques and confidence of surgeons, but their use is unavoidable in certain clinical situations. The surgical drain use is associated with complications such as hemorrhage, infection, tissue damage, pain, blockage and herniation of viscera.¹

CASE REPORT

A 40-year-old G₆P₅L₅ referred from a Taluk headquarter hospital to government medical college hospital as a

case of 8 months amenorrhea with abruptio placenta and intrauterine fetal death. Under general anesthesia, emergency Lower segment Caesarean section was proceeded and a fresh, dead female baby was delivered. Active management of the third stage of labor followed, uterus was found to be atonic. All uterotonics were given. Conservative surgical measures were also followed. In spite of these measures uterus was flabby and hence subtotal hysterectomy was done. Both fallopian tubes were unduly long - 15 cm. In view of prolonged surgery (2 h and 30 min), a drain was inserted through a separate incision in right iliac fossa and placed intraperitoneally in the pouch of Douglas. Abdomen was closed after securing perfect hemostasis. 6 units of fresh frozen plasma and 4 units of whole blood were transfused intraoperatively. On the 3rd post-operative day, drainage tube removed. At the drain tube site, there was a prolapse of a reddish tissue, which was suspected to be omental prolapse (Figure 1). Surgeon's opinion was suspected small bowel prolapse and laparotomy was advised. Laparotomy proceeded via the previous suprapubic transverse incision. The prolapsed tissue via the drainage tube site was reduced and traced and was found to be the fimbrial portion of the oedematous right fallopian tube (Figure 2). Since the tube was congested and oedematous,

Access this article online



www.ijss-sn.com

Month of Submission : 12-2015
Month of Peer Review : 01-2016
Month of Acceptance : 01-2016
Month of Publishing : 02-2016

Corresponding Author: Dr. Muthuramu Poovathi, Department of Obstetrics and Gynaecology, Thanjavur Medical College, Thanjavur, Tamil Nadu, India. Phone: +91-9047486668. E-mail: drmpoovathi@gmail.com

right salpingectomy was done. Left tube was found to be normal and healthy. Omentum, small bowel, and large bowel were inspected and found to be intact and normal. Post-operative period was uneventful. The patient was discharged in good condition. The excised right fallopian tube was sent for histopathological examination and was reported as the fallopian tube with submucosal edema, congestion, and features of acute inflammation (Figure 3).

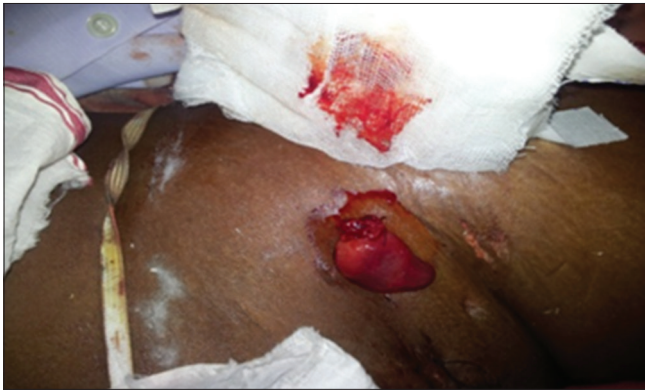

Figure 1: Right fallopian tube prolapsed, congested and oedematous like a small bowel

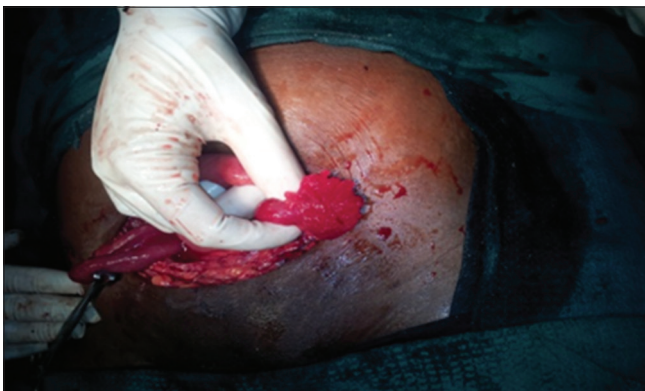

Figure 2: Fimbrial portion of congested and inflamed right fallopian tube (intra-operative)

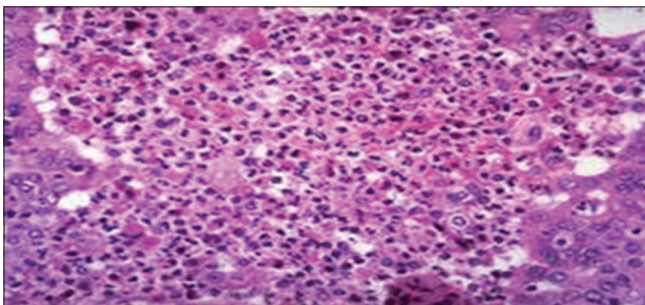


Figure 3: Histopathological examination with inflammatory changes

DISCUSSION

Drains are not used routinely, and their use is restricted in unavoidable circumstances only. Depending on the amount of collection patient may have the drain in place for 1 day to weeks. Patency of tube must be assessed and maintained frequently. Cavities and sacs in the body are potential fluid collection areas. Drains used following abdominal surgeries are closed one, consists of tube draining into a bottle or a bag. Complications due to drains in the post-operative period are mainly due to poor drain selection, poor drain placement, and inadequate post-operative management. Indications for surgical drains may be therapeutic (to evacuate existing collection of fluid) or prophylactic (to prevent the collection of fluid). In literature, there are reports of herniation of intestine,² appendix³ and omentum⁴ through the surgical drainage site but fewer cases of the fallopian tube prolapse have been reported. The incidence of prolapsed tube via port following laparoscopic surgeries is 65-2.5%.⁵ We have used prophylactic drain in our patient, a no. 32 closed penrose drain with openings, kept in pouch of Douglas. Large studies revealed that prophylactic drains should be minimized in uncomplicated surgeries.⁶ It has been reported that herniation of viscera increases with increase in port size more than 10 mm. Factors which increase intra-abdominal pressure such as coughing, straining, prolonged surgery poor nutrition, infection, obesity, and steroid use may cause poor wound healing and herniation.⁷ In our patient, prolonged surgery may be the cause for the prolapse of the fallopian tube. In our case, the length of the fallopian tube was long - 15 cm as against the usual 10 cm. The wrong technique of insertion and removal is another causative factor.

CONCLUSION

Drains are not a substitute for good surgical techniques. Although a large number of cases of herniation of omentum and intestine have been reported, herniation of fallopian tube is uncommon. Prevention of tubal prolapse can be achieved by suturing the adnexae high in the pelvis at abdominal hysterectomy and by the proper closure of the pelvic peritoneum. In this particular case, the unduly long fallopian tube and prolonged surgery could have been the causes for herniation.

REFERENCES

1. Mosley JG, Jantet G. Herniation at the site of an abdominal drain. *Br J Clin Pract* 1978;32:56, 58.

Poovathi and Kalarani: Fallopian Tube Prolapse

2. Kulkarni S, Krijgsman B, Sharma D, Kaisary AV. Incarcerated small bowel hernia through drain site. *Ann R Coll Surg Engl* 2004;86:W24-5.
3. O'Riordan DC, Horgan LF, Davidson BR. Drain-site herniation of the appendix. *Br J Surg* 1995;82:1628.
4. Howard FM, Sweeney TR. Omental herniation after operative laparoscopy. A case report. *J Reprod Med* 1994;39:415-6.
5. Tonouchi H, Ohmori Y, Kobayashi M, Kusunoki M. Trocar site hernia. *Arch Surg* 2004;139:1248-56.
6. Gurusamy KS, Samraj K, Mullerat P, Davidson BR. Routine abdominal drainage for uncomplicated laparoscopic cholecystectomy. *Cochrane Database Syst Rev* 2007:CD006004.
7. Loh A, Jones PA. Evisceration and other complications of abdominal drains. *Postgrad Med J* 1991;67:687-8.

How to cite this article: Poovathi M, Kalarani E. Fallopian Tube Prolapse: An Unusual Complication of Surgical Drainage Site. *Int J Sci Stud* 2016;3(11):287-289.

Source of Support: Nil, **Conflict of Interest:** None declared.