

# Comparison of Z-Plasty and Limberg Flap Techniques in Management of Sacrococcygeal Pilonidal Sinus

B D Manjunath<sup>1</sup>, A Prem Kumar<sup>1</sup>, N Nischal<sup>2</sup>, Ramya Ramachandra<sup>3</sup>

<sup>1</sup>Assistant Professor, Department of General Surgery, Bangalore Medical College and Research Institute, Bengaluru, Karnataka, India,

<sup>2</sup>Post-graduate Student, Department of General Surgery, Bangalore Medical College and Research Institute, Bengaluru, Karnataka, India,

<sup>3</sup>Under-graduate Student, Department of General Surgery, Bangalore Medical College and Research Institute, Bengaluru, Karnataka, India

## Abstract

**Introduction:** Pilonidal sinus is a fairly common problem encountered in general surgical practice. Though there are many surgical techniques for its management, controversy still continues regarding best surgical technique to treat with respect to postoperative complications, patient compliance, and minimizing recurrence.

**Aims and Objectives:** The aim of this study was to compare the two techniques of Limberg flap method and Z-plasty in the management of pilonidal sinus in terms of duration of surgery, postoperative pain, duration of hospital stay, drain removal time, postoperative complications, and recurrence rate.

**Materials and Methods:** A prospective comparative study was conducted in the Department of General Surgery, Victoria Hospital. A total of 50 cases were included, of which 31 underwent Limberg flap procedure and 19 underwent Z-plasty.

**Results:** The mean age of sacrococcygeal pilonidal sinus presentation was 29 years with male preponderance presenting with pain and seropurulent discharge as most common complaints. The parameters regarding the duration of surgery, the mean duration of hospital stay, postoperative complications were comparable between 2 groups. Postoperative pain was significantly less in Limberg method. The drain could be removed earlier in the Limberg flap procedure than in the Z-plasty technique, the difference being statistically significant.

**Conclusion:** In this study, Limberg flap methods had a shorter duration of operation, lesser postoperative pain, and earlier drain removal time when compared to Z-plasty. Hence, Limberg flap may be a better alternative to Z-plasty in the management of sacrococcygeal pilonidal sinus.

**Key words:** Limberg flap, Pilonidal sinus, Prospective comparative study, Z-plasty

## INTRODUCTION

The term pilonidal is derived from the Latin word pilus meaning hair and nidus meaning nest. It is a characteristic epithelial tract (the sinus) located in the natal cleft, generally containing hair.<sup>1</sup> It is a common disorder affecting young adults, in the age group 15-30 years. Sex hormones affecting pilosebaceous glands and body hair growth have been

implicated for this age prevalence. The incidence of the disease varies from 10 to 26 per 100,000 population.<sup>2,3</sup>

Karyadaki's theory is the most popular theory accepted to explain the pathogenesis of the disease. He proposed that pilonidal sinus results from the interplay of three main factors resulting in the insertion of hair into the natal cleft which are: The presence of loose hairs (the invader), some force facilitating hair insertion into the skin, and the vulnerability of the skin, such as intergluteal sulcus depth.<sup>4</sup> A deep natal cleft favors sweating, hair penetration, and bacterial contamination. Buttock movements while walking further cause hair to penetrate the skin, thus, initiating a foreign body reaction and inflammation. This gradually leads to pilonidal abscess and/or sinus formation.<sup>5,6</sup>

Access this article online



www.ijss-sn.com

**Month of Submission :** 12-2015  
**Month of Peer Review :** 01-2016  
**Month of Acceptance :** 01-2016  
**Month of Publishing :** 02-2016

**Corresponding Author:** Dr. N Nischal, Room No 508, BMC & RI PG Men's Hostel, Near Bowring and Lady Curzon Hospital, Shivajinagar, Bengaluru - 560 001, Karnataka, India. Phone: +91-7259762362. E-mail: dnrnischal89@gmail.com

Controversy exists regarding the ideal treatment. All the surgical methods described include complete excision of the sinus but differ in the management of the wound after excision.<sup>7</sup> Excision and packing, excision and primary closure, marsupialization, and flap techniques are some of the surgical procedures that have been developed for the treatment of pilonidal sinus.<sup>8</sup> An ideal operation is one that is cost effective, ensures speedy return to work, is simple to perform, not requiring a prolonged hospital stay, inflicts minimal pain, and has a low disease recurrence rate.<sup>9,10</sup>

## MATERIALS AND METHODS

This is a prospective comparative study which was conducted in the Surgery Department of Victoria Hospital. A total of 50 cases were included in this study. Patients were divided into two groups randomly. Group A included 31 patients who underwent Limberg flap procedure. Group B included 19 patients who underwent the Z-plasty procedure. Informed consent was obtained from all the patients. Statistical analysis was done using the Chi-square test.  $P < 0.05$  was considered significant.

### Inclusion Criteria

1. Pilonidal sinus in the natal cleft of the sacrococcygeal area
2. Patients aged between 16 and 60 years.

### Exclusion Criteria

1. Pilonidal abscess
2. Patients having systemic conditions which affect postoperative wound healing like diabetes mellitus, Human immunodeficiency virus positive patients, on cancer chemotherapeutic drugs, immunosuppressant therapy
3. Recurrent pilonidal sinus.

### Methods

All patients in both treatment groups were given subarachnoid blockade and placed in the prone position with buttocks taped apart.

A rhomboid was marked around the lesion with a marking pen, and one of the angles was extended and dropped as with a conventional Limberg's flap. The lesion and all the sinus tracts were excised in entirety in all cases. The fasciocutaneous flap was raised and rotated. Skin closure was achieved after hemostasis with ethilon 3-0 sutures. For the Z-plasty, a vertical ellipse was initially marked with a marking pen with the sinus tract as its center and thus forming the vertical limb of the Z-plasty. Two horizontal limbs were then drawn depending on the length of the vertical limb. The lesion with all the sinus tracts was excised

into and after raising flaps, the Z-plasty was completed to cover the defect. The skin was closed using ethilon 3-0 sutures.

In both methods, suction drain was placed and removed when drain output was  $<10$  cc over 24 h.

Two methods were compared with respect to the duration of surgery, postoperative pain and complications, average time of drain removal, mean duration of hospital stay and recurrence.

## RESULTS

A total of 50 patients, of mean age 29 (range: 19-41) were included in the study, of which 6 (12%) were females, and 42 (88%) were males. The most common clinical presentations were pain (86%), seropurulent discharge (78%), and swelling (16%).

Of the 50, 31 (62%) patients underwent Limberg flap procedure while the rest nineteen (38%) underwent Z-plasty. The former operation lasted for 45 min on an average (range: 40-50 min) while the latter for 52 min on average (range: 35-60 min). The difference between the two was not statistically significant ( $P = 0.783$ ) (Figure 1).

The patients of each group were asked to rate their pain on a visual analog scale on postoperative day 1, 2, and 3. Average of 3 values was taken into consideration. Among the former group, the average pain score was 3.65 (range: 3-5) and among the latter, 4.05 (range: 3-5). The difference between the two were statistically significant ( $P = 0.049$ ) (Figure 2).

The mean duration of hospital stay was 4 days for both the procedures, the range being 3-5 days for the former group and 3-7 days for the latter group, the difference not being statistically significant ( $P = 0.064$ ). The drain was

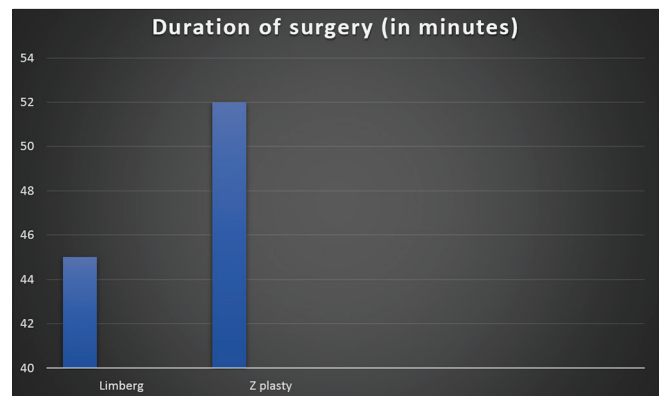


Figure 1: Graph comparing duration of surgery between Limberg and Z-plasty in minutes

removed after an average of 3 days in the former group (range: 2-4 days) and 4 days (range: 2-5 days) in the latter. The difference between the two procedures was found to be statistically significant ( $P = 0.042$ ) (Figure 3). The sutures were removed after an average of 10 days.

Wound infection was noted in 2 patients (6.25%) of those who underwent Limberg procedure and in 2 patients (11.11%) of those who underwent Z-plasty. One incident of flap necrosis was noted in a patient

who underwent Limberg procedure (3.13%). Seroma formation was noted in 4 patients in the former group (12.5%) and in 3 patients in the latter group (16.67%). A single incidence of wound dehiscence was noted in the latter group (5.55%). No significant difference was noted in both groups with regard to complications ( $P = 0.69$  for wound dehiscence,  $P = 0.526$  for flap necrosis,  $P = 0.398$  for seroma formation). Table 1 showing comparison between Limberg method and Z-plasty with respect to various parameters.

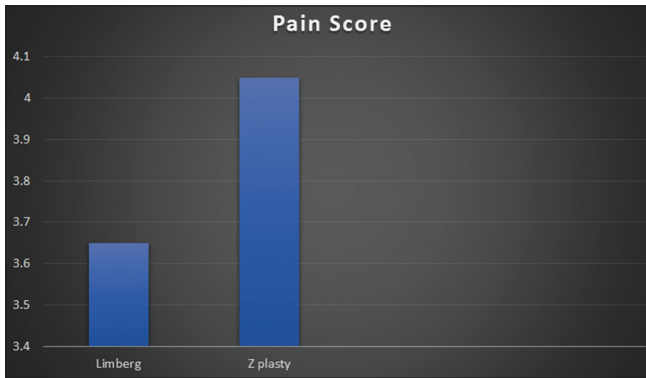


Figure 2: Graph depicting postoperative pain score

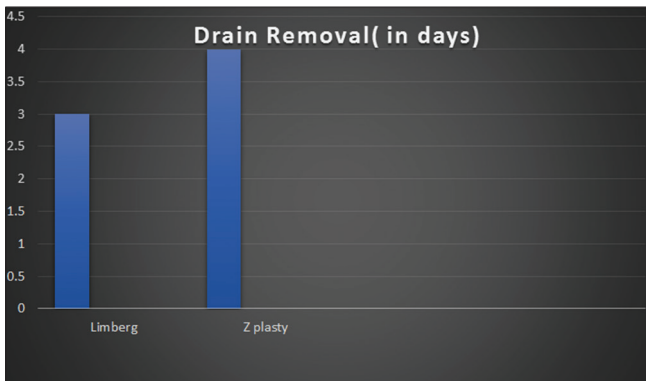


Figure 3: Graph comparing drain removal time between two methods

Table 1: Comparing different parameters between Limberg and Z-plasty

Parameter	Limberg method (n=31)	Z-plasty (n=19)	P value
Duration of operation	45 min	52 min	0.783
Postoperative pain score	3.65	4.05	0.049
Mean duration of hospital stay	4 days (range: 3-5 days)	4 days (range: 3-7 days)	0.064
Drain removal	3 days (range: 2-4 days)	4 days (range: 2-5 days)	0.042
Postoperative complications			
Wound infection	2	2	0.69
Flap necrosis	1	0	0.526
Seroma	4	3	0.398

## DISCUSSION

Many surgical treatment methods have been described in literature but the controversy remains regarding the ideal treatment method, which has not yet been established for pilonidal disease. Complete excision of the sinus is widely practiced, but controversy remains about what to do with the wound after excision. Limberg flap method and Z-plasty are the two common methods followed in surgical practice. This study was conducted to compare the two methods in various aspects so as to arrive at the conclusion which method is better.

In this study, most of the patients were male in their 3rd decade of life. Most of the patients presented with pain and seropurulent discharge as common complaints. In a study conducted by Khan, most patients were also in the 3rd decade with male preponderance which is comparable with our study.<sup>11</sup>

In the present study, duration of surgery was comparatively short for Limberg method. The mean postoperative pain score on day 1, 2, and 3 was significantly less in Limberg flap method when compared to Z-plasty. The drain was removed earlier in patients who underwent Limberg procedure, and it was statistically significant when compared to Z-plasty.

Duration of hospital stay was decided when the patient could walk freely without any significant pain and mean average duration of hospital stay was 4 days for both groups. In a study conducted by Akin *et al.*,<sup>12</sup> mean duration of stay was 3.2 days for Limberg method which is comparable with our study.

Main complications in the present study were wound infection, seroma, flap necrosis, and wound dehiscence. Moreover, recurrence was defined as persistent purulent or bloody discharge from in and around operated site. Wound infection was managed conservatively with antibiotics and regular wound dressings, seroma by aspiration, and antibiotics. Wound dehiscence was managed by antibiotics, regular debridement and delayed primary suturing.

According to study conducted by Priyadarshini *et al.*,<sup>13</sup> on Z-plasty postoperative complications were present in 36% and recurrence in 5% of subjects. In the present study, 14% patients had postoperative complications and zero recurrence. In a study conducted by Akin *et al.*, on Limberg flap postoperative complications were present in 16% and recurrence in 3% of patients. In the present study, it was 12% and 0%, respectively. There was no statistical difference with respect to postoperative complications and recurrence between Limberg and Z-plasty in our study.

## CONCLUSION

Postoperative pain was significantly more in the patients who underwent Z-plasty than in the patients who underwent Limberg flap procedure. The drain could be removed earlier in the Limberg flap procedure than in the Z-plasty technique, the difference being statistically significant. The duration of operation was insignificantly more in the Z-plasty procedure than in the Limberg flap procedure. No significant difference was noted in both groups with regard to postoperative complications and mean duration of hospital stay. Thus, Limberg flap may be a better alternative to Z-plasty in the management of pilonidal sinus as it has a shorter duration of operation, lesser postoperative pain, and earlier drain removal time.

## REFERENCES

1. Hodges RM. Pilonidal sinus. *Bosten Med Surg J* 1880;103:456-586.
2. Søndena K, Andersen E, Nesvik I, Søreide JA. Patient characteristics and symptoms in chronic pilonidal sinus disease. *Int J Colorectal Dis* 1995;10:39-42.
3. McCallum IJ, King PM, Bruce J. Healing by primary closure versus open healing after surgery for pilonidal sinus: Systematic review and meta-analysis. *BMJ* 2008;336:868-71.
4. Karydakis GE. Easy and successful treatment of pilonidal sinus after explanation of its causative process. *Aust N Z J Surg* 1992;62:385-9.
5. Notaras MJ. A review of three popular methods of treatment of postanal (pilonidal) sinus disease. *Br J Surg* 1970;57:886-90.
6. Eryilmaz R, Sahin M, Alimoglu O, Dasiran F. Surgical treatment of sacrococcygeal pilonidal sinus with the Limberg transposition flap. *Surgery* 2003;134:745-9.
7. Corman ML. *Colon and Rectal Surgery*. 2<sup>nd</sup> ed. Philadelphia, PA: Lippincott; 1989. p. 297-304.
8. Armstrong JH, Barcia PJ. Pilonidal sinus disease. The conservative approach. *Arch Surg* 1994;129:914-7.
9. Koorista HP. Pilonidal sinuses. Review of literature and report of three hundred and fifty cases. *Am J Surg* 1942;55:3-17.
10. Akinci OF, Coskun A, Uzunköy A. Simple and effective surgical treatment of pilonidal sinus: Asymmetric excision and primary closure using suction drain and subcuticular skin closure. *Dis Colon Rectum* 2000;43:701-6.
11. Khan A. Prognostic factors of pilonidal sinus. *J Med Sci* 2006;14:40-3
12. Akin M, Gokbayir H, Kilic K, Topgul K, Ozdemir E, Ferahkose Z. Rhomboid excision and Limberg flap for managing pilonidal sinus: Long-term results in 411 patients. *Colorectal Dis* 2008;10:945-8.
13. Priyadarshi S, Dogra BB, Nagare K, Rana KV, Sunkara R, Kandari A. A comparative study of open technique and Z-plasty in management of pilonidal sinus. *Med J DY Patil Univ* 2014;7:574-8.

**How to cite this article:** Manjunath BD, Kumar AP, Nischal N, Ramachandra R. Comparison of Z-Plasty and Limberg Flap Techniques in Management of Sacrococcygeal Pilonidal Sinus. *Int J Sci Stud* 2016;3(11):90-93.

**Source of Support:** Nil, **Conflict of Interest:** None declared.