

Concentration of Proteins in Intra-Osseous Jaw Cysts as an Adjunct to Diagnosis

Asish Kumar Das¹, V K Prajapati²

¹Associate Professor, Department of Oral & Maxillofacial Surgery, Burdwan Dental College & Hospital, Burdwan, West Bengal, India,

²Professor & Head, Department of Dentistry, Rajendra Institute of Medical Sciences, Ranchi, Jharkhand, India

Abstract

Introduction: Cysts of the jaw are a recognized clinical entity for a long time and are a benign bone destroying lesion. Their remains a diagnostic ambiguity between cysts and cyst-like lesions of the jaws.

Objective: The main objective of this study was to assess the total soluble protein content in fluid aspirates of intra osseous cyst of maxilla and mandible.

Materials and Methods: A total number of 43 patients provisionally diagnosed being afflicted by intra-osseous jaw cysts on the basis of clinical, and radiological examination were selected randomly irrespective of caste, creed, age, sex and religion. The chief consideration was radicular, dentigerous and odontogenic keratocysts along with its albumin and different globulin fractions and corroborating them with the clinical, radiological and histopathological findings.

Results: Among the total number of 43 uninfected intra-osseous jaw cysts histopathological evaluation revealed 24 cases to be radicular cysts, 11 cases were odontogenic keratocysts and 5 cases were dentigerous cysts. Calcifying odontogenic cyst, Nasopalatine duct cyst and residual cyst were one each in a number in the total sample. A peak frequency of radicular cysts was observed in the 4th decade of life dentigerous cysts in the second decade while keratocysts in the 3rd decade. All the cases revealed a male preponderance.

Conclusion: Today there remains an ambiguity in the diagnosis and treatment planning of intra-osseous jaw cysts. For this reason, it is necessary to evaluate and corroborate the clinical, radiological and biochemical findings with the histopathological features of cystic lesions with a view to proper diagnosis and treatment planning.

Keywords: Cystic fluid protein, Electrophoresis, Jaw cysts, Odontogenic keratocyst

INTRODUCTION

Many of the bone lesions in the oral and maxillofacial region are cystic or have features similar to cystic lesions. Spectrum of the lesions having cyst-like radiolucency in the oral and maxillofacial region include benign odontogenic cysts, aggressive cysts like keratocyst, calcifying odontogenic cyst, cystic tumors such as cystic ameloblastoma and other radiolucent non-odontogenic lesions. There is a large group of lesions that does not show any specific clinical

and radiographical finding.¹ Cysts in jaws enlarge when the permeability of the cyst wall changes, which the proteins of cyst fluid increase, and that the intracystic fluid pressure on the jaw bone increases because of inflammation. On the other hand, it is also believed that cysts enlarge when a prostaglandin-like substance, which is generated in the wall, acts chemically in the resorption of the jaw bone.² Jaw cyst lining cells have an active transporting mechanism for Na⁺ ion and K⁺ ion, a secreting mechanism and a selecting mechanism, and they allow permeation of electrolytes, lipids and protein into cysts.³ Although odontogenic keratocysts are benign, they are often locally destructive and tend to recur after conservative surgical treatment. They must therefore be distinguished from other cysts of the jaw.⁴ Since odontogenic cysts constitute an important part of facial lesions, diagnosing them before surgery will help a lot to determine surgical procedure for preventing the future recurrence of the cyst.⁵

Access this article online



www.ijss-sn.com

Month of Submission : 12-2014
Month of Peer Review : 01-2015
Month of Acceptance : 01-2015
Month of Publishing : 02-2015

Corresponding Author: Dr. V K Prajapati, Bisheswar Apartment, Baxi Compound, Bariatu, Ranchi, Jharkhand, India. Phone: +91 9431373147. E-mail: prajajoy@gmail.com

Objectives

To evaluate the different clinical, radiological, biochemical, intra-operative and light microscopic features of intra-osseous jaw cysts and to compare and corroborate the findings, which will help to establish the diagnostic parameters for the intra-osseous jaw cysts. The surgical management of such jaw cysts thereby will vary accordingly.

METHODOLOGY

A total number of 43 patients provisionally diagnosed being afflicted by intra-osseous jaw cysts on the basis of clinical, and radiological examination were selected randomly irrespective of caste, creed, age, sex and religion. The bone overlying the cystic lesion was incompressible and thick, compressible and thin or fluctuant with destruction of overlying bone. In all the cases after infiltrating the overlying mucosa with local anesthetic solution under aseptic condition, the cystic content was aspirated in a sterile 5 ml. Disposable syringe by a sterile, thick, wide-bore 18 gauge needle thick enough to penetrate a thin layer of bone overlying the lesion. Where the overlying bone was thick enough, a suitable mucoperiosteal flap was reflected and with a No.8 surgical round bur the superficial portion of the cortical bone was thinned out in such a way so that the remaining portion of bone was thin enough to be penetrated by an 18 gauge needle. Bone removed by the surgical bur was done at a low speed with a continuous flow of normal saline solution. Specimens, which contained visible quantities of fresh blood or pus were discarded. The cystic content not <1 ml. was then collected in a sterile test-tube, tightly stoppered and stored.

Under natural light the specimens were examined for their color, consistency, presence of cholesterol crystals with their characteristic shimmering effect or Keratin flecks, which present themselves as yellowish white thread-like strands, which appear to be pus but without any offensive odor and lack of confirmation of secondary infection in the history of the lesion.

Biochemical Analysis

In all the cases 5 ml. of blood was drawn by venepuncture from the ante cubital vein under proper aseptic condition and collected in non-heparinized sterile test tube and kept at room temperature for 1 h. The blood specimen and the cystic content were then centrifuged at 2, 000 rev/min for 5 min to remove the cell debris and deposits. The supernatant cystic fluid and autologous serum thus collected were subsequently analyzed for their protein contents by cellulose acetate membrane (CAM) electrophoresis.

The protein content and its different fractions were also quantitated by scanning the CAM strips in a densitometer

at 590 nm (green filter) and the relative percentage and absolute value of the different protein fractions were recorded directly. The various biochemical findings were then recorded and analyzed according to the total soluble protein content, albumin and globulin content along with the different globulin fractions (alpha-1, alpha-2, Beta and Gamma Globulin).

Radiological Finding

The radiological features were recorded and corroborated with other relevant parameters using Intra-oral periapical radiographs, orthopantomograph and paranasal sinus views.

Intra-operative Finding

All the cases were operated under local anesthesia or general anesthesia either by enucleation or marsupialization depending on the individual patients and various other operative findings were recorded and the specimens were subjected to histopathological evaluation.

RESULTS AND OBSERVATIONS

Amongst the total number of 43 uninfected intra-osseous jaw cysts histopathological evaluation revealed 24 cases to be radicular cysts, 11 cases were odontogenic Keratocysts and 5 cases were dentigerous cysts. Calcifying odontogenic cyst, nasopalatine duct cyst and residual cyst were one each in a number in the total sample. A peak frequency of radicular cysts was observed in the 4th decade of life dentigerous cysts in the 2nd decade while Keratocysts in the third decade. All the cases revealed a male preponderance. 19 of the 24 cases of radicular cysts showed a significant degree of expansion, 4 out of 5 cases in dentigerous cysts while none in the case of odontogenic keratocysts. Egg-shell crackling was found in 80% of dentigerous cysts and 33% in case of dentigerous cysts. About 16% cases of radicular cysts were radiologically observed to be multilocular, all cases of dentigerous to be unilocular while 64% cases of odontogenic keratocysts were multilocular. All the cases of dentigerous cysts had an impacted tooth in the lesion with marked root resorption in 40% cases. About 67% of radicular cysts were associated with carious exposed tooth/teeth and intra-operatively the cystic lining was found to be adherent to the root apex of the carious tooth/teeth. The mean value of the total soluble protein content in the cystic fluid (6.85gm/dl) of radicular cysts was higher (Table 1) than that in autologous serum (6.10 g/dl). Analysis by *t*-test revealed the observation to be statistically significant ($t = 2.78$). However, the mean albumin level in the cystic fluid (3.76 g/dl) was found to be lower (Table 2) than that in autologous serum (4.04g/dl). The mean globulin level in (Table 3) was found to be higher (3.13 g/dl) than autologous serum (2.49 g/dl). In dentigerous cysts, the

Table 1: Total soluble protein content in cystic fluid and autologous serum

Type of jaw cyst	Nature of specimen	Mean value (g/dl)	SD (\pm)	Minimum value (g/dl)	Maximum value (g/dl)	t value
Radicular cyst	Cystic fluid	6.85	1.01	5.20	8.80	2.78
	Autologous serum	6.10	0.77	5.20	7.60	2.78
Odontogenic keratocyst	Cystic fluid	4.14	0.63	3.10	5.80	13.28
	Autologous serum	7.46	0.47	6.40	7.90	13.28
Dentigerous cyst	Cystic fluid	5.60	0.45	5.20	6.40	0.21
	Autologous serum	5.66	0.37	5.20	6.30	0.21

SD: Standard deviation

Table 2: Albumin content in cystic fluid and autologous serum

Type of jaw cyst	Nature of specimen	Mean value (g/dl)	SD (\pm)	Minimum value (g/dl)	Maximum value (g/dl)	t value
Radicular cyst	Cystic fluid	3.76	0.55	2.60	4.80	1.65
	Autologous serum	4.04	0.58	2.90	4.90	1.65
Odontogenic keratocyst	Cystic fluid	2.92	0.33	2.30	3.60	13.62
	Autologous serum	4.69	0.26	4.40	5.40	13.62
Dentigerous cyst	Cystic fluid	3.30	0.24	2.90	3.60	0.81
	Autologous serum	3.08	0.48	2.60	3.70	0.81

SD: Standard deviation

Table 3: Globulin content in cystic fluid and autologous serum

Type of jaw cyst	Nature of specimen	Mean value (g/dl)	SD (\pm)	Minimum value (g/dl)	Maximum value (g/dl)	t value
Radicular cyst	Cystic fluid	3.13	0.69	2.00	4.50	4.00
	Autologous serum	2.49	0.34	1.80	3.02	4.00
Odontogenic keratocyst	Cystic fluid	1.22	0.39	0.80	2.20	8.61
	Autologous serum	2.77	0.43	1.80	3.30	8.61
Dentigerous cyst	Cystic fluid	2.50	0.47	2.00	3.20	1.00
	Autologous serum	2.78	0.31	2.30	3.20	1.00

SD: Standard deviation

mean value of the total soluble protein content in the cystic fluid was 5.60 g/dl, which was less (Table 1) than that in autologous serum (5.66 g/dl). However the mean albumin level in the cystic fluid (3.30 g/dl) was found to be higher (Table 2) than that in autologous serum (3.08 g/dl). The mean globulin level in dentigerous cysts (Table 3) was found to be lower (2.50 g/dl) than autologous serum (2.78 g/dl). In odontogenic keratocysts, the mean value of the total soluble protein content in the cystic fluid was 4.14g/dl, which was less (Table 1) than that in autologous serum (7.46 g/dl). However the mean albumin level in the cystic fluid (2.92 g/dl) was found to be lower (Table 2) than that in autologous serum (4.69 g/dl), which was statistically significant ($t = 13.62$). The mean globulin level (Table 3) was found to be lower (1.22 g/dl) than autologous serum (2.77 g/dl) and was also statistically significant ($t = 8.61$). Tables 4-7 reveals the different values of alpha 1, alpha 2, beta and gamma globulin fractions in different cystic fluids and autologous serum. The mean alpha 1 globulin level in radicular cyst was 0.31 g/dl, while in dentigerous cyst it was 0.16 g/dl and 0.19 g/dl in odontogenic keratocysts, which was found to be statistically significant ($t = 3.0$). The mean alpha 2 globulin level in radicular cyst was 0.44 g/dl, while in dentigerous cyst it was 0.29 g/dl and 0.32 g/dl

in odontogenic keratocysts, which were also statistically significant ($t = 3.17$). The mean beta globulin fraction in cystic fluid of radicular cyst was found to be 0.73 g/dl, while in dentigerous cyst it was 0.45 g/dl and 0.25 g/dl in odontogenic keratocysts with a t value of 6.77. The mean gamma globulin level in cystic fluid of radicular cyst was 1.71 g/dl ($t = 2.72$), while in dentigerous cyst it was 1.39 g/dl and in odontogenic keratocysts 0.46 g/dl and was statistically significant ($t = 6.77$).

Radicular Cyst

24 cases (55.8%) were of radicular variety. The peak frequency was in the 4th decade with equal involvement of both anterior and posterior regions. All cases had either a carious discolored tooth/teeth with a history of trauma in the involved region. Aspiration of cystic content revealed straw-colored fluid. All the cases revealed a regular radiological outline and intra-operatively a thick and intact lining with a smooth surface texture were found to be firmly attached to the carious or discolored tooth/teeth. Electrophoretic analysis revealed that the total soluble protein content of cystic fluid was higher than that of autologous serum, and the % of albumin and globulin was 54.89 and 45.11 respectively (Figure 1).

Odontogenic Keratocyst

25.58% cases were Odontogenic keratocysts with a peak frequency in the 3rd decade. Marked preponderance was found in the mandibular posterior region with least expansion of bony cortical plates and having maximum, radiological involvement of the jaw bone. Only 1-3rd of the cases revealed true anodontia. Dirty-white cheesy inspissated material was found on aspiration in all the cases. Keratin squames in the aspirated cystic fluid was a constant finding. Intra-operatively the cystic lining was thin and fragile with an irregular surface texture in majority of the cases. Electrophoretic analysis revealed that the total soluble protein content of the cystic fluid was lower than that in serum. Calcifying odontogenic cyst, nasopalatine duct cyst and residual cyst were one each in a number in the total sample (Figure 2).

Dentigerous Cyst

5 cases (11.62%) were of dentigerous variety with a peak frequency in the 2nd decade with all the cases revealing clinical anodontia and radiologically having impacted teeth within the lesion. A marked preponderance involving the maxillary canines was observed. Intra-operatively the cystic lining was mostly thick and intact in nature with a smooth surface texture associated with an impacted tooth. Biochemical analysis revealed that the total soluble protein content of the cystic fluid was similar to that in autologous serum with 58.93% albumin and 41.07% globulin (Figure 3).

DISCUSSION

Electrophoresis is the name given to the movement of charged particles through an electrolyte subjected to an electric field and was 1st developed by Toller in 1936.⁶ Proteins in fluid from non-keratinizing jaw cysts showed separation patterns on CAM and percentage distribution of the electrophoretic fractions.⁷ Electrophoresis separates proteins based on their physical properties and the subsets of these proteins are used in interpreting the results.⁸ Various plasma proteins have different surface charges. They, therefore, migrate at different rates from the point of application of the protein mixture to the other end of the CAM strip.⁹

Different authors have shown the use of electrophoresis for the separation of the different protein fractions in the fluids of jaw cysts and thereby to distinguish between the different protein fractions both qualitatively and quantitatively.^{6,7,10,11} Quantitative determinations of the protein fractions can be carried out either by elution or by scanning of the stained CAM strips by densitometer, which convert bands to characteristic peaks of albumin, alpha 1,

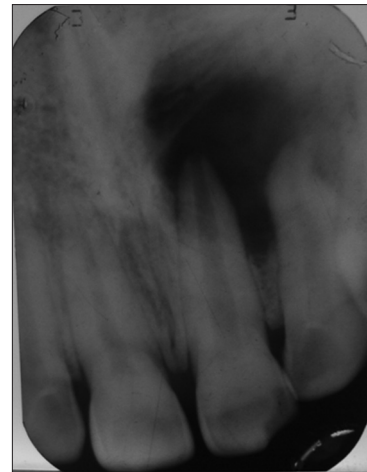

Figure 1: Radicular cyst

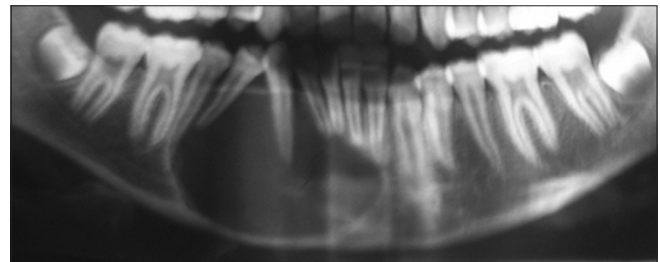


Figure 2: Odontogenic keratocyst

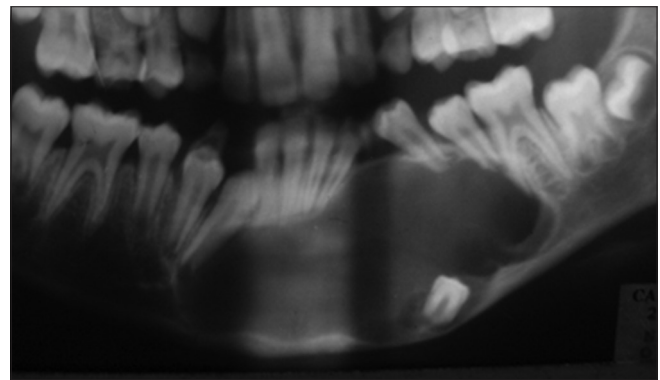


Figure 3: Dentigerous cyst

alpha 2, globulin, and gamma globulin. The areas below each section of the curve can be measured during scanning by an integrator. Each fraction can then be calculated as a percent of the total by simple proportion.¹²

In the present study, the albumin content in the cystic fluid of odontogenic keratocysts ranged from 2.30 g/dl to 3.60 g/dl with a mean level of 2.92 g/dl while the albumin content in autologous serum ranged from 4.40 g/dl to 5.40 g/dl with a mean value of 4.69 g/dl. The mean albumin level in the cystic fluid was lower than that in autologous serum, which was statistically significant. Toller (1970) postulated that soluble protein levels for non-keratinizing cysts were in the range of 5.0-11.0 g per 100 ml. with a mean

of 7.1 g per 100 ml while all the Keratinizing cysts fluids exhibited soluble protein levels below 3.5 g per 100 ml.

Browne observed that the continuous layer of keratinized epithelium lining the keratocyst forms a less readily penetrable barrier than the frequently discontinuous, non-keratinized epithelium lining the other cysts and thus the proteins would accumulate in the cystic fluid only with difficulty.¹⁰

Majority of the cases of odontogenic keratocysts were treated either when the diagnosis was not made at the time of treatment, or the significance of the diagnosis was not understood. An extra-oral approach and even jaw resection are often recommended.⁷ Ahlfors *et al.* (1984)¹³ designated the term “benign cystic tumor” for odontogenic Keratocysts. Bornstein *et al.* (2005)¹⁴ opined that besides a predilection for recurrence, the keratocysts, in contrast to other odontogenic cysts, show a more aggressive clinical behavior and demonstrate a high mitotic count and higher turnover rate of the epithelium. This led to the tentative suggestion that the keratocyst might be a benign cystic neoplasm rather than simply an odontogenic cyst. DeGould *et al.* (1991).¹⁵ Reported of recurrence of odontogenic keratocyst in a bone graft after partial mandibulectomy and reconstruction. Macroscopic examination of the removed dentigerous cyst occasionally reveals mural thickenings which, on microscopical investigation, proved to be ameloblastic changes. Eversole *et al.* (1975)¹⁶ reported of 36 cases of intra-osseous squamous cell carcinoma of which 27 (75%) appeared to originate in odontogenic cysts. Hamidreza *et al.* (2012)⁵ postulated that odontogenic keratocyst Oklahoma City has a more aggressive nature than other odontogenic cysts and its recurrence after surgery is higher than other cysts.

In this study, the mean gamma globulin level in cystic fluid of radicular cyst was 1.71 g/dl ($t = 2.72$) and in odontogenic keratocysts 0.46 g/dl, which was also statistically significant ($t = 6.77$). Compared with serum, the fluid of radicular cysts contain more gamma globulin probably due to the high level of immunoglobulins in cystic fluid, which are the result solely of their exudation from the blood vessels in the cyst capsule into the cyst cavity. The concentration of some non-immunoglobulin proteins in cyst fluids is proportional to their concentration in their plasma and inversely proportional to their molecular weight.⁴

The cyst levels of alpha-1 globulin were found to be higher than that of autologous serum in case of radicular and dentigerous cysts whereas the alpha-2 globulin levels were found to be lower than the autologous serum in radicular and keratocysts. While that of dentigerous cyst was marginally higher. Similar were the observations of Browne (1976)¹⁰ and Skaug (1977)¹¹ who found that the

cyst levels of alpha-2 globulin lower than the autologous serum in majority of the jaw cysts. They postulated that cystic fluid is primarily exudates with an increased gamma globulin fraction and not simply a dialysate from the blood plasma produced by filtration through the cyst capsule.

CONCLUSIONS

Since odontogenic cysts encompass an important part of oral and maxillofacial lesions, diagnosing them before surgery will help us to determine surgical procedures, conservative or radical, for preventing the future recurrence of the cyst. Odontogenic keratocyst has a more aggressive character than any other odontogenic jaw cysts, and its recurrence rate following surgery is comparatively higher than that of other jaw cysts. The different biochemical findings can be used for diagnosing cysts before surgery and thereby formulating the surgical procedure to minimize the chances of recurrence. In odontogenic keratocysts, the mean value of the total soluble protein content in cystic fluid was significantly less than that in autologous serum along with a significantly lower albumin and globulin levels in sharp contrast to that of the radicular or dentigerous varieties. Concentration of α 1 and β globulin in radicular cysts was found to be higher than other varieties. Still today there remains an ambiguity in the diagnosis and treatment planning of intra-osseous jaw cysts. For this reason, it is necessary to evaluate and corroborate the clinical, radiological and biochemical findings with the histopathological features of cystic lesions with a view to proper diagnosis and treatment planning.

REFERENCES

- Guyot JP, Obradovic D, Krayenbuhl M, Zbaeren P, Lehmann W. Fine-needle aspiration in the diagnosis of head and neck growths: is it necessary? *Otolaryngol Head Neck Surg* 1990;103:697-701.
- Suzuki M. A biochemical study of the nature of jaw cysts (II). The role of lipids in the enlargement of cysts. *J Maxillofac Surg* 1984;12:213-24.
- Suzuki M. A study of biological chemistry on the nature of jaw cysts. On the maintenance of homeostasis in jaw cyst fluid. *J Maxillofac Surg* 1975;3:106-18.
- Singh M, Gupta KC. Surgical treatment of odontogenic keratocyst by enucleation. *Contemp Clin Dent* 2010;1:263-7.
- Arabian H, Fani MM, Nejad SH. Comparison of the concentration and types of the proteins present in maxillofacial odontogenic cysts fluid. *Afr J Microbiol Res* 2012;6:2816-21.
- Toller PA. Protein substances in odontogenic cyst fluids. *Br Dent J* 1970;128:317-22.
- Skaug N, Hofstad T. Proteins in fluid from non-keratinizing jaw cysts. 1. Separation patterns on cellulose acetate membranes and percentage distribution of the electrophoretic fractions. *J Oral Pathol* 1973;2:112-25.
- O'Connell TX, Horita TJ, Kasravi B. Understanding and interpreting serum protein electrophoresis. *Am Fam Physician* 2005;71:105-12.
- Keele CA, Neil E, Joels N. *Samson Wright's Applied Physiology*. 13th ed. New York: Oxford University Press; 1982. p. 20-2.
- Browne RM. Some observations on the fluids of odontogenic cysts. *J Oral Pathol* 1976;5:74-87.

11. Skaug N. Soluble proteins in fluid from non-keratinizing jaw cysts in man. *Int J Oral Surg* 1977;6:107-21.
12. Smith I. Chromatographic and electrophoretic techniques. *Zone Electrophoresis*. 4th ed., Vol. 2. London: Heinemann; 1976.
13. Ahlfors E, Larsson A, Sjögren S. The odontogenic keratocyst: A benign cystic tumor? *J Oral Maxillofac Surg* 1984;42:10-9.
14. Bornstein MM, Filippi A, Altermatt HJ, Lambrecht JT, Buser D. The odontogenic keratocyst– Odontogenic cyst or benign tumor? *2005;115:110-28.*
15. DeGould MD, Goldberg JS. Recurrence of an odontogenic keratocyst in a bone graft. Report of a case. *Int J Oral Maxillofac Surg* 1991;20:9-11.
16. Eversole LR, Sabes WR, Rovin S. Aggressive growth and neoplastic potential of odontogenic cysts: with special reference to central epidermoid and mucoepidermoid carcinomas. *Cancer* 1975;35:270-82.

How to cite this article: Das AK, Prajapati VK. Concentration of Proteins in Intra-Osseous Jaw Cysts as an Adjunct to Diagnosis. *Int J Sci Stud* 2015;2(11):150-155.

Source of Support: Nil, **Conflict of Interest:** None declared.