

# Panorama of Pleomorphic Adenoma in a Series of Patients Presented over a Period of 5-year

Pawan Bhat<sup>1</sup>, Sachan Bhat<sup>1</sup>, Deepa Hatwal<sup>2</sup>, Sheela Chaudhri<sup>2</sup>

<sup>1</sup>Assistant Professor, Department of Pathology, Vir Chander Singh Garhwali Government Medical Science & Research Institute, Garhwal, Uttarakhand, India, <sup>2</sup>Associate Professor, Department of Pathology, Vir Chander Singh Garhwali Government Medical Science & Research Institute, Garhwal, Uttarakhand, India

## Abstract

**Introduction:** Salivary gland tumors are one of the most heterogeneous groups of human tumors with over 40 subtypes of neoplasms reported. Pleomorphic adenoma is the most common salivary gland tumor accounting for nearly 60% of all the salivary gland neoplasms. As there has been very little study, if any, carried out on salivary gland pathology in our region, hence we conducted this study on histological diversity and variability among cell types within pleomorphic adenoma. This study can help us determine the various characteristics of pleomorphic adenoma.

**Purpose:** To study the panorama of pleomorphic adenoma including its histopathological patterns and cell types.

**Materials and Methods:** A retrospective study, over a period of 5-year, was carried out on the material, which included the histopathological slides and tissue blocks and relevant clinical data were obtained from the Department of Pathology.

**Results:** Parotid gland was the most common salivary gland affected by a pleomorphic adenoma (66.3%). Stroma-rich pleomorphic adenomas were the most common histopathological type (45.65%) with plasmacytoid cells being the most common single cell types seen (85.87%).

**Conclusion:** In our study, parotid gland came out to be the most common site for the development of pleomorphic adenoma with stroma-rich pleomorphic adenoma being the most common histopathological type. Among minor salivary glands, the palate was most commonly affected.

**Key words:** Histopathological diversity, Pleomorphic adenoma, Salivary gland neoplasms

## INTRODUCTION

The salivary glands in the body are classified into the major salivary glands and the minor salivary glands. The major salivary glands include the paired parotid glands, the submandibular glands, and the sublingual glands. The minor salivary glands are smaller in size, more numerous and are present throughout the upper aerodigestive tract such as the floor of mouth, palate, lips, tongue, cheeks, and oropharynx. There is a whole range of lesions, both reactive and neoplastic that can be encountered in more than 500 salivary glands present in the human body. Histologically,

salivary gland tumors have been described as one of the most heterogeneous group of human tumors and over 40 subtypes of neoplasms have been reported.<sup>1</sup> Salivary gland tumors are rare neoplasms comprising <3% of all neoplasms of head and neck region and are known by their diverse histological features.<sup>2</sup> Pleomorphic adenoma is the most common salivary gland tumor and accounts for about 60% of all salivary gland neoplasms. The mean age at presentation is 46 years, but the age ranges from the first to the tenth decade with a slight female predominance. About 80% of pleomorphic adenomas arise in the parotid, 10% in the submandibular gland and 10% in the minor salivary glands.<sup>3</sup> Pleomorphic adenoma is characterized by histological diversity and shows variable cell types, hence also known as a mixed tumor or polymorphic adenoma. The aim of the current study was to describe the various characteristic features of pleomorphic adenoma including clinical features and special reference to the various histopathological patterns and cell types seen in this tumor type.

### Access this article online



www.ijss-sn.com

**Month of Submission :** 12-2015  
**Month of Peer Review :** 01-2016  
**Month of Acceptance :** 01-2016  
**Month of Publishing :** 02-2016

**Corresponding Author:** Dr. Pawan Bhat, Department of Pathology, Vir Chander Singh Garhwali Government Medical Sciences & Research Institute, Srikot, Srinagar, Garhwal, Uttarakhand, India. E-mail: pawanrajbhat@gmail.com

## MATERIALS AND METHODS

This was a hospital-based retrospective study carried out in the Department of Pathology, Vir Chander Singh Garhwali Government Medical Science and Research Institute, Srinagar, Garhwal, Uttarakhand. The material for the study included histopathology slides, and tissue blocks, of all salivary gland tumor specimens received between August 2010 and August 2015. All cases of benign salivary gland tumors including pleomorphic adenomas diagnosed on histopathology were taken for study. The hematoxylin and eosin (H and E) stained histopathology slides were retrieved and were reviewed using light microscopy under various magnifications. Various cytological and histopathological findings were noted. Fresh sections were taken from tissue blocks in some cases, wherever required, and were stained with H and E stain. The various histopathological features of all cases were noted down. Data were analyzed using tables, figures, and percentages.

## OBSERVATIONS

A total of 116 cases of benign salivary gland neoplasms were reported in the mentioned study period, extending from August 2010 to August 2015, of which 92 cases were diagnosed as pleomorphic adenoma. All the relevant data including the age of patients, site of tumors, side or laterality, size of the tumors, and gender distribution were recorded. Parotid glands were found to be the most commonly affected salivary glands followed by submandibular glands and sublingual glands. Predominant cell types in sections and

stromal tissue percentages were studied and are represented in tabulated form as in Tables 1-4.

### Site

81 cases of pleomorphic adenoma were seen affecting major salivary glands while the rest 11 cases were seen affecting minor salivary glands. The most common site was a parotid gland, which was affected in 61 cases (66.3%) followed by submandibular gland with 11 cases (11.9%), sublingual with 9 cases (9.8%), and all minor salivary glands included together amounting to 11 cases (11.9%). Out of all the minor salivary glands, the palate was seen to be the most common site of pleomorphic adenoma with 6.5% of total cases. One case of pleomorphic adenoma affecting lacrimal gland in orbit was also seen. The detailed description is given in Table 1.

### Age and Sex Distribution

In our study, we found out pleomorphic adenoma affecting patients in all age groups. The youngest case affected was a 14-year-old male and the eldest was a 72-year-old female. The most common age group affected was of 21-30 years and more than 50% cases were found in third and fourth decades of life. Pleomorphic adenoma was found to be more commonly affecting the females than males. Out of a total of 92 cases, 52 (56.52%) were found in females, and 40 (43.48%) were seen in males. The descriptive analysis is given in Table 2.

### Laterality and Size

Out of 72 cases of pleomorphic adenoma affecting parotid and submandibular glands, left sided salivary glands were seen to be affected in 40 (55.56%) cases, and right sided were seen to be affected in 32 (44.44%) cases. 50 cases were seen to be presenting with tumors having size between 3 and 6 cm, while 28 cases were seen presenting with tumor size <3 cm and only 4 cases were seen to be presenting with tumor size more than 6 cm.

**Table 1: Anatomic distribution of pleomorphic adenoma**

Site of tumor	Number of cases	Percentage
Parotid	61	66.3
Submandibular gland	11	11.9
Sublingual	09	9.8
Palate	06	6.5
Cheek	02	2.2
Lip	02	2.2
Lacrimal gland	01	1.1
Total	92	100

**Table 2: Age distribution & sex distribution of pleomorphic adenoma**

Age (years)	N (%)	Female	Male
11-20	04 (04.35)	2	2
21-30	26 (28.26)	14	12
31-40	24 (26.09)	14	10
41-50	16 (17.39)	10	06
51-60	14 (15.22)	07	07
61-70	08 (08.69)	05	03
Total	92 (100)	52 (56.52)	40 (43.48)

**Table 3: Laterality of pleomorphic adenoma**

Site	Side	
	Left	Right
Parotid	34	27
Submandibular	6	5
Total (%)	40 (55.56)	32 (44.44)

**Table 4: Distribution of histological types of pleomorphic adenoma**

Histological pattern	N (%)
Stroma-rich	42 (45.65)
Classical type	32 (34.78)
Cell-rich	18 (19.57)
Total	92 (100)

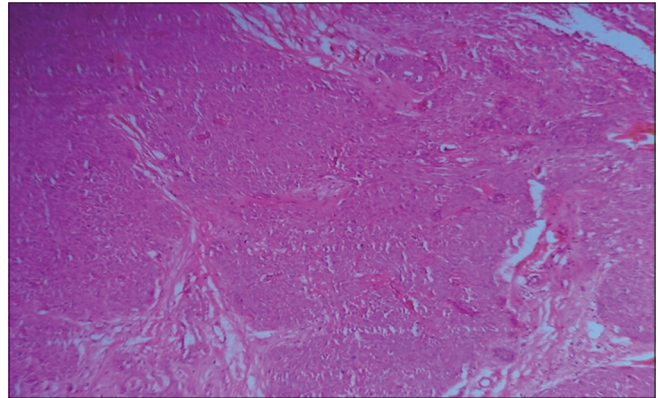
### Predominant Histological Type and Predominant Cell Type

Pleomorphic adenoma was classified into stroma-rich or myxoid, cell-rich or cellular and classical types as described by Seifert *et al.*<sup>4</sup> Stroma-rich pleomorphic adenomas (Figure 1) were the most common accounting for 42 cases (45.65%), followed by classical type with 32 cases (34.78%) and cell-rich type (Figure 2) with 18 (19.57%) cases and are depicted in Table 4. Plasmacytoid cells and spindle cells (Figure 3) were the most common cell types seen, and all the 100 % cases had the presence of either of the two. Plasmacytoid cells were the most common single type of cells seen in 79 (85.87%) cases while spindle cells, basaloid cells, and squamous cells were seen in 72 cases (78.26%), 34 cases (36.95%), and 15 cases (16.30%), respectively. Islands of cartilage, foci of mature bone, and microcystic pattern were seen in few cases (Figures 4-6).

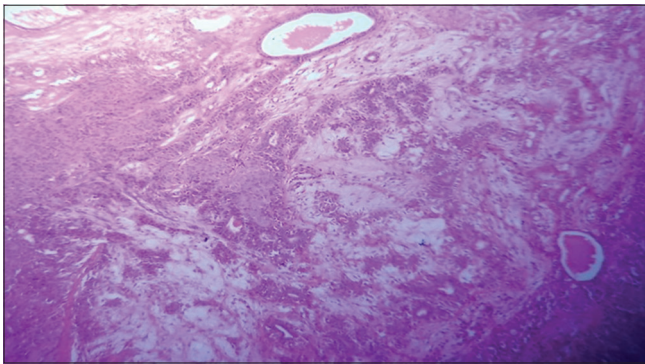
### DISCUSSION

Pleomorphic adenoma also known as a benign mixed tumor or polymorphic adenoma is a slow growing benign salivary gland neoplasm, most commonly affecting the parotid gland. In the present study of 92 cases of pleomorphic adenomas, the majority of cases were seen to be affecting the major salivary glands, while only 11 cases (11.6%) were seen to be

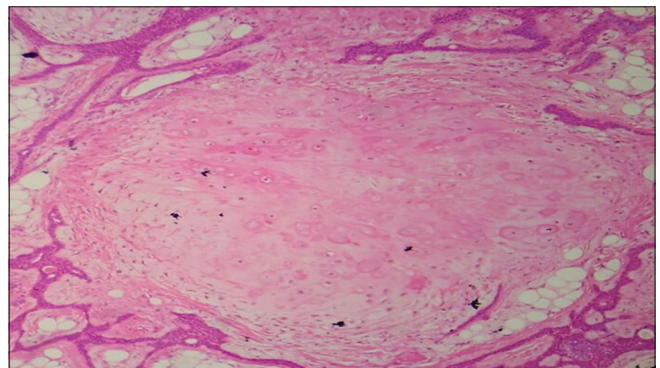
affecting the minor salivary glands. Parotid gland was seen to be the most commonly affected gland, and it accounted for 61 cases (66.3%). These findings are similar to the findings from the studies done by Ito *et al.*,<sup>5</sup> Waldron,<sup>6</sup> and Eveson and Cawson<sup>7</sup> whose studies found 70%, 63%, and 71% cases of pleomorphic adenoma affecting parotid glands, respectively. Pleomorphic adenomas were seen affecting 11 minor salivary glands in our study and out of those, 4 cases were found in the palatal area. Palate was seen to be the most common site of pleomorphic adenoma among the



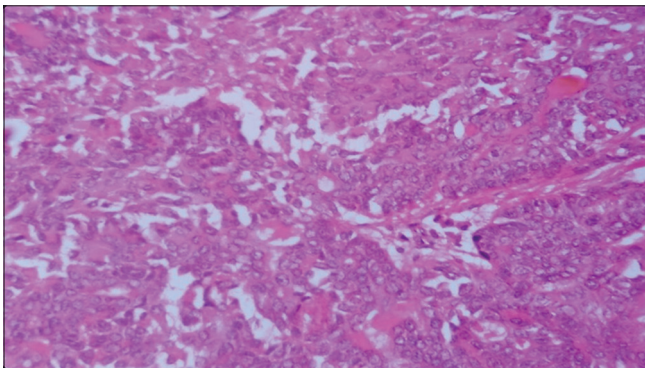
**Figure 3: Cellular pleomorphic adenoma showing spindle cells and plasmacytoid cells (H and E stain, x100)**



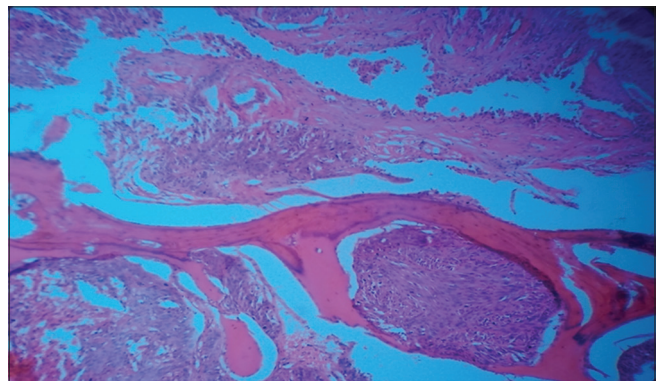
**Figure 1: Pleomorphic adenoma showing myxoid areas (H and E stain, x100)**



**Figure 4: Pleomorphic adenoma showing cartilaginous differentiation (H and E stain, x100)**

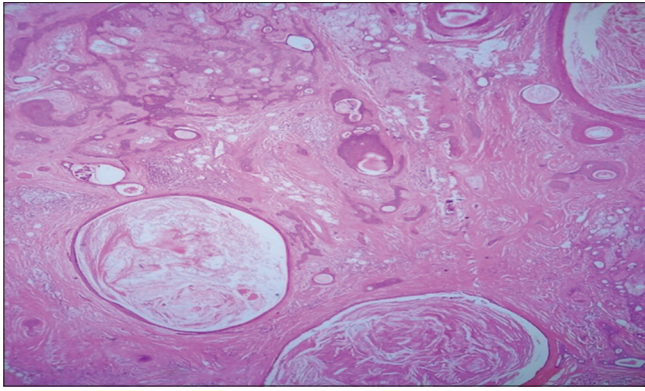


**Figure 2: Pleomorphic adenoma with hypercellular appearance (H and E stain, x100)**



**Figure 5: Pleomorphic adenoma with osseous differentiation (H and E stain, x100)**





**Figure 6: Pleomorphic adenoma showing keratinized epithelial plugs in the lumen (H and E stain, x100)**

minor salivary glands which is in close concordance with the study of Vaidya *et al.*<sup>8</sup> In our study, the most common age group affected was seen to be of 21-30 years and more than 50% cases of pleomorphic adenomas were found in patients in their third and fourth decades of life. Nearly 56% of all patients were females. However, studies of Al-Khtoum *et al.*<sup>9</sup> found it marginally more common in males. Our study findings were very similar to the study done by Chidzonga *et al.*,<sup>10</sup> who in a study of a series of more than 200 cases of pleomorphic adenomas, found 58% of tumors occurred in females, and the tumor was most common in the 3<sup>rd</sup>, 4<sup>th</sup>, and 5<sup>th</sup> decades of life. However, quite a few studies including the studies of Eveson and Cawson<sup>7</sup> and Chidzonga *et al.*<sup>10</sup> showed this neoplasm affecting patients in the 4<sup>th</sup> and 5<sup>th</sup> decades. In studies done by Al-Khtoum *et al.*<sup>9</sup> and Friedrich *et al.*,<sup>11</sup> laterality of tumors was more obvious, and the two studies showed the involvement of right side in 72.5 % and 65.8% cases, respectively. However, in our study, we found left sided major salivary glands (56%) marginally more commonly involved than the right sided (44%), which was in concordance with the study of Ito *et al.*<sup>5</sup> We also came to the conclusion from our study that most of these tumors were smaller in size and only 4 (4.34%) were larger than 6 cm at the time of presentation. All the minor salivary gland pleomorphic adenomas were <6 cm in size. In our study, stromal rich type corresponded with 45.6% cases while classical subtype and cell-rich subtype were lesser common with 34.7% and 19.5% cases, respectively. Most of other studies, such as the studies of Stennert *et al.*<sup>12</sup> and Paris *et al.*,<sup>13</sup> were having a similar distribution of the subtypes with stromal subtype being the most common. Plasmacytoid cells were the most common cell type in almost all the studies such as the studies of Ellis and Auclair<sup>14</sup> and Ito *et al.*,<sup>5</sup> which found spindle cells the second most common type of cell after plasmacytoid cells.

## CONCLUSION

In our series of patients, pleomorphic adenoma of the salivary glands was found to have similar characteristic features clinically as well as histopathologically to many of the studies done and published worldwide. However, a paradox to many studies on pleomorphic adenoma in literature, we found the neoplasm affecting predominantly younger patients and also sublingual glands were involved in quite a few cases, in our study. Furthermore, from our study, we concluded that while diagnosing pleomorphic adenoma, various histopathological patterns should be thoroughly kept in mind, the knowledge of which is essential for correct diagnosis.

## REFERENCES

1. Facquin WC, Powers CN. Salivary Gland Cytopathology: Essentials in Cytopathology. Vol. 5. New York: Springer; 2008. p. 57-80.
2. Forty MJ, Wake MJ. Pleomorphic salivary adenoma in an adolescent. Br Dent J 2000;188:545-6.
3. WHO Classification of Tumours. Salivary glands-pleomorphic adenoma. In: Barnes L, Everson JW, Reichart P, Sidran Sky D, editors. Pathology and Genetics Head and Neck Tumours. 20th ed. Lyon: IARC Press; 2005. p. 254-9.
4. Seifert G, Langrock I, Donath K. A pathological classification of pleomorphic adenoma of the salivary glands (author's transl). HNO 1976;24:415-26.
5. Ito FA, Jorge J, Vargas PA, Lopes MA. Histopathological findings of pleomorphic adenomas of the salivary glands. Med Oral Patol Oral Cir Bucal 2009;14:E57-61.
6. Waldron CA. Mixed tumor (pleomorphic adenoma) and myoepithelioma. In: Ellis GL, Auclair PL, Gnepp DR, editors. Surgical Pathology of Salivary Glands. Philadelphia, PA: WB Saunders Co.; 1991. p. 165-86.
7. Eveson JW, Cawson RA. Salivary gland tumours. A review of 2410 cases with particular reference to histological types, site, age and sex distribution. J Pathol 1985;146:51-8.
8. Vaidya AD, Pantvaidya GH, Metgudmath R, Kane SV, D'Cruz AK. Minor salivary gland tumors of the oral cavity: A case series with review of literature. J Cancer Res Ther 2012;8:S111-5.
9. Al-Khtoum N, Qubilat AR, Al-Zaidaneen S, Al Mefleh S, Al-Qudah A. Clinical characteristics of pleomorphic adenoma of salivary glands among Jordanian patients. J Pak Med Assoc 2013;63:358-60.
10. Chidzonga MM, Lopez Perez VM, Portilla Alvarez AL. Pleomorphic adenoma of the salivary glands. Clinicopathologic study of 206 cases in Zimbabwe. Oral Surg Oral Med Oral Pathol Oral Radiol Endod 1995;79:747-9.
11. Friedrich RE, Li L, Knop J, Giese M, Schmelzle R. Pleomorphic adenoma of the salivary glands: Analysis of 94 patients. Anticancer Res 2005;25:1703-5.
12. Stennert E, Guntinas-Lichius O, Klusmann JP, Arnold G. Histopathology of pleomorphic adenoma in the parotid gland: A prospective unselected series of 100 cases. Laryngoscope 2001;111:2195-200.
13. Paris J, Facon F, Chrestian MA, Giovanni A, Zanaret M. Pleomorphic adenoma of the parotid: histopathological study. Ann Otolaryngol Chir Cervicofac 2004;121:161-6.
14. Ellis GL, Auclair PL. Tumors of the salivary glands. Atlas of Tumor Pathology. 3rd Series, Fascicle 17. Washington, DC: Armed Forces Institute of Pathology; 1996.

**How to cite this article:** Bhat P, Bhat S, Hatwal D, Chaudhri S. Panorama of Pleomorphic Adenoma in a Series of Patients Presented over a Period of 5-year. Int J Sci Stud 2016;3(11):210-213.

**Source of Support:** Nil, **Conflict of Interest:** None declared.