

# A Step toward Precision: A Review on Surgical Guide Templates for Dental Implants

Amrita Pawar<sup>1</sup>, Sangam Mittal<sup>2</sup>, Ricky Pal Singh<sup>3</sup>, Rabbpreet Bakshi<sup>4</sup>, Varun Sehgal<sup>5</sup>

<sup>1</sup>Private Practitioner, Jalandhar, Punjab, India, <sup>2</sup>Private Practitioner, Malerkotla, Punjab, India, <sup>3</sup>Senior Lecturer, Department of Public Health Dentistry, ITS Dental College, Ghaziabad, Uttar Pradesh, India, <sup>4</sup>Post-graduate Student, Department of Conservative Dentistry & Endodontics, Manav Rachna Dental College, Faridabad, Haryana, India, <sup>5</sup>Private Practitioner, Delhi, India

## Abstract

Dental implants are becoming a more common treatment option nowadays with a large number of patients opting for this treatment option. For a good prognosis of implant treatment, proper implant placement is the major criteria. To establish a logical continuity between diagnosis, prosthetic planning and surgical phases, use of transfer device is essential. To increase the precision of implant placement, use of surgical guides had been suggested by various authors. Accurate pre-surgical planning taking into account anatomical limitations and prosthetic demands is mandatory to ensure a predictable treatment, without incurring possible intra- and post-operative complications. This article reviews the ideal requisites of a surgical guide along with basic methods of surgical guide fabrication and certain common recent advances in this field.

**Key words:** Cone beam computed tomography, Implants, NobelGuide, Stereolithography, Surgical template

## INTRODUCTION

The protocol for a successful implant is one that demonstrates osseointegration, as well as optimal position of the implant for the fabrication of an esthetic and functional restoration. Ideal placement facilitates the establishment of favorable forces on the implants and prosthetic components while ensuring an esthetic outcome. To increase the predictability of success, it is essential that the implants are placed properly.<sup>1</sup>

To establish a logical continuity between diagnosis, prosthetic planning and surgical phases, use of transfer device is essential. The surgical guide template is fabricated by the restoring dentist after the pre-surgical restorative appointments, the final prosthesis design, optional abutment number and location, occlusal scheme, and implant angulation have been determined.

A surgical guide is “A guide, derived from the diagnostic wax-up, used to assist in the preparation for, and placement of, dental implants. It dictates drilling position and angulation.” A number of types of guides and templates have been described in the literature.<sup>2</sup>

## IDEAL REQUISITES

The surgical guide should accurately translate diagnostic information from pre-surgical diagnostic work-up to direct implant placement in three dimensions (Figure 1):

- Bucco-lingually
- Mesio-distally, and
- Apico-coronally.<sup>2</sup>

The guide should, if possible, be able to carry radiographic markers to provide contrast between the guide and sites selected for implant trajectory to be used in diagnostic imaging. The American Academy of Oral and Maxillofacial Radiology has recommended the use of surgical templates with radiographic markers in conjunction with imaging.

Ideally, the surgical guide should possess the following characteristics:<sup>3</sup>

### Access this article online



www.ijss-sn.com

**Month of Submission** : 12-2015  
**Month of Peer Review** : 01-2016  
**Month of Acceptance** : 01-2016  
**Month of Publishing** : 02-2016

**Corresponding Author:** Dr. Amrita Pawar, 43, Professor Colony, P.O. PAP lines, Jalandhar - 144 006, Punjab, India.  
 Phone: +91-8570984584/9216856050. E-mail: dr.amritapawar@gmail.com

- Simple and cost-effective to fabricate
- Stable retention in surgical field (adjacent teeth or landmark)
- Easy access of drills/guide pins/osteotomes intraoperatively (Figure 2)
- Ability to translate pre-surgical work-up information accurately to operating field.

### Extensions

If the arch treated has remaining teeth, the template should fit over and/or around enough teeth to stabilize and position the guide stent.

When no remaining teeth are present, the template should extend onto unreflected soft tissue regions, that is, the palate and tuberosities in the maxilla, or the retromolar pads in the mandible. In this way, the guide template may be used after the soft tissue has been reflected from the implant site, and during preparation for the implant osteotomy.

### Implant Angulation

The ideal angulation for implant insertion should be visualized during surgery and requires, at least, two reference points for each implant. For that purpose, the surgical guide must be elevated above the edentulous site. The distance between the occlusal surface of the abutment crown and the crest of the ridge represents 8 mm or more. As a result, these two points of reference correspond to the path of ideal implant insertion. The ideal angulation is perpendicular to the occlusal plane and parallel to the most anterior abutment joined to the implant.

### Gingival Contouring

The surgical template should relate the ideal gingival contour position. Lost bone and gingival width may be replaced during implant insertion by an onlay graft of dense hydroxyapatite and demineralized freeze-dried bone. The amount of augmentation required to support the tissue can be determined by the surgical template.

### Construction of Surgical Templates

The easiest method to construct the implant surgical template is to use a modification of Preston's clear splint for the diagnosis of tooth contours, tooth position, and occlusal form (Figure 3). The diagnostic wax-cast is completed to determine tooth size, position, contour, and occlusion in the edentulous regions where implants will be inserted. A full arch irreversible hydrocolloid impression is made and poured in dental stone. On the duplicate cast of the wax-up teeth, a vacuum acrylic shell is pressed and trimmed to fit over the teeth and gingiva contours of the buccal aspect of the ridge. If no natural teeth remain, the posterior

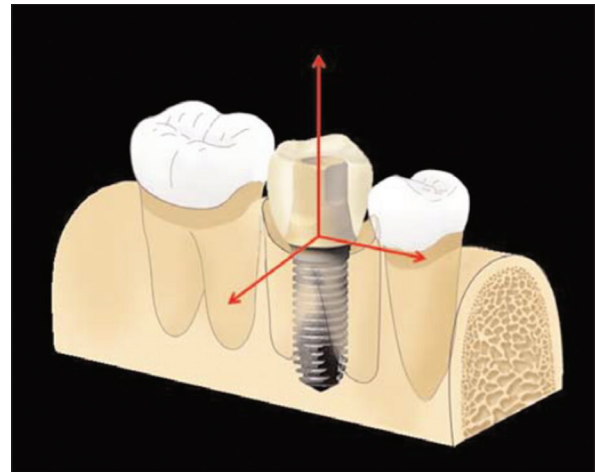


Figure 1: An ideal surgical guide should facilitate placement of a dental implant in the optimal bucco-lingual, mesio-distal, and apico-coronal dimension

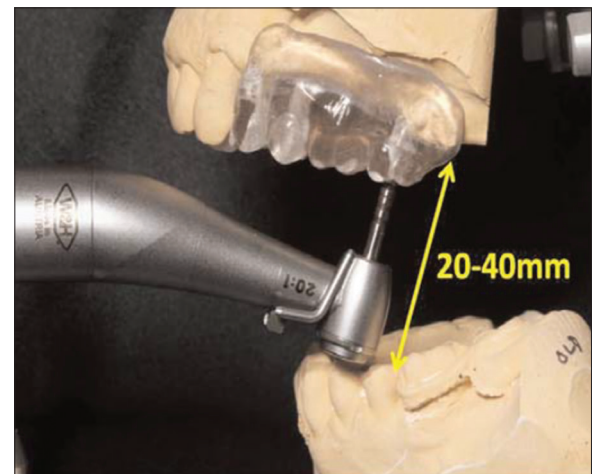

Figure 2: A surgical guide should have easy access to drills, osteotomes, and other devices commonly used during implant surgery

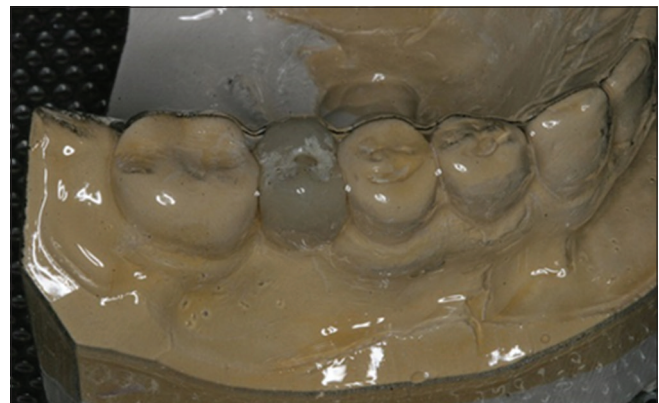

Figure 3: Clear vacuum shell adapted over diagnostic wax up duplicate cast

portion of the template should be maintained and cover the retromolar pads or tuberosities to aid in positioning.

The occlusal acrylic is removed over the ideal and optional implant sites, maintaining the facial and facio-occlusal line angle of the surgical template. This provides maximum freedom for implant placement, yet communicates the ideal tooth position and angulation during surgery. In the edentulous arch, the vacuum form may be of the existing removable prosthesis, if within accepted guidelines.<sup>4</sup>

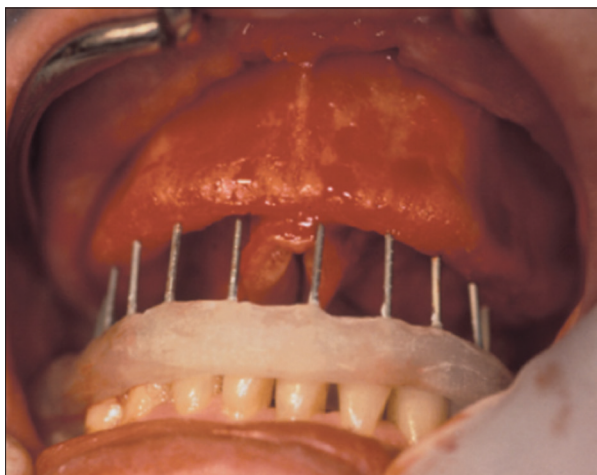
The surgical template for complete denture engaging occlusal aspect of opposing arch (Laney Poitras Template) contains an acrylic stent on the opposing arch with projecting orthodontic wires at the desired implant sites.

This allows each pin of the template to contact bone, once the tissue is reflected during surgery, without modifying the occlusal vertical dimension and consequently the emergence position of the implant. The wire should approach within 1-3 mm of opposing arch.

Once the soft tissue is reflected the template is positioned over teeth of the opposing arch. The patient may occlude on pins and each one determines the ideal center position of teeth. A pilot drill can be used to mark each implant body positions (Figure 4).<sup>4</sup>

#### Advantages

- Angulation of the osteotomy can also be determined
- Easily determines the implant position yet surgeon can have complete access and vision
- Template may also be used with osteoprotegrin before surgery
- Can also be used for second stage surgery to determine the exact position of implants for conservative soft tissue reflection.



**Figure 4:** Once the tissues are reflected, the template is seated on the opposing arch and indicates the position and angulation of each implant

## RECENT ADVANCES

### Computer-Aided Design (CAD)/Computer-Aided Manufacturing (CAM) Surgical Guides

Treatment planning decisions made with CAD can be easily transferred to the surgical treatment phase, be performed, in turn, with CAM. CAD can be conducted through reading and interpreting multiplanar computerized tomography (CT) scans or cone beam CT (CBCT), performing measurements, and evaluating anatomic relationship by placing virtual images on the screen. In the CAM process, stereolithography method can be used for the fabrication of three-dimensional (3D) surgical templates. The method includes a laser beam traveling above the photosensitive liquid acrylic, allowing the surgical template to be polymerized in the layers according to the design. Then, stainless steel tubes are inserted in the spaces that represent implant location. After insertion the tubes, the surgical template is ready for use. Thus, CAD/CAM surgical templates allow the software-based planning to transfer to the surgical field.<sup>5</sup>

Nokar *et al.* investigated the accuracy of implant placement using a CAD/CAM surgical guide by means of an *in vitro* study. The results showed that the average differences between the planned and actual entry points in the mesiodistal and buccolingual directions, lengths, and angles of the implants and the osteotomy showed a considerable reduction in the CAD/CAM group versus the conventional group and it was concluded that accuracy of implant placement was improved using an innovative CAD/CAM surgical template.<sup>6</sup>

### Stereolithography

Once CT scan data are segmented, the software interpolates the data on all three planes to form a smooth 3D model. A computer file of this model can be alternatively transferred to stereolithography equipment where a physical model of the patient's bone structure is created. The finalized treatment plan is thus used for fabrication of a surgical template using this technique.

In oral implantology, this technology develops a precise evaluation of anatomic points such as the size of the maxillary sinus in the upper jaw and the location of the alveolar nerve in the lower jaw. It also provides information about size, direction, and bone location for accurate positioning of implants.<sup>5</sup>

Using this technique, surgical procedure would be simplified, reliable, and easily reproducible. Wound size and bone surface exposure would be minimal and no soft tissue trauma would be derived by use of burrs during bone drilling. Furthermore, during the operative procedure,

there will no major problems of bleeding or nerve lesion. The post-operative time would be without complications.

This technique offers many advantages which include:

- Correct management of the tissues with minimal trauma and a superior planned treatment
- In cases of severe atrophy, this methodology allows fixture measurements by the indication of exact surgical limitations and prevents complications related to poor stability of a denture.

## DRAWBACKS

The main drawback of the surgical template can be seen in the possible movement of the template during surgery and reproducibility of the splint position between the CT exam and surgical procedure.

The degree of the difference between the proposed and actual implant direction may be influenced by various factors, such as the construction accuracy of the template, the surgical accuracy using these templates, the accuracy of the study model, the accuracy of the stereolithographic machines and the measurement accuracy.

The CT scan involves a higher dose/higher cost method. However, the CT scan is less time consuming when multiple implants are required, and it allows imaging of the entire jaw, making it possible to use software for virtual implant placement. As long as radiographic imaging has been enhanced by the development of various techniques, multi-slice, and spiral CT are being replaced by CBCT systems for oral and maxillofacial imaging, enabling a significant reduction dose (Loubele *et al.*, 2008).

## NOBELGUIDE COMPUTERIZED SURGICAL TEMPLATE SYSTEM

Nobel Biocare's NobelGuide is a planning and surgical concept that allows dentists to place implants in a single visit so that the patient leaves the office with a fully functioning tooth or teeth. NobelGuide uses Nobel Biocare's Procera® surgical planning software and flapless surgery, alternatively described as "keyhole surgery." Using Procera software, dentists can plan complete implant treatment, including number, length, and angulation. CT or a plaster model taken of the patient's teeth and mouth provide the basis for determining the bone's shape and location. Planning data allow Nobel Biocare or a dental laboratory to create a surgical template permitting less invasive, flapless surgery. The surgical template, secured over the patient's soft tissue, allows the dentist to drill directly into the bone through the soft tissue through guide holes.

NobelGuide allows the simultaneous placement of implant, abutment, and restorative crown or bridge; furthermore, conventional or computer aided-3D design can be used to construct the surgical template for placing implants in the exact position and depth needed for completion of the restorative plan.<sup>7</sup>

## CONCLUSION

In a research to determine the "Effect of Surgical Guide Design and Surgeon's Experience on the Accuracy of Implant Placement," it was found that surgical guide design, surgeon's experience, and size of the edentulous site all statistically significantly affect the accuracy of implant placement. An angulation error in the buccal-lingual direction was shown to be less likely to occur in the experienced group.<sup>8</sup> An electronic and hand search of the literature revealed three categories, namely, non-limiting, partially limiting, and completely limiting design. Most clinicians still adopt the partially limiting design due to its cost-effectiveness and credibility. Moreover, clinicians use cross-sectional imaging during the pre-implant assessment of surgical sites.<sup>9</sup> Precision has been improved and uncertainty, and surgical time have been reduced with the use surgical templates, thus addressing complex rehabilitation with greater confidence. A study was done to determine the accuracy of computer-aided template-guided oral implant placement and it was concluded that computer-aided flapless implant surgery seemed to provide several advantages to the clinicians as compared to the standard procedure; however, linear and angular deviations are to be expected. Therefore, accurate pre-surgical planning taking into account anatomical limitations and prosthetic demands is mandatory to ensure a predictable treatment, without incurring possible intra- and post-operative complications.<sup>10</sup> In addition, predictable positioning allows for the better prosthetic outcome by simplifying abutment selection and avoiding complex laboratory fabrication when misalignment must be corrected.

## REFERENCES

1. Arlin ML. Dental implants and the partially edentulous patient. *Periodontics* 1989;79:19-21.
2. Kim JY. The implant positioning guide and stent: Part I. *Dent Implantol* 2009;20:73-80.
3. Kim JY. The implant surgical guide: Practical and innovative designs and approaches. *Dent Implantol* 2009;20:73-80.
4. Misch CE. *Diagnostic casts and surgical guides. Contemporary Implant Dentistry*. 3<sup>rd</sup> ed., Ch. 10. Missouri: Elsevier, Mosby; 2008. p. 142-56.
5. Moslehifard E. *Computer Aided Techniques Developed for Diagnosis and Treatment Planning in Implantology*. Available from: <http://www.intechopen.com>. [Last accessed on 2015 Nov 19].
6. Nokar S, Moslehifard E, Bahman T, Bayanzadeh M, Nasirpour F, Nokar A. Accuracy of implant placement using a CAD/CAM surgical guide: An *in vitro* study. *Int J Oral Maxillofac Implants* 2011;26:520-6.

Pawar, *et al.*: A Step toward Precision: A Review on Surgical Guide Templates for Dental Implants

7. Garg AK. Implant surgical templates in implant dentistry: Nobel Guide™. *Dent Implantol* 2007;18:25-8.
8. Hinckfuss S, Conrad HJ, Lin L, Lunas S, Seong WJ. Effect of surgical guide design and surgeon's experience on the accuracy of implant placement. *J Oral Implants* 2012;38:311-23.
9. D'Souza KM, Aras MA. Types of implant surgical guides in dentistry: A review. *J Oral Implantol* 2012;38:643-52.
10. Beretta M, Poli PP, Maiorana C. Accuracy of computer-aided template-guided oral implant placement: A prospective clinical study. *J Periodontal Implant Sci* 2014;44:184-93.

**How to cite this article:** Pawar A, Mittal S, Singh RP, Bakshi R, Sehgal V. A Step towards Precision: A Review on Surgical Guide Templates for Dental Implants. *Int J Sci Stud* 2016;3(11):262-266.

**Source of Support:** Nil, **Conflict of Interest:** None declared.