International Journal of Scientific Study

General Information

About The Journal

International Journal of Scientific Study (IJSS) is a monthly journal publishing research articles after full peer review and aims to publish scientifically sound research articles in across all science like Medicine, Dentistry, Genetics, Pharmacy, etc.

Each article submitted to us would be undergoing review in three stages: Initial Review, Peer Review & Final Review.

Abstracting & Indexing Information

PubMed - Selected Citations (As Mentioned on National Library of Medicine Catalog Website) - www.ncbi.nlm.nih.gov/nlmcatalog/101729001, Index Medicus (IMSEAR), Global Index Medicus, Google Scholar, WorldCat, SafetyLit, Genamics Journal Seek Ulrichsweb Serials Solutions, International Committee of Medical Journal Editors (ICJME) Geneva Foundation for Medical Education & Research (GFMER), Socolar, Bielefeld Academic Search Engine (BASE), Research Bible, Academic Journals Database, J-Gate, Jour Informatics, Directory of Research Journal Indexing (DRJI), Scientific Indexing Services (SIS) Rubriq-Beta, SHERPA RoMEO, New Journal (EIJASR), IndianScience.in, CiteFactor, Scientific Journal Impact Factor (SJIF), Journal Index.net, ROAD, Global Impact Factor (GIF), International Society for Research Activity (ISRA), Advanced Science Index (ASI)

Information for Authors

The authors should follow "Instructions to Authors" which is available on website http://www.ijss-sn.com/instructions-to-authors.html. Authors should fill the Copyright Transfer form & Conflict of Interest form. Manuscripts should be submitted directly to: editor@ijss-sn.com.

Publication Charges

International Journal of Scientific Study aims to encourage research among all the students, professionals, etc. But due to costs towards article processing, maintenance of paper in secured data storage system, databases and other financial constraints, authors are required to pay. However discount will be provided for the non-funding quality research work upon request. Details about publication charges are mentioned on journal website at: http://www.ijss-sn.com/publication-charges.html.

Advertising Policy

The journal accepts display and classified advertising Frequency discounts and special positions are available. Inquiries about advertising should be sent to editor@ijss-sn.com.

Publishing Details

Publisher Name: International Research Organization for Life & Health Sciences (IROLHS)

Registered Office: L 214, Mega Center, Magarpatta, Pune - Solapur Road, Pune, Maharashtra, India – 411028. Contact Number: +919759370871.

Designed by: Sinjore Technologies (www.sinjore.com)

Disclaimer

International Journal of Scientific Study

Editorial Board

International Journal of Scientific Study
January 2022 • Vol 9 • Issue 10

Contents

CASE REPORTS

Plasma Cell Gingivitis: A Case Report
Shweta S Bhole, Pramod Waghmare, Rinisha Sinha, Shashwat R Thombare 1

Deformity Correction in a Patient of Osteofibrous Dysplasia of Tibia using Avascular Fibular Strut Graft as Intramedullary Nail – A Case Report
Neetin P Mahajan, Tushar C Patil, Sunny Sangma, Ravi Dadhaniya 4

Bilateral, Congenital Isolated Aniridia in a Child: A Case Report
Subhamita Guha, Reena Kumari, Dinesh Kumar Bhagat, Sumit Randhir Singh 8

Surgical Challenges in the Management of Unusual Splenic Pathology - A Case Series
Shrenik Govindaraj, Sridar Govindaraj, T J Clement Prakash 11

CASE SERIES

Taurodontism: A Rare Dental Anomaly - A Brief Review
B Sivasaranya, S Sankarakrishnan, R Sridharan, S Arunpriyatharsini 18

REVIEW ARTICLE

A Comparative Safety Assessment of Levosalbutamol and Salbutamol, with the Conventional Drug Delivery System, Metered-Dose Inhaler, in Mild Asthma; with a Pharmacovigilance Monologue
Moumita Hazra 22

ORIGINAL ARTICLES

Comparative Evaluation of Pushout Bond Strength of Biodentine after Root Dentin Conditioning with Different Irrigating Solutions- An *In Vitro* Study
Pooja Gandhe, Ashwini Gaikwad, Varsha Pandit, Anandita Sengupta, Pruthviraj Deshmukh 28

Role of Sliding Transposition Flap in Coverage of Soft Tissue Defects of Leg: An Experience of 50 Cases
Sharma Samira, Bhandari Mrinal, Gupta Arshiya 33

Comparative Study of the Influence of Instrument Taper on the Fracture Resistance of Endodontically Treated Teeth Using Hand and Rotary Files
Anandita Sengupta, Varsha Pandit, Ashwini Gaikwad, Pooja Gandhe 37

International Journal of Scientific Study

January 2022 • Vol 9 • Issue 10

Comparative Evaluation of Remineralization Potential and pH Change of GC Tooth Mousse Plus and Alcoholic Extract of Cocoa Powder, and Antibacterial Efficacy against *Streptococcus mutans*: An *In Vitro* Study
Mayuri M. Tawde, Laxmi S. Lakade, Rohan Shah, Sneha Desai, Shweta Jajoo, Preetam Shah 43

Effect of Hypertension on Sensory Nerve Conduction Variables
Barkha Rani, Anand Kumar Singh 50

Chronic Urticaria and Subclinical Hypothyroidism: A Cross-sectional Study
J Kavitha, Vineela Rani Chowdary, Md. Dawood Sulemani 54

Role of Inflammatory Markers in the Severity and Outcome in Patients with COVID-19 Infection
Manasa A S Gowda, K Smruthi, T A Shilpa 59

Reproductive Morbidity in Adolescents: A Case-control Study in the Central India
Meeta Banerjee, G K Banerjee 63

Comparison of Efficacy of Intrathecal 2-Chloroprocaine and 2-Chloroprocaine with Fentanyl in Perianal Surgery: A Randomized Control Study
S Arivazhagan, T Padma Rubini, V Thiruchelvan 69

Role of Computed Tomography in Assessing Anatomical Variants of Nasal Cavity and Paranasal Sinuses in Chronic Sinusitis
A Aravindhan, M Annas, N Thamarai Selvi, A P Jaya Iswarya 75

Echocardiographic Evaluation of Asymptomatic Type 2 Diabetes Mellitus Patients for Cardiovascular Disease in a Tertiary Care Hospital
Parimal Sarkar, B Khaham Debbarma 80

Diagnostic Accuracy of Hounsfield Unit on Non Contrast Computed Tomography in Predicting Chemical Composition of Urinary Calculi
Padma V Badhe, Sanika Patil, Jagneet S Chatha, K N Puneethkumar 88

Study of Silodosin, Darifenacin, and Combination Therapy for the Treatment of Ureteral Stent-Related Discomfort
G. Latha 95

Print ISSN: 2321-6379
Online ISSN: 2321-595X

Case Report

Plasma Cell Gingivitis: A Case Report

Shweta S Bhole[1], Pramod Waghmare[2], Rinisha Sinha[3], Shashwat R Thombare[1]

[1]3rd Year Post Graduate Student, Department of Periodontology, Bharati Vidyapeeth (Deemed to be) University Dental College and Hospital, Pune, Maharashtra, India, [2]Associate Professor, Department of Periodontology, Bharati Vidyapeeth (Deemed to be) University Dental College and Hospital, Pune, Maharashtra, India, [3]2nd Year Post Graduate Student, Department of Periodontology, Bharati Vidyapeeth (Deemed to be) University Dental College and Hospital, Pune, Maharashtra, India

Abstract

The aim of the article is to present a report on the rare gingival condition called plasma cell gingivitis (PCG) which is a benign condition of gingiva usually characterized by sharply demarcated erythematous and edematous gingival lesion. It is said to be a hypersensitivity reaction to some antigens. This article presents a case of PCG in a 65-year-old female patient with an unknown cause, diagnosed by histopathological examination of the excised gingival tissue and its management by surgical interventions.

Key words: Antibiotics, External bevel gingivectomy, Gingival lesion, Hypersensitivity, Plasma cell gingivitis

INTRODUCTION

Plasma cell gingivitis (PCG) is known as a benign inflammatory condition of the gingiva. It is characterized by sharply demarcated erythematous and edematous gingivitis often extending to the mucogingival junction.[1,2] PCG is considered as a hypersensitive reaction to some antigen.[1] Some common allergens previously attributed are chewing gums, certain components of toothpaste, cinnamon, mint, and red pepper. This condition has been classified into three categories based on its etiology which is due to allergens, neoplastic origin, and unknown origin.[1,2] However, the allergen in most cases is unknown, despite extensive allergy testing.

The other names of the conditions are idiopathic gingivostomatitis, atypical gingivostomatitis, plasmacytosis of gingiva, and allergic gingivostomatitis.[3] Clinically, the lesion can be seen as diffuse gingival erythema with edematous smooth swelling, which is shiny and sometimes velvety in texture involving free gingiva and attached gingiva. The lesion usually shows a sharp demarcation often extending to the mucogingival border.[4,5] The diagnosis requires hematological screening in addition to clinical and histopathological examination. Histopathological features of PCG show dense infiltration of plasma cells in the subepithelial layer that results in a disruption of the basement membrane and dilated capillaries.[6] Hematological examination is necessary in order to investigate other serious plasma cell lesions, including multiple myeloma or solitary plasmacytoma since the histopathological changes of PCG mimic those lesions.[4] The differential diagnosis includes lesions that possess similar clinical characteristics like mucous membrane pemphigoid, pemphigus vulgaris, HIV gingivitis, and leukemia. Here, we present a rare case report of PCG with a cause of unknown origin.

Access this article online

IJSS

www.ijss-sn.com

Month of Submission : 11-2021
Month of Peer Review : 12-2021
Month of Acceptance : 12-2021
Month of Publishing : 01-2022

CASE DESCRIPTION

A 65-year-old female patient presented to the Department of Periodontics, Bharati Vidyapeeth Deemed to be University, Pune, Maharashtra with the chief complaint of pain, swelling, and bleeding from gums in right and left upper and lower teeth region for 1 year. She also revealed a history of bleeding on slight provocation. Her medical, dental, and personal history were noncontributory. No history of any allergy or any abnormalities was detected in her general physical examination but her submandibular and sublingual lymph nodes were palpable and tender on both sides.

Clinical examination revealed diffuse gingival enlargement in both the arches which were covered by an erythematous

Corresponding Author: Dr. Shweta S Bhole, Department of Periodontology, Bharati Vidyapeeth (Deemed to be) University Dental College and Hospital, Pune, Maharashtra, India.

epithelium and was hemorrhagic [Figure 1]. The gingiva appeared red, exophytic, and sessile with a broad base with the presence of bleeding on probing.

Routine hematological investigations were found to be normal. An Orthopantomogram showed severe alveolar bone loss everywhere.

Excision of the gingival lesion was done and sent for histological examination. However, the biopsy report revealed the presence of stratified squamous and para-keratinized epithelium which was lymphatic and atrophic at some places. The epithelium exhibited dysplastic features like prominent intercellular bridges, individual cell keratinization, basilar hyperplasia, cellular and nuclear pleomorphism. The connective tissue was dense and fibrous which consisted of collagen fiber bundles interspersed with fibroblasts. Abundant dense inflammatory cell infiltrate chiefly plasma cells which were oval with eccentrically placed hyperchromatic nucleus was noted. A few lymphocytes, macrophages, and foam cells followed by dilated engorged blood vessels and extravasated red blood cells were also noted down. All these features were suggestive of PCG.

The preliminary treatment comprised of oral hygiene instructions followed by scaling and root planning. The patient was advised to use a mouth rinse of 0.2%, 10 ml chlorhexidine gluconate twice daily along with the use of an ultrasoft toothbrush. Patient was recalled after 15 days and slight regression of the lesion was noted down. Insignificant changes in the color of gingiva along with no bleeding on probing and combined pockets were observed on her recall visit at the 15th day. Hence, a surgical approach was planned with gingival lesion and consent was taken. External bevel gingivectomy was done in all sextants followed by antibiotics (Augmentin 625 mg) and analgesics (Ketorol DT) course for 5 days with routine oral hygiene instructions. Post-operative healing was uneventful [Figure 2]. The patient was followed up for 1 year where no recurrence of the lesion was observed.

Figure 1: Preoperative picture of plasma cell gingivitis

Figure 2: Postoperative picture of the case

DISCUSSION

PCG is a peculiar oral lesion related to some allergens. Exact mechanism of the disease is still unknown.[6] The etiology of this condition is not clear but due to the presence of plasma cells, it appears to be an immunological reaction to some allergens. The patient mentioned in this case report revealed no history of allergy which was suggestive of PCG of unknown origin. In this case, patient reported with diffuse reddening of the gingiva with edematous swelling, which was seen to be improved after conventional periodontal therapy. The diagnosis of the lesion was made on the basis of histopathological examination of the excised gingival tissue. Difficulty in distinguishing this condition from exotic plasma cell lesions affecting the gingiva can be observed due to the presence of a large number of plasma cells in the established lesions of chronic inflammatory periodontal disease. These exotic plasma cell lesions include plasmacytosis, plasmacytoma, plasma cell granuloma.[1,7,8] The important management of PCG is to avoid identified allergens. Many studies showed the improvement purely refraining from positive agents and intensive oral hygiene care.[9,10] Combined treatment using Chlorhexidine gluconate mouth rinse was also reported to be effective in the management of PCG.[4,5]

CONCLUSION

It is of utmost importance of recognizing PCG as one of the entities in the differential diagnosis of gingival conditions. This is because the diagnosis of PCG is based on comprehensive history taking, clinical examination, and appropriate diagnostic test. Histopathological examination

is one of the most significant test for differentiating PCG from other similar lesions. Thus, the present case report highlights the diagnosis, clinical features, and management of rare gingival lesion called PCG.

ACKNOWLEDGMENT

We thank the participant who was a part of present study and sincerely acknowledge her efforts in complying with the requirements of the study.

REFERENCES

1. Macleod RI, Ellis JE. Plasma cell gingivitis related to the use of herbal toothpaste. Br Dent J 1989;166:375-6.
2. Gargiulo AV, Ladone JA, Ladone PA, Toto PD. Case report: Plasma cell gingivitis A. CDS Rev 1995;88:22-3.
3. Silverman S Jr., Lozada F. An epilogue to plasma-cell gingivostomatitis (allergic gingivostomatitis). Oral Surg Oral Med Oral Pathol 1977;43:211-7.
4. Mishra MB, Sharma S, Sharma A. Plasma cell gingivitis: An occasional case report. N Y State Dent J 2015;81:57-60.
5. Agarwal S, Chaubey KK, Arora VK, Nirwal A, Thakur R, Madan E. Plasma cell gingivitis-a misnomer or realty. J Adv Res Biosci 2013;6:58-62.
6. Regezi JA, Sciubba JJ, Jordan RC. Oral Pathology: Clinical Pathologic Correlations. 6th ed. St. Louis: Elsevier; 2012.
7. Kerr DA, Clatchy KD, Regezi JA. Idiopathic gingivostomatitis. Cheilitis, glossitis, gingivitis syndrome; atypical gingivostomatitis, plasma-cell gingivitis, plasmacytosis of gingiva. Oral Surg Oral Med Oral Pathol 1971;32:402-23.
8. Palmer RM, Eveson JW. Plasma-cell gingivitis. Oral Surg Oral Med Oral Pathol 1981;51:187-9.
9. Marker P, Krogdahl A. Plasma cell gingivitis apparently related to the use of khat: Report of a case. Br Dent J 2002;192:311-3.
10. Rawal SY, Rawal YB, Anderson KM, Bland PS, Stein SH. Plasma cell gingivitis associated with khat chewing. Perio 2008;5:21-8.

How to cite this article: Bhole SS, Waghmare P, Sinha R, Thombare SR. Plasma Cell Gingivitis: A Case Report. Int J Sci Stud 2022;9(10):1-3.

Source of Support: Nil, **Conflicts of Interest:** None declared.

Print ISSN: 2321-6379
Online ISSN: 2321-595X

Case Report

Deformity Correction in a Patient of Osteofibrous Dysplasia of Tibia using Avascular Fibular Strut Graft as Intramedullary Nail – A Case Report

Neetin P Mahajan[1], Tushar C Patil[2], Sunny Sangma[2], Ravi Dadhaniya[2]

[1]Professor and Unit Head, Department of Orthopaedics, Grant Government Medical College, Mumbai, Maharashtra, India, [2]Junior Resident, Department of Orthopaedics, Grant Government Medical College, Mumbai, Maharashtra, India

Abstract

Introduction: Osteofibrous dysplasia (OFD) is a developmental fibro-osseous rare benign disease, most commonly seen involving diaphysis of tibia and/or fibula of children. OFD lesion shows good prognosis due to benign nature, the majority of lesions ceases to grow after skeletal maturity and is most commonly seen in first decade of life. Initially, lesions were observed and conservatively managed with bracing and splintage, even for severe deformities. However, conservative management was often associated with increased recurrences and stimulate progression of lesion. Complications of extensive excision lead to bone defect. Hence, extensive surgeries are better reserved after skeletal maturity and progressive lesions. Radical extraperiosteal excision with secondary reconstructive surgery is the ideal mode of the treatment and usually does not show any recurrence.

Case Report: Here, we present a rare case of OFD in a 4-year-old female with pain and deformity, after traumatic fall. Diagnosis confirmed on histopathological examination. Patient was treated with local excision and deformity correction using ipsilateral avascular fibular graft and tens nail for additional stability.

Conclusion: OFD is a rare benign bone tumor seen in children which can lead to pain, severe deformity, and fragility fractures which necessitate extraperiosteal surgical excision of the lesion to prevent recurrence. This leads to bone defect that should be managed by reconstructive surgery. Avascular fibular strut graft used as an intramedullary nail provides rigid internal biological stability to fragile tibia of OFD and increased chances of bony union due to osteogenesis of bone in bone fixation which can be aided by tens nail or Kirschner wire with preservation of periosteum.

Key words: Avascular fibular graft, Bone in bone, Deformity correction, Osteofibrous dysplasia, Strut graft

INTRODUCTION

Osteofibrous dysplasia (OFD) is a developmental fibro-osseous rare benign disease, most commonly seen involving diaphysis of tibia and/or fibula of children. Although, OFD has also been documented in radius and ulna.[1] First case of OFD was named as congenital osteitis fibrosa by Frangenheim in 1921. It was termed as OFD of tibia and fibula by Campanacci in 1976 considering its developmental origin, anatomical location, and histological similarity to fibrous dysplasia.[1]

Access this article online

www.ijss-sn.com

Month of Submission : 11-2021
Month of Peer Review : 12-2021
Month of Acceptance : 12-2021
Month of Publishing : 01-2022

OFD lesion shows good prognosis due to benign nature, the majority of lesions ceases to grow after skeletal maturity and is most commonly seen in first decade of life whereas adamantinoma is a biphasic malignant tumor more common in second and third decades of life. OFD comprises of 0.2% of primary benign and adamantinoma consists of 1% of primary malignant bone tumors.[1,2]

There are various modalities of treating bone affected with OFD such as curettage, local excision, or radical excision with reconstructive procedures. Recurrence is seen after incomplete excision while radical excision can lead to pseudarthrosis.[1]

Non-vascularized autogenous bone grafts have been used in limb salvage surgeries involving recalcitrant bone defects after severe trauma, resection of wide spread osteomyelitis, or bone tumor. For the same purpose, fibula because of its corticocancellous structure provides appropriate

Corresponding Author: Dr. Tushar C Patil, Department of Orthopaedics, Grant Government Medical College, Mumbai, Maharashtra, India.

geometrical shape and mechanical strength for large bone defects.[3,4]

CASE REPORT

A 4-year-old female brought by parents to our outpatient department with the right leg pain and swelling since 1 day after history of fall while playing. On clinical examination, she had local tenderness, swelling, and deformity of the right distal third leg. On X-rays, she had old distal third tibia shaft fracture with anterior tibial bowing as seen in Figure 1. Her parents gave history of similar episode in past for which she was managed conservatively with above knee slab from a private practitioner. On 3D computed tomography (CT) and magnetic resonance imaging (MRI) scans, eccentric lytic bony lesion with surrounding sclerosis in proximal and distal third tibia is seen in Figure 2. Based on clinical symptoms and extent of lesion, patient was planned for excision of lesion and deformity correction with intramedullary avascular fibular graft.

Surgical Procedure

Anteromedial incision was taken over distal third tibia. Exicison of OFD lesion is done. The varus deformity is corrected with wedges osteotomy, followed by reaming of medullary canal of proximal and distal tibial fragments with solid reamers. Avascular fibular graft was obtained subperiosteally, preserving proximal and distal 5 cm of intact fibula. Immediately, insertion of avascular fibular strut graft in proximal tibial fragment performed as intramedullary nail and fracture site approximated followed by gradual advancement of fibular graft into distal tibial fragment using bone clamp. A 1.5 mm tens nail inserted in retrograde fashion for additional stability. Fibular periosteum sutured water tight, followed by closure of tibial wound as shown in Figure 3.

Immediate post-operative X-rays are shown in Figure 4. Diagnosis of OFD was confirmed on histopathological examination of intra-operative samples as seen in Figure 5.

Figure 1: Pre-operative clinical pictures and X-rays of the right leg showing anterior tibial bowing deformity

Figure 2: Pre-operative magnetic resonance imaging and 3D computed tomography cuts showing lesions of osteofibrous dysplasia affecting right proximal and distal third tibia

DISCUSSION

OFD usually has a self-limiting course which starts in early childhood with little male preponderance, progresses up to 10 years of age, and stabilizes up to 15 years of age. The OFD lesion usually involves anterior tibial cortices and subsequent anterior tibial bowing as most common presentation.[5,6] Age of patient, location of lesion, radiographic features, and clinical presentation distinguish OFD from fibrous dysplasia.[1]

In some cases, these OFD lesions can progress to adamantinoma which is a low-grade malignancy occurring primarily in tibia of young adolescents. Springfield *et al.* coined the term OFD like adamantinoma for an intermediate progressive lesion. Except slight variation in patient age, there is no clear distinguishing feature between OFD and adamantinoma as both have similar histological and radiographic findings. Hazelbag *et al.* have even suggested OFD to be precursor of adamantinoma showing isolated keratin positive cells with a distinct fibroblastic epithelial hybrid phenotype.[1,2,7]

Figure 3: Intra-operative clinical pictures showing anteromedial tibial incision, anterior tibial deformity, deformity correction after wedge osteotomy, subperiosteal resection of ipsilateral avascular fibular graft, insertion of fibular strut graft inside proximal tibial fragment after reaming, approximation of two tibial segments, and suturing of periosteum of fibula

Figure 4: Immediate post-operative X-rays showing deformity correction with intramedullary avascular fibular strut graft and tens nail

Diagnosis is made on X-rays and confirmed on histopathological examination. CT and MRI scans provide better extent of the lesion. On plain radiographs, OFD in tibia is seen as multilocular, eccentric expansile lytic lesion surrounded by a zone of sclerosis with ballooning of anterior cortex. On histopathological examination, OFD shows spicules of bony trabeculae with characteristic osteoblastic rimming over storiform loose fibrous background. It has a zonal spread of immature woven bony trabeculae at the center to more mature woven bony trabeculae as we move to periphery.[6]

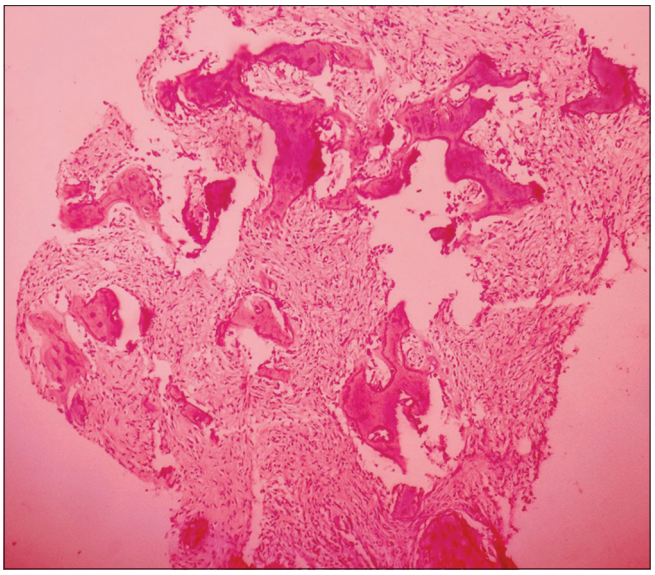

Figure 5: Histopathological slide showing spicules of bony trabeculae with characteristic osteoblastic rimming over storiform loose fibrous background

OFD like adamantinoma can be better diagnosed with open biopsy rather than needle biopsy as small sparse clusters of epithelial cells surrounded by spindle cell osteofibrous component which are pathognomonic can be detected more accurately in open biopsy. Severe pain around the lesion can also suggest progression of OFD to OFD like adamantinoma in 80% of cases.[5]

Initially, lesions were observed and conservatively managed with bracing and splintage, even for severe deformities. However, conservative management was often associated with increased recurrences and stimulates progression of lesion. Complications of extensive excision lead to bone defect. Hence, extensive surgeries are better reserved after skeletal maturity and progressive lesions. Radical extraperiosteal excision with secondary reconstructive surgery is the ideal mode of the treatment and usually does not show any recurrence.[7]

Debilitating pain, repeated pathological fractures, gross deformity, and increasing tumor mass necessitate surgical management to achieve good functional outcome and mobility.[1]

Allografts or autografts, vascularized fibular grafts, extracorporeal avascular fibular grafts, segmental bone

transport, and segmental endoprosthesis are some of the reconstructive procedures which are performed alone or in conjunction after radical excision of the lesion.[5]

Radical excision of tumor with partial preservation of cortex ensures better prognosis of the following reconstructive procedure.[5] Vascularized fibular grafts have been shown to achieve higher bony union rates but it also carries a burden of donor site complications and decreased ankle function. Both avascular and vascularized fibular graft show similar graft hypertrophy at long-term follow-up. Avascular fibular grafts carry the advantage of being simple, less expensive, and short operating time and allow full remodeling of fibula at donor site. Stress fracture and valgus deformity are some documented complications.[3,4]

Optimum reaming the medullary canal of tibia adequate enough for snug fitting of triflanged fibula increases endosteal circulation which aides bone in bone osteogenesis of fibula as intramedullary nail increasing the chances of direct bony union with periosteum preservation.[8]

CONCLUSION

OFD is a rare benign bone tumor seen in children which can lead to pain, severe deformity, and fragility fractures which necessitate extraperiosteal surgical excision of the lesion to prevent recurrence. This leads to bone defect that should be managed by reconstructive surgery. Avascular fibular strut graft used as an intramedullary nail provides rigid internal biological stability to fragile tibia of OFD and increased chances of bony union due to osteogenesis of bone in bone fixation which can be aided by tens nail or Kirschner wire with preservation of periosteum.

REFERENCES

1. Park JW, Lee C, Han I, Cho HS, Kim HS. Optimal treatment of osteofibrous dysplasia of the tibia. J Pediatr Orthop 2018;38:e404-10.
2. Scholfield DW, Sadozai Z, Ghali C, Sumathi V, Douis H, Gaston L, *et al*. Does osteofibrous dysplasia progress to adamantinoma and how should they be treated? Bone Joint J 2017;99:409-16.
3. Liu S, Tao S, Tan J, Hu X, Liu H, Li Z. Long-term follow-up of fibular graft for the reconstruction of bone defects. Medicine 2018;97:e12605.
4. Sharma VS, Joshi N, Dhukia R, Shekhawat V. Comparision of non-vascularized fibular graft as an intramedullary strut v/s conventional bone grafting for management of nonunion of long bones. Int J Orthop 2021;7:691-702.
5. Yamamura Y, Emori M, Takahashi N, Chiba M, Shimizu J, Murahashi Y, *et al*. Osteofibrous dysplasia-like adamantinoma treated via intercalary segmental resection with partial cortex preservation using pedicled vascularized fibula graft: A case report. World J Surg Oncol 2020;18:1-6.
6. Abraham VT, Marimuthu C, Subbaraj R, Rengarajan N. Osteofibrous dysplasia managed with extraperiosteal excision, autologous free fibular graft and bone graft substitute. J Orthop Case Rep 2015;5:41.
7. Lee RS, Weitzel S, Eastwood DM, Monsell F, Pringle J, Cannon SR, *et al*. Osteofibrous dysplasia of the tibia: Is there a need for a radical surgical approach? J Bone Joint Surg Br 2006;88:658-64.
8. Yadav SS. The use of a free fibular strut as a "biological intramedullary nail" for the treatment of complex nonunion of long bones. JB JS Open Access 2018;3:e0050.

How to cite this article: Mahajan NP, Patil TC, Sangma S, Dadhaniya R. Deformity Correction in a Patient of Osteofibrous Dysplasia of Tibia using Avascular Fibular Strut Graft as Intramedullary Nail – A Case Report. Int J Sci Stud 2022;9(10):4-7.

Source of Support: Nil, **Conflicts of Interest:** None declared.

Print ISSN: 2321-6379
Online ISSN: 2321-595X

Case Report

Bilateral, Congenital Isolated Aniridia in a Child: A Case Report

Subhamita Guha, Reena Kumari, Dinesh Kumar Bhagat, Sumit Randhir Singh

Senior Resident, Department of Ophthalmology, Mata Gujri Memorial Medical College and LSK Hospital, Kishanganj, Bihar, India

Abstract

Congenital aniridia is a rare genetic disorder due to PAX6 gene mutation primarily characterized by partial or complete absence of iris, associated with panocular defects. Here, we report a case of congenital, isolated bilateral aniridia with an affected parent. Our index case was a 7-year-old girl having diminution of vision since birth. We performed a through clinical examination; slit lamp biomicroscopy, gonioscopy, and fundus examination, apart from screening of her parents which revealed similar disease pattern in her father. The patient had no ocular and systemic complications; henceforth, she was treated conservatively for visual rehabilitation with best corrected visual acuity of 6/24 in both eyes.

Key words: Aniridia-associated keratopathy, Congenital aniridia, Ultrasound B scan

INTRODUCTION

Aniridia is a rare bilateral genetic disorder having a spectrum of ophthalmologic abnormalities.[4] Aniridia may further be subdivided into two broad categories congenital or acquired (post trauma and surgery). Majority (around 2/3rd) of the cases of congenital aniridia are familial with autosomal dominant pattern of inheritance with complete penetrance but variable severity.[1,5] People with familial aniridia, mainly display isolated ocular defects. Rest of the cases (1/3rd of the cases) are sporadic with ocular as well as systemic findings.[1] Visual acuity is highly variable in these patients, but the presence of nystagmus generally worsen the quality of vision.[5] Patients with aniridia mainly complaints of photophobia and glare.[6] Mainstay of treatment is conservative management, that is, maintenance of best corrected visual acuity by correction of refractive error.[5]

CASE REPORT

A 7-year-old girl presented in the eye clinic with chief complaints of painless diminution of vision associated with photophobia and glare since birth. There was no history of trauma, drug intake, and no significant past medical history. Her father had severe visual impairment in both eyes, mother had no complaints regarding her vision. Our case of interest had no siblings. Her uncorrected Snellen visual acuity was 4/60 in both eyes, with jerky horizontal nystagmus. Slit lamp examination revealed bilateral total aniridia (360°) with normal anterior chamber depth. In both eyes, there was subluxation of clear crystalline lens upward, and no zonules inferiorly lead to straightening of inferior lens margin mimicking lens coloboma [Figure 1]. Intraocular pressure (IOP) measured by applanation tonometry was 14 mm Hg and 16 mm Hg for the right and left eyes, respectively. Gonioscopy examination revealed open angles with rudimentary iris frill present in 360° [Figure 1]. Bilateral fundus evaluation done by indirect ophthalmoscopy showed mild optic disc hypoplasia at inferior disc margin.

Biometry		
Parameter	**Right eye**	**Left eye**
Axial length	20.78 mm	21.00 mm
AC depth	2.19 mm	2.47 mm
Lens thickness	3.90 mm	3.85 mm
K1	42.25 D	41.00 D
K2	44.75 D	43.00 D
Axis	9°	168°

A thorough pediatric evaluation was done to rule out any systemic associations and the findings are listed below:

Access this article online

www.ijss-sn.com

Month of Submission : 11-2021
Month of Peer Review : 12-2021
Month of Acceptance : 12-2021
Month of Publishing : 01-2022

Corresponding Author: Sumit Randhir Singh, Department of Ophthalmology, Mata Gujri Memorial Medical College and LSK Hospital, Kishanganj, Bihar, India.

Parameter	Finding in our subject	Expected at this age of 7 years
Height	110 cm	119 cm
Weight	16 kg	20 kg
Head circumference	46.5 cm	51 cm
Chest circumference	52 cm	66.71 cm
Upper segment: Lower segment (US: LS ratio)	0.8: 1 (56/63)	1.1: 1

Arm span–111 cm, body mass index–13 (underweight). Therefore, she had stunted growth [Figure 2].

No other systemic abnormalities were detected. Since she had subluxation of lens, Marfan's syndrome was ruled out by lower arm span: Height ratio = 1.009 compared to >1.5 seen in Marfan's syndrome. Thumb sign, wrist sign was negative, with no pectus excavatum or scoliosis.

Systemic examination including hemogram, blood coagulation profile, and serum calcium was within normal limits. Serum homocysteine level was normal and urine sodium nitroprusside test was negative. Electrocardiography and 2-D echocardiogram were unremarkable.

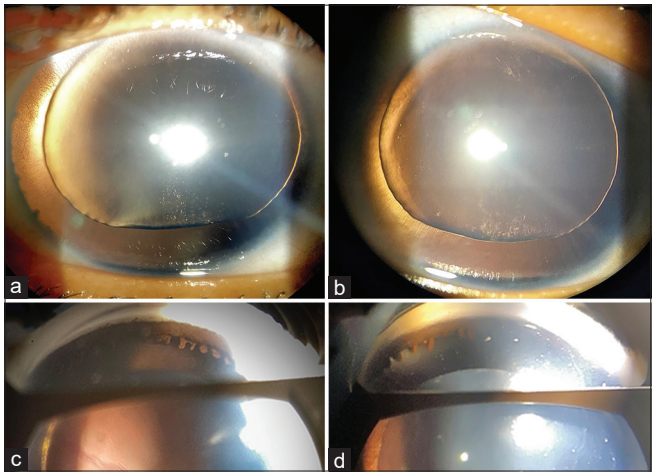

Figure 1: Slit lamp photography of the right (a) and left eye (b) showing aniridia with straightening of inferior lens margin due to absence of zonules inferiorly. Gonioscopy showing rudimentary iris frill in the right (c) and left eye (d), respectively

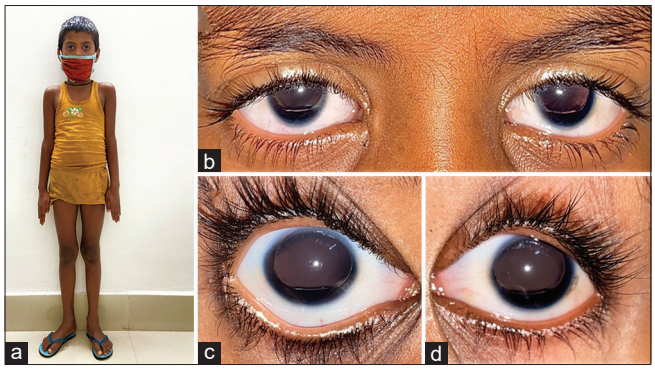

Figure 2: Clinical photograph (a) and facial profile (b) of a 7-year-old girl with clinical aniridia in the right (c) and left eye (d), respectively

Screening of parents was also done, keeping in mind the autosomal inheritance pattern of isolated aniridia. Subject's father had gross visual impairment in both eyes with no perception of light in the right eye and perception of light with accurate projection of rays in the left eye associated with bilateral horizontal jerky nystagmus, and conjunctival xerosis. In the right eye, he had history of vegetative matter trauma 2 years back leading to fungal corneal ulcer, which lead to central leukoma formation with peripheral scarring and corneal vascularization, iris details could not be seen [Figure 3]. In the left eye, there was diffuse corneal opacity associated with scarring of central and inferior cornea suggestive of Aniridia-associated keratopathy (AAK) due to limbal stem cell deficiency, and superiorly rudimentary iris was visible. The presence of ciliary staphyloma was also noted in the left eye [Figure 3]. IOP measurement revealed hypotony in the right eye, and high IOP 24 mm hg in the left eye. Ultrasound B scan showed choroid-scleral thickening, reduced axial length leading to pre-phthisical state in the right eye and posterior vitreous detachment with the low reflectivity vitreous echoes in the left eye [Figure 4]. He was under treatment for bilateral AAK and secondary glaucoma in the left eye for the past 2 years.

Our patient was prescribed glasses (right eye - 2.5 dS/-4.25 dC × 2°, left eye -1.75 dS/-5.25dC × 167°) with best corrected visual acuity of 6/60 in both eyes and advised to use preservative free lubricating eye drop, tinted glasses when exposed to sunlight to reduce photophobia and glare. Since she had no other ocular or systemic complications, she was asked to come for periodic follow-up in eye clinic mainly focusing on her visual impairment caused by any lenticular changes, and IOP measurement to prevent advancement of any glaucomatous optic neuropathy changes.

DISCUSSION

Aniridia is a rare genetic disease which can have ocular as well as systemic associations. Here, we screened three family members, among which daughter and father were found to be affected. Genetic analysis forms the backbone to identify this disease, but due to financial constraint, in this case diagnosis was solely based on thorough clinical ocular and systemic examination. This family presented with a plethora of ocular manifestations associated with congenital aniridia and its complications having a dreadful impact on the vision which can adversely affect the patient's day to day life. The girl had congenital isolated aniridia with no other complications, and these types of cases can

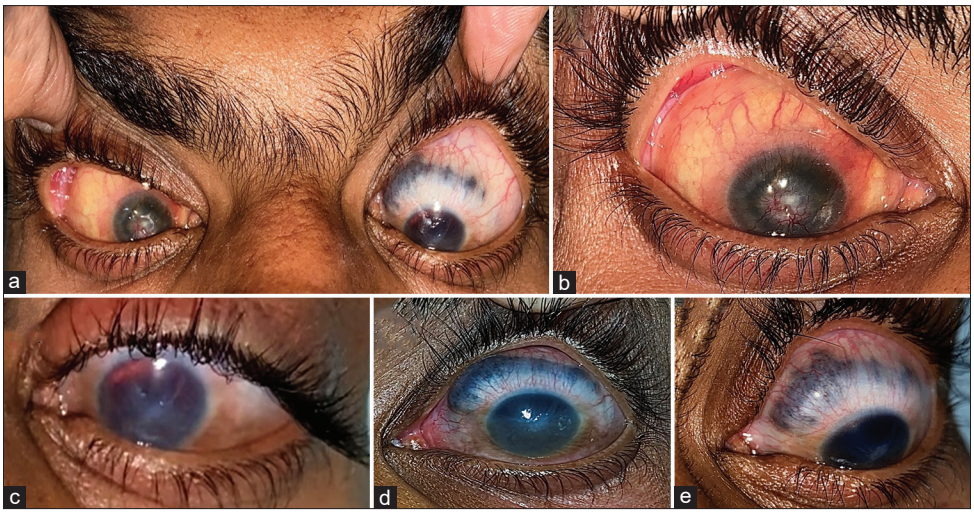

Figure 3: Facial profile of the father of index case (a) with right eye showing central leukoma with peripheral scarring and corneal vascularization (b). Left eye (c) showing diffuse corneal opacity and scarring involving central and inferior cornea suggestive of aniridia-associated keratopathy with rudimentary iris seen superiorly along with ciliary staphyloma in superiorly (d and e).

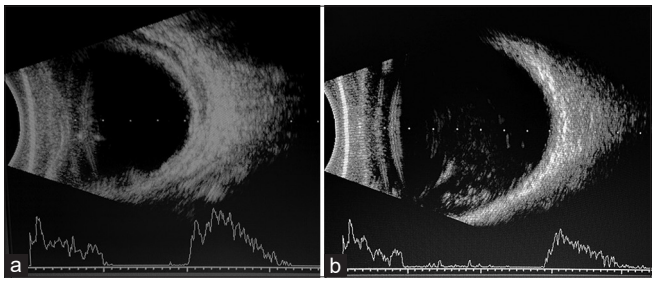

Figure 4: Ultrasound B scan of both eyes of father showing reduced axial length with thickened ocular coats in the right eye suggestive of pre-phthisical state (a). Left eye showing posterior vitreous detachment, low reflectivity vitreous echoes with attached retina (b)

be treated by correction of refractive error, tear substitute and periodic follow-up. However, her father was a case of aniridia having other ocular complications as well. These cases need to be treated for glaucoma, cataract extraction, tear substitute, and keratoplasty as per the need of the complication present in the affected individual.

CONCLUSION

Aniridia even being rare can have impact on visual outcome to a great extent and it may vary in severity from one person to another. However, proper diagnosis, timely intervention, and regular periodic follow-up are necessary for early visual rehabilitation. Apart from that, family screening is essential, along with genetic testing and counseling to raise more awareness.

AUTHORS CONTRIBUTIONS

The manuscript has been read and approved by all the authors that the requirements for authorship as stated earlier in this document have been met and that each author believes that the manuscript represents honest work.

REFERENCES

1. Landsend EC, Lagali N, Utheim TP. Congenital aniridia-a comprehensive review of clinical features and therapeutic approaches. Surv Ophthalmol 2021;66:1031-50.
2. Traboulsi EI. Aniridia. In: Ocular Disease. Netherlands: Elsevier; 2010. p. 472-7. Available from: https://www.linkinghub.elsevier.com/retrieve/pii/B9780702029837000619 [Last accessed on 2021 Aug 20].
3. Goetz K, Vislisel JM, Raecker ME, Goins KM. Congenital Aniridia. Available from: http://www.EyeRounds.org/cases/211-Aniridia.htm [Last accessed on 2015 Mar 10].
4. Lee H, Khan R, O'Keefe M. Aniridia: Current pathology and management. Acta Ophthalmol (Copenh) 2008;86:708-15.
5. Hingorani M, Hanson I, van Heyningen V. Aniridia. Eur J Hum Genet 2012;20:1011-7.
6. Tripathy K, Salini B. Aniridia. In: StatPearls. Treasure Island, FL: StatPearls Publishing; 2021. Available from: https://www.ncbi.nlm.nih.gov/books/NBK538133 [Last accessed on 2021 Aug 11].

How to cite this article: Guha S, Kumari R, Bhagat DK, Singh SR. Bilateral, Congenital Isolated Aniridia in a Child: A Case Report. Int J Sci Stud 2022;9(10):8-10.

Source of Support: Nil, **Conflicts of Interest:** None declared.

Print ISSN: 2321-6379
Online ISSN: 2321-595X

Case Series

Surgical Challenges in the Management of Unusual Splenic Pathology - A Case Series

Shrenik Govindaraj[1], Sridar Govindaraj[2], T J Clement Prakash[3]

[1]MBBS Student, Department of General Surgery and Division of MAS, St. John's National Academy of Health Science, Bengaluru, Karnataka, India, [2]Professor and Head, Department of General Surgery and Division of MAS, St. John's National Academy of Health Science, Bengaluru, Karnataka, India, [3]Assistant Professor, Department of General Surgery and Division of MAS, St. John's National Academy of Health Science, Bengaluru, Karnataka, India

Abstract

Spleen is an important organ in humans with numerous complex functions, most notably immunity. Surgical pathologies of the spleen such as tuberculosis (TB), cyst, and hemangioma are very rare. A high index of suspicion is required for diagnosis and treatment. A retrospective analysis of four young patients was done. Their clinical manifestations were nonspecific and varied, most common being vague abdominal pain and splenomegaly. The first patient had a large recurrent splenic epithelial cyst. Initially, treated by a laparoscopic fenestration procedure but recurred within 8 months. Second was a Littoral cell angioma. Third, TB of the spleen and the last was a ruptured pseudocyst. Blood investigations were normal; thrombocytopenia was observed with the splenic cyst due to sequestration or destruction. Diagnosis was by imaging with ultrasound and contrast enhanced computer tomography. Patients underwent a laparoscopy or open splenectomy. Distal pancreatectomy was combined in the pseudocyst case. All recovered well following surgery. To conclude, this case series provides a varied and nonspecific presentation of splenic pathologies. In suspected cases, imaging is very crucial for diagnosis. Most often, such rare pathology of the spleen need splenectomy for diagnoses or definitive treatment.

Key words: Spleen, Tuberculosis, Cyst, Hemangioma, Splenectomy

INTRODUCTION

The spleen is one of the versatile organs in humans that plays a very important role in the immune system. In the fetus, spleen develops in the dorsal mesogastrium from condensation of mesodermal tissue. The adult spleen weighs between 80 and 200 g and measures 10 × 7 × 3 cm. The parenchyma of the spleen consists of white and red pulp, surrounded by a capsule that is composed of smooth muscle fibers and serosa. It is a vital organ in children and adults, harbouring 66.5% of the body's T lymphocytes and 10–15% of B lymphocytes. Spleen is a major site of Immunoglobulin M production, opsonins promote phagocytosis and complement activation resulting in destruction of bacteria. Furthermore, the aged red blood cells are sequestrated and destroyed here. It performs an important auxiliary function of hematopoiesis when the bone marrow fails. It acts like a buffer with the portal circulation in soaking up the pressure in portal hypertension. Thus, we see the spleen being involved in many important and complex functions of the human body, thereby having a potential to get affected by various pathologies. Here, we will highlight a few interesting case scenarios encountered in our tertiary care center.

Access this article online

www.ijss-sn.com

Month of Submission : 11-2021
Month of Peer Review : 12-2021
Month of Acceptance : 12-2021
Month of Publishing : 01-2022

CASE 1

A 19 year old medical student had presented with intermittent episodes of left upper quadrant abdominal pain of 6 years duration, aggravated in the past 6 months, associated with fullness of the upper abdomen and early satiety. Examination had shown a large nontender, cystic mass in the left hypochondrium extending into the epigastrium, left lumbar and umbilical regions. Admission blood reports were normal except thrombocytopenia. Ultrasound of the abdomen showed a large cyst arising from the spleen. Contrast enhanced computed tomography (CECT) revealed a massive unilocular splenic cyst measuring 17 × 15 × 14 cm displacing the stomach/colon/small bowel [Figure 1]. Clinically, a benign splenic cyst was

Corresponding Author: T J Clement Prakash, SJNAHS, Sarjapur Road, Koramangala, Bengaluru, Karnataka, India.

suspected. Patient underwent a laparoscopic fenestration procedure with decompression. The massive thinned out spleen showed a thick walled cyst involving the entire organ extending from the visceral to the diaphragmatic surface with enlarged veins saddling the cyst. The analysis of aspirated straw colored fluid showed scanty pus cells. Patient made an uneventful recovery and was discharged on the second postoperative day. Histopathology of the cyst was reported as a benign splenic epithelial cyst [Figure 2].

Although he did well on short follow-up, 8 months later he presented with similar symptoms of upper abdominal pain, early satiety and upper abdominal fullness. Clinical examination also revealed similar findings as before, so we presumed a recurrence of the splenic cyst. A repeat CECT scan confirmed recurrence of the large cyst. We went ahead with hand assisted laparoscopic splenectomy (HALS) using Gelport. Vaccination for pneumococcus, meningococcus, and influenza was given 3 weeks before surgery. Laparoscopically, we saw a recurrence of the large splenic cyst with adhesions and the fenestra from previous surgery was closed by a huge omental plug [Figure 3]. Histopathology confirmed the same finding as before, a benign epithelial cyst. Now on follow-up he is doing well.

CASE 2

A 20 year old student presented with a history of vague pain involving the left hypochondrium of 4 years. There was acute exacerbation of pain associated with nausea and vomiting once or twice every month over the last 8 months. On examination, vitals were normal and the spleen was just palpable. Blood tests were normal. Ultrasound of the abdomen revealed a possible splenic hemangioma/hamartoma with internal bleed, CECT abdomen showed splenomegaly with multiple hemangiomas but no bleed [Figure 4]. Clinically, a diagnosis of splenic hemangiomas was suspected. As the patient was symptomatic, she was counselled for a laparoscopic splenectomy. Vaccination for pneumococcus, meningococcus, and influenza was given

Figure 1: Contrast enhanced computed tomography showing a large splenic cyst displacing the stomach, colon and small bowel

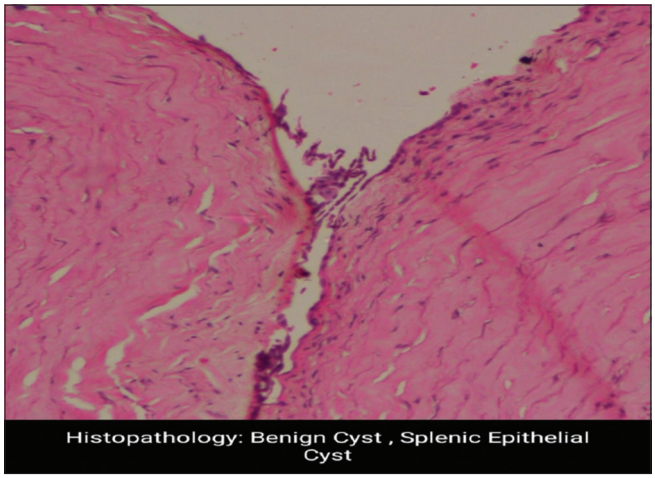

Figure 2: Histopathology showing fibro collagenous tissue with flattened epithelium and fibrin: benign epithelial cyst

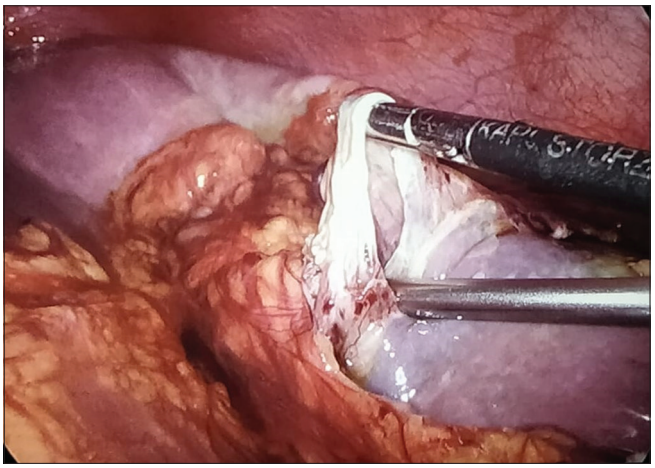

Figure 3: Laparoscopic view of an omental plug closing the fenestra from previous surgery

Figure 4: Contrast enhanced computed tomography scan showing splenomegaly with multiple isodense lesions with centripetal enhancement (periphery to center) suggestive of hemangiomas

3 weeks before surgery. Patient underwent a laparoscopic splenectomy. Post-operative period was uneventful and she was discharged 3 days later. Histopathology showed marked proliferation of vascular channels lined by plump endothelial cells, features suggestive of Littoral cell angioma (LCA) [Figure 5].

CASE 3

A 50 year old gentleman with diabetes mellitus, presented with pain in the left lumbar region since a month, low grade fever of 15 days, loss of appetite, malaise and weight loss. On physical examination, he was afebrile, tachycardia at 110 beats/min and blood pressure of 134/84 mm Hg. Abdomen examination revealed, fullness in the left lumbar region and tenderness in the left hypochondrium. Blood tests showed a high erythrocyte sedimentation rate (ESR) of 80 mm/h. Abdominal ultrasonography revealed splenomegaly with multiple small hypoechoic lesions within the spleen. CECT showed, multiple hypodense lesions in splenic parenchyma (micro abscesses) with thin splenic subcapsular fluid and also multiloculated collections in the subcutaneous plane and left paraspinal muscle at L2 [Figure 6]. In view of the computed tomography (CT) scan findings and a high ESR, in the Indian context a strong suspicion of Tubercular pathology was considered. Echocardiogram of the heart ruled out vegetations. He underwent an open splenectomy with drainage of the left paraspinal collection. The histopathology of the spleen demonstrated multifocal areas of necrotizing granulomatous inflammation [Figure 7] and Zhiel Neelson staining showed no acid-fast bacillus. In the Indian subcontinent, *Mycobacteria tuberculosis* was the final diagnosis. He was treated with anti-tubercular drugs for 6 months, quadruple drugs for 2 months and triple drug for 4 months, to which he has responded well. On follow-up, he has gained weight and his appetite has returned.

CASE 4

A 39 year gentleman had presented with a 4 month history of diffuse pain abdomen mainly in the upper quadrants, however of late it has increased in intensity with radiation to the back and a pleuritic chest pain. On examination, he was hemodynamically stable. Abdominal examination revealed fullness in the left hypochondriac region with minimal tenderness and auscultation of chest revealed decreased breath sounds on the left side. Blood investigations showed a high leucocyte count of 22,400, lipase and amylase were normal. Chest X-ray showed a left hydrothorax [Figure 8]. CECT revealed a large pancreatic tail pseudocyst eroding the spleen with a mass effect and rupture into the left hemi thorax with pleural effusion [Figure 9]. Subsequently, patient underwent an open splenectomy with distal pancreatectomy, lavage of the ruptured splenic pseudocyst and intercostal tube drainage. The intraoperative fluid analysis showed a high lipase and amylase value of 23,015 and 12,305 units respectively. The patient was electively ventilated in intensive care unit with a stormy postoperative period; intercostal tube was removed on the 6 postoperative day. He recovered well and was discharged on the 12th post-operative day. On follow-up, he is doing well.

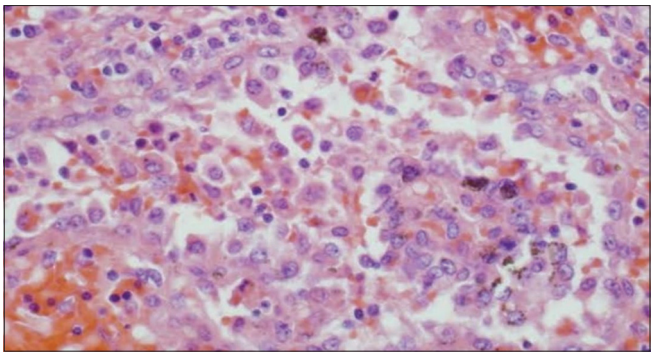

Figure 5: Histology showing proliferation of vascular channels lined by plump endothelial cells, littoral cell angioma

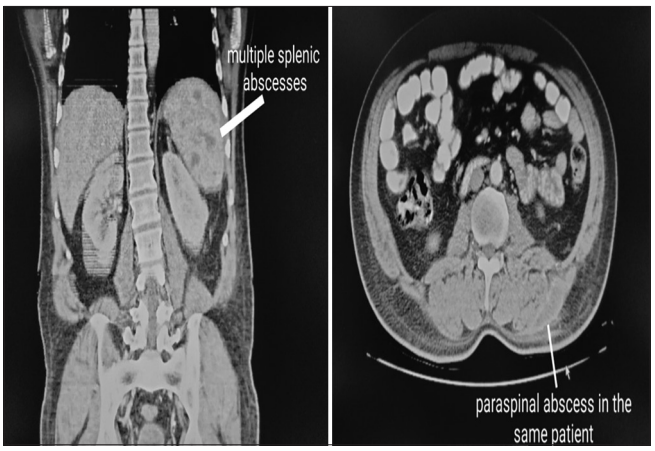

Figure 6: Contrast enhanced computed tomography showing multiple splenic abscesses and multiloculated paraspinal abscess

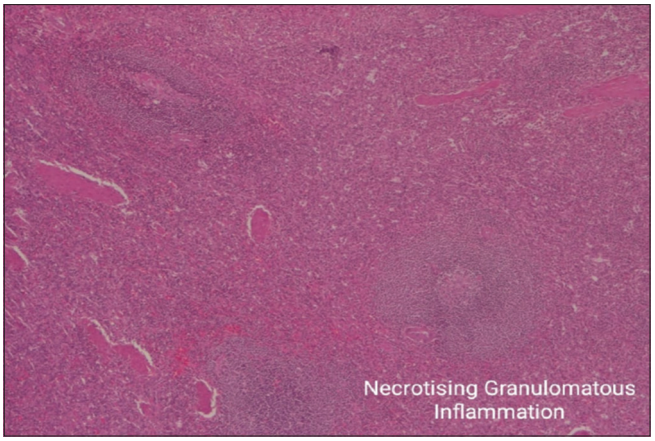

Figure 7: Histology of spleen showing necrotizing granulomatous inflammation

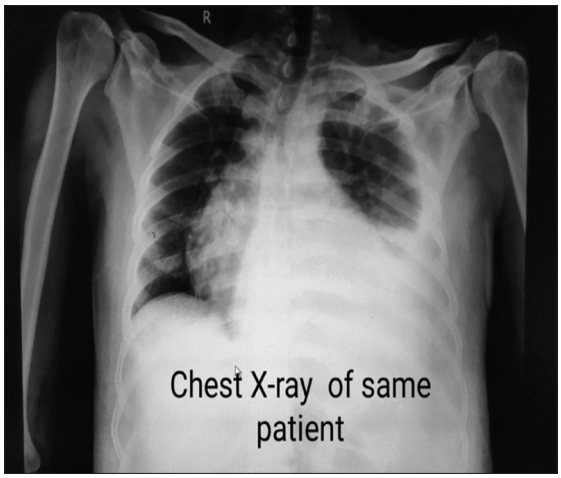

Figure 8: Chest X-ray showing a left hydrothorax due to rupture of splenic pseudocyst

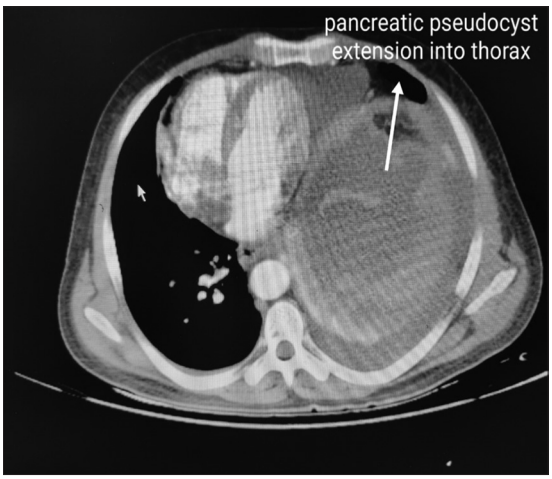

Figure 9: Contrast enhanced computed tomography scan of a pancreatic pseudocyst with extension into the hemi thorax

DISCUSSION

Fowler and Martin classified splenic cysts based on the presence (type 1) or absence (type 2) of cellular lining of the cystic wall into primary or true and secondary or pseudo cysts.[1,2] True cysts are further classified into parasitic (60%) and non-parasitic cysts. There are various theories regarding the development of splenic cyst. Most true splenic cysts are epithelial in origin and have an embryonic endodermal inclusion theory of epithelial cells from adjacent structures.[3] This lining is pluripotential and may undergo metaplastic changes and fluid accumulation with resultant cyst expansion. Congenital splenic cysts develop when there is an invagination of the mesothelium lined splenic capsule during development, that is, mesothelial invagination theory. According to the lymph space theory the cysts may arise from the normal lymph spaces within the spleen.[4] Primary splenic epithelial cyst is a rare condition with an incidence rate of 0.07% as reported in a review of 42,327 autopsies,[4-7] seen mostly in children, adolescents and young adults.[5] The symptoms are primarily gastrointestinal which include vague abdominal pain, early satiety, nausea, vomiting and dysphagia.[8] Histologically, epidermoid cysts have a squamous epithelial lining with intracellular bridges and a thick collagenous wall. Large symptomatic cysts must be treated surgically due to their susceptibility of hemorrhage, rupture and infection.[9] Because of the anonymity of the splenic cysts the surgical options are percutaneous aspiration or percutaneous drainage, marsupialization or cyst decapsulation or fenestration or deroofing, partial or total splenectomy. This can be done either by laparotomy or laparoscopy. Partial splenectomy preserves more than 25% of the splenic parenchyma, which is the minimal splenic tissue to preserve immunologic protection without increasing the risk of recurrence.[9] Common disadvantages of these methods except total spelenectomy are the high recurrence rate and bleeding.[9] So in cases of recurrence and large cysts, total splenectomy should be considered, as we did in our case with a good outcome and no long term follow-up.

Hemangiomas are the most common benign primary neoplasm of spleen. They are congenital in nature and very rare. Majority of them are asymptomatic and slow growing. Literature review shows <100 reported cases. Littoral-cell angioma (LCA) is a rare primary vascular tumor of the spleen that was first described by Falk *et al.* in 1991.[10] LCA is a unique lesion of the spleen that arises from the Littoral cells lining the venous sinuses of the splenic red pulp and shows features of combined endothelial and histiocytic differentiation. It is described as benign, but its biologic behavior could vary with malignant variation.[10-17] Splenomegaly, abdominal pain can be the presenting feature in a few cases. A hemogram may suggest to the existence of splenic hemangioma by showing thrombocytopenia secondary to unexplained consumptive coagulopathy caused by platelet trapping, especially in large or multiple hemangiomas. CECT scan findings of LCA is nonspecific, often multifocal and variable in size. Differential diagnosis includes hamartoma, hemangioma, hemangiopericytoma, hemangioendothelioma, and angiosarcoma. One-third of the previously reported cases were associated with tumors of visceral organs, including colorectal, renal, hepatocellular,[18] lung[19] and pancreatic adenocarcinomas, malignant lymphoma,[20] myelodysplastic syndrome,[21] or aplastic anemia.[22] LCA is a histological diagnosis showing endothelial and histiocytic differentiation. Immunohistologically; it is CD 34 and CD 8 negative but positive for CD 68 and CD 21.[23] Spontaneous rupture with hemorrhage is a serious risk with large lesions and some develop thrombosis with infarction. The natural course of the hemangioma is a very slow growth over time, but malignant transformation with distant metastases has been

reported.[24] The treatment options ranges from regular follow-up to total splenectomy, depending on whether the tumor is symptomatic or asymptomatic and on the size of the tumor. Partial splenectomy can be done when the tumor is at one of the poles. Total splenectomy should be done when the tumor is massive in size, multiple or laparoscopic splenectomy is planned. Angioembolization of a specific splenic arterial branch to the hemangioma can be considered based on the age of the patient, site and size of the lesion or before partial splenectomy.[25] Even after splenectomy, close surveillance is necessary in view of malignant nature of some LCA.

Splenic abscess is a rare clinical condition with a reported incidence of 0.14% to 0.70% in various autopsy series.[26-29] Primary tuberculosis (TB) as a cause of splenic abscess is even rarer, especially in the anti-tubercular era. The common organisms in most series are aerobic microbes, in particular *Staphylococci*, *Streptococci*, *Salmonella* and *Escherichia coli*.[30] TB commonly present as pulmonary disease. Extrapulmonary splenic TB occurs in two forms. The first presents during miliary TB, especially in immunocompromised patients.[31,32] The second, more unusual form of splenic TB is the primary involvement of the spleen in immunocompetent patients.[33,34] There are 5 types of pathomorphological classifications for splenic TB which includes miliary, nodular, abscess, calcific and mixed. Pyrexia of unknown origin is the commonest clinical presentation associated with loss of appetite and weight loss. CECT imaging is the best modality to diagnose these lesions. Image guided fine needle aspiration for cytological and microbiological assessment is an important method for diagnosis. The typical feature is caseation along with granuloma of epitheloid cells and Langhan's cells. Evidence supports the use of anti-tuberculosis therapy for 6 months alone in splenic TB where a definite diagnosis can be reached without splenectomy.[35,36] In most of the reported series, patients had undergone splenectomy for confirmation of diagnosis. A few controlled studies suggest a 12-month course of anti-tuberculous treatment to be appropriate for the treatment of patients with splenic TB. However, there are also reports available showing inadequate or the absence of response to anti-tuberculosis therapy without splenectomy.[37,38] However, our patient underwent an open splenectomy, as there was a subcapsular collection along with a large paraspinal abscess with extension into the subcutaneous region (rupture).

Pancreatic pseudocysts are a common clinical problem after acute pancreatitis, with an estimated prevalence of 6–18.5%. In chronic pancreatitis its prevalence is higher, ranging from 20 to 40%.[39] Despite the close proximity of the pancreas to the spleen, splenic complications are very rare (2%). Splenic involvement from the pancreatitis includes splenic vascular injury, intrasplenic pseudocysts, abscess, hematoma, infarction, necrosis, and rupture.[40-43] Among the above, intrasplenic pseudocysts are the most frequent. Several mechanisms have been proposed for the intrasplenic pseudo pancreatic cyst invasion. Pancreatic tail and splenic vessels are the contents of splenorenal ligament, anterior peritoneal layer of splenorenal ligament is in continuity with splenic capsule. The pancreatic enzymes released during inflammation or collected fluid (pseudocyst of tail/body) of pancreas can travel to spleen by dissecting postero-laterally along the splenic vessels and thus gain access to splenic parenchyma and result in intrasplenic (splenic pseudocyst) or perisplenic collection.[40] Pancreatic enzymes can also erode the splenic capsule directly and thus results in isolated splenic pseudocyst.[40] These complications have a high morbidity of 75% and mortality of 8%. There are very few cases reported in literature of splenic involvement in pancreatitis with rupture into thorax. Recognition of splenic complications is important because splenectomy is often indicated. The factors that contribute to the rupture of this pancreatic pseudocyst into the pleural cavity are uncertain. The pressure within the cyst, especially following hemorrhage, the erosion of tissue by pancreatic enzymes and the negative intrathoracic pressure may be the contributing factors. CECT and magnetic resonance imaging are important modalities to diagnose these complications.[44] Pancreatic pseudocysts are generally treated conservatively and majority of them resolve. Endoscopic drainage of pseudocysts is becoming the preferred therapeutic approach as it is less invasive, with minimum morbidity and almost no mortality. Endoscopic drainage depends on the anatomy and topography of the pseudocyst and can be done either transpapillary (via endoscopic retrograde cholangiopancreatography) if the cyst is communicating with the pancreatic duct or transmurally if it is not into the stomach or jejunum or duodenum. However, if there is rupture, like our case where pancreatitis involving the spleen forming a pseudocyst and rupture into thorax, surgery is indicated. Also in such complicated case scenarios, a multidisciplinary team approach will help.

CONCLUSION

This case series provides an idea of the varied and nonspecific presentation of the rare splenic pathologies. Imaging is very crucial for diagnosis. Most often, such rare pathology of the spleen need splenectomy either for diagnoses or definitive treatment.

ACKNOWLEDGMENTS

I would like to express my gratitude to Dr. Julian Crasta, Professor and Head, Department of Pathology for the

excellent slides which she provided and Dr. Arun George, Professor in the Department of Radiodiagnosis at St. John's National Academy of Health Sciences (SJNAHS) for the CT images.

AVAILABILITY OF DATA AND MATERIAL

Yes.

ETHICAL APPROVAL

The study was approved by the Institutional Ethics Committee.

PATIENT CONSENT FOR PUBLICATION

Informed consent was obtained from individual patients who participated in the study.

AUTHOR'S CONTRIBUTION

Shrenik Govindaraj: Data acquisition, interpretation and analysis, drafting of the article and approval of the manuscript.

Sridar Govindaraj: Critical review for intellectual content, final drafting and approval of the manuscript, photographs, pathology slides.

Clement Prakash: Critical review for intellectual content and approval of the manuscript, article design, final drafting and approval of the manuscript.

REFERENCES

1. Martin JW. Congenital splenic cysts. Am J Surg 1958;96:302-8.
2. Williams RJ, Glazer G. Splenic cysts: Changes in diagnosis, treatment and aetiological concepts. Ann R Coll Surg Engl 1993;75:87-9.
3. Lippitt WH, Akhavan T, Caplan GE. Epidermoid cyst of the spleen with rupture and inflammation. Arch Surg 1967;95:74-8.
4. Robbins FG, Yellin AE, Lingua RW, Craig JR, Turrill FL, Mikkelsen WP. Splenic epidermoid cysts. Ann Surg 1978;187:231-5.
5. Macheras A, Misiakos EP, Liakakos T, Mpistarakis D, Fotiadis C, Karatzas G. Non-parasitic splenic cysts: A report of three cases. World J Gastroenterol 2005;11:6884-7.
6. Doolas A, Nolte M, McDonald OG, Economou SG. Splenic cysts. J Surg Oncol 1978;10:369-87.
7. Geraghty M, Khan IZ, Conlon KC. Large primary splenic cyst: A laparoscopic technique. J Minim Access Surg 2009;5:14-6.
8. Trompetas V, Panagopoulos E, Priovolou-Papaevangelou M, Ramantanis G. Giant benign true cyst of the spleen with high serum level of CA 19-9. Eur J Gastroenterol Hepatol 2002;14:85-8.
9. Hansen MB, Moller AC. Splenic cysts. Surg Laparosc Endosc Percutan Tech 2004;14:316-22.
10. Falk S, Stutte HJ, Frizzera G. Littoral cell angioma. A novel splenic vascular lesion demonstrating histiocytic differentiation. Am J Surg Pathol 1991;15:1023-33.
11. Ramdall RB, Alasio TM, Cai G, Yang GC. Primary vascular neoplasms unique to the spleen: Littoral cell angioma and splenic hamartoma diagnosis by fine-needle aspiration biopsy. Diagn Cytopathol 2007;35:137-42.
12. Heese J, Bocklage T. Specimen fine-needle aspiration cytology of littoral cell angioma with histologic and immunohistochemical confirmation. Diagn Cytopathol 2000;22:39-44.
13. Nagarajan P, Cai G, Padda MS, Selbst M, Kowalski D, Proctor DD, *et al*. Littoral cell angioma of the spleen diagnosed by endoscopic ultrasound-guided fine-needle aspiration biopsy. Diagn Cytopathol 2011;39:318-22.
14. Ben-Izhak O, Bejar J, Ben-Eliezer S, Vlodavsky E. Splenic littoral cell haemangioendothelioma: A new low-grade variant of malignant littoral cell tumour. Histopathology 2001;39:469-75.
15. Meybehm M, Fischer HP. Littoral cell angiosarcoma of the spleen. Morphologic, immunohistochemical findings and consideration of histogenesis of a rare splenic tumor. Pathologe 1997;18:401-5.
16. Suvajdzić N, Cemerikić-Martinović V, Saranović D, Petrović M, Popović M, Artiko V, *et al*. Littoral-cell angioma as a rare cause of splenomegaly. Clin Lab Haematol 2006;28:317-20.
17. Hu ZQ, Yong-Jun A, Sun QM, Li W, Li L. The splenic littoral cell angioma in China: A case report and review. World J Surg Oncol 2011;9:168.
18. Lin CH, Yu JC, Shih ML, Peng YJ, Hsieh CB. Littoral cell angioma of the spleen in a patient with hepatocellular carcinoma. J Formos Med Assoc 2005;104:282-5.
19. Collins GL, Morgan MB, Taylor FM 3rd. Littoral cell angiomatosis with poorly differentiated adenocarcinoma of the lung. Ann Diagn Pathol 2003;7:54-9.
20. Bisceglia M, Sickel JZ, Giangaspero F, Gomes V, Amini M, Michal M. Littoral cell angioma of the spleen: An additional report of four cases with emphasis on the association with visceral organ cancers. Tumori 1998;84:595-9.
21. Erçin C, Gürbüz Y, Hacihanefioğlu A, Karakaya AT. Multiple littoral cell angioma of the spleen in a case of myelodysplastic syndrome. Hematology 2005;10:141-4.
22. Tholouli E, Roulson JA, Byers R, Burton I, Yin JA. Littoral cell angioma of the spleen in a patient with severe aplastic anaemia. Haematologica 2003;88:ECR33.
23. Arber DA, Strickler JG, Chen YY, Weiss LM. Splenic vascular tumors: A histologic, immunophenotypic, and virologic study. Am J Surg Pathol 1997;21:827-35.
24. Fernandez S, Cook GW, Arber DA. Metastasizing splenic littoral cell hemangioendothelioma. Am J Surg Pathol 2006;30:1036-40.
25. Patrzyk M, Glitsch A, Hoene A, von Bernstorff W, Heidecke CD. Laparoscopic partial splenectomy using a detachable clamp with and without partial splenic embolisation. Langenbecks Arch Surg 2011;396:397-402.
26. Billings AE. Abscess of the spleen. Ann Surg 1928;88:416-28.
27. Chulay JD, Lankerani MR. Splenic abscess. Report of 10 cases and review of the literature. Am J Med 1976;61:513-22.
28. Lawhorne TW Jr., Zuidema GD. Splenic abscess. Surgery 1976;79:686-9.
29. Walker JJ. Abscess of the spleen. N Engl J Med 1930,203:1025-8.
30. Ooi LL, Leong SS. Splenic abscesses from 1987 to 1995. Am J Surg 1997;174:87-93.
31. Pramesh CS, Tamhankar AP, Rege SA, Shah SR. Splenic tuberculosis and HIV-1 infection. Lancet 2002;359:353.
32. Thomson SR, Ghimenton F. Splenic tuberculosis. Postgrad Med J 1999;75:578.
33. Chandra S, Srivastava DN, Gandhi D. Splenic tuberculosis: An unusual sonographic presentation. Int J Clin Pract 1999;53:318-9.
34. Adil A, Chikhaoui N, Ousehal A, Kadiri R. Splenic tuberculosis. Apropos of 12 cases. Ann Radiol (Paris) 1995;38:403-7.
35. Ho PL, Chim CS, Yuen KY. Isolated splenic tuberculosis presenting with pyrexia of unknown origin. Scand J Infect Dis 2000;32:700-1.
36. Wilde CC, Kueh YK. Case report: Tuberculous hepatic and splenic abscess. Clin Radiol 1991;43:215-6.
37. Kundu PR, Mathur SK, Singh S, Duhan A, Aggarwal G, Sen R. Isolated tuberculous splenic abscess in an immunocompetent individual. Asian Pac J Trop Med 2011;4:81-2.
38. Nayyar V, Ramakrishna B, Mathew G, Williams RR, Khanduri P. Response to antituberculous chemotherapy after splenectomy. J Intern Med 1993;233:81-3.

39. Rocha R, Marinho R, Gomes A, Sousa M, Pignatelli N, Carneiro C, *et al*. Spontaneous rupture of pancreatic pseudocyst: Report of two cases. Case Rep Surg 2016;2016:7056567.
40. Warshaw AL, Chesney TM, Evans GW, McCarthy HF. Intrasplenic dissection by pancreatic pseudocysts. N Engl J Med 1972;287:72-5.
41. Slater G, Burrows L, Rudick J. Pseudocysts of the pancreas involving the spleen. Am Surg 1982;48:324-5.
42. Sitzmann JV, Imbembo AL. Splenic complications of a pancreatic pseudocyst. Am J Surg 1984;147:191-6.
43. Malka D, Hammel P, Lévy P, Sauvanet A, Ruszniewski P, Belghiti J, *et al*. Splenic complications in chronic pancreatitis: Prevalence and risk factors in a medical-surgical series of 500 patients. Br J Surg 1998;85:1645-9.
44. Fishman EK, Soyer P, Bliss DF, Bluemke DA, Devine N. Splenic involvement in pancreatitis: Spectrum of CT findings. AJR Am J Roentgenol 1995;164:631-5.

How to cite this article: Govindaraj S, Govindaraj S, Prakash TJ. Surgical Challenges in the Management of Unusual Splenic Pathology - A Case Series. Int J Sci Stud 2022;9(10):11-17.

Source of Support: Nil, **Conflicts of Interest:** None declared.

Print ISSN: 2321-6379
Online ISSN: 2321-595X

Review Article

Taurodontism: A Rare Dental Anomaly - A Brief Review

B Sivasaranya[1], S Sankarakrishnan[2], R Sridharan[3], S Arunpriyatharsini[3]

[1]Reader, Department of Prosthodontics, CSI College of Dental Sciences and Research, Madurai, Tamil Nadu, India, [2]Senior Lecturer, Department of Prosthodontics, Sathyabama Dental College, Chennai, Tamil Nadu, India, [3]Senior Lecturer, Department of Prosthodontics, CSI College of Dental Sciences and Research, Madurai, Tamil Nadu, India

Abstract

Human dentition is affected by a wide variety of abnormalities, which include variation in the number, morphology, and eruption sequences. The absence of tooth development manifests as anodontia, hypodontia, and oligodontia. Taurodontism is a developmental anomaly affecting the teeth leading to minimal or no constriction at the cementoenamel junction level manifesting as an enlarged pulpal chamber and also the trunk of the roots is displaced toward the apex giving a rectangular shape to the involved tooth. Due to the prevalence of taurodontism in modern dentitions and the critical need for its true diagnosis and management, this review article addresses the etiology, clinical and radiographic features, its association with variation syndromes and anomalies as well as clinical implications of dental treatments of such teeth.

Key words: Anomaly, Cementoenamel junction, Taurodont

INTRODUCTION

Dental morphological traits are of particular importance in the study of phylogenetic relationships and population affinities.[1] In this, dental anomalies are formative defects caused by genetic disturbances during tooth morphogenesis.[2] One such anomaly is taurodontism. Taurodontism is a developmental anomaly that has altered intrinsic pulp chamber morphology which results in the extension of the pulp chamber apically towards the root area in a multirooted tooth. It is characterized that lacks of constriction at the level of the cementoenamel junction (CEJ) and is characterized by a vertically elongated pulp chambers, apical displacement of the pulpal floor, and bifurcation or trifurcation of the roots. Witkop defined taurodontism as "teeth with large pulp chambers in which the bifurcation or trifurcation is displaced apically and hence that the chamber has greater apico occlusal height than in normal teeth and lacks the constriction at the level of CEJ." Taurodontism is currently defined as the tooth morphological alterations with the absence of the usual constriction at the CEJ, apical shift of the pulp chamber floor and furcation area at the expense of the roots and the root canal length.[1-4]

Access this article online

www.ijss-sn.com

Month of Submission : 11-2021
Month of Peer Review : 12-2021
Month of Acceptance : 12-2021
Month of Publishing : 01-2022

HISTORY

In 1903, De Terra described taurodontism as unusually shaped teeth having a cylindrical or prismatic form in remnants of prehistoric hominids. In 1907, taurodontism was first described by Gorjanovic- Kramberger. The first report of taurodontism in modern man's dentition was published in 1909 by Pickerill, who used the term "radicular dentinoma" to describe the dentition. He described the maxillary first molars exhibiting an overall cuboidal or bale shape with normal crowns and one central quadrilateral shaped pulp cavity instead of individual root canals.[5] The term taurodontism was first stated by Sir Arthur Keith in 1913. In 1939, Senyurek noted taurodontism in ancient Egyptians, ancient Icelanders, and early American Indians. In 1954, the recent literature contains reports of taurodontism as an isolated oddity, a familial trait, a trait with high frequency in Eskimos and other associated with several types of other systemic disturbances. The origin of the name taurodontism is a combination of the two words "tauros" meaning bull in Latin and "odus" which is of Greek origin meaning "tooth" and the initial use of

Corresponding Author: Dr. B Sivasaranya, CSI College of Dental Sciences and Research, Madurai, Tamil Nadu, India.

the term taurodontism was to describe the molar teeth resembling those of ungulates particularly bulls.[1-3,5-7]

ETIOLOGY

Theories concerning the etiology of taurodontism have been diverse and are commonly attributed to the failure of invagination of epithelial root sheath sufficient early to form the cynodont. This alteration in the Hertwig's epithelial root sheath involves failure of the epithelial diaphragm to form a bridge prior to dentin deposition resulting in a large pulp chamber.[5-8] This anomaly represents a primitive pattern, a mutation, a specialized or retrograde character, an atavistic feature, an X-linked trait, familial or an autosomal dominant trait. Taurodontism appears most frequently as an isolated anomaly, but it also has been associated with several developmental syndromes and anomalies including Amelogenesis Imperfecta, Down Syndrome, Ectodermal Dysplasia, Klinefelter Syndrome, Trichodento Osseous Syndrome, Mohr Syndrome, Wolf Hirschorn Syndrome, and Lowe Syndrome. Taurodontism has been present with other rare syndromes such as Smith-Magnesis Syndrome, William Syndrome, Mucune Albrright Syndrome, and Van de Wonde Syndrome.[9]

According to some authors, interferences in the epithelio-mesenchymatose induction have been proposed as a possible etiology. Some reports suggest that taurodontism may be genetically transmitted and could be associated with an increased number of X-chromosomes. However other researchers have found no simple genetic association but have noticed a trend for X-chromosomal aneuploidy amongst patients with more severe forms of the trait.[9,10]

But the etiology of taurodontism is still unclear. The possible causes of taurodontism have been enumerated by Mangion as follows, (a) A specialized or retrograde character, (b) A primitive pattern, (c) A Mendelian recessive trait, (d) An atavistic feature, (e) A mutation resulting from odontoblastic deficiency during dentinogenesis of the roots. Today it is considered as an anatomic variant that could occur in a normal population. The prevalence of taurodontism is reported to be in range from 2.5% to 11.3% of the human population. Females have been reported to be affected more by tooth agenesis in comparision with males.[1,5]

Theories concerning the pathogenesis of taurodontic root formation are also varied: An unusual developmental pattern, a delay in the calcification of pulpal chamber, an odontoblastic deficiency, an alteration in Hertwig's epithelial root sheath. According to some authors, taurodontism is most likely the result of disrupted developmental homeostasis.[1,11]

DIAGNOSIS

The external features have been primarily used for the diagnosis of taurodontism. It should be noted that gross external characteristics are not sufficient to generate diagnosis. Clinically taurodont appears as a normal tooth. In fact, because the body and roots of a taurodont tooth lie below the alveolar margin, its distinguishing features cannot be recognized clinically Identification of taurodontism can only be done by radiographic examination as the external teeth morphology within normal configurations. Therefore the diagnosis of taurodontism is usually a subjective determination made from diagnostic radiographs. The radiographic configuration is the best way to visualize the pulp chamber in a rectangular configuration. Diagnosis of taurodontism has been mainly based on subjective radiographic assessment. Radiographically, in taurodont tooth the pulp chamber is extremely large and elongated with much greater apico-occlusal height than normal and thus extends apically below the CEJ. The CEJ constriction is less marked than that of the normal tooth, giving the taurodont a rectangular shape. Furthermore, the furcation is displaced apically resulting in shorter roots whilst enlarging the body of a tooth. The radiographic characteristics of taurodont teeth are extension of the rectangular pulp chamber into the elongated body of the tooth, shortened roots and root canal, location of furcation size despite a normal crown size.[11]

CLASSIFICATION

Differences of opinion exist as to how much displacement and morphologic change constitutes taurodontism. In classifying tauroodont teeth, it is necessary to consider not only the size of the alveolar margin. Different classifications have been proposed in the literature.

In 1928, Shaw classified this condition based on the relative displacement of the floor of the pulp chamber as hypotaurodontism, mesotaurodontism, and hypertaurodontism. In 1966, Keene classified taurodontism based on the relation of the height of the pulp chamber to the length of the longest root. Keene proposed a taurodont index, cynodont index value of 0–24.9%, hypo-T: index value of 25–49%, meso-T: index value of 50–74.9%, hyper-T: index value of 75–100%.

In 1971 Blumberg, proposed a classification based on the mesiodistal diameter of the tooth, variable 1: Mesiodistal diameter taken at contact points, variable 2: Mesiodistal diameter taken at the level of the CEJ. Variable 3: Perpendicular distance from baseline to highest point on the pulpal chamber floor. Variable 4: Perpendicular distance

from baseline to the apex of the longest root. Variable 5: Perpendicular distance from baseline to lowest point on pulp chamber roof.

In 1977, Feichfnger and Rossiwall proposed a classification based on the distance from the bifurcation or trifurcation of the root to the CEJ should be greater than the occluso-cervical distance. In 1978, Shifman and Chanamel based on the distance between the occlusal third of the pulp chamber to the apex of the root, hypodont- T: 20–20.9%, Mesodont-T: 30–39.9%, Hyperdont-T: 40–75%.[1,11,12]

EPIDEMIOLOGY AND PREVALENCE

Taurodontism was at first thought to be a primitive tooth form. On the other hand, it is found in such diverse groups as Inuit, Aleuts, Mongolians, Europians. Except for a higher prevalence of taurodontism amongst females in a Chinese sample, no study has found a gender difference for this abnormality. Although permanent mandibular molars are most commonly affected. The degree of taurodontism increases from the first to the third molar. Furthermore, taurodontism is occasionally observed in mandibular premolars and even in maxillary premolars, mandibular canines, and incisors.

Taurodontism appears most frequently as an isolated anomaly. However reported as a feature of multiple systems malformation syndromes such as ectodermal dysplasia, down syndrome, Klinefelter syndrome, tricho-dento-osseous syndrome, and X-linked hypophosphatemic rickets. It has been found in association with various anomalies including amelogenesis imperfecta and hypodontia.[11,13]

CLINICAL CONSIDERATIONS

The clinical implication of taurodontism has a potentially increased risk of pulp exposure because of dental caries and dental procedures. Endodontic considerations include wide variation in the size and shape of the pulp chamber, varying degrees of obliteration, canal configuration, apically positioned canal orifices ant potential for additional root canal system. Endodontic therapy of choice in these clinical situations will be conservative. For its successful endodontic management, clinician should be aware of the complex canal system.[14,15] Surgical considerations include extraction of a taurodont tooth is usually complicated because of shift in the furcation to apical third. It has also been hypothesized that the large body with limited surface area of a taurodont teeth is embedded in the alveolus. Extraction of such teeth may not be problem unless the roots are not widely divergent. Pedodontic considerations include, pulp therapy for taurodonts is a challenging treatment, with increased incidence of hemorrhage during access opening which may be mistaken for perforation. Since the roots are short and pulpal floor is placed apically, care should be taken to prevent perforation. Taurodontism may complicate prosthodontic and orthodontic treatment planning. For the prosthetic treatment of a taurodont tooth, it has been recommended that post-placement be avoided for tooth reconstruction. Because less surface area of the tooth is embedded in the alveolus, a taurodont tooth may not have as much stability as a cynodont when used as an abutment for either prosthodontic or orthodontic purposes. From a periodontal view, taurodont teeth may in specific cases offer favorable prognosis. Where periodontal pocketing or gingival recession occurs, the chances of furcation involvement are considerably less than those in normal teeth because taurodont teeth have to demonstrate significant periodontal destruction before furcation involvement occurs. Taurodontism, although not very common has to be emphasized due to its influence on various dental treatments.

It is very important for a clinician to be familiar with taurodontism not only with regards to clinical complications but also its management. Taurodontism also provides a valuable clue in detecting its association with many syndromes and other systemic conditions. It can be seen that taurodontism has until now received insufficient attention from clinicians.[11,12]

CONCLUSION

Taurodontism is one of the rare dental anomalies in modern man which needs special attention while performing any treatment. This review attempts to provide knowledge regarding its etiology, related syndromes, classification, radiographic features, and clinical considerations in the treatment of such taurodont teeth. It can be seen that taurodontism has until now received insufficient attention from clinicians. No long term follow-up studies have been published regarding treatment of taurodont tooth.

REFERENCES

1. Dineshshankar J, Sivakumar M, Balasubramanium AM, Kesavan G, Karthikeyan M, Prasad VS. Taurodontism. J Pharm Bioallied Sci 2014;6 Suppl 1:S13-5.
2. Manjunatha BS. Taurodontism-a review on its etiology, prevalence and clinical considerations. J Clin Exp Dent 2010;2:187-90.
3. Patil SR, Reddy AK. Taurodontism with oligodontia in a young female patient: A case report with a brief literature review. J Dent Res Rev 2015;2:34-6.
4. Poornima P, Katkade S, Eregowda NI, Sangeeta KM. Bilateral taurodontism in primary and permanent molars associated with hypodontia. J Res Dent Sci 2017;8:46-9.
5. Jaspers MT, Witkop CJ Jr. Taurodontism, an isolated trait associated with syndromes and X-chromosomal aneuploidy. Am J Hum Genet 1980;32:396-413.

6. Luder HU. Malformations of the tooth root in humans. Front Physiol 2015;6:307.
7. Vashisth P, Dwivedi S, Arora S, Mayall S. Multiple bilateral taurodontic teeth in primary dentition: A case report. Int J Clin Pediatr Dent 2013;6:132-3.
8. Mena C. Taurodontism. Sci Dir 1971;32:812-23.
9. Nagaveni NB. An unusual occurrence of multiple dental anomalies in a single nonsyndromic patient: A case report. Case Rep Dent 2012;2012:426091.
10. Panigrahi A, Panigrahi RG, Srilatha KT, Bhuyan R, Bhuyan SK. Non syndromic familial bilateral decidious taurodontism-a first case report. J Clin Diagn Res 2014;8:ZD01-2.
11. Jafarzadeh H, Azarpazhooh A, Mayhall JT. Taurodontism: A review of the condition and endodontic treatment challenges. Int Endod J 2008;41:375-88.
12. Abdulgani A. Taurodontism; clinical considerations. J Dent Med Sci 2016;15:66-7.
13. Hasan M. Taurodontism Part 1: History, aetiology and molecular signalling, epidemiology and classification. Dent Update 2019;46:158-65.
14. Benazzi S, Nguyen HN, Kullmer O, Hublin JJ.Exploring the biomechanics of taurodontism. J Anat 2015;226:180-8.
15. Bharti R, Chandra A, Tikku AP, Wadhwani KK. Taurodontism" an endodontic challenge: A case report. J Oral Sci 2009;51:471-4.

How to cite this article: Sivasaranya B, Sankarakrishnan S, Sridharan R, Arunpriyatharsini S. Taurodontism: A Rare Dental Anomaly - A Brief Review. Int J Sci Stud 2022;9(10):18-21.

Source of Support: Nil, **Conflicts of Interest:** None declared.

Print ISSN: 2321-6379
Online ISSN: 2321-595X

Original Article

A Comparative Safety Assessment of Levosalbutamol and Salbutamol, with the Conventional Drug Delivery System, Metered-Dose Inhaler, in Mild Asthma; with a Pharmacovigilance Monologue

Moumita Hazra[1,2,3,4,5,6,7]

[1]Associate Professor, Head of Department In Charge, Department of Pharmacology, Pharmaco-Haemo-Materio-Vigilance Specialist, Pharmacovigilance Committee, Mamata Medical College and Hospitals, Khammam, Telangana, India, [2]Former Associate Professor, Head of Department In Charge, Department of Pharmacology, Rama Medical College Hospital and Research Centre, Rama University, Uttar Pradesh, India, [3]Medical Director, Medical Superintendent, Consultant Clinical Pharmacological Physician, Consultant Respiratory Pharmacological Physician, Consultant Clinical Pathologist, Consultant Drug Safety and Quality Physician, Pharmaco-Haemo-Materio-Vigilance Specialist, Dr. Moumita Hazra's Polyclinic And Diagnostic Centre, Hazra Nursing Home, West Bengal, India, [4]Former Resident and Tutor, Departments of Pharmacology and Pathology, J. J. M. Medical College, Bapuji Hospital, Chigateri General Hospital, Karnataka, India, [5]Former Deputy Medical Superintendent, Department of Medical Administration, Assistant Professor, Head of Department In Charge, Department of Pharmacology, Shri Ramkrishna Institute of Medical Sciences and Sanaka Hospitals, West Bengal, India, [6]Former Deputy Medical Superintendent, Department of Medical Administration, Raipur Institute of Medical Sciences, Chhattisgarh, India, [7]Former Manager, Quality Management and Clinical Excellence, Department of Medical Administration, Fortis Hospitals, India.

Abstract

Introduction: Short-acting β2-agonists, such as salbutamol and levosalbutamol, are the most commonly used bronchodilators for the routine treatment of mild asthma. Occupation of β2 receptors by agonists results in the activation of the Gs-adenylyl cyclase-cAMP-PKA pathway, resulting in phosphorylative events, leading to bronchial smooth muscle relaxation. A metered-dose inhaler is a portable and a very convenient drug delivery system, conventionally used in the treatment of mild asthma.

Objective: The aim of this pharmacovigilance (PV) study was to compare the safety of levosalbutamol with salbutamol inhalation therapy, in the routine treatment of mild asthma, with a PV monologue.

Methods: Fifty patients, with mild asthma, were randomly allotted to Group A=25 and Group B=25. The patients in Group A and Group B were prescribed the inhalation treatment of levosalbutamol and salbutamol, respectively, two puffs in each nostril, with a metered-dose inhaler, once in the early evening, for 2.5 months. After the inhalation dose, the patients were monitored for 10 h, for adverse effects, such as headache, tremor, irritation in the oral cavity, and palpitation, with Adverse Event Case Report Forms; and the observations were statistically analyzed.

Results: In both Groups A and B, the adverse effects of levosalbutamol and salbutamol were not statistically significant; and both were equally safe and tolerable.

Conclusion: Inhaler administered levosalbutamol and salbutamol was equally safe, as the prevalent drug-through-the-device therapeutic system, for treating mild asthma.

Key words: Pharmacovigilance, levosalbutamol, salbutamol, metered-dose inhaler, asthma, drug safety.

Access this article online

IJSS

www.ijss-sn.com

Month of Submission : 11-2021
Month of Peer Review : 12-2021
Month of Acceptance : 12-2021
Month of Publishing : 01-2022

INTRODUCTION

Short-acting β2-agonists, such as salbutamol and levosalbutamol, are the most commonly used bronchodilators for the routine treatment of mild asthma.

Corresponding Author: Dr. Moumita Hazra's, Polyclinic And Diagnostic Centre, Hazra Nursing Home, Jagadishpur Road, P.O. Domjur, Dist. Howrah, West Bengal - 711 405, India.

Occupation of β2 receptors by agonists results in the activation of the Gs-adenylyl cyclase-cAMP-PKA pathway, resulting in phosphorylative events, leading to bronchial smooth muscle relaxation.[1]

Salbutamol is a mixed dextro- and levo-rotatory racemate, and levosalbutamol is the purified enantiomer of racemic salbutamol that has a greater affinity for the β2 receptor as compared to salbutamol; both causing bronchodilatation, inhibition of inflammation, and baseline airway reversibility.[1,2]

A metered-dose inhaler is a topical drug delivery system, conventionally used in the treatment of mild asthma. It is portable, very convenient, cost effective, less time consuming, less energy resources consuming, requiring less maintenance and with lesser adverse effects like ororespiratory mucosal irritation.

Inhaled medications for asthma are available as pressurized metered-dose inhaler, metered-dose inhaler with spacer, breath-actuated metered-dose inhaler, dry powder inhalers, soft mist inhalers, and nebulized or wet aerosols.

Inhaler devices differ in their efficacy of drug delivery to the lower respiratory tract, depending on:
1. Form of devices
2. Formulation of medication
3. Particle size
4. Velocity of aerosol cloud or plume
5. Ease with which device can be used by majority of patients

Studies have shown no statistically significant differences on spirometric variables such as peak expiratory flow rate (PEFR), forced expiratory volume in 1 s (FEV1), forced vital capacity (FVC), and FEV1/FVC, after giving bronchodilators, by metered-dose inhaler, nebulizer or dry powder inhaler.

Choice of an inhaler device depends on:
1. Patient's age
2. Cognitive status
3. Visual acuity
4. Manual dexterity and strength
5. Ability to coordinate inhaler actuation with inhalation
6. Disease severity
7. Convenient to use
8. Portability
9. Cost-effectiveness.[3]

Objectives

The objective of this comparative, multicenter, pharmacovigilance (PV) study was the safety assessment of levosalbutamol and salbutamol, administered with the familiar drug delivery system, a metered-dose inhaler, in the routine treatment of mild asthma; along with a PV monologue.

METHODS

Study Type

This was a multicenter, prospective, randomized, open-labeled, comparative PV study; and a PV monologue.

Study Population

The study participants consisted of 50 patients, suffering from mild asthma.

Study Place

The research study and the compilation of the study literature were conducted in the Departments of Pharmacology, Clinical Pharmacology, Rational Pharmacotherapeutics, PV, Respiratory Medicine and Chest Diseases, Medical Administration, in Mamata Medical College and Hospitals, Rama Medical College Hospital and Research Centre, Rama University, Dr. Moumita Hazra's Polyclinic and Diagnostic Centre, Hazra Nursing Home, J. J. M. Medical College, Bapuji Hospital, Chigateri General Hospital, Shri Ramkrishna Institute of Medical Sciences and Sanaka Hospitals, Raipur Institute of Medical Sciences, and Fortis Hospitals.

Study Period

The study period for the research study and the compilation of the study literature were 2.5 months, that is, December 2020–February 2021; and October 2021–November 2021.

Ethical Approval

At first, the clearance and the approval from the Institutional Ethics Committee were obtained. The study was conducted in accordance with the ethical principles originating from the Declaration of Helsinki and Good Clinical Practices contained within the International Council for Harmonization of Technical Requirements for Pharmaceuticals for Human Use (ICH-E6), and in compliance with the regulatory requirements. Informed consent was obtained from each patient.

Selection Criteria of the Patients

Inclusion criteria

The following criteria were included in the study:
(a) Age >18 years, of any gender;
(b) British Thoracic Society definition of asthma grades;[4]
(c Ability to perform spirometry maneuvers;
(d) Cooperative and conscious patients.

Exclusion criteria

The following criteria were excluded from the study:
(a) Uncooperative and unconscious patients;

(b) Patients presenting with acute severe or acute life-threatening or near-fatal asthma;
(c) History of hypersensitivity to the study drugs;
(d) Pregnant or lactating women;
(e) Other associated medical illness having impact on study results;
(f) Children or very old patients.

Study Procedure

Fifty patients, with mild asthma, were randomly allotted to Group A = 25 and Group B = 25. The demographic characteristics of the patients, and the details of complete general physical examination, and systemic examination, including oto-rhino-laryngo-tracheal, respiratory and cardiopulmonary examinations, were recorded. Pulse rate, oxygen saturation of arterial hemoglobin (SpO2), and respiratory rate were recorded.

Spirometric variables such as PEFR, FEV1, FVC, and FEV1/FVC were recorded, after giving bronchodilators, by metered-dose inhaler. The patients in Group A and Group B were prescribed the inhalation treatment of levosalbutamol and salbutamol, respectively, two puffs in each nostril, with a metered-dose inhaler, once in the early evening, for 2.5 months. After the inhalation dose, the patients were monitored for 10 h, for adverse effects, such as headache, tremor, irritation in the oral cavity, and palpitation, with adverse event (AE) case report forms; and the observations were statistically analyzed with the test of significance with p values, with subsequent tabular representations.

RESULTS

The demographic characteristics of the study participants were comparable.

In both Groups A and B, the adverse effects of levosalbutamol and salbutamol were not statistically significant; and both were equally safe and tolerable, as depicted in Table 1.

DISCUSSION

PV plays a key role in assessing, monitoring, and preventing adverse drug reactions (ADRs). In recent years, national legislative bodies and national regulatory authorities (NRAs) across the world have issued a significant amount of legislation and guidance enforcing the obligation to perform PV activities. In countries where the NRA is a member of the International Council for Harmonization of Technical Requirements for Pharmaceuticals for Human Use (ICH), safety management requirements are generally consistent with ICH guidelines. In a number of countries beyond this scope, requirements may deviate from internationally agreed standards, adding a substantial complexity and increasing burden on the stakeholders involved, while the benefit for patients' safety may not be evident. Committed to fulfilling safety regulatory obligations in any country for a medicinal product license, global pharmaceutical companies have accumulated a broad and deep experience acquired while meeting the expectations of a large array of diverse PV systems across the world. These range from suboptimal frameworks, according to the World Health Organization (WHO) Global Benchmarking Tool, to highly effective resource-optimized PV systems. To support countries creating or further developing their PV systems, especially where infrastructure and resources are limited, the European Federation of Pharmaceutical Industries and Associations International PV Group (IPVG) has developed consensus recommendations consistent with harmonized standards for the development and step-wise implementation of key PV system components.

The ability to oversee suspected ADRs and information on medicinal product use in special situations is fundamental to the detection, assessment, understanding, and mitigation of medicinal product risks. Various collection tools for such information are available depending on local needs and preferences, for example, telephone hotlines, paper forms, websites, and mobile applications such as the WEBRADR Mobile App. Suspected ADRs need to be maintained in a safety database. To maximize the use of limited resources, the IPVG recommends the use of the WHO's VigiFlow when not setting up a specific national database.

Further elements of a national PV system may include:
- Requirements for the submission of periodic safety reports,
- Requirements for the submission of risk management plans,
- Requirements for a written description of the key stakeholders' PV system,
- Establishment of a local safety responsible,

The priority and the order in which each element may be added will depend on local needs, available resources, and preferences in relying on outputs from other regulators, and the choice to use own or NGO-offered safety systems either temporally or permanently.

Table 1: Adverse effects of levosalbutamol and salbutamol, with their frequency of occurrence

Adverse effects	Levosalbutamol (*n*=25)	Salbutamol (*n*=25)	*P*-value
Headache	0	0	ns
Tremor	0	1	ns
Irritation in oral cavity	0	1	ns
Palpitations	0	0	ns

ns: Non-significant

A successful reporting system requires public awareness. The IPVG recommends that global public awareness tools such as those provided by the Strengthening Collaboration for Operating PV in Europe initiative and by the Uppsala Monitoring Center (UMC) are used to increase public awareness and importance of ADR reporting. Educational material for health-care professionals (HCPs) is also available through SCOPE and may be used for training of HCPs in university courses and beyond. It is recommended that public health campaigns center around a specific public health initiative, for example, a vaccination program or an emergency medicine.

The foundation of any national PV system is a national reporting system. Such a system facilitates the collection of AEs and information on medicinal product use in special situations from HCPs and consumers/patients, and the expedited reporting of suspected ADRs as individual case safety reports (ICSRs). ICSR data form the basis of a national dataset for medicinal products. This dataset is constantly evolving based on the information received. ICSR data also serve as the basis for the detection of safety signals, the review of the benefit–risk relationship in periodic safety reports, and risk management planning. NRAs receiving ICSRs in an expedited manner, that is, within specific timelines, should assess individual reports soon after receipt. If a significant public health concern is identified, the NRA should quickly take regulatory action to mitigate risks to patients. The most accepted standards for PV come from the International Council for Harmonization of Technical Requirements for Pharmaceuticals for Human Use (ICH) and the Council for International Organizations of Medical Sciences (CIOMS), which have set many of the founding principles for PV, including the CIOMS form for reporting suspected ADRs. In addition to the collection of AEs, collection of information on medicinal product use in special situations is required by many regulators for systematic safety surveillance. This information can be collected in the same way as AEs. ICSRs should be considered valid for expedited reporting only if the report contains the four minimal criteria as described in the ICH E2D guidance. The minimum criteria for ICSRs valid for regulatory reporting are as follows:

1. An identifiable reporter,
2. A single identifiable patient,
3. A suspect medicinal product,
4. A suspect adverse reaction.

To support their national PV database, NRA members of the WHO Programme for International Drug Monitoring (WHO-PIDM) are entitled to use the VigiFlow system made available by the UMC, the WHO-associated center for international drug monitoring. VigiFlow is an online platform, structured according to country-specific ICSR containers owned, and controlled by the respective NRAs. VigiFlow includes functionality to let NRAs forward ICSRs to VigiBase (the global WHO PV database). In addition, any NRA contributing to the WHO-PIDM (using VigiFlow or not) has access to VigiBase to search for signals at country, regional, or global levels, using VigiLyze, an advanced online analytic tool supplied by the UMC. VigiLyze also allows a NRA to view foreign ICSRs as they relate to a search topic.

The IPVG recommends that NRAs request marketing authorization holder (MAHs) to collect information on all domestic AEs as well as cases of parent–child exposure even if no AE occurred. Other domestic cases of exposure in special situations lacking the occurrence of any AE do not require expedited reporting, but should be compiled by the MAH and reported in the Periodic Benefit Risk Evaluation Report (PBRER). For expedited reporting, the following reporting timelines are recommended:

- 15 calendar days for serious ICSRs as per ICH E2D guidance.
- 90 calendar days for non-serious ICSRs as per European Union (EU) Good Vigilance Practice (GVP)

For access to foreign ICSRs, the IPVG recommends considering accessing the WHO's VigiBase, the largest global PV database, currently containing over 20 million ICSRs, using the WHO's VigiLyze software. VigiLyze is exclusively reserved for NRAs contributing to the WHO-PIDM, free of charge, and represents a powerful and resource-efficient alternative to the receipt of foreign ICSRs from MAHs. In addition, the VigiLyze data analytic tool can be used to perform signal detection and other analytic investigations at the country, regional, or global level.

A medicinal product is authorized for marketing if the applicant can demonstrate sufficient evidence for quality, safety, and efficacy in the specified indication(s) and target population(s). As the investigated clinical trial population is usually limited in size and duration of drug exposure, as well as selective for criteria such as age, gender, genetic variants, concomitant diseases, and comedication, not all ADRs and risks will be known at the time of the initial marketing authorization. In fact, certain ADRs and risks can only be discovered or further characterized post-authorization. According to internally accepted standards and regulations, MAHs should, therefore, have continuous safety monitoring and signal management systems in place that permits early detection of potential new risks or potentially changed characteristics of known risks. Signal management is defined as a set of activities performed to determine whether, based on an examination of ICSRs, aggregated data from active surveillance systems or studies,

scientific literature information, or other data sources, there are new risks associated with an active substance or a medicinal product or whether known risks have changed, as well as any related recommendations, decisions, communications, and tracking. Depending on the size of the dataset, different signal detection methodologies or combinations of methodologies may be used. Review of global safety data should reside with experienced staff of the MAH that owns the global safety database for the medicinal product and who are in the position to oversee and analyze signals from all sources from the totality of the globally available dataset relevant to a given safety issue. If a MAH does not own or have access to the global safety database or lacks the expertise to conduct signal detection and analysis, the MAH may delegate some or all activity to the global safety database-owning organization. Review of national safety data for local signals by NRAs/national PV centers may contribute to understanding a medicinal product's safety profile in the local market and may focus on, for example, medication errors, off-label use, misuse, abuse, or potential risks described in RMPs. Regional and/or global data may supplement local data as appropriate. For example, identified similarities of national data with regional or global data will further strengthen a local signal, whereas differences between national and regional/global data may help in identifying factors that are specific to a country/region and need to be considered when discussing appropriate local risk minimization measures. For reviewing pools of individual safety data, the IPVG recommends using VigiLyze for searching into the WHO PV database (VigiBase) to detect signals at the country level compared to searches at the regional or global levels. NRAs may also consider networking with stakeholders or other NRAs for confirmation of their signal detection finding and/or use signal detection outcomes from established NRAs as surrogates for their own analyses.

Signal reporting from the MAH to NRAs should be proportionate to the information arising from the signal analysis. The IPVG proposes a risk appropriate approach to signal reporting similar to recommendations made by the Swiss medic and that those signals that require in-market action (e.g., product information update, direct market communication, and marketing authorization suspension/revocation/withdrawal for safety reasons) should be notified to an NRA.

The IPVG also recommends using common terminology such as the terminology proposed by the CIOMS or EU-GVP to avoid misunderstandings in reportability of signals to NRAs. The term "emerging safety issue" should only be used for the most serious risks where an immediate in-market action is required to protect patients and public health.

Periodic safety reports such as the EU Periodic Safety Update Report (PSUR) provide a review of the current benefit–risk profile of a medicinal product, taking into account, all available worldwide data including:

- Safety, efficacy, and effectiveness data
- Use of the medicinal product in authorized and non-authorized ("off-label") indications
- Missing data (e.g., data in special populations)

For a consistent global approach to the periodic evaluation of a medicinal product's benefit–risk profile, the IPVG recommends the use of the PBRER format as outlined by the ICH E2C guidance. The PBRER is very comprehensive, describing post-marketing data, data from completed and ongoing clinical trials, relevant non-interventional studies and other activities, cumulatively, and for the specified report period, at a global level. The document also presents a comprehensive and critical analysis of new or emerging information on the risks of the medicinal product in the context of its benefits, taking into account new information from the last reporting period and cumulative information. The analysis of the risks is based on the reference safety information. The International Birth Date (IBD) is the date of the first marketing authorization for any medicinal product containing the active substance granted to an applicant in any country in the world. Using a single birth date such as the IBD and aligned review periods/data lock points (DLPs) for periodic safety reports worldwide is recommended, not only for harmonization purposes and reduction of administrative burden but also to facilitate true global periodic benefit–risk assessment for the medicinal product. In addition, the IPVG recommends aligning the periodicities of existing country-specific periodic safety reports with the periodicities of the global benefit–risk assessments in the PBRERs to allow for direct comparability of local data with global data and the interpretation of local data in the context of available global data from all sources. The PBRER should preferably be written in a commonly understood technical language, that is, English, to allow for consistency and avoid translation errors. Should translations into national languages be required, a translation of the executive summary could be an effective approach, as it contains a summary of the key information contained in the document. The frequency of report submission to NRAs depends on factors such as the length of time the medicinal product has been on the market, product-specific risks, and the extent of knowledge regarding the product's benefit–risk profile. In general, PBRER periodicities and submission frequencies for newly authorized medicinal products in a country should follow ICH E2C and/or EU-GVP recommendations and be based on the DLP calculated from the IBD, that is, 6-month periodicity the first 2 years after approval, then annually for the subsequent 3 years. When a newly authorized medicinal product in a country already has a marketing authorization in

a reference country, the IPVG recommends alignment with the periodicity and submission frequency for the medicinal product in the reference country or alignment with the periodicity and submission frequency as described in the EU Reference Dates list. The IPVG recommends harmonized timelines for PBRER preparation and submission according to internationally acceptable timelines such as:

- Within 70 calendar days of the DLP for PBRERs covering intervals up to 12 months.
- Within 90 calendar days of the DLP for PBRERs covering intervals in excess of 12 months.

Furthermore, the IPVG would like to mention that the European Medicines Agency (EMA) has an EU-GVP for PSUR assessment report (PSUSA) in place where one EU member state ensures a coordinated single assessment for medicinal products that contain the same active substance or combination of active substances. The PSUSA procedure is an excellent example of resource-effective regulatory reliance advocated earlier.[5]

CONCLUSION

Inhaler administered levosalbutamol and salbutamol was equally safe, as the prevalent drug-through-the-device therapeutic system, for treating mild asthma. Therefore, this PV research study rendered an elaborate medical treatise regarding the algorithmic logistics of ADRs monitoring mechanisms.

ACKNOWLEDGMENTS

My profound gratitude to the Departments of Pharmacology, Clinical Pharmacology, Rational Pharmacotherapeutics, PV, Respiratory Medicine and Chest Diseases, Medical Administration, in Mamata Medical College and Hospitals, Khammam, Telangana; Rama Medical College Hospital and Research Centre, Rama University, Uttar Pradesh; Medical Director, Medical Superintendent, Consultant Multi-Specialist Clinical Pharmacological Physician, Consultant Respiratory Pharmacological Physician, Consultant Clinical Pathologist, Dr. Moumita Hazra's Polyclinic And Diagnostic Centre, Hazra Nursing Home, West Bengal; and J. J. M. Medical College, Bapuji Hospital, Chigateri General Hospital, Karnataka; Shri Ramkrishna Institute of Medical Sciences and Sanaka Hospitals, West Bengal; Raipur Institute of Medical Sciences, Chhattisgarh; and Fortis Hospitals; India; for the successful completion of this research project.

REFERENCES

1. Hazra M. A pharmacoepidemiological study of prescription patterns of β2 sympathomimetic bronchodilators in exacerbation of non-severe asthma in tertiary care hospitals, not needing hospitalization. Int J Basic Clin Pharmacol 2019;8:2674-80.
2. Hazra M, Geetha M, Somashekar HS, Arun BJ, Vidyasagar B. A study comparing rescue medications: Arformoterol and salbutamol nebulization in exacerbation of non-severe asthma at a tertiary care center, not needing hospitalization. Int J Pharm Sci Res 2013;4:3151-6.
3. Rizvi DA, Abidi A, Agarwal A, Ahmad A. The comparison the efficacy of budesonide by nebuliser, metered dose inhaler and dry powder inhaler in chronic stable bronchial asthma. Int J Basic Clin Pharmacol 2018;7:1333-8.
4. British Thoracic Society, Scottish Inter Collegiate Guidelines Network. British guidelines on the management of asthma. Thorax 2008;63 Suppl 4:1-121.
5. Peters T, Soanes N, Abbas M, Ahmad J, Delumeau JC, Herrero-Martinez E, *et al*. Effective pharmacovigilance system development: EFPIAIPVG consensus recommendations. Drug Saf 2021;44:17-28.

How to cite this article: Hazra M. A Comparative Safety Assessment of Levosalbutamol and Salbutamol, with the Conventional Drug Delivery System, Metered-Dose Inhaler, in Mild Asthma; with a Pharmacovigilance Monologue. Int J Sci Stud 2022;9(10):22-27.

Source of Support: Nil, **Conflicts of Interest:** None declared.

Print ISSN: 2321-6379
Online ISSN: 2321-595X

Original Article

Comparative Evaluation of Pushout Bond Strength of Biodentine after Root Dentin Conditioning with Different Irrigating Solutions- An *In Vitro* Study

Pooja Gandhe[1], Ashwini Gaikwad[2], Varsha Pandit[3], Anandita Sengupta[3], Pruthviraj Deshmukh[4]

[1]Post Graduate Student, Department of Conservative Dentistry and Endodontics, Bharati Vidyapeeth Dental College and Hospital, Pune, Maharashtra, India, [2]Professor, Department of Conservative Dentistry and Endodontics, Bharati Vidyapeeth Dental College and Hospital, Pune, Maharashtra, India, [3]Post Graduate Student, Department of Conservative Dentistry and Endodontics, Bharati Vidyapeeth Dental College and Hospital, Pune, Maharashtra, India, [4]Post Graduate Student, Vasantdada Patil Dental College and Hospital, Kavalapur, Maharashtra, India

Abstract

Introduction: Sodium hypochlorite (NaOCl) is the main irrigant used to clean the root canal system. Chelating agents are used as additional means to condition the root dentin. The aim of this *in vitro* study is to evaluate and compare the effect of NaOCl in conjunction with Etidronic acid and Chlorhexidine on pushout bond strength of biodentine.

Materials and Methods: Single root canals of 30 extracted, mature human teeth were divided into three groups (n = 10) and enlarged using rotary instruments. Canals were irrigated according to the irrigation regimen: Group A (n = 10)–control group- distilled water. Group B (n = 10)- 2.5% NaOCl +9% HEDP. Group C (n = 10)- 2.5% NaOCl for 1 min-5 ml saline-2% chlorhexidine. Each sample was then filled with biodentine. A horizontal section of 1.5-mm thickness was taken from the middle root third, and a pushout bond test was performed. Data were statistically analyzed using Chi-square to find the significance of study parameters on categorical scale. Analysis of variance/Tukeys *post hoc* analysis to test the intergroup analysis.

Results: The pushout bond strength of Biodentine was significantly higher when the root canal was irrigated with 2.5% NaOCl/9% HEDP (9.45 ± 0.35 MPa) than with 2.5% NaOCl/saline/2% Chlorhexidine (8.27 ± 0.52 MPa). The lowest pushout bond strength values were found with distilled water irrigation (7.21 0.50.37 MPa). NaOCl+ HEDP showed significantly higher pushout bond strength when compared with other groups (P < 0.05).

Conclusion: Irrigation with 2.5% NaOCl/9% HEDP significantly improved the pushout bond strength of Biodentine to the root canal dentin.

Key words: Biodentine, EDTA, HEDP, Pushout bond strength, Smear layer, Sodium hypochlorite

INTRODUCTION

Endodontic therapy aims at achieving long-term retention and function of the tooth. Cleaning and shaping is very important step in root canal therapy. Studies have shown that large areas of root canal walls are left untouched by hand and rotary instruments during canal preparation. This shows the importance of irrigating solutions in cleaning and disinfecting the root canal system.

Various irrigating solutions are used such as sodium hypochlorite (NaOCl), Chlorhexidine, Etidronic acid (HEDP), and hydrogen peroxide.[1]

NaOCl is one of the most accepted and widely used endodontic irrigants since 1920 as for its antibacterial activity as for its capacity of dissolving organic tissue. When NaOCl reacts with organic debris, it leads to a formation of hypochlorous acid (HOCl) which has an antimicrobial effect. HOCl disrupts the microbial metabolism within the bacterial enzyme by oxidation of sulphydryl groups present in the bacteria.[2]

Access this article online

www.ijss-sn.com

Month of Submission : 11-2021
Month of Peer Review : 12-2021
Month of Acceptance : 12-2021
Month of Publishing : 01-2022

Corresponding Author: Dr. Pooja Gandhe, Plot No 44A, Siddhakala Housing Society, Warje Pune, Maharashtra, India.

Chlorhexidine gluconate (CHX) is another endodontic irrigation solution that has been used to disinfect root canals. CHX has substantive and potent antimicrobial activity against some resistant bacteria. It has been indicated that the use of combination of NaOCl and CHX during root canal treatments decreases the bacterial load more efficiently, and this reduction is significant compared to use of NaOCl alone.[3]

Etidronic acid or 1 -hydroxyethane 1,1 -diphosphonic acid (HEDP) is a nitrogen-free bisphosphonate. An etidronate is a salt of etidronic acid, in which the anions are bound to the cations of HEDP. HEDP is a calcium chelator, averts the accumulation of smear layer and hard tissue debris. This single combined solution irrigation concept can have commendatory effects on the adhesion of various types of sealers to root dentine.[4]

The next important step after cleaning and shaping is obturation. The objective of obturation is to give a hermetic seal of the root canal system with an inert biocompatible stable filling material. Biodentine has an extensive range of applications including endodontic repair (root perforations, apexification, resorptive lesions, and root-end filling material in endodontic surgery).

Biodentine (Septodont, Saint Maur des Fosses, France) is a tricalcium silicate developed by Septodont's research group as a new range of dental cement that exhibits superior mechanical properties besides biocompatibility and bioactivity. Whenever the original dentin is damaged it is used as a dentin replacement material. Biodentine has a comparatively short setting time of around 12 min.

The pushout bond strength test estimates the bond strength of a restorative material to root canal dentin. It is a practical and reliable method to evaluate the adaptation of a material to its surrounding root canal dentin.

There are three possible mechanisms by which the bond failure can occur; cohesive, adhesive, and mixed failure. Adhesive failure occurs between the root canal dentin wall and Biodentine interface. Cohesive failure occurs within the Biodentine. Mixed failure includes both the failures between root canal dentin wall and Biodentine and failure within Biodentine.[1]

Thus, this study was planned to evaluate and compare effect of NaOCl in conjunction with etidronic acid and chlorhexidine on pushout bond strength of biodentine.

MATERIALS AND METHODS

Inclusion criteria 30 single-rooted single canal human teeth extracted for periodontal reasons devoid of any caries, endodontic treatment, or immature apices were used for the study. The presence of caries, root cracks or perforations, previous endodontic treatment, calcifications, or obstructions in the root canal morphology were excluded from the study.

Thirty single-rooted single canal extracted for periodontal reasons were selected. All soft tissue remnants on the root surface were cleaned and debris removed with the help of ultrasonic scaler and teeth were stored in distilled water until use. The samples were decoronated transversely 1 mm coronal to cementoenamel junction using diamond disc. The working length was established using 10K file until it was just visible at the apical foramen and then subtracted 1 mm from recorded length. The apices of all teeth were sealed with sticky wax to prevent the flow of irrigant through them and to allow effective reverse flow of irrigant to simulate closed-end system.

Solution preparation -sixty percent aqueous HEDP solution was obtained from a commercial source. This was mixed with ultrapure water to a resultant concentration of 9% HEDP. And this solution was mixed with 2.5% of NaOCl in 1:1 ratio to obtain a mixture of HEDP and NaOCl in a chemical laboratory.

The specimens were then divided randomly into three groups depending on irrigation regimens. Irrigation regimens

- Group A (n = 10)–control group- 5 ml distilled water used for 1min after each instrument change
- Group B (n = 10)- 5 ml 2.5% NaOCl +9% Etidronic acid (HEDP) used for 1min after each instrument change then final rinse with distilled water
- Group C (n = 10)-5 ml 2.5% NaOCl for 1 min-5 ml saline-2% chlorhexidine used for 1 min after each instrument change then final rinse with distilled water

The biomechanical preparation of all the samples was then carried out. The apical preparation was done upto #20k file. All samples were cleaned and shaped using Neoendo rotary file system up to size 20 taper 0.06. With every change in instrument irrigation was performed using a 27 gauge needle by inserting it 1mm short of working length as per the irrigation regimen. After final irrigation, Biodentine was mixed according to manufacturer's instructions and placed in canal with a hand plugger in all the samples. All the samples were then placed in 100% humidity for 1 week to allow for complete setting of biodentine. Then, each sample was divided into three parts by sectioning them horizontally using a diamond disc and a middle 3rd section of 1.5 mm thickness was obtained from each sample.

The push-out test was then performed using universal testing machine. The force was applied with a stainless steel plunger, positioned so that it contacted only the filling material until bond failure occurs. The crosshead speed was 1 mm/min.

Area-4.241 mm^2 Formula for pushout bond strength (MPa) = Pushout load (N) Area of bonded interface (sq/mm) Where Area of bonded interface (sq/mm)= $2\pi rh$ π =3.1416, r= radius of perforated cross section, h= height of perforation.

Fractographic Analysis

After testing all samples were subjected to stereomicroscopic at ×40 magnification for the evaluation of bond failures. The modes of bond failures were categorized as follows: (1) Adhesive failure between the root canal dentin wall and Biodentine interface (2) Cohesive failure within the Biodentine (3) Mixed failure.

Statistical Analysis

The level of significance was fixed at $P = 0.05$ and any value less than or equal to 0.05 was considered to be statistically significant. Chi-square analysis was used to find the significance of study parameters on categorical scale. Analysis of variance (ANOVA) was used to find the significance of study parameters between the groups (inter-group analysis). Further *post hoc* analysis was carried out if the values of the ANOVA test were significant. The Statistical software IBM SPSS statistics 20.0 (IBM Corporation, Armonk, NY, USA) was used for the analyses of the data and Microsoft Word and Excel were used to generate graphs, tables, etc.

RESULTS

On intergroup comparison, Graph 1 (NaOCl+ HEDP) showed significantly higher pushout bond strength (9.452 MPa) when compared with other groups ($P < 0.05$). Group A (Distilled water) had significantly lower pushout bond strength in comparison with the other groups (7.212 MPa) ($P < 0.05$). Group C (NaOCl + Chlorhexidine) showed significantly lower pushout bond strength (8.312 MPa) than Group A ($P < 0.05$).

Fractographic Analysis

On intergroup comparison in Graph 2, Group A, the mode of bond failure was observed to be 20% adhesive and 80% cohesive. In Group B 10% was adhesive, and 70% was cohesive and 20% was mixed. In Group C 20% was adhesive, 60% was cohesive and 20% was mixed. Overall, in all the experimental groups, adhesive failure was observed in 5 of 30 specimens (16.66%), cohesive failure in 21 of 30 specimens (70%), and mixed type of failure in 4 of 30 specimens (13.33%).

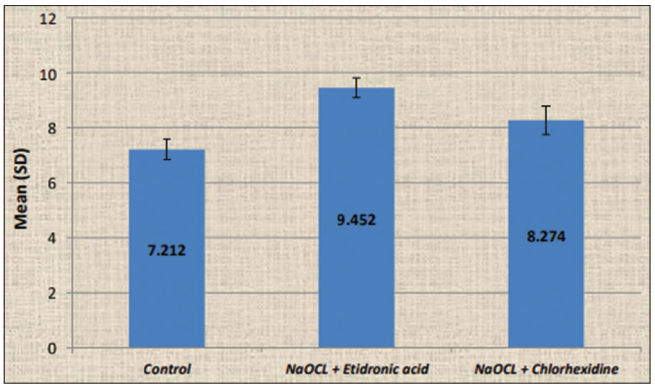

Graph 1: Intergroup comparison of push out bond strength in terms of {Mean (SD)} among all the groups using ANOVA test

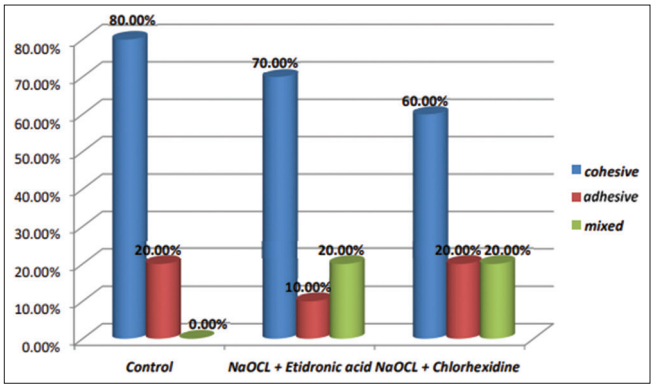

Graph 2: Intergroup comparison of fracture mode among all the 3 groups using Chi-square test

DISCUSSION

The mixture of NaOCl and HEDP has the ability to reduce the formation of smear layer during rotary root canal instrumentation to an extent similar to the standard use of NaOCl followed by EDTA while also reducing the accumulation of hard tissue debris. In addition, HEDP does not affect the dissolution activity and antimicrobial properties of NaOCl.[1]

Group A (HEDP+NaOCl) showed the highest mean push out bond strength (7.2120 MPa) which was statistically significantly higher than the Group A (control group) and Group C(NaOCl + CHX) ($P < 0.001$).

This was attributed to the fact that HEDP has no adverse effect on the hydration properties of calcium silicate cements. A 2.5% NaOCl concentration was selected because when mixed with 9% HEDP this combination has been shown to reduce the dentin debris accumulation

and to maintain the antimicrobial and tissue dissolution properties of NaOCl alone.[5]

Ulusoy *et al.* stated that there was no significant difference between the 18% HEDP and 9% HEDP in terms of elimination of the smear layer. Therefore, lower (9%) concentrations of this solution can be more safely used for root canal final irrigation to prevent the deleterious effects of high concentration.[6]

The result in the present study showed that Group C (Chlorhexidine + NaOCl) had poor pushout bond strength than Group B (NaOCl +HEDP). These results were in accordance with the results of Hong *et al.* who showed that 2% Chlorhexidine reduced the push-out strength of calcium silicate cements.[7]

This was attributed to the fact that when chlorhexidine was used as an irrigant, there was no apparent crystal structure on the surface of calcium silicate cements. The surface crystals had thin plate structures, and their size was decreased almost to one tenth. The silicon was detected along with calcium, oxygen, and carbon. It proved that they were not the typical calcium hydroxide crystals. These findings may explain why the push-out strength of the CHX groups was significantly reduced.[8]

In the present study Group A showed the least pushout bond strength than Group B and Group C. The possible reason might be that the calcium silicate cements set via hydration reaction. When they are used for endodontic purpose, the hydraulic cements adherence with the surrounding dentin is necessary. Thus, during the setting reaction water availability for calcium-silicate cements plays an important role in determining the final strength of the completely set material. Thus, biodentine in the control group showed reduced push–out bond strength.[9]

However, Graph B showed the distribution of failure rates. Analysis of the mode of bond failure showed 70% cohesive type of bond failure. This may be attributed to the good adhesion of Biodentine to the root canal walls because the size of the particles is finer compared to other calcium silicate cements, which, in turn, enhances the infiltration of the cement into the dentinal tubules.[10]

When Biodentine gets exposed to NaOCl, it increases the size and number of calcium hydroxide crystals and also releases calcium. Thus, building up of calcium hydroxide enhances the pH of Biodentine resulting in greater sealing ability of the material.[11]

Singh *et al.* showed that calcium and silicon ion uptake into dentin leading the formation of tag-like structures in Biodentine was higher than MTA.[12]

This vitro study has limitations, as the tests were carried out in single-rooted teeth, with specific dimensions, under a static compressive loading applied at a single point and at a fixed angulation. Thus, dynamic or fatigue behavior cannot be inferred. The ultimate clinical decision-making should also consider patient-related variables such as occlusion, masticatory force, and parafunctional habits, to maximize the long-term prognosis.

CONCLUSION

Within the limitations of this *in vitro* study, it can be concluded that -The pushout bond strength of biodentine was differentially influenced by the various irrigation regimens. –The use of the combination of 2.5% NaOCl/9% HEDP for 1 min enhanced the bond strength of Biodentine to the root canal dentin compared to the use of 2.5% NaOCl and 2% chlorhexidine. Analysing the modes of failure of these resin cements it can be concluded that Biodentine showed good adhesion to the root canal walls, proving its better efficiency clinically.

REFERENCES

1. Paulson L, Ballal NV, Bhagat A. Effect of Root dentin conditioning on the pushout bond strength of biodentine. J Endod 2018;44:1186-90.
2. Niyas FM, Subbarao C. Effectiveness of sodium hypochlorite and etidronic acid in combination as a root canal irrigant with varying apical preparation sizes-an *in vitro* analysis. J Pharm Sci Res 2017;9:716-8.
3. Homayouni H, Majd NM, Zohrehei H, Mosavari B, Adel M, Dajmar R, *et al.* The effect of root canal irrigation with combination of sodium hypochlorite and chlorhexidine gluconate on the sealing ability of obturation materials. Open Dent J 2014;8:184-7.
4. Zollinger A, Mohn D, Zeltner M, Zehnder M. Short-term storage stability of NaOCl solutions when combined with dual rinse HEDP. Int Endod J 2017;51:691-6.
5. Morago A, Ordinola-Zapata R, Ferrer-Luque CM, Baca P, RuizLinares M, Arias-Moliz MT. Influence of smear layer on the antimicrobial activity of a sodium hypochlorite/etidronic acid irrigating solution in infected dentin. J Endod 2016;42:1647-50.
6. Ulusoy Öİ, Zeyrek S, Çelik B. Evaluation of smear layer removal and marginal adaptation of root canal sealer after final irrigation using ethylenediaminetetraacetic, peracetic, and etidronic acids with different concentrations. Microsc Res Tech 2017;80:687-92.
7. Hong ST, Bae KS, Baek SH, Kum KY, Shon WJ, Lee W. Effects of root canal irrigants on the push-out strength and hydration behavior of accelerated mineral trioxide aggregate in its early setting phase. J Endod 2010;36:1995-9.
8. Guneser MB, Akbulut MB, Eldeniz A. Effect of various endodontic irrigants on the push-out bond strength of biodentine and conventional root perforation repair materials. J Endod 2013;39:380-4.
9. Banu MA. Effect of Sodium Hypochlorite on the Pushout Bond Strength of Biodentine and Endosequence Bioceramic Root Repair Material on Furcal

Perforation: An *In Vitro* Study. Tiruchengode: Masters Thesis, K.S.R. Institute of Dental Science and Research; 2018.
10. Malkondu Ö, Karapinar Kazandağ M, Kazazoğlu E. A review on biodentine, a contemporary dentine replacement and repair material. Biomed Res Int 2014;2014:160951.
11. Adl A, Sobhnamayan F, Sadatshojaee N, Azadeh N. Effect of blood contamination on the push-out bond strength of two endodontic biomaterials. J Res Dent 2016;4:59-63.
12. Singh S, Podar R, Dadu S, Kulkarni G, Vivrekar S, Babel S. An *in vitro* comparison of push-out bond strength of biodentine and mineral trioxide aggregate in the presence of sodium hypochlorite and chlorhexidine gluconate. Endodontology 2016;28:42.

How to cite this article: Gandhe P, Gaikwad A, Pandit V, Sengupta A, Deshmukh P. Comparative Evaluation of Pushout Bond Strength of Biodentine after Root Dentin Conditioning with Different Irrigating Solutions- An *In Vitro* Study. Int J Sci Stud 2022;9(10):28-32.

Source of Support: Nil, **Conflicts of Interest:** None declared.

Print ISSN: 2321-6379
Online ISSN: 2321-595X

Original Article

Role of Sliding Transposition Flap in Coverage of Soft Tissue Defects of Leg: An Experience of 50 Cases

Sharma Samira[1], Bhandari Mrinal[2], Gupta Arshiya[3]

[1]Associate Professor and Head, Department of Plastic Surgery, Government Medical College, Amritsar, Punjab, India, [2]MBBS Intern, Department of Surgery , Government Medical College, Patiala, Punjab, India, [3]MBBS Student, Government Medical College, Amritsar, Punjab, India

Abstract

Introduction: Lower limb defects are frequently the result of trauma, tumors, or chronic illnesses. The small defects can even become problematic in leg because of thin and nonexpendable soft tissue requiring reconstruction in the form of flap cover. The procedure selected should be simple, easily performed in short duration by esthetic way and leave minimum donor site morbidity. The sliding transposition flap is selected for providing soft tissue cover for the leg defects in this study.

Aims: The aim of this article is to study the usefulness of sliding transposition flap in the soft tissue defects of upper, middle, and lower 1/3rd of the leg.

Materials and Methods: A retrospective study was conducted on 50 patients between Jan 2015 and Dec 2019 having leg defects as a result of trauma, electric burns, implant exposure, or chronic osteomyelitis. Etiology, site and size of defect were recorded. Patients underwent sliding transposition flap. Post-operatively patients were followed for any flap-related complication till the wound cover became stable.

Results: The aetiology was trauma in 90%, osteomyelitis in 6% and electric burns in 4% patients. In 24 % of patients, implant was exposed. 56% patients had soft-tissue defect in the lower 1/3rd and all of them required inferiorly based sliding transposition flap cover. Flaps survived well in all the patients. Donor sites healed well.

Conclusion: The sliding transposition flap is a very easy and safe option for covering small leg defects.

Key words: Leg defects, Reconstruction, Sliding transposition flap, Trauma

INTRODUCTION

Lower limb trauma requiring soft tissue coverage comprises a significant proportion of these injuries worldwide. Reconstruction of the soft tissues overlying fractures is essential for bone union.[1] Due to limited mobility and a paucity of overlying skin, even small defects of the lower limb generally need flap coverage.[2]

Nowadays with so many options available in the form of numerous local as well as free flaps, reconstruction of a lower limb defect may not be difficult however making choice which method to be used is difficult. A flap that is perfect in a particular situation may prove to be the worst for another situation. The size, site and the type of defect, condition of the surrounding tissues, age, and general condition of the patient are the deciding factors for flap selection along with the experience, education, and resources of the operating surgeon.[3]

Sliding transposition flap for leg defects was first of all described by Harrison and Saad.[4] A basic but neglected factor that has been responsible for the large percentage of failed flaps in the legs is convexity of its surface. Therefore the standard transposition flap across the convex surface of the leg results in transverse tension across the pedicle and embarrassment of its blood supply. Use of sliding transposition flap in the leg obviates the transverse tension.[5]

This paper presents our study conducted retrospectively with sliding transposition flaps while managing the leg

Access this article online

www.ijss-sn.com

Month of Submission : 11-2021
Month of Peer Review : 12-2021
Month of Acceptance : 12-2021
Month of Publishing : 01-2022

Corresponding Author: Dr. Sharma Samira, Department of Plastic Surgery,Government Medical College, Amritsar-143001, Punjab,India.

defects due to trauma, electric burns, or as a result of osteomyelitis.

Aims

The aim of this article is to study the usefulness of sliding transposition flap in the defects of upper, middle, and lower 1/3rd of the leg.

MATERIALS AND METHODS

After taking approval from the institutional ethical committee (Vide letter no GMC/IEC/21/SS/46 Dated3/11/2021), a retrospective study was conducted on 50 patients, operated during the period of Jan 2015 to Dec 2019 in a tertiary care hospital in Punjab. The records of all these patients were reviewed in detail. The patients included in the study had soft tissue defects of the leg in the form of exposed bone or fracture site as a result of trauma, electric burn or osteomyelitis, and exposed implant. The soft tissue defects of 3–5 cm size were included in the study. The larger defects and those with degloving or crushing of the surrounding skin were not included in the study. The defects were divided into three categories, upper 1/3rd, middle 1/3rd, and lower 1/3rd of the leg. All patients after thorough examination had undergone routine and special investigations if any (CBC, RFTs, LFTs, and viral markers). The surgery was done under spinal anesthesia in all these cases.

In all patients, the sliding transposition flap[5] was marked on the medial or lateral side, based inferiorly or superiorly depending on the location of the defect. The Posterior Tibial or Peroneal artery perforators were incorporated in the flap base wherever possible by marking the flap over the expected location of perforators. The width of the flap was marked equal to the length of the defect.

In all the patients the dissection of the flap had been done in the sub-fascial plane. The length: breadth ratio was from 2:1 to 3:1. In all the patients the donor area was grafted with a split skin graft harvested from the thigh. The primary dressing was done on 5th post-operative day. Sutures and staplers were removed after 7 days [Figures 1-3]. All patients were followed biweekly for 3 weeks. The record was maintained till the soft tissue cover became stable. Fracture healing or bony union was not a part of this study.

RESULTS

Out of total 50 patients, 46 (92%) were male and 4 (8%) were female. The age ranged from 18 to 78 years with an average of 44.5 years. Tibia was the involved bone in all the patients. The etiology was trauma in 45 patients (90%), osteomyelitis in 3 patients (6%), and electric burns in 2 patients (4%). The 32 patients (64%) had exposed fracture site of the tibia, 6 (12%) had exposed non-fractured tibia and in 12 patients (24%) implant was exposed. The size of defect ranged from 3 cm to 5 cm. The upper 1/3rd of the tibia was involved in 8(16%), middle 1/3rd in 14 (28%), and lower 1/3rd in 28 patients (56%). The flap was raised from the medial side in 28 (56%) and from the lateral side in 22 patients (44%). The flap was superiorly based in 19 (38%) and inferiorly based in 31patients (62%) [Figures 4 and 5].

In all the patients of lower 1/3rd defects inferiorly based flap was done. The operative time ranged from 30 min to 45 min with a mean of 38 min.

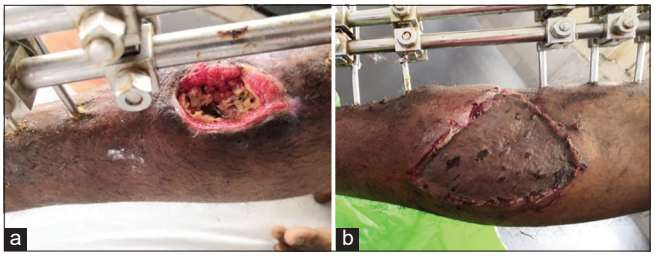

Figure 1: A case of posttraumatic soft tissue defect middle 1/3rd of leg covered with medial inferiorly based sliding transposition flap (a) pre-operative (b) post-operative day 7

Figure 2: A case of post osteomyelitis soft tissue defect upper 1/3rd legcovered with lateral superiorly based sliding transposition flap (a) pre-operative (b) post-operative day 7

Figure 3: A case of exposed implant lower 1/3rd legcovered with medial inferiorly based sliding transposition flap (a) pre-operative (b) post-operative day 7 (c) post- operative day 21

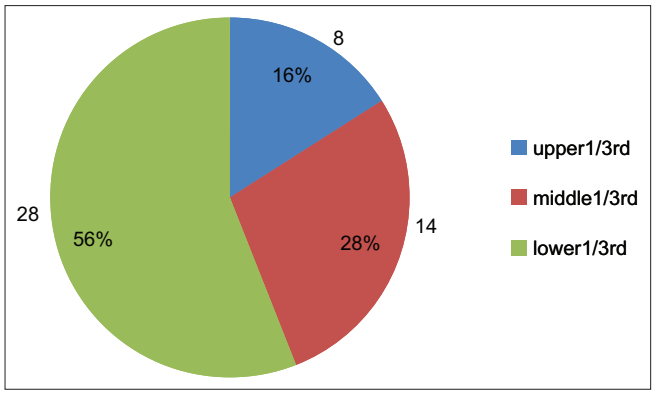

Figure 4.distribution of patients with respect to the site of the defect

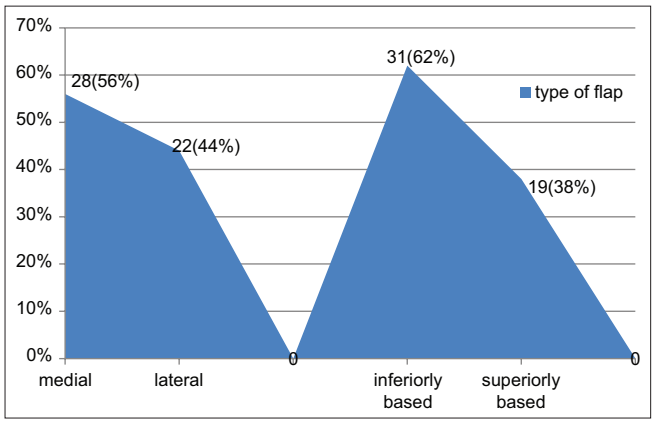

Figure 5: Distribution of patients with respect to the type of flap

All the flaps healed well. There was no necrosis or graft loss seen in any of the patients. There was no donor area morbidity in any of the patients.

DISCUSSION

There is a wide variety of flaps available for the reconstruction of soft tissue defects overlying the tibia. The leg is divided into proximal third, middle third, and lower third for the purpose of selection of the type of reconstruction procedure required. The type of reconstruction required depends on the site, size as well as condition of the surrounding skin. The large defects with extensive surrounding crushing can no doubt be managed by free flap tissue transfer only but a large proportion of the rest is successfully managed by local muscle, fasciocutaneous, or cross leg flaps. The local fasciocutaneous flaps have the advantage of low donor site morbidity when used for the coverage of lower limb defects. The fasciocutaneous flaps for the leg were first of all described by Ponten.[6] The inclusion of fascia in the flap increased its blood supply via direct cutaneous, musculocutaneous, and septocutaneous perforators thus making the flap more viable along with improving the length breadth ratio of the flap. With the incorporation of 2–3 sizable perforators in the pedicle of the flap a nonconventional long flap can be designed with safety.[7] Plastic surgery armamentarium for leg defect reconstruction is full of innumerable fasciocutaneous flaps. In addition to the traditional fasciocutaneous flaps there is bipedicle flap,[8] keystoneflap,[9] v-y advancement flap[10] and other perforator based flaps.[11]

In their earlier studies, Harrison and Saad did not include fascia in the sliding transposition flap described by them and it was included in their later series after the description of fasciocutaneous flap by Ponten in 1981. In our findings, 50 sliding transposition flaps were raised covering all regions of the leg. Fascia was included in all the flaps. The decision of raising the flap on the medial or lateral side had been based on skin condition, skin laxity, and a preference to include perforators of Posterior Tibial and Peroneal artery in the flap base. Out of inferiorly based or superiorly based whichever flap seemed more feasible was harvested. In the lower 1/3rd, all the flaps harvested were inferiorly based because of the anatomical shape of the leg. Success was defined as ability to transpose flaps to cover defects without tension. None of our patients had even marginal necrosis.

We included small defects up to 5 cm only in our study. However, sliding transposition flap can cover bigger defects also if we divide the defect into two parts and plan to raise two small flaps from each side of the leg. Patients with degloving injuries were not included in the study. The presence of degloving or crushing around the wound will need other options for wound coverage.

CONCLUSION

The sliding transposition flap is a very easy and safe option for covering the small leg defects.

REFERENCES

1. Khundkar R. Lower extremity flap coverage following trauma. J Clin Orthop Trauma 2019;10:839-44.
2. Godina M. Early microsurgical reconstruction of complex trauma of the extremities. Plast Reconstr Surg 1986;78:285-92.
3. AlMugaren FM, Pak CJ, Suh HP, Hong JP. Best local flaps for lower extremity reconstruction. PRS Glob Open 2020;8:e2774.
4. Harrison SH, Saad MN. The sliding transposition flap: Its applications to leg defects. Br J Plast Surg 1977;30:54-8.
5. Harrison SH, Saad MN. The sliding transposition flap. In: Staunch B, Vasconez LO, Hall-Findley ED, editors. Grabb's Encyclopedia of Flaps. 2nd ed., Ch. 440. Philadelphia, PA: Lippincott-Raven; 1998. p. 1717-9.
6. Ponten B. The fasciocutaneous flap: Its use in soft tissue defects of the lower leg. Br J Plast Surg 1981;34:215-20.
7. Bhattacharya V, Watts RK. Ipsilateral fasciocutaneous flaps for leg and foot

defects. Indian J Plast Surg 2003;36:30-5.
8. Granzow JW, Li A, Suliman A, Caton A, Goldberg M, Boyd JB. Bipedicle flaps in posttraumatic lower extremity reconstruction. J Plast Reconstr Aesthet Surg 2013;10:1415-20.
9. Rao AI, Janna RK. Keystone flap for reconstruction of limb defects. J Clin Diagn Res 2015;9:5-7.
10. Niranjan NS, Price RD, Govilkar P. Fascial feeder and perforator based v-y advancement flaps in the reconstruction of lower limb defects. Br J Plast Surg 2000;53:679-89.
11. Wong CH, Tan BK. Perforator sparing Transposition flaps for Lower limb defects: Sanatomical study and clinical application. Ann Plast Surg 2007;58:614-21.

How to cite this article: Samira S, Mrinal B, Arshiya G. Role of Sliding Transposition Flap in Coverage of Soft Tissue Defects of Leg: An Experience of 50 Cases. Int J Sci Stud 2022;9(10):33-36.

Source of Support: Nil, **Conflicts of Interest:** None declared.

Print ISSN: 2321-6379
Online ISSN: 2321-595X

Original Article

Comparative Study of the Influence of Instrument Taper on the Fracture Resistance of Endodontically Treated Teeth Using Hand and Rotary Files

Anandita Sengupta[1], Varsha Pandit[2], Ashwini Gaikwad[3], Pooja Gandhe[1]

[1]MDS, Department of Conservative Dentistry and Endodontics, Bharati Vidyapeeth Dental College and Hospital, Pune, Maharashtra, India, [2]Assoscite Professor and MDS, Department of Conservative Dentistry and Endodontics, Bharati Vidyapeeth Dental College and Hospital, Pune, Maharashtra, India, [3]Professor and MDS, Department of Conservative Dentistry and Endodontics, Bharati Vidyapeeth Dental College and Hospital, Pune, Maharashtra, India

Abstract

Aim: To evaluate and compare the influence of instrument taper on the fracture resistance of endodontically treated teeth with hand, twisted, and protaper rotary files.

Materials and Methods: All teeth were sectioned at 13mm from the anatomic apex using a diamond-coated bur under water cooling and then were allocated to four groups. Instrumentation was done in the four groups with respective files, following the manufacturer's protocol. During instrumentation, the root canal was irrigated with 2.5% sodium hypochlorite (NaOCl) solution. After instrumentation, a final irrigation procedure was done using 5 ml distilled water, and roots were obturated using single cone technique with gutta percha and AH plus as the canal sealer. The roots were then placed in acrylic blocks in order to create an artificial periodontal ligament. All specimens were tested with a universal testing machine until the root fracture occurred.

Conclusion: Teeth instrumented with 2% hand K files has the highest fracture resistance followed by teeth instrumented with 4% taper Twisted files (TFs), 6% taper TFs and 6% taper ProTaper files.

Key words: Endodontic treatment, Fracture resistance, Rotary files

INTRODUCTION

Root canal therapy is the most thorough and perfect method for the endodontic and periapical disease. Root canal preparation is the key procedure for root canal therapy.[1] Root canal procedure comprises of three intricate processes, first, the access opening, second, cleaning and shaping, disinfection, and third, obturation of the root canal space. Out of the 3 processes, cleaning and shaping procedures are of paramount importance as it is responsible for the eradication of microorganism with the help of irrigants and for subsequently shaping it so that the canal is adequately obturated by an inert filling material.[2] However, many studies showed that the teeth after root canal therapy may have an inclination towards longitudinal fracture in the tooth root. There was a close correlation between the degree of root canal preparation and tooth resistance to fracture.[3] Stainless steel root canal instruments clean the canal superficially and can create canal aberrations such as ledges, zips, and elbows. To eliminate these shortcomings of stainless steel instruments, nickel-titanium (Ni-Ti) instruments have been developed.[4] Using NiTi engine-driven instruments for root canal preparation has become the fundamental of endodontic treatments.[5] These instruments have many advantages such as less operation time, increased cleanliness of root canal walls, and fewer procedural accidents (apical canal transportation, perforations and ledges). These properties mostly stem from the increased flexibility of NiTi alloy which helps in the preservation of root canal curvatures. However, it is stated that engine-driven instruments may damage root dentin by forming craze lines and microcracks. During root canal preparation, thinned dentinal walls and increased

Access this article online

www.ijss-sn.com

Month of Submission : 11-2021
Month of Peer Review : 12-2021
Month of Acceptance : 12-2021
Month of Publishing : 01-2022

Corresponding Author: Dr. Anandita Sengupta, Department of Conservative Dentistry and Endodontics, Bharati Vidyapeeth Dental College and Hospital, Pune, Maharashtra, India.

strain can lead to microcrack formation especially at the apical area.[6]

Introduction 2 Technological innovations in rotary NiTi files have led to new concepts of root canal instrumentation including an increased taper of preparation.[7] A higher taper of mechanical preparation offers sufficient enlargement of the root canal entailing better removal of debris and smear layer, improvement of irrigant flow, and better distribution of stresses during both lateral and vertical gutta-percha compaction. However, possible excessive removal of dentin raised concerns regarding the susceptibility of roots to fractures.[8] Although multiple factors contribute to file separation, cyclic fatigue has been shown as one of the leading causes. Fatigue failure usually occurs by the formation of microcracks at the surface of the file that starts from surface irregularities often caused by the grinding process during the manufacturing.[9] During each loading cycle microcracks develop, propagating getting deeper in the material, until complete separation of the file occurs. All endodontic files show some irregularities on the surface, and inner defect, as a consequence of the manufacturing process, and distribution of these defects influence fracture strength of the endodontic instruments.[10]

Vertical root fracture (VRF) is a complication in both endodontically and non endodontically treated teeth, usually leading to extraction. Predisposing factors for root fractures have been discussed thoroughly in the literature, and various classifications have been proposed.[11] Mechanical preparation affects both the geometry and volume of root canals, leading to stresses to the root dentin leading to, dentinal defects. The root canal preparation instruments and methods used combined might all be involved in the increased risk for root fracture during and subsequent to root canal treatment.[12] Introduction 3 Many factors can contribute to VRFs, thus making the assessment of their individual contributions challenging, especially when measured under *in vitro* experimental conditions. Previous studies have attempted to compare the susceptibility to fractures of endodontically treated teeth that were instrumented with hand and Rotary Instruments of Different Tapers. Methodologic Limitations Concerning Both The standardization and randomization of the sample combined with the instrumentation and experimental techniques used have produced a variety of results.[13] ProTaper (Dentsply Maillefer, Ballaigues, Switzerland) is amongst the pioneer engine-driven instruments that employ full 360° rotation with a convex triangular cross-section and multiple tapers within the shaft. The ProTaper Universal (PTU) system is comprised shaping (SX, S1, and S2) and finishing (F1, F2, and F3) instrument. PTU rotary files, which have been used for years, that enable an active cutting motion and the removal of relatively more dentin coronally. PTU rotary files are made from a conventional superelastic NiTi wire. In previous studies, the PTU system was associated with more cracks than other rotary NiTi instrument.[14] Recently, a new system has been introduced called Twisted File Adaptive (TF Adaptive) (Axis/Sybron Endo, Orange, CA). TF design increases flexibility and allows the file to be adjusted to intracanal torsional forces.[15]

The objective of this study was to examine the influence of instrument taper on the fracture resistance of endodontically treated roots, using hand and rotary files (protaper and twisted) under *in vitro* experimental conditions.

MATERIALS AND METHODS

Forty human maxillary single-rooted mandibular premolars extracted for periodontal reasons were selected for this *in vitro* study [Figure 1]. Samples were collected from the department of oral and maxillofacial surgery, Bharati Vidyapeeth Deemed University Dental College and Hospital, Pune. A consent form along with subject information sheet was given to parents/patients explaining the entire procedure. Identity of all the patients was kept confidential. Strict anonymization was observed while collecting the teeth. After extraction, the soft tissues, dental calculus, and stains were immediately removed from the teeth. The teeth were stored in distilled water until the time they were intentionally fractured.

Inclusion Criteria

Single rooted, single canal extracted teeth with sound roots, extracted because of periodontal or orthodontic reasons.

Exclusion Criteria

- Presence of caries
- Presence of roots cracks or perforations.

Figure 1: Single rooted single canal mandibular premolars were collected

Sample Preparation

All teeth were sectioned at 13 mm from the anatomic apex using a diamond coated bur [Figure 2] under water cooling and then were allocated to 4 groups. Instrumentation was done in the four groups with respective files, following the manufacturer's protocol. During instrumentation, the root canal was irrigated with 2.5% sodium hypochlorite (NaOCl) solution. After instrumentation, a final irrigation procedure was done using 5 ml distilled water, and roots were obturated using single cone technique with gutta percha and AH plus as the canal sealer. The roots were then placed in acrylic blocks in order to create an artificial periodontal ligament. All specimens were tested with a universal testing machine until the root fracture occurred.

Experimental groups

The selected teeth were randomly divided into four groups of 10 [Figure 3] each based on the files used. Group-I Hand Instruments (2% TAPER):

- Group-II TFs (4% TAPER)
- Group-III TFs (6% TAPER)
- Group-IV Protaper Files (6% TAPER) [Table 1].

Fracture Testing

All the samples were subjected to testing using Universal Testing Machine [Figure 4]. The roots were tested with a universal testing machine. A steel conical tip tapered at 60° was aligned with the center of the canal orifice of each specimen. Force was applied with 1-mm/min crosshead speed until root fracture occurred. The load necessary to cause fracture was recorded in Newton.

Statistical Analysis

Descriptive and inferential statistical analyses were carried out in the present study. Results on continuous measurements were presented on Mean SD. The level of significance was fixed at $P = 0.05$ and any value ≤ 0.05 was considered to be statistically significant. Analysis of variance (ANOVA) was used to find the significance of study parameters between the groups (Intergroup analysis). Further post hoc analysis was carried out if the values of the ANOVA test were significant.

The Statistical software IBM SPSS statistics 20.0 (IBM Corporation, Armonk, NY, USA) was used for the analyses of the data and Microsoft Word and Excel were used to generate graphs, tables, etc.

Table 1: Experimental groups

Groups	Instruments	Sample
Group 1	Hand instruments (2% Taper)	10
Group 2	Twisted Files (4% Taper)	10
Group 3	Twisted Files (6% Taper)	10
Group 4	Protaper Files (6% Taper)	10

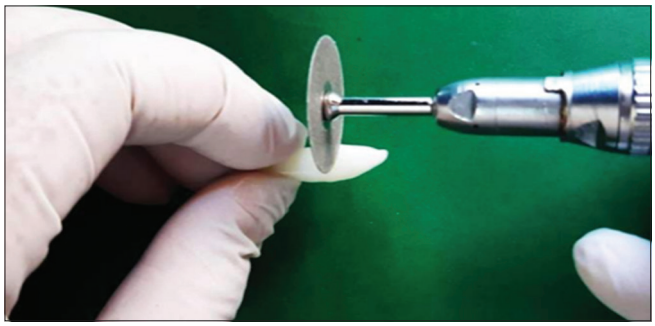

Figure 2: Samples were decoronated with a diamond disc

RESULTS

Group I has a statistical significant difference between Group II, III, and IV.

- When Group II was compared with Group IV, it was seen to have statistically significant difference
- When Group II was compared with Group III, it was seen to have no statistically significant difference



Figure 3: Samples were randomly divided into 4 groups



Figure 4: Sample subjected under universal testing machine after mounting on an acrylic block

- When Group III was compared with Group II and Group IV, there was statistical significant difference with Group IV whereas there was no statistical significant difference with Group II [Graph 1].

DISCUSSION

The main objective of root canal treatment is to shape and clean the root canal system effectively by maintaining original configuration of the canal. It also aims to create tapered funnel preparation with increase in diameter to facilitate effective irrigation and three-dimensional obturation of root canal space. However, possible excessive removal of dentin raised concern for susceptibility of root fractures.[16]

VRF is a complication in endodontically treated teeth leading to extraction. Removal of caries, access cavity preparations and canal instrumentation techniques, diameter of prepared canals are the predisposing factors for VRFs.[1]

Rotary nickel-titanium files safety and efficiency are collectively determined by design of file, the manner in which the file is used and the method of manufacturing. Excessive taper can result in excessive removal of dentin and weakening of the root.[17]

In recent decades, advances in rotary nickel-titanium instruments have led to new design concepts for better root canal shaping and success. Working with NiTi engine-driven instruments for biomechanical preparation of the root canal has become the fundamental of today's endodontic treatments. These instruments have many benefits including less operating time, less procedure-related accidents, and increased cleanliness of root canal walls. They are being increasingly used as they cause less fatigue to the dentist and make the procedure less time intensive.[2]

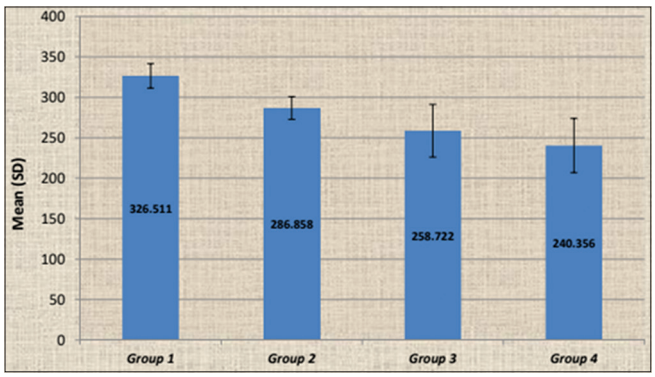

Graph 1: Mean values of fracture load of the 4 groups

Research data suggests that in the formation of dentinal fractures, shape, and taper of the files as influencing factors could play an important role. Crack formation in the walls of the root canal is of utmost concern during the use of rotary systems and it can further lead to VRF and adversely affect the prognosis of the tooth in the long run and this kind of fracture is one of the annoying complications of root canal treatment leading to extraction of tooth in most of the cases.[18] Bier *et al.* have also reported that fractures do not occur immediately after preparation of canal. Although, craze lines (4% to 16%), might develop into fractures during retreatment or after long term functional stresses such as chewing and misbalanced occlusal forces.[19]

Resistance to tooth fracture is an important aim in endodontics because such fractures may decrease the long-term survival rate. Experimental studies have shown that excessive removal of dentin during root canal preparation, post space preparation, and obturation procedures with spreader can create fractures in teeth.[13,15]

Whether hand or rotary instrumentation is used, it must be kept in mind that all canal instrumentation techniques will inevitably weaken the root structure. The present study compared the fracture resistance of teeth instrumented with different tapered NiTi files, i.e., 6% protaper, 4% and 6% TFs, and 2% hand files. In this present study, 40 standardized samples, i.e., 40 single-rooted human extracted premolars were used because they are more prone to fracture. They were mounted in acrylic socket to simulate periodontal ligament. The 40 samples were divided into four groups (n = 10) Group I: instrumented with 2% tapered hand files Group II: instrumented with 4% tapered TF Group III: instrumented with 6% tapered TF Group IV: instrumented with 6% tapered TF.

The use of hand and TFs in this study has compared a similar instrument design with an engine-driven mode and on hand use. The study included protapers so that it provided an opportunity to compare a nonstandard tapered "ProTaper" instrument with a standard tapered instrument. The gold standard of comparison in the study was with that of time tested conventional ISO standard 0.02 tapered K-files.

TF is recently developed to enhance super elasticity and provide superior mechanical properties. The TF Adaptive technique consists of 3 files This instrument can change to a reciprocation mode, with specifically designed clockwise and counterclockwise angles that vary from 600 to 0 up to 370 to 50. Depending on the amount of pressure placed on the file, the manufacturer claims that this adaptive technology TF design increase flexibility and allow the file to be adjusted to intracanal torsional forces.[20]

Compared to other systems, the protaper file demonstrates completely new design features. The following innovations characterize the ProTaper system: (1) Progressive taper (2) Modified guiding tip (3) Varying tip diameters (4) New cross section of the instruments (5) Varying helical angel and pitches. One of the main unique design features of ProTaper is varying taper within one file ranging from 3.5% to 19% which makes it possible to shape specific sections of the root canal with one file.[21]

In this study, roots were obturated using single cone technique with gutta percha and AH plusas the canal sealer. Gutta percha was used as it is by far the most popular and commonly used root canal filling material. AH plus was used in this study as it has good apical sealing ability. In this study, all the samples mounted in acrylic blocks were subjected to testing in universal testing machine until root fracture occurred Force was applied with 1-mm/min crosshead speed until root fracture occurred. The load necessary to cause fracture was recorded in Newton. Graph 1 shows the mean values of fracture load of the 4 groups and it was observed that Group I (2% taper hand instruments) showed highest fracture resistance followed by Group II (4% taper TFs), Group III (6% taper TFs) and the least was shown by Group IV (6% taper protaper files). The values thus obtained were analyzed statistically. ANOVA was used to find the significance of study parameters between the groups (Intergroup analysis). The $P < 0.001$**, which means one or more groups are statistically highly significant, i.e., there is statistical significant difference between the groups. Further *post-hoc* analysis was carried out since the values of the ANOVA test were significant. When Group I was compared with the other three groups, it was seen to have statistical significant difference with Group II (0.007), Group III (<0.001), and Group IV (0.001). In this study, it was observed that samples instrumented with hand K files (Group I), showed higher fracture resistance than the samples instrumented with rotary twisted (Group II and III) and ProTaper files (Group IV), which was in accordance with most of the studies. In this present study, conventional hand instrumentation with 2% taper K files must have weakened the roots least when compared to the other groups. In many studies, it was found out that hand instrumentation with 0.002 tapered K files removed least amount of dentin at all levels as compared to other files. Previous studies also showed that canals prepared with conventional hand instrumentation techniques using 0.002 tapered instruments left more RDT, which provided strength to the roots than various rotary NiTi instruments. This is in concurrence with earlier studies by Zandbiglari *et al.*, Wilcox *et al.*, McCann *et al.*, and Katz and Tamse *et al.* They had compared the force required to fracture uninstrumented and instrumented teeth with rotary and hand files and concluded that engine-driven rotary instrumentations tend to weaken the roots more.[22-25] When Group II (4% taper TFs) was compared with Group III (6% taper TFs), no statistical significant difference was seen (0.083), which can be attributed to the same file design and kinematics which was in accordance with the studies conducted by Krikeli *et al.*, and Singla *et al.* Krikeli *et al.* had compared Mtwo rotary files while Single *et al.* had compared Profile files of different taper, i.e., 0.002,0.004 and 0.006 and found out that the highest fracture resistance was shown by 0.002, followed by 0.004 and least by 0.006 which was similar to the results of our study.[1,26] However, Group II had statistically significant difference when compared with Group IV (6% taper ProTaper files) (<0.001), which were instrumented with 6% protaper file which was in accordance with the studies of Wilcox *et al.* and Zandbiglari *et al.* which emphasized that fracture resistance was related to how much dentin was removed during canal preparation and concluded that the more root dentin was removed, the more likely a root was to fracture.[22,23] When Group III (6% taper TFs) was compared with Group IV (6% taper ProTaper), no statistically significant difference (0.386) was seen which can be attributed to the same taper size and approximately same amount of dentin removal which led to no statistical significant difference when compared for fracture resistance. In a study done by Yoshimine *et al.*, it was observed that ProTaper instrumentation caused greater widening of canals with increased tendency to ledge or zip formation compared to other files.[27] During instrumentation, root canal geometry is formed by various momentary contacts between the files and the dentinal walls. These contacts induce stresses on the canal walls, producing dentinal defects that can increase the susceptibility of the tooth to fracture. The level of these contact stresses depends on the mechanical behavior of the files, something mainly determined by their cross-sectional and longitudinal design, torque settings, number of rotations, and kinematic.[28,29] From the results of this present study it can be concluded that teeth instrumented with 2% tapered hand instruments have the highest fracture resistance followed by 4% tapered TFs and 6% tapered TF and the least by 6% tapered ProTaper files. Nonetheless, under clinical conditions, both tooth pathology and root canal anatomy should be taken into consideration when the apical size and taper of preparation are chosen. The cleaning efficacy of root canal instrumentation and the resultant vertical fracture strength of the roots are two parameters contributing to the success of root canal treatment. Moreover, specimen preparation and the direction of the force applied in this study are different from the clinical conditions.[1,30]

CONCLUSION

Within the limitations of this *in vitro* study, it can be concluded that Teeth instrumented with 2% hand K files have the highest fracture resistance followed by teeth

instrumented with 4% taper TFs, 6% taper TFs, and 6% taper ProTaper files.

REFERENCES

1. Krikeli E, Mikrogeorgis G, Lyroudia K. *In vitro* comparative study of the influence of instrument taper on the fracture resistance of endodontically treated teeth: An integrative approach-based analysis. J Endod 2018;44:1407-11.
2. Rundquist BD, Versluis A. How does canal taper affect root stresses? Int Endod J 2006;39:226-37.
3. Lam PP, Palamara JE, Messer HH. Fracture strength of tooth roots following canal preparation by hand and rotary instrumentation. J Endod 2005;31:529-32.
4. Kishen A. Mechanisms and risk factors for fracture predilection in endodontically treated teeth. Endod Top 2006;13:57-83.
5. Tang W, Wu Y, Smales RJ. Identifying and reducing risks for potential fractures in endodontically treated teeth. J Endod 2010;36:609-17.
6. Pawar AM, Barfiwala D, Pawar M, Metzger Z, Kfir A, Jain N. Assessment of the fracture resistance of teeth instrumented using 2 rotary and 2 reciprocating files versus the self-adjusting file (SAF): An *ex vivo* comparative study on mandibular premolars. J Conserv Dent 2016;19:138-42.
7. Kim HC, Lee MH, Yum J, Versluis A, Lee CJ, Kim BM. Potential relationship between design of nickel-titanium rotary instruments and vertical root fracture. J Endod 2010;36:1195-9.
8. Çiçek E, Aslan MA, Akkoçan O. Comparison of the resistance of teeth instrumented with different nickel-titanium systems to vertical root fracture: An *in vitro* study. J Endod 2015;41:1682-5.
9. Lertchirakarn V, Palamara JE, Messer HH. Patterns of vertical root fracture: Factors affecting stress distribution in the root canal. J Endod 2003;29:523-8.
10. Mahran AH, AboEl-Fotouh MM. Comparison of effects of ProTaper, HeroShaper, and gates Glidden burs on cervical dentin thickness and root canal volume by using multislice computed tomography. J Endod 2008;34:1219-22.
11. Castelló-Escrivá R, Alegre-Domingo T, Faus-Matoses V, Román-Richon S, Faus-Llácer VJ. *In vitro* comparison of cyclic fatigue resistance of ProTaper, WaveOne, and twisted files. J Endod 2012;38:1521-4.
12. Boutsioukis C, Gogos C, Verhaagen B, Versluis M, Kastrinakis E, van der Sluis LW. The effect of root canal taper on the irrigant flow: Evaluation using an unsteady computational fluid dynamics model. Int Endod J 2010;43:909-16.
13. Tsesis I, Rosen E, Tamse A, Taschieri S, Kfir A. Diagnosis of vertical root fractures in endodontically treated teeth based on clinical and radiographic indices: A systematic review. J Endod 2010;36:1455-8.
14. Sornkul E, Stannard JG. Strength of roots before and after endodontic treatment and restoration. J Endod 1992;18:440-3.
15. Pitts DL, Matheny HE, Nicholls JI. An *in vitro* study of spreader loads required to cause vertical root fracture during lateral condensation. J Endod 1983;9:544-50.
16. Fuss Z, Lustig J, Katz A, Tamse A. An evaluation of endodontically treated vertical root fractured teeth: Impact of operative procedures. J Endod 2001;27:46-8.
17. Park H. A comparison of greater taper files, ProFiles, and stainless steel files to shape curved root canals. Oral Surg Oral Med Oral Pathol Oral Radiol Endod 2001;91:715-8.
18. Tan BT, Messer HH. The quality of apical canal preparation using hand and rotary instruments with specific criteria for enlargement based on initial apical file size. J Endod 2002;28:658-64.
19. Bier CA, Shemesh H, Tanomaru-Filho M, Wesselink PR, Wu MK. The ability of different nickel-titanium rotary instruments to induce dentinal damage during canal preparation. J Endod 2009;35:236-8.
20. Capar ID, Arslan H, Akcay M, Ertas H. An *in vitro* comparison of apically extruded debris and instrumentation times with ProTaper universal, ProTaper next, twisted file adaptive, and HyFlex instruments. J Endod 2014;40:1638-41.
21. De-Deus G, Barino B, Zamolyi RQ, Souza E, Fonseca A Jr., Fidel S, *et al.* Suboptimal debridement quality produced by the single-file F2 ProTaper technique in oval-shaped canals. J Endod 2010;36:1897-900.
22. ElSayed M, Taleb A, Balbahaith M. Sealing ability of three single-cone obturation systems: An *in vitro* glucose leakage study. J Conserv Dent 2013;16:489-93.
23. Zandbiglari T, Davids H, Schäfer E. Influence of instrument taper on the resistance to fracture of endodontically treated roots. Oral Surg Oral Med Oral Pathol Oral Radiol Endod 2006;101:126-31.
24. Wilcox LR, Roskelley C, Sutton T. The relationship of root canal enlargement to finger-spreader induced vertical root fracture. J Endod 1997;23:533-4.
25. McCann JT, Keller DL, LaBounty GL. Remaining dentin/cementum thickness after hand or ultrasonic instrumentation. J Endod 1990;16:109-13.
26. Katz A, Tamse A. A combined radiographic and computerized scanning method to evaluate remaining dentine thickness in mandibular incisors after various intracanal procedures. Int Endod J 2003;36:682-6.
27. Singla M, Aggarwal V, Logani A, Shah N. Comparative evaluation of rotary ProTaper, Profile, and conventional stepback technique on reduction in *Enterococcus faecalis* colony-forming units and vertical root fracture resistance of root canals. Oral Surg Oral Med Oral Pathol Oral Radiol Endod 2010;109:e105-10.
28. Yoshimine Y, Ono M, Akamine A. The shaping effects of three nickeltitanium rotary instruments in simulated S-shaped canals. J Endod 2005;31:373-5.
29. Versluis A, Messer HH, Pintado MR. Changes in compaction stress distributions in roots resulting from canal preparation. Int Endod J 2006;39:931-9.
30. Veltri M, Mollo A, Pini PP, Ghelli LF, Balleri P. *In vitro* comparison of shaping abilities of ProTaper and GT rotary files. J Endod 2004;30:163-6.

How to cite this article: Sengupta A, Pandit V, Gaikwad A, Gandhe P. Comparative Study of the Influence of Instrument Taper on the Fracture Resistance of Endodontically Treated Teeth Using Hand and Rotary Files. Int J Sci Stud 2022;9(10):37-42.

Source of Support: Nil, **Conflicts of Interest:** None declared.

Print ISSN: 2321-6379
Online ISSN: 2321-595X

Original Article

Comparative Evaluation of Remineralization Potential and pH Change of GC Tooth Mousse Plus and Alcoholic Extract of Cocoa Powder, and Antibacterial Efficacy against *Streptococcus mutans*: An *In Vitro* Study

Mayuri M. Tawde[1], Laxmi S. Lakade[2], Rohan Shah[3], Sneha Desai[3], Shweta Jajoo[3], Preetam Shah[4]

[1]Dental Resident, Part III, Department of Pediatric and Preventive Dentistry, Bharati Vidyapeeth Dental College and Hospital, Pune, Maharashtra, India, [2]Associate Professor, Department of Pediatric and Preventive Dentistry, Bharati Vidyapeeth Dental College and Hospital, Pune, Maharashtra, India, [3]Assistant Professor, Department of Pediatric and Preventive Dentistry, Bharati Vidyapeeth Dental College and Hospital, Pune, Maharashtra, India, [4]Professor, Department of Pediatric and Preventive Dentistry, Bharati Vidyapeeth Dental College and Hospital, Pune, Maharashtra, India

Abstract

Context: Dental caries in its early stages is a reversible phenomenon for which various remineralizing agents have been used, most common being fluoride, casein phosphopeptide-amorphous calcium phosphate. Plant extracts have also been researched for their remineralizing properties, as alternative to fluoride containing agents.

Objectives: The aim of this study is to evaluate and compare the remineralization potential, pH change, and effect on *Streptococcus mutans*, of a fluoride remineralizing agent and alcoholic extract of cocoa powder, in an *in vitro* setup.

Methods: Eighteen extracted premolars were prepared and tested for surface microhardness at three intervals: Baseline, demineralization, and remineralization. Demineralization was carried out using demineralizing solution until white spot lesion was seen, following this remineralization was carried out with Group A (GC Tooth Mousse Plus) and Group B (alcoholic extracts of cocoa powder). pH change: Dilutions of both solutions were checked for pH changes from initial, 5, 10, and 15 min intervals. Antimicrobial activity: Zones of inhibition at different concentration of solutions of both groups were checked.

Results: Statistically significant difference was observed in the values from demineralization to remineralization in both groups. Statistical analysis was performed using SPSS Version 19 software. Comparison of hardness, pH, and antimicrobial activity were done by independent t-test.

Conclusion: Both GC Tooth Mousse Plus and alcoholic extract of cocoa powder are equally effective as remineralizing agents, GC Tooth Mousse Plus is seen to be slightly more effective.

Key words: Remineralization, Casein phosphopeptide-amorphous calcium phosphate, Cocoa extract, GC Tooth Mousse Plus

INTRODUCTION

Dental caries, the most common oral health-related issue, is a multifactorial disease and has high global prevalence and incidence rates. Enamel is under constant influences of oral milieu, salivary fluctuations, and pH changes by accumulated food debris resulting in bacteria and their products. Caries is not a continuous and unidirectional process, rather a cyclic event consisting of periods of remineralization and demineralization, predominance of latter leads to a subsurface lesion, then cavitation.

The diagnosis and treatment of dental caries plays a very important role in maintaining oral health, for which research is never ending. The process of tackling dental caries had evolved from various treatment approaches

Access this article online

www.ijss-sn.com

Month of Submission : 11-2021
Month of Peer Review : 12-2021
Month of Acceptance : 12-2021
Month of Publishing : 01-2022

Corresponding Author: Mayuri M. Tawde, 208, Department of Pediatric and Preventive dentistry, Bharati Vidyapeeth Dental College and Hospital, Pune - 411 046, Maharashtra, India.

aimed at restoring the tooth to a sound structure and function, to, development of novel and efficient diagnostic aids that enable detection at earlier stages, encouraging the concept of minimally invasive dentistry that is advocated, in the recent times. Remineralizing agents are non-invasive approaches to deal with the early carious lesions and are significant in decreasing their progress and clinical management of the disease.

Various remineralizing agents have been used in dentistry, fluoride being the most widely accepted, used, and incorporated in both in-office and home applications. Apart from fluoride used in varnish, gels, toothpastes, and tablets, other agents that have been developed over the years are casein phosphopeptide (CPP), amorphous calcium phosphate (ACP), bioactive glass, tricalcium phosphate, xylitol, CPP-ACP, and casein phosphopeptide-ACP fluoride (CPP-ACPF) have been used. Fluoride which has been in use since a long time basically forms a complex called fluorapatite replacing lost ions from the enamel, making it more resistant to dissolution by bacterial products and promoting remineralization. The anti-caries action of topical fluorides is now universally accepted and has been the subject of several reviews and meta-analyses of clinical data.[1]

CPP contains the amino acid cluster sequence of -Ser(P)-Ser(P)-Ser(P)-Glu-Glu can be purified as CPP-ACP nanocomplexes by selective precipitation, ion exchange.[2] These sequences are reservoir of calcium and phosphate ions incorporated in GC tooth mousse by Recaldent™, which have a synergistic action with fluoride (900 ppm) as in the GC Tooth Mousse Plus.

However, the use of fluoride for caries prevention is limited due its toxicity issues.[3] Hence, natural agents such as green tea,[4] grape extract,[5] cocoa bean husk, and cocoa extracts[6,7] have been researched.[8] Theobromine containing dentifrices claims to remineralize enamel lesions effectively.[9] Theobromine is a natural alkaloid derived from cacao beans (*Theobroma cacao* L.) containing secondary metabolites in the form of purine alkaloids derived from xanthine.[10] It is an alkaloid readily available in cocoa (240 mg/cup) in both cocoa bean and its husk. The mean theobromine content of cocoa beans is approximately 20.3 mg/g.[11]

Therefore, in the current study, fluoride in conjunction with CPP-ACP system, that is, CPP-ACPF is compared with alcoholic extract of cocoa containing theobromine, to assess the remineralization of enamel, antimicrobial action against *Streptococcus mutans,* and pH changes in an *in vitro* model.

MATERIALS AND METHODS

Materials

(1) Twenty intact premolars indicated for orthodontic extraction
(2) Thymol in distilled water for storage
(3) Demineralizing solution
(4) Alcoholic extract of cocoa powder
(5) Fluoride containing remineralizing agent (GC Tooth Mousse Plus)
(6) Artificial saliva
(7) Strains of *S. mutans*
(8) Agar plates for culturing
(9) Pocket pH meter.

Methodology

One kilogram of cocoa powder was treated in with 5 g of cellulose in 4.75 l of distilled water at 50°C for 4 h. Ethanol was then added up to 50 v/v of final concentration and mixture was refluxed for 1 h. After filtration, ethanol was removed by evaporation and aqueous solution lyophilized to form a powder. It is diluted with distilled water to attain a concentration of 0.05 mg/ml.

Evaluation of Surface Microhardness

Twenty premolars indicated for orthodontic extraction were obtained, only intact premolars, with the absence of cracks, caries, and defects were sorted and stored in thymol solution. The crowns were separated from the roots using a diamond disc and straight handpiece under water cooling. The crowns were mounted in circular resin blocks such that the buccal surface was exposed. The exposed tooth surface was polished slightly using a fine grit sandpaper to obtain a flat surface, for measuring surface microhardness. Samples were then stored in deionized water until further testing.

Baseline microhardness (SMH-1)

Specimens were thoroughly rinsed and dried. The exposed enamel surface was tested using a Diamond indenter of Microhardness Tester, Reichert Austria Make (Sr. No.363798), subjected to a load of 50 g. Two indentations were made on the surface at two different points, on each sample, to avoid discrepancy and their average was taken as the final value.

Demineralizing solution

Freshly prepared demineralizing solution with pH adjusted between 4.5 and 5.5 (critical pH) with contents as follows: Calcium 2.0 mMol/L, phosphate 2.0 mMol/L, and acetic acid 75.0 mMol/L was used for demineralization of surface enamel. All the specimens were immersed individually in the solution till white spot lesion was seen on the surface.

Second microhardness test (SMH-2)

It was conducted after white spot lesions were seen on exposed enamel surface, similar to that of baseline, for all 20 specimens.

Remineralization protocol

The samples were divided into two groups, Group A (10 samples) was immersed individually in alcoholic extract of cocoa powder and Group B (10 samples) was immersed in GC Tooth Mousse Plus, with equal dilutions with distilled water for both groups. This process was carried out every day 15 min for 7 days, in between the samples were stored in deionized water.

Third microhardness test (SMH-3)

It was carried out after the remineralization protocol using values of two indentations on the surface to obtain an average value for all the samples individually.

Antimicrobial Efficacy

To check the antimicrobial efficacy of both Group A (alcoholic extract of cocoa powder) and Group B (GC Tooth Mousse Plus) against *S. mutans*, organism was grown on MHA agar plates, and wells were created, in which three different concentrations 0.1. 0.5, and 1 ml were checked for zone of inhibition, for both groups.

pH Analysis

pH analysis was done using a pocket pH meter (Digital). Both the solutions were mixed with artificial saliva, and pH was checked initially, and then later at intervals of 5, 10, and 15 min. Three readings were taken and their average was calculated.

RESULTS

The values for baseline, demineralization, and remineralization for all 20 samples, average of two values, per sample are listed in Table A1.

On using concentrations of both products at 0.1 ml, 0.5 ml, and 1 ml for alcoholic extract of cocoa and 0.1 g, 0.5 g, and 1 g GC Tooth Mousse Plus, no inhibition of *S. mutans* is seen. This indicates that both the products do not affect the growth of *S. mutans in vitro* [Table A2].

The results of pH test and comparison of these values in Table A3, where only minor fluctuations are seen, show no significant *P* value at different intervals.

All the statistical analyses were performed using SPSS Version 19 software. Comparison of change in hardness and pH at each interval in each group was using repeated measure ANOVA test followed by *post hoc* test for pairwise comparison. Comparison of hardness and pH in between two groups at each interval was done using independent *t*-test. Comparison of antimicrobial activity in between two groups at each interval was done using independent *t*-test. Level of significance was kept at $P \leq 0.05$.

DISCUSSION

In this study, GC Tooth Mousse and alcoholic extract of cocoa powder containing theobromine have been tested for their remineralization properties. The enamel is made up of crystal lattice of hydroxyapatite predominantly calcium and phosphate ions, the concentrations of which influence the structural composition of sound and defective enamel. During phases that promote dissolution of enamel, ions are lost from this lattice, making it more susceptible to bacterial invasion. Remineralizing agents essentially restore the ions lost from the lattice creating a more stable structure that can withstand further breakdown promoting a temporary arrest of lesion progression, in its early stages of subsurface or white spot lesions.

Increase in the surface microhardness is seen on remineralization of carious enamel lesions Tencate *et al*., 1978, and Finke *et al*., 2000. Dental caries in its early stage of formation (non-cavitated) can be remineralized (Ten Cate and Featherstone, 1991; Featherstone, 2008). Fluoride, the gold standard in remineralization, is also preceded before use by caution of do not ingest. These risks of ingestion, especially in children, have made non-fluoride agents such as CPP-ACP and natural products among other systems as the subject of ongoing research.

Theobromine, a xanthine alkaloid found in extracts of cocoa powder and cocoa bean husk, has shown cariostatic effect at concentration of 71 times,[7] twice the protective effect on teeth as compared to fluoride at 142 times lesser concentrations as proposed by Carey.

In the present study, as seen in Graph A1, there is a significant difference seen, from demineralization to remineralization in both ($P > 0.5$), indicating that both agents are effective in remineralization of enamel lesions. However, when comparison of Group A and Group B was done, to see which agent was better as a remineralizing agent, [Graph A2] Group A – 5.91% as compared to Group B – 8.49%, Group A (alcoholic extracts of cocoa powder) has shown to be lesser effective in increasing surface microhardness as compared to Group B, but the difference is not enough to be statistically significant.

In this study, theobromine is used in calibrated concentrations to 1.1 mmol/l, which was the effective

concentration required to cause remineralization by Amaechi *et al*. The action of theobromine in cocoa extracts is owed to its ability to improve the surface chemical composition of enamel.[12,13]

Amaechi *et al*. have found that theobromine enhanced the resistance of remineralized surfaces to subsequent caries challenge. This action can be attributed to increased apatite crystallite size formed with theobromine (2 μm) as compared to 0.5 μm to that formed by fluoride crystals in an apatite forming medium. The results of this study are synchronous with studies conducted before by Frank Lippert,[14] Parvathy *et al*.,[9] Irawan *et al*.,[15] and Abdullah[16] where they have used theobromine incorporated within products and have concluded fluoride to be more effective. Irawan *et al*.[15] found that theobromine is not able to restore after demineralization on remineralization to its initial surface microhardness. Gundogar[17] and Kargul *et al*.[18] have found that the effect of theobromine is directly related to concentration used. In studies conducted by Duraisamy *et al*.[6] he has found theobromine to be more effective when compared to CPP ACPF and Nakumoto 2016[12] has seen better occlusion of dentinal tubules with a theobromine containing dentifrice as compared to fluoride containing dentifrice.

This may be attributed to two factors, that is, first, elemental theobromine is not used in this study, instead, theobromine is calibrated to an effective concentration in a naturally occurring plant product, and second, there are two synergistic systems involved in CPP- ACPF, mainly CPP and fluoride, which can also be a factor for the results being slightly in favor of GC Tooth Mousse Plus.

Since the values between both groups for remineralization are not statistically significant, it can be said that both GC Tooth Mousse Plus and alcoholic extracts of cocoa powder, both are effective in remineralization of tooth, as corroborated in studies conducted by Sadeghpour,[19] Amaechi *et al*.,[20] Kargul *et al*.,[18] Mahardhika *et al*.,[21] 2017, and Sulistianingsih *et al*.[22]

For the antimicrobial efficacy of GC Tooth Mousse Plus and alcoholic extracts of cocoa powder [Table A2], no significant results were seen in the study [Figure A1]. The main property of theobromine and GC Tooth Mousse Plus is enamel remineralization, evaluation of cariostatic property is an adjunct. Nevertheless, they have been shown to be effective by inhibiting biofilm formation on teeth and affecting the adherence properties of *S. mutans*, and other bacteria, in case of theobromine by inhibiting glucosyltransferases. This indirectly leads to inhibition or increase in time required for colonization of tooth surfaces that result in the display of inhibition of bacteria.[23]

In a study by Pinhero,[24] where CPP-ACP complex was added to GIC to check inhibition of *S. mutans*, there was inhibition seen immediately after placement, but counts increased after 6 months–1 year. This adds up to the previous observation where the adherence of bacteria is hampered due to the application of GC Tooth Mousse Plus.

Studies which have proven statistically significant activity with theobromine in terms of inhibition of bacteria[23] have used commercially available theobromine tooth paste, ingredients of which being Rennou™ (theobromine, calcium acetate, and sodium hydrogen phosphate) which can result in synergistic activity as compared to the use of elemental theobromine. Furthermore, a biofilm model may be more suited to evaluate this parameter, as its antimicrobial property is attributed to the prevention of biofilm formation.

As for pH activity, it is a very important factor and a predictor of dental caries. Decrease in pH below critical level causes the calcium ions to leach out of hydroxyapatite crystals and increase their concentration in saliva, which over prolonged periods of time causes demineralization and hollowing out of dentinal tubules creating pathways for bacteria to enter and cause dental caries. Prolonged lowered levels of pH cause irreversible demineralization, which then needs institution of treatment to restore it to normal form. Most remineralizing agents when mixed with saliva increase concentration of ions essential to form complexes with hydroxyapatite and cause rise in pH which helps in remineralization. In the present study, pH values were measured using a pH meter at 5, 10, and 15 min intervals, *in vitro* and no significant changes were seen. Both groups individually when mixed with artificial saliva had pH that was alkaline. The values did not fluctuate on standing, from 5, 10, and 15 min. The constant values were as a result of no external influencing factors on the solutions.

Shortcomings: Since it was an *in vitro* model, physiological conditions in the mouth could not be simulated, which could affect the study outcomes. Furthermore, naturally occurring theobromine devoid of any additives is seen.

CONCLUSION

Both the systems that were used in the present study were effective in remineralization, almost equally which can allow us to consider theobromine as an alternative to fluoride. Addition of which components to enhance remineralization properties of theobromine needs to be researched, since it is a very promising and safe agent as compared to fluoride. Relying on their antimicrobial activity is still doubtful, and more studies need to be done to test

this aspect. pH changes can also be tested effectively in an *in vivo* model. More research needs to be done to establish the currently available evidence.

ACKNOWLEDGMENT

Conducting this research has been possible, only with the guidance, support, and constant encouragement from a lot of people. First, I would like to thank my Guide, whose vision has led to the successful completion and without whose encouragement, this would be far from being a completed task. My family has also been utmost supportive, and I thank them for being understanding and patient, even in the most trying times. I would also like to thank my friends, Dr. Manasi, Dr. Anisha, Dr. Preeti, and Dr. Sayali for being rock pillars of love and support, always. Tastree Foods has been generous enough to provide unprocessed cocoa powder, for the research, for which I am very thankful. I would also like to thank Praj Metallurgical Labs for carrying out the surface microhardness tests for the study, and their immense patience and expertise of the subject, was a great help for the research. Last but not the least, I would like to thank all my teachers, whose inputs have been very valuable and my dear colleagues, for their love and support.

REFERENCES

1. Lenzi TL, Montagner AF, Soares FZ, de Oliveira Rocha R. Are topical fluorides effective for treating incipient carious lesions? A systematic review and meta-analysis. J Am Dent Assoc 2016;147:84-91.
2. Morgan MV, Adams GG, Bailey DL, Tsao CE, Fischman SL, Reynolds EC. The anticariogenic effect of sugar-free gum containing CPP-ACP nanocomplexes on approximal caries determined using digital bitewing radiography. Caries Res 2008;42:171-84.
3. Ullah R, Zafar MS, Shahani N. Potential fluoride toxicity from oral medicaments: A review. Iran J Basic Med Sci 2017;20:841-8.
4. Suyama E, Tamura T, Ozawa T, Suzuki A, Iijima Y, Saito T. Remineralization and acid resistance of enamel lesions after chewing gum containing fluoride extracted from green tea. Aust Dent J 2011;56:394-400.
5. Xie Q, Bedran-Russo AK, Wu CD. *In vitro* remineralization effects of grape seed extract on artificial root caries. J Dent 2008;36:900-6.
6. Duraisamy Y, Chaly P, Priyadharshini I, Mohammed J, Vaishnavi. Evaluation of remineralization potential of theobromine on human enamel surfaces an *in vitro* study. Int J Sci Res 2017;6:435-38.
7. Taneja V, Nekkanti S, Gupta K, Hassija J. Remineralization potential of theobromine on artificial carious lesions. J Int Soc Prev Community Dent 2019;9:576-83.
8. Heifetz SB, Horowitz HS. Amounts of fluoride in self-administered dental products: Safety considerations for children. Pediatrics 1986;77:876-82.
9. Premnath P, John J, Manchery N, Subbiah GK, Nagappan N, Subramani P. Effectiveness of theobromine on enamel remineralization: A comparative *in-vitro* study. Cureus 2019;11:e5686.
10. Permatasari R, Suniarti DF, Herda E, Mas'ud ZA. Identification of alkaloids of Indonesian Cacao beans (*Theobroma cacao* L.) and its effect on tooth enamel hardness. J Med Plants Res 2016;10:202-8.
11. Verma A, Khurshid S, Parveen F, Khanna S, Pandey P. Remineralisation: An approach towards conservation of tooth. J Evol Med Dent Sci 2015;4:10713-9.
12. Nakamoto T, Falster AU, Simmons WB Jr. Theobromine: A safe and effective alternative for fluoride in dentifrices. J Caffeine Res 2016;6:1-9.
13. Hussein SI, El-Haddad KE. Comparison between solution and gel forms of theobromine and sodium fluoride in remineralization of the demineralized human enamel. Egypt Dent J 2018;64:2371-80.
14. Lippert F. The effects of fluoride, strontium, theobromine and their combinations on caries lesion rehardening and fluoridation. Arch Oral Biol 2017;80:217-21.
15. Suryana M, Irawan B, Soufyan A. The effects of toothpastes containing theobromine and hydroxyapatite on enamel microhardness after immersion in carbonated drink. J Phys 2018;3:1073.
16. Nasution A, Zawil C. The comparison of enamel hardness between fluoride and theobromine application. Int J Contemp Dent Med Rev 2014;10:15713.
17. Gündoğar ZU, Keskin AG, Çinar C. Comparison of fluoride and the novel anti-caries agent theobromine on initial enamel caries: An *in vitro* study. Fluoride 2019;52:456-66.
18. Kargul B, Özcan M, Peker S, Nakamoto T, Simmons WB, Falster AU. Evaluation of human enamel surfaces treated with theobromine: A pilot study. Oral Health Prev Dent 2012;10:275-82.
19. Sadeghpour A, Nakamoto T. Methods and Compositions to Improve Mechanical Resistance of Teeth. US Patent.
20. Amaechi BT, Porteous N, Ramalingam K, Mensinkai PK, Vasquez RA, Sadeghpour A, *et al*. Remineralization of artificial enamel lesions by theobromine. Caries Res 2013;47:399-405.
21. Mahardhika A, Noerdin A, Eriwati Y. The effects of brushing on human enamel surface roughness after NaF gel and theobromine gel exposure. J Phys 2007;884:1742.
22. Sulistianingsih S, Irmaleny I, Hidayat OT. The remineralization potential of cocoa bean extract (*Theobroma cacao*) to increase the enamel micro hardness. Padjadjaran J Dent 2017;29:107-12.
23. Lakshmi A, Sharmin D. Comparative evaluation on antimicrobial activity of theobromine and two commercial kids fluoride toothpaste an *in vitro* study. Int J Dent Oral Health 2016;2:61-5.
24. Pinheiro SL, Azenha GR, de Milito F, Democh YM. Antimicrobial capacity of casein phosphopeptide/amorphous calcium phosphate and enzymes in glass ionomer cement in dentin carious lesions. Acta Stomatol Croat 2015;49:104-11.

How to cite this article: Tawde MM, Lakade LS, Shah R, Desai S, Jajoo S, Shah P. Comparative Evaluation of Remineralization Potential and pH change of GC Tooth Mousse Plus and Alcoholic Extract of Cocoa Powder, and Antibacterial Efficacy against *Streptococcus mutans*: An *In Vitro* Study. Int J Sci Stud 2022;9(10):43-49.

Source of Support: Nil, **Conflicts of Interest:** None declared.

APPENDIX TABLES

Table A1: Baseline microhardness values for Group A and Group B, SMH-1 (microhardness in HV)

Surface microhardness 1 (baseline)						Surface microhardness 2 (demineralization)						Surface microhardness 3 (remineralization)					
Group A			Group B			Group A			Group B			Group A			Group B		
R1	R2	AVG	R1	R2	AVG	R1	R2	AVG	R1	R2	AVG	R1	R2	AVG	R1	R2	AVG
320	323	322	308	313	310	280	276	279	263	267	265	288	290	289	300	301	301
301	303	302	303	306	305	270	274	272	279	285	282	290	291	291	295	299	297
300	307	204	335	337	336	288	282	285	290	292	291	287	288	288	310	312	311
310	313	312	302	306	304	267	271	269	265	271	268	280	282	281	290	292	291
312	315	314	318	312	316	260	268	264	286	288	287	282	286	284	300	302	301
322	330	326	315	320	318	282	290	286	255	261	258	297	298	298	299	305	303
330	332	331	301	303	302	259	269	264	269	275	272	290	293	292	290	295	293
323	325	324	310	314	312	271	277	274	290	296	293	292	296	294	300	302	301
295	302	298	304	307	305	263	269	266	260	264	262	280	281	281	296	299	298
310	318	314	299	315	307	258	264	261	269	273	271	280	282	281	280	284	282

Table A2: Effect of Group A and Group B agents on *Streptococcus mutans*

Test organism	Product details	Result – zone of inhibition (mm)
Streptococcus mutans	0.1 ml extract	NI
Streptococcus mutans	0.5 ml extract	NI
Streptococcus mutans	1 ml extract	NI
Streptococcus mutans	0.1 g GC Tooth Mousse Plus	NI
Streptococcus mutans	0.5 g GC Tooth Mousse Plus	NI
Streptococcus mutans	1 g GC Tooth Mousse Plus	NI

NI: No inhibition. Since results showed no change, statistical analysis of this parameter could not be done

Table A3: Comparison of values of pH and their statistical analysis

Interval	Group A pH	Group B pH	Difference	*P* value
Initial	5.80±0.20	6.90±0.10	−1.10	0.001*
At 5 min	5.67±0.06	6.97±0.06	−1.30	0.001*
At 10 min	5.67±0.06	6.97±0.06	−1.30	0.001*
At 15 min	5.60±0.00[a]	7.00±0.00[a]	--	--

pH analysis of all specimens in Group A and B. Paired t-test; * indicates significant at $P \leq 0.05$

APPENDIX FIGURE

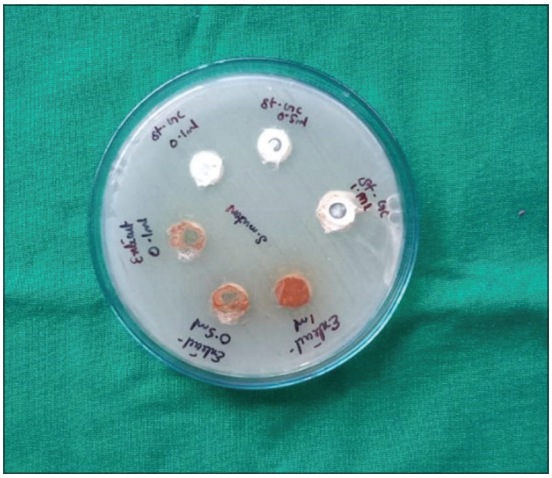

Figure A1: No zone of inhibition seen with both groups

APPENDIX GRAPH

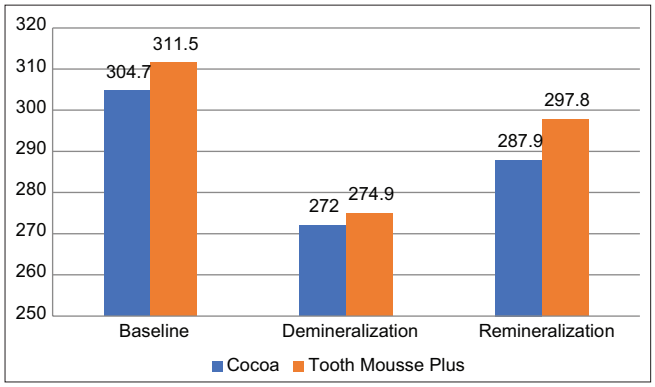

Graph A1: Graphical representation of microhardness of Group A and Group B at different intervals. Significant difference seen from demineralization to remineralization in both groups

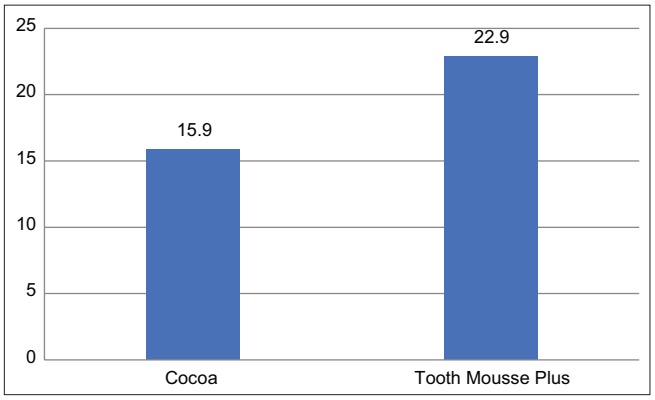

Graph A2: Increase in microhardness for both groups post-demineralization, difference is not statistically significant

Print ISSN: 2321-6379
Online ISSN: 2321-595X

Original Article

Effect of Hypertension on Sensory Nerve Conduction Variables

Barkha Rani[1], Anand Kumar Singh[2]

[1]Assistant Professor, Department of Physiology, Government Medical College, Nagpur, Maharashtra, India, [2]Senior Resident, Department of Orthopaedics, All India Institute of Medical Sciences, Raipur, Chhattisgarh, India

Abstract

Background: Hypertension is most prevalent cardiovascular disorder that affects many organs of our body and it markedly increases both mortality and morbidity. Nerve conduction studies (NCSs) are most commonly used electro-diagnostic tests to determine the conduction in motor and sensory nerves. NCS estimates conduction velocity, latency, duration, and amplitude. The present study is done to evaluate velocity, latency, and amplitude of sensory nerve conduction variables in peroneal and sural nerve.

Aims and Objectives: The aim was to assess the effect of hypertension on sensory nerve conduction.

Materials and Methods: The study was conducted in tertiary care hospital. A written informed consent was acquired from every member. The study was done in 50 hypertensives and 50 normotensives between the age gatherings of 40–60 years. The data analysis will be done using the "MedCalc." NCV measures were expressed as mean ± SD. Student paired "*t*-test" and Chi-square test were used for comparison of the values between hypertensive and normotensive group.

Results: Peroneal nerve in hypertensive shows latency (1.31 ± 0.35), amplitude (12.60 ± 2.56), and velocity (50.16 ± 2.94) when compared with normotensive shows latency (1.38 ± 0.26), amplitude (12.01 ± 2.51), and velocity (50.05 ± 4.04). Hence, hypertensive group is statistically not significant than normotensive group. Sural nerve in hypertensive shows latency (2.20 ± 0.62), amplitude (18.8 ± 2.18), and velocity (70.4 ± 3.5) when compared with normotensive shows latency (2.16 ± 0.61), amplitude (18.6 ± 2.15), and velocity (69.6 ± 3.56). The final results of sensory nerve conduction variables were not statistically significant when compared in both study groups ($P > 0.05$).

Conclusion: Hypertension may create axonal degeneration, yet may not be influencing the myelination in this way safeguarding nerve conduction speed. Consequently, hypertension itself may not influence the nerve conduction factors. Broad investigations are needed to examine the impact of hypertension in nerve conduction variables.

Key words: Hypertension, Nerve conduction study, Peripheral neuropathy, Peroneal nerve, Sensory nerve, Sural nerve

INTRODUCTION

Hypertension is the most common disease and it markedly increases both mortality and morbidity. The adverse effects of hypertension principally involve the blood vessels, retina, heart, and kidneys including central nervous system.[1] Nerve conduction studies (NCSs) are the most commonly used electro-diagnostic tests to determine the conduction in motor and sensory nerves.[2] NCS involves activation of nerves with small, safe electrical impulses over multiple points on the skin of limbs, and thereafter measuring the obtained responses.[3] NCS is diagnostically helpful in patients suspected of having almost any kind of peripheral nervous system disorder including disorders of nerve roots, peripheral nerves, muscle, and neuromuscular junction.[4] Nerve conduction study measures duration, latency, amplitude, and conduction velocity. Amplitude denotes the number of functioning fibers and it is altered in diseases causing axonal degeneration. Conduction velocity and latency represent the speed of nerve impulse propagation. They are affected in diseases, which causes demyelination of nerves.[5]

Access this article online

www.ijss-sn.com

Month of Submission : 11-2021
Month of Peer Review : 12-2021
Month of Acceptance : 12-2021
Month of Publishing : 01-2022

Corresponding Author: Dr. Anand Kumar Singh, Department of Orthopaedics, All India Institute of Medical Sciences, Raipur, Chhattisgarh, India.

The aim of the study was to identify the effect of essential hypertension alone (without associated diabetes mellitus) on sensory nerve conduction velocity of peroneal and sural nerve.

MATERIALS AND METHODS

The study was conducted in a teaching college and hospital with prior permission of the Institutional Ethics Committee. A written informed consent was acquired from every member. The study was done in 50 hypertensives and 50 normotensives between the age gatherings of 40–60 years which included both males and females. The hypertensives were selected from the outpatient department (OPD) of the hospital and the controls were normotensive volunteers.

Inclusion Criteria

Selection of hypertensive patient

The following criteria were included in the study

- Clinically stable hypertensive patients with duration of illness more than 5 years
- The criteria of considering patient hypertensive were a blood pressure >140/90 mm Hg based on the average of 2 or more readings taken during each of his/her visits to the OPD
- These subjects were not on any antihypertensive medication and they were not acutely ill.

Selection of controls

- The controls were healthy volunteers with systolic blood pressure <120 mm of Hg and diastolic blood pressure <80 mm of Hg.

Exclusion Criteria for Both

The following criteria were excluded from the study

- Age <40 and more than 60
- Subjects having any – Diabetes mellitus, ischemic heart disease, strokes, cardiac pacemaker, gout, rheumatoid arthritis, thyroid, major psychiatric diseases, renal failure, leprosy, tuberculosis, and acquired immunodeficiency syndrome
- Subjects with history of addiction to alcohol, drug abuse, and smokers
- Athletes.

Recording of Nerve Conduction Velocity

The study was done using NEURO – MEP – NET Machine equipped for EMG/NCV/EP manufactured by NEUROSOFT TM. The apparatus works on a computer with Windows 98 operating system having MS Office 97 package.

For sensory nerve conduction study, the low frequency filter was set at 5 Hertz (Hz) and high frequency filter at 3 kHz. Thus, the signals between the above mentioned frequencies were recorded.

Sweep speed: The sweep speed was set at 2 ms/division.

Peroneal (superficial) sensory nerve conduction study [Table 1 and Figure 1]

leg is relaxed over couch and lateral aspect of leg, ankle and foot exposed.

Sural sensory nerve conduction study [Table 2 and Figure 2]

Leg is relaxed and placed in lateral position.

RESULTS

Superficial Peroneal Nerve [Table 3 and Graph 1]

The results of Sensory nerve conduction variables were not statistically significant between normotensive and hypertensive group ($P > 0.05$).

Sural Nerve [Table 4 and Graph 2]

The results of sensory nerve conduction variables were not statistically significant between normotensive group and hypertensive group ($P > 0.05$).

Table 1: Peroneal (superficial) sensory nerve conduction study

Electrodes	Position
Recording electrode	Placing active electrode just above the junction of lateral third of a line connecting the malleoli
Reference electrode	3 cm distal to the active electrode
Ground electrode	Placing between the stimulating and recording electrodes
Stimulating Electrode	Anti-dromic surface stimulation is carried out 10–15 cm proximal to the upper edge of lateral malleolus anterior to peroneus longus

Table 2: Sural sensory nerve conduction study

Electrodes	Position
Recording electrode	Placed on motor point between lateral malleolus and Achilles tendon
Reference electrode	Placed 3cm distal to recording electrode
Ground electrode	Placed below the lateral malleolus of ankle
Stimulating electrode	• Cathode: 10–16 cm proximal to recording electrode, distal to the lower border of gastrocnemius at the junction of middle and lower third of the leg • Anode: Placed 3 cm distal to the cathode

Table 3: Superficial peroneal sensory nerve conduction variables in normotensive and hypertensives

Parameters	Hypertensive (*n*=50) Mean±SD	Normotensive (*n*=50) Mean±SD	*P*-value
Latency	1.31±0.35	1.38±0.26	0.2590
Amplitude	12.60±2.56	12.01±2.51	0.2474
Velocity	50.16±2.94	50.05±4.04	0.8766

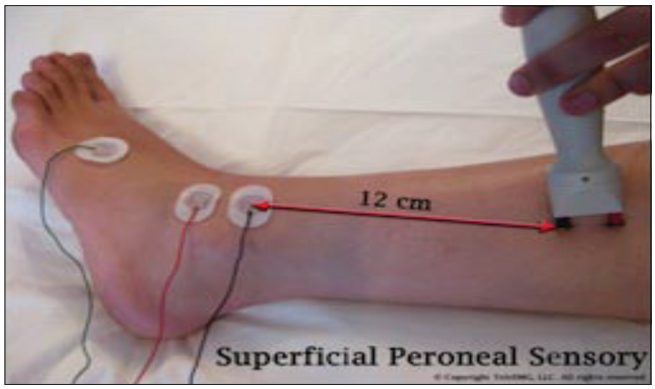

Figure 1: Recording of Superficial Peroneal nerve conduction

Figure 2: Recording of sural sensory nerve conduction

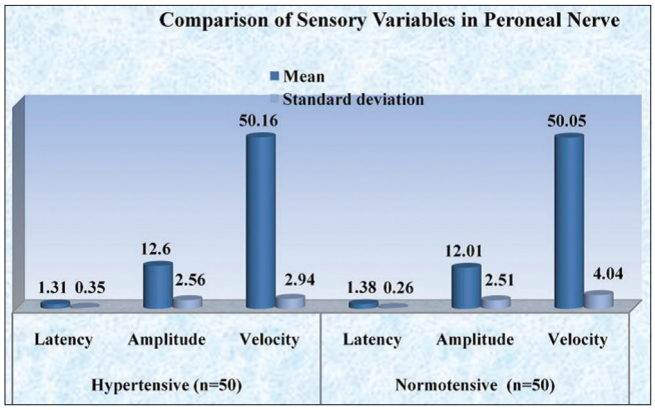

Graph 1: Superficial peroneal sensory nerve conduction variables in normotensive and hypertensives

DISCUSSION

This study aimed to investigate the effect of sensory nerve conduction variables in patients with hypertension. No statistical significant differences were found in sensory nerve conduction velocity of hypertensives as compared to normotensives.

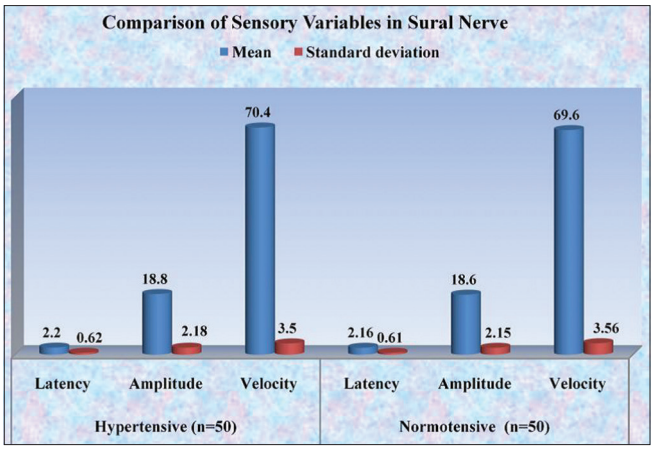

Graph 2: Sural nerve conduction variables in normotensive and hypertensives

Table 4: Sural nerve conduction variables in normotensive and hypertensives

Parameters	Hypertensive (*n*=50) Mean±SD	Normotensive (*n*=50) Mean±SD	*P*-value
Latency	2.20±0.62	2.16±0.61	0.7457
Amplitude	18.8±2.18	18.6±2.15	0.6452
Velocity	70.4±3.5	69.6±3.56	0.2599

A study was done by Yassin *et al.*[6] to assess the relationship between hypertension and peripheral neuropathy. The study assessed nerve conduction variables of sensory nerve function, motor nerve function, and also F wave measurement. They observed statistical significance of ($P < 0.05$) for the association between hypertension patients and sensory nerve conduction that presented deterioration. However, the motor NCSs (Median, Ulnar, and Tibial) did not show many changes; whereas, in their F-wave parameter assessment, the latency of the slowest F wave was observed in the common peroneal nerve, which was prolonged. From their results, they interpret that smallest fibers were affected in hypertension.

Legrady *et al.*[7] presented that non-diabetic hypertensive patients also present the complications presented in diabetes. Patients who presented hypertension were undergoing antihypertensive therapy. In the study done by Viskoper *et al.*,[8] there is a reduction in nerve conduction velocity in hypertensives. This is because hypertension causes vasospasm of blood vessels supplying the nerves. Popvtzer *et al.*[9] showed that motor nerve conduction velocity is reduced in hypertensives when compared with controls. The result of our study is in accordance with the study done by Shubhangi *et al.*[10] and Lloyds *et al.*[11] who failed to demonstrate the effect of hypertension on nerve conduction velocity. Another study done by Negler *et al.*[12] also showed similar results of our study,

which showed that there is no effect of hypertension on nerve conduction. They proposed that hypertension maybe producing axonal degeneration, but not affecting myelination there by preserving nerve conduction velocity. Crowley[13] and Yasunari *et al*.[14] have proved clinically that oxidative stress is an outcome of chronic inflammation in hypertensive subjects. The onset of oxidative stress in hypertensive subjects depletes the levels of nitric oxide through the formation of peroxynitrite. This mechanism has been clinically proved by Moriel *et al*.[15]

However, our study is in relation with the study done by Negler *et al*.,[12] Shubhangi *et al*.,[10] and Lloyds *et al*.[11] which showed a negative correlation between nerve conduction and hypertension.

CONCLUSION

This study demonstrates that:

- Hypertension may create axonal degeneration, yet may not be influencing the myelination in this way safeguarding nerve conduction speed
- Hypertension itself may not affect the nerve conduction variables. Associated factors such as age, body mass index, and other diseases may cause variations in nerve conduction defects. Broad investigations are needed to examine the impact of hypertension in nerve conduction variables
- Finding of reduced nerve conduction velocity in hypertensive patients should alert the physician to the possibility of associated diseases such as diabetes mellitus, alcoholism, or concomitant peripheral vascular diseases
- Extensive studies are required to study the effect of hypertension alone on nerve conduction velocity, taking into consideration the severity, duration, and treatment of hypertension.

ACKNOWLEDGEMENT

The authors acknowledge the immense help received from the scholars whose articles are cited and included in references of this manuscript. The authors are also grateful to authors/editors/publishers of all those articles, journals, and books from where the literature for this article has been reviewed and discussed.

DATA AVAILABILITY

The data used to support the findings of this study are included within this article.

REFERENCES

1. Fisher ND, Williams HG. Hypertensive vascular disease. In: Kasper DL, Braunwald E, Fauci AS, Mauser SL, Longo DL, Jameson JL, *et al*., editors. Harrison's Principles of Internal Medicine. 17th ed., Vol. 2. United States: McGraw Hill Companies; 2005. p. 1549-62.
2. Mora-Brambila AB, Trujillo-Hernández B, Coll-Cardenas R, Huerta M, Trujillo X, Vásquez C, *et al*. Blink reflex, H-reflex and nerve-conduction alterations in leprosy patients. Lepr Rev 2006;77:114-20.
3. Mallik A, Weir AI. Nerve conduction studies: Essentials and pitfalls in practice. J Neurol Neurosurg Psychiatry 2005;76:ii23-31.
4. Saeed S, Akram M. Impact of anthropometric measures on sural nerve conduction in healthy subjects. J Ayub Med Coll Abbottabad 2008;20:112-4.
5. Kong X, Lesser EA, Potts FA, Gozani SN. Utilisation of nerve conduction studies for the diagnosis of polyneuropathy in patients with diabetes. J Diabetes Sci Technol 2008;2:268-74.
6. Yassin DI, Shamma YM, AjeenaI M. Electrophysiological study of peripheral nerves inhypertensive patients. Kufa Med J 2009;12:367-79.
7. Legrady P, Bajcsi D, Lengyel C, Varkonyi TT, Fejes I, Kempler P, *et al*. Investigation of cardiac autonomic and peripheral sensory neuropathy in diabetic and nondiabetic patients with hypertension. Clin Exp Hypertens 2013;35:465-9.
8. Viskoper RJ, Chaco J, Aviram A. Nerve conduction velocity in assessment of hypertension. Arch Intern Med 1971;128:574-5.
9. Popvtzer MM, Rosenbaum BJ, Gordon A, Maxwell MH. Relief of uremic polyneuropathy after bilateral nephrectomy. N Engl J Med 1969;281:949-50.
10. Shubhangi D, Jaya M, Khan ST. A prospective randomized parallel control study to evaluate the nerve conduction velocity in patients with essential hypertension. IJRTST 2013;7:127-8.
11. Lloyds A, Subhash S, Swornila DL, Justus AM. Effect of hypertension on motor nerve conduction variables. J Evid Based Med Healthc 2016;3:4091-3.
12. Negler W. Motor nerve conduction velocity in systemic diseases JAMA 1972;219:1632.
13. Crowley SD. The cooperative roles of inflammation and oxidative stress in the pathogenesis of hypertension. Antioxid Redox Signal 2014;20:102-20.
14. Yasunari K, Maeda K, Nakamura M, Yoshikawa J. Oxidative stress in leukocytes is a possible link between blood pressure, blood glucose, and C-reacting protein. Hypertension 2002;39:777-80.
15. Moriel P, Sevanian A, Ajzen S, Zanella MT, Plavnik FL, Rubbo H, *et al*. Nitric oxide, cholesterol oxides and endothelium-dependent vasodilation in plasma of patients with essential hypertension. Braz J Med Biol Res 2002;35:1301-9.

How to cite this article: Rani B, Singh AK. Effect of Hypertension on Sensory Nerve Conduction Variables. Int J Sci Stud 2022;9(10):50-53.

Source of Support: Nil, **Conflicts of Interest:** None declared.

Print ISSN: 2321-6379
Online ISSN: 2321-595X

Original Article

Chronic Urticaria and Subclinical Hypothyroidism: A Cross-sectional Study

J Kavitha[1], Vineela Rani Chowdary[2], Md. Dawood Sulemani[3]

[1]Senior Resident, Department of Biochemistry, Government General Hospital, Sangareddy, Telangana, India, [2]Assistant Professor, Department of Biochemistry, Gandhi Medical College, Secunderabad, Telangana, India, [3]Professor, Department of Biochemistry, Gandhi Medical College, Secunderabad, Telangana, India

Abstract

Introduction: Chronic urticaria or recurrent urticaria is defined as persistence of urticarial lesions for >6 weeks, with symptoms present at least 3 times in a week. About 30–45% of chronic spontaneous urticaria are related to autoimmune origin. The incidence of thyroid autoimmune conditions is about 4.3–57.4% in adults and 3.5–8% in children with chronic urticaria.

Aim and Objectives: The present study was undertaken to estimate the levels of anti-thyroid peroxidase (Anti-TPO) antibodies, T3, T4, thyroid-stimulating hormone (TSH), and to evaluate their use in early diagnosis of the sub clinical hypothyroidism in chronic urticaria.

Materials and Methods: A cross-sectional observational study was conducted in the Department of Biochemistry at Gandhi Medical College and Hospital over duration of 2 years after obtaining Institutional Ethics Committee. Fifty diagnosed chronic urticaria patients attending the dermatology outpatient department and 50 age and sex matched apparently healthy controls were included in the study. Blood samples were collected and analyzed for anti-TPO antibodies, T3, T4, and TSH by chemiluminescence immunoassay (CLIA) method.

Results: In the present study, the female to male ratio was 2.8:1 for cases and mean ± SD for age was 27.04 ± 5.77 years. The serum anti-TPO antibodies levels were significantly increased in the chronic urticaria cases with mean ± SD 43.10 ± 7.78 IU/ml compared to the controls with mean ± SD, 13.72 ± 1.28 IU/ml. Serum T3 and T4 levels were significantly decreased in cases ($P < 0.01$ and $P < 0.037$) and serum TSH was higher (Mean ± SD 5.55 ± 1.03 μIU/ml) in cases than in controls (2.86 ± 0.31 μIU/ml.) with significant ($P < 0.001$). Among the 50 chronic urticaria cases, 78 were euthyroid, 20% were subclinical hypothyroid, and 2% cases were clinical hypothyroid.

Conclusion: Chronic urticaria patients must be screened for subclinical hypothyroidism which would help in early diagnosis and change in treatment modalities thus improving the quality of life.

Key words: Anti thyroid peroxidase antibodies, Chronic urticaria, Serum thyroid-stimulating hormone, Subclinical hypothyroidism

INTRODUCTION

Chronic urticaria also called as recurrent urticaria is defined as persistence of urticarial lesions for >6 weeks, with symptoms present at least 3 times in a week with an annual incidence of about 1.4% in the general population.[1,2] It is grouped as chronic inducible urticaria when the urticaria occurs by external triggering stimulus such as food, pressure, and temperature and chronic spontaneous urticaria or chronic idiopathic urticaria when occurs without any specific triggering stimulus.[3]

About 30–45% of chronic spontaneous urticaria are related to autoimmune origin[4] and the autoimmune diseases associated with chronic urticaria are autoimmune thyroid diseases (Hashimoto's disease and Grave's disease), rheumatoid arthritis, type I diabetes mellitus, Sjogren's syndrome, Celiac disease, and systemic lupus erythematous, among which thyroid autoimmune conditions are more commonly associated with incidence about 4.3–57.4% in adults and 3.5–8% in children.[5]

Access this article online

www.ijss-sn.com

Month of Submission : 11-2021
Month of Peer Review : 12-2021
Month of Acceptance : 12-2021
Month of Publishing : 01-2022

Corresponding Author: Vineela Rani Chowdary, Department of Biochemistry, Gandhi Medical College, Secunderabad, Telangana, India.

Anti-thyroid peroxidase (Anti-TPO) antibodies are most commonly associated thyroid antibodies in chronic urticaria.[6] These are auto antibodies formed against TPO enzyme involved in the thyroid hormone synthesis. The anti-TPO antibodies act against high affinity receptor for immunoglobulin E(IgE) on mast cells and basophils resulting in histamine release and lead to urticaria[7] and they also inhibit TPO enzyme activity and show cytotoxic effect on thyroid follicular cells leading to thyroid abnormalities such as hypothyroidism and hyperthyroidism.[8,9] Due to these effects, the persons with the high-levels anti-TPO antibodies develop chronic urticaria and thyroid abnormalities.

Subclinical hypothyroidism in chronic urticaria patients is more prone to develop clinical hypothyroidism due to cytotoxic effect of anti-TPO antibodies on thyroid follicular cells.[8,9]

The present study was undertaken to estimate the serum levels of anti-TPO antibodies and T3, T4, and thyroid-stimulating hormone (TSH) in chronic urticaria patients. This would help in early diagnosis of subclinical hypothyroidism and changes in the treatment modalities of patients with chronic urticaria thus improving the quality of life.

Aim

The aim of the study was to estimate the serum levels of anti-TPO antibodies, T3, T4, and TSH in chronic urticaria patients.

Objectives

The objectives of the study are as follow:

1. To estimate anti-TPO antibodies, T3, T4, and TSH in chronic urticaria patients
2. To evaluate the use of anti-TPO antibodies and TSH in early diagnosis of subclinical hypothyroidism in chronic urticaria patients.

MATERIALS AND METHODS

A cross-sectional observational study was conducted in the Department of Biochemistry at Gandhi Medical College and Hospital from October 2018 to September 2020 after obtaining Institutional Ethics Committee.

Fifty patients attending the outpatient department of dermatology with complaint of urticaria >6 weeks, aged between 10 and 35 years of either sex were enrolled in the study.

Pregnant women, diagnosed cases of diabetes mellitus, chronic kidney disease, autoimmune thyroid diseases, patients on thyroxine replacement therapy, and anti-allergic therapy were excluded from the study. Fifty apparently healthy age and sex matched individuals were enrolled as controls.

Sample Collection and Analysis

With prior instructions, 5 ml of fasting venous sample was collected; serum was separated and stored at –200C. Anti-TPO antibodies and TSH were analyzed by chemiluminescent; sequential two-step immunoenzymatic ("sandwich") assay and serum T3 and T4 were analyzed by chemiluminescent method.

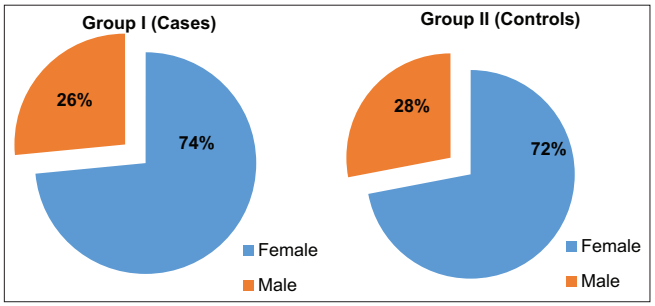

Chart 1: Sex-wise distribution of study groups

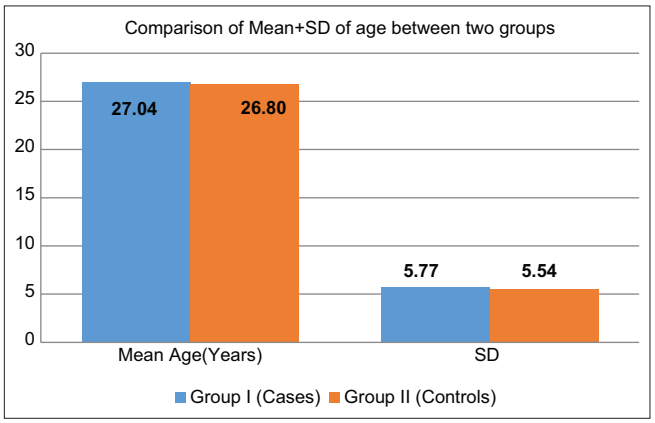

Chart 2: Comparison of mean and standard deviation two groups based on age

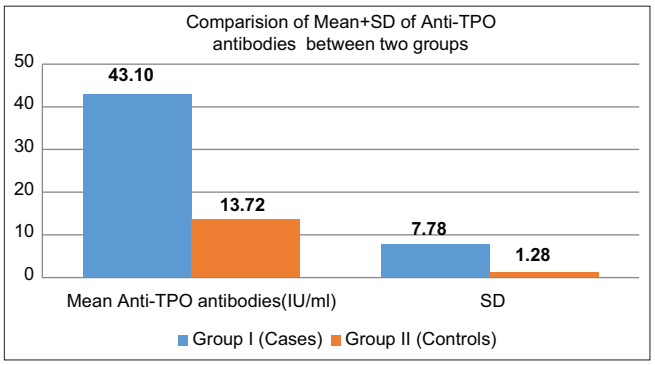

Chart 3: Comparison of serum anti-thyroid peroxidase antibodies between two groups

The results were tabulated in master chart and statistically analyzed using Microsoft Excel 2010 and SPSS software. $P < 0.05$ was considered as significant.

RESULTS

In the present study, 50 clinically diagnosed patients of chronic urticaria were categorized as cases (group I) and 50 apparently healthy subjects as controls (group II).

In the present study, the female to male ratio in group I was 2.8:1 and in group II was 2.6:1.

The Mean Age of the Study Population

In the present study, the mean age of group I (cases) was 27.04 years and of the group II (controls) was 26.80 years with standard deviation (SD) ±5.77 and ±5.54, respectively(as shown in chart 2).

As shown in Chart 3, the anti-TPO antibodies were significantly increased in group I subjects as compared to group II subjects. As shown in Chart 4, the serum T3 levels were decreased in cases than in group I (cases) as compared to group II (controls).

As shown in Chart 5, serum T4 levels were increased in group I (cases) than in group II (controls). As shown in Chart 6, serum TSH levels were increased in group I (cases) than in group II (controls).

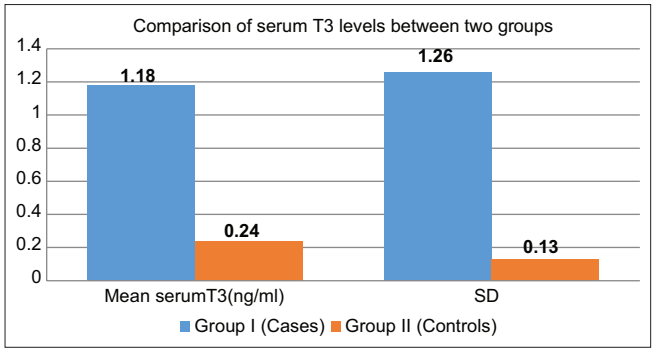

Chart 4: Comparison of serum T3 levels between case and control groups

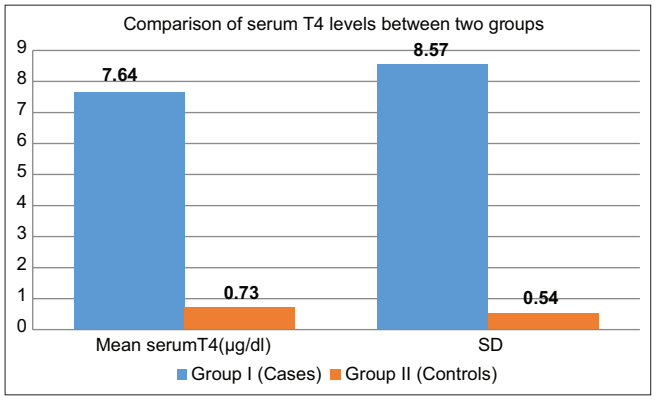

Chart 5: Comparison of serum T4 levels between cases and controls

Euthyroid, Subclinical Hypothyroid, and Clinical Hypothyroid Status in Patient Group

Among the 50 chronic urticaria cases, 39 cases were euthyroid, 10 cases were with subclinical hypothyroidism, and one case was with clinical hypothyroidism.

As shown in Chart 7, 78% cases were euthyroid, 20% cases were subclinical hypothyroid, and 2% cases were clinical hypothyroid.

DISCUSSION

Chronic urticaria is a common dermatological problem in India and is a distressing disorder that has significant impact on the quality of life of the patient. The most of the chronic urticaria cases remain idiopathic and are associated with systemic autoimmune diseases, most commonly with thyroid autoimmunity that results in thyroid dysfunction.

Anti-TPO antibodies have two-way effect; they show effects both on thyroid gland and skin. They can stimulate dermal mast cells and cause onset of urticaria and at the same time they show cytotoxic effect on thyroid follicular cells results in abnormalities in thyroid hormone levels

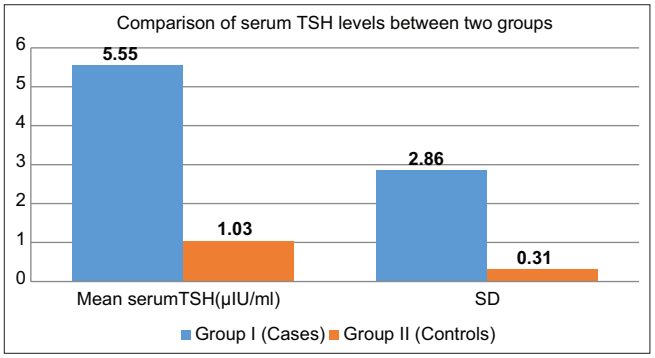

Chart 6: Comparison of serum thyroid-stimulating hormone levels between cases and controls

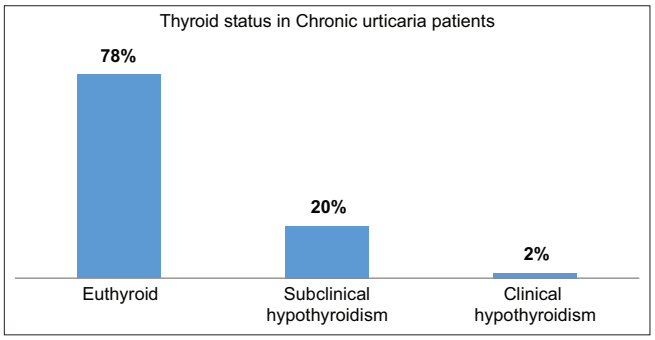

Chart 7: Distribution of euthyroid, subclinical hypothyroid, and clinical hypothyroid status in patient group

leading to hypothyroidism or hyperthyroidism. Hence, chronic urticaria and thyroid disease are considered as associated and parallel autoimmune events.

Chronic urticaria is more common in the age group of 20–35 years (27.04 ± 5.77 years)(as shown in Table 1) and more common in females than in males (74% were females and 26% were Males, as shown in chart 1) with female to male ratio of 2.8:1. In the present study, the statistical analysis of the obtained values showed that the serum anti-TPO antibodies levels were significantly increased in the chronic urticaria cases with mean ± SD 43.10 ± 7.78 IU/ml compared to the controls with mean ± SD 13.72 ± 1.28 IU/ml. The mean difference was statistically highly significant at P < 0.001 as shown in table 2. The majority of cases with increased levels of serum anti-TPO antibodies were in the age group of 25–35 years and the duration of disease ranged from 3 months to 2 years. Out of 50 cases, 60% cases had significantly increased levels of serum anti-TPO antibodies.

The cases with increased levels of serum anti-TPO antibodies were associated with thyroid abnormalities and subclinical hypothyroidism was the most common thyroid abnormality found in our study.

Work done by Turktas *et al.*,[10] Palma-Carlos *et al.*,[11] and Kasumagic-Halilovic *et al.*,[12] detected increased levels of anti-TPO antibodies in chronic urticaria patients. A retrospective longitudinal chart review study done by Amin *et al.*[13] in chronic urticaria patients found that 28.3% of patients had high-levels of serum anti-TPO antibodies. In the present study, serum anti-TPO antibodies levels were significantly increased in cases when compared to controls, thus correlating with above studies.

The statistical analysis of the obtained values showed that(as shown in table 2) mean ± SD of serum T3 levels for cases was 1.18 ± 0.24 ng/ml and for controls was 1.26 ± 0.13 ng/ml and was significantly decreased in cases compared to controls and the mean ± SD of serum T4 levels for cases was 7.64 ± 0.73 μg/dl and for control was 8.57 ± 0.54 μg/dl and was significantly decreased in chronic urticaria patients compared to healthy controls.

Among 50 chronic urticaria cases, one case had significantly decreased levels of serum T3 and T4 and 49 cases had serum T3 and T4 levels in within the normal limits but were nearer to the lower limit value. The statistical analysis of the obtained values showed that mean ± SD for levels of serum TSH for cases was 5.55 ± 1.03 μIU/ml and for controls was 2.86 ± 0.31 μIU/ml as shown in table 2. Mean ± SD of serum TSH levels was higher in cases than in controls and *P*<0.01 which was statistically significant.

Table 1: Sample distribution according to the age group, *n*=100

Age group (years)	Group I (Cases) *n*=50		Group II (Controls) *n*=50		Total
	X	%	Y	%	
10–15 years	01	2	01	2	2
16–20 years	06	12	06	12	12
21–25 years	12	24	12	24	24
26–30 years	14	28	15	30	29
31–35 years	17	34	16	32	33
Total	50	100%	50	100%	100

X: Number of cases. Y: Number of controls. N: Total cohort

Table 2: Comparison of mean±SD of serum anti-TPO, T3, T4, and TSH between two Groups, *n*=100

Mean±SD	Group I (Cases) (*n*=50)	Group II (Controls) (*n*=50)	*P*-value
Serum anti-TPO (IU/ml)	43.10±7.78 IU/ml	13.72±1.28 IU/ml	<0.001
Serum T3 (ng/ml)	1.18±0.24	1.26±0.13	<0.01
Serum T4 (μg/dl)	7.64±0.73	8.57±0.54	<0.05
Serum TSH (μIU/ml)	5.55±1.03	2.86±0.31	<0.001

TPO: Thyroid peroxidase, TSH: Thyroid-stimulating hormone

Table 3: Distribution of euthyroid, subclinical hypothyroid, and clinical hypothyroid status in patient group

Thyroid status	No. of female	No. of male	%
Euthyroid	29	10	78
Subclinical hypothyroidism	7	3	20
Clinical hypothyroidism	1	0	2
Total	37	13	100

Among 50 chronic urticaria cases, 11(22%) cases had significantly increased levels of TSH and 39 (78%) cases had serum TSH levels in within the normal limits but were nearer to the upper limit value. As shown in the table 3, among 11 cases with thyroid abnormalities, one case had clinical hypothyroidism and 10 cases had subclinical hypothyroidism.

In a study done by Mallick *et al.*[5] with 55 chronic urticaria cases, 45.5% patients had significantly increased levels of anti-TPO antibodies and 18.2% had hypothyroidism and our study results were consistent with above studies.

A case-control study performed by Diaz-Angulo *et al.*[14] from Spain detected increased levels of serum anti-TPO antibodies in 20.4% of chronic urticaria patients with *P* < 0.001. They also reported that 14.9% patients were detected with thyroid dysfunction and the most common thyroid abnormality was subclinical hypothyroidism (5.8%). In consistent with this study, in our study, also the most common thyroid abnormality in cases was subclinical hypothyroidism.

These findings may provide stimulus to further investigate the relationship between anti-TPO antibodies and thyroid abnormalities in chronic urticaria patients and also help in finding the subclinical hypothyroidism in chronic urticaria cases with high anti-TPO antibodies as the available data regarding these in our county is less.

CONCLUSION

This study revealed a significant association between chronic urticaria and serum anti-TPO antibodies. Serum anti-TPO antibodies and serum TSH levels were significantly increased and serum T3 and serum T4 levels were significantly decreased in chronic urticaria patients as compared to controls.

As the anti-TPO antibodies show slow cytotoxic progression, the most of the cases present as subclinical hypothyroidism and later on they progress to clinical hypothyroidism if left untreated. Hence, early detection of anti-TPO antibodies and thyroid dysfunction and periodic follow-up with proper management may help in better control of urticaria and prevent patients from going into disease related complications. This would help to improve the quality of life of the patients.

Hence, it is beneficial to consider testing for serum anti-TPO antibodies along with the primary thyroid markers serum T3, T4, and TSH to prevent long-term morbidity in chronic urticaria.

Limitations of the Study

Small sample size, follow-up, and response of the patient to the treatment were not taken into account.

REFERENCES

1. Confino-Cohen R, Chodick G, Shalev V, Leshno M, Kimhi O, Goldberg A. Chronic urticaria and autoimmunity: Associations found in a large population study. J Allergy Clin Immunol 2012;129:1307-13.
2. Bernstein JA, Lang DM, Khan DA, Craig T, Dreyfus D, Hsieh F, *et al*. The diagnosis and management of acute and chronic urticaria: 2014 update. J Allergy Clin Immunol 2014;133:1270-7.
3. Bracken SJ, Abraham S, MacLeod AS. Autoimmune theories of chronic spontaneous urticaria. Front Immunol 2019;10:627.
4. Kaplan AP. Diagnosis, pathogenesis, and treatment of chronic spontaneous urticaria. Allergy Asthma Proc 2018;39:184-90.
5. Abd Mallick Y, Hussain SA, Mansoor M, Gul S, Izhar M. Frequency of thyroid autoimmunity and thyroid dysfunction in patients of chronic spontaneous urticaria in our population. J Pak Assoc Dermatol 2019;29:361-8.
6. Najafipour M, Zareizadeh M, Najafipour F. Relationship between chronic urticaria and autoimmune thyroid disease. J Adv Pharm Technol Res 2018;9:158-61.
7. Nuzzo V, Tauchmanova L, Colasanti P, Zuccoli A, Colao A. Idiopathic chronic urticaria and thyroid autoimmunity: Experience of a single center. Dermatoendocrinol 2011;3:255-8.
8. Upadhyay P, Fiza B. Significance of anti-thyroperoxidase antibody estimation in patients with hypothyroidism. Int J Sci Res 2018;7:805.
9. Dutta J, Jain S, Jain A, Jain S, Jain S. An association of anti-thyroid peroxidase antibodies in clinical and subclinical hypothyroidism. Int J Clin Biochem Res 2019;6:415-20.
10. Turktas I, Gokcora N, Demirsoy S, Cakir N, Onal E. The association of chronic urticaria and angioedema with autoimmune thyroiditis. Int J Dermatol 1997;36:187-90.
11. Palma-Carlos AG, Palma-Carlos ML. Chronic urticaria and thyroid autoimmunity. Eur Ann Allergy Clin Immunol 2005;37:143-6.
12. Kasumagic-Halilovic E, Beslic N, Ovcina Kurtovic N. Thyroid autoimmunity in patients with chronic urticaria. Med Arch 2017;71:29.
13. Amin P, Levin L, Holmes SJ, Picard J, Bernstein JA. Investigation of patient-specific characteristics associated with treatment outcomes for chronic urticaria. J Allergy Clin Immunol 2015;3:400-7.
14. Díaz-Angulo S, López-Hoyos M, Munoz Cacho P, Fernández M, López-Escobar M, Rodríguez F, *et al*. Prevalence of thyroid autoimmunity in Spanish patients with chronic idiopathic urticaria: A case-control study involving 343 subjects. J Eur Acad Dermatol Venereol 2016;30:692-3.

How to cite this article: Kavitha J, Chowdary VR, Sulemani MD. Chronic Urticaria and Subclinical Hypothyroidism: A Cross-sectional Study. Int J Sci Stud 2022;9(10):54-58.

Source of Support: Nil, **Conflicts of Interest:** None declared.

Print ISSN: 2321-6379
Online ISSN: 2321-595X

Original Article

Role of Inflammatory Markers in the Severity and Outcome in Patients with COVID-19 Infection

Manasa A S Gowda[1], K Smruthi[2], T A Shilpa[1]

[1]Assistant Professor, Department of General Medicine, KIMS Hospital and Research Centre, Bengaluru, Karnataka, India, [2]Senior Resident, Department of General Medicine, KIMS Hospital and Research Centre, Bengaluru, Karnataka, India

Abstract

Introduction: Inflammatory responses triggered by active viral replication of severe acute respiratory syndrome coronavirus 2 plays a critical role in the pathogenesis of COVID-19 pneumonia. It induces the release of cytokines and chemokines. This study was undertaken to assess the role of inflammatory markers in COVID-19 infection.

Materials and Methods: This is a retrospective cohort study which included 200 patients with COVID-19 diagnosed by RTPCR positivity who were classified as severe and non-severe based on oxygen saturation levels.

Results: Among 200 patients who had COVID-19 infection, 56% were male and 44% were female with mean age group of 18–89 years. Among them, 58% had non-severe disease and 42% had severe disease. Out of 200 patients, 71% of them survived and 29% of them were non-survivors. In the present study, inflammatory markers were elevated among patients with severe disease than among patients with non-severe disease. The mean value of inflammatory markers among non-survivors was as follows NLR being 16.85, D-dimer 20.47, C reactive protein 13.49, lactate dehydrogenase 614.48, and ferritin 1182.51 showing statistically significant association with $P < 0.001$ among non-survivors when compared to survivors.

Conclusion: Our study showed that inflammatory markers were raised predominantly among patients who were classified as having severe pneumonia, which shows prognostic significance in the treatment of the disease.

Key words: Corona virus disease, Severe acute respiratory syndrome, Neutrophil lymphocyte ratio, D-dimer, C reactive protein, Lactate dehydrogenase, Ferritin

INTRODUCTION

The ongoing pandemic of COVID-19 has posed a huge threat to public health. Globally as of December 13, 2021, there have been 269,468,311 confirmed cases of COVID-19, including 5,304,248 deaths, reported to the World Health Organization (WHO).[1]

The pathogen has been identified as novel single-stranded ribonucleic acid beta coronavirus named as severe acute respiratory syndrome coronavirus 2 (SARS COV-2).[2]

Access this article online

IJSS

www.ijss-sn.com

Month of Submission : 11-2021
Month of Peer Review : 12-2021
Month of Acceptance : 12-2021
Month of Publishing : 01-2022

The clinical severity of COVID-19 ranged from asymptomatic to severe pneumonia, acute respiratory distress syndrome, and even death. Hence, monitoring and early intervention are the fundamental measures for favorable clinical outcome.[3]

Inflammatory responses triggered by rapid viral replication of SARS COV-2 play an important role in the progression of COVID-19. Cellular destruction recruits' macrophages and monocytes which in turn induces the release of cytokines and chemokines. In most cases, this process is capable of resolving the infection. However, in some cases, a dysfunctional immune response occurs, which can cause severe lung and even systemic pathology.[4] These cytokines and chemokines attract immune cells and activate them. Thus, the activated immune response leads to cytokine storm and progression of the disease, which can be monitored by measuring inflammatory markers.[5]

Corresponding Author: Dr. Manasa A S Gowda, House Number 2, Santhosh Vihar Phase 1, 19th A Cross, Jakkur Main Road, Bengaluru - 560 092, Karnataka, India.

Inflammatory markers such as procalcitonin, serum ferritin, ESR, C-reactive protein, and IL-6 have reported significant association with the severity of disease.[2]

Our study highlights the role of inflammatory markers in COVID-19 disease and further can assist in monitoring and prognosis of disease.

MATERIALS AND METHODS

This is a retrospective cohort study which included 200 patients with COVID-19 infection diagnosed by RTPCR positivity age >18 years at Kempegowda Institute of Medical Sciences, Bangalore.

In the present study, severe and non-severe disease was classified based on oxygen saturation levels: Non-severe disease with oxygen saturation >90% and severe disease with oxygen saturation <90% (based on the WHO criteria).

Data based on medical records of the hospital.

Statistical Analysis

Descriptive analysis was done using frequency and proportions for categorical variables, whereas mean and standard deviation for continuous variables.

Mann–Whitney test was used to compare the mean values of diagnostic markers based on the clinical severity and outcome.

ROC curve analysis was performed for diagnostic parameters for determining the cutoff between severe and non-severe and also between survivors and non-survivors of COVID-19 patients.

The level of significance was set at $P < 0.05$.

RESULTS

Among 200 patients who had COVID-19 infection, 56% were male and 44% were female with mean age group of 18–89 year. The demographic characteristics are as shown in Table 1.

In the study, out of 200 cases, 58% had non-severe disease and 42% had severe disease. Among 200, 71% survived and 29% died because of disease, as described in Table 2.

Inflammatory markers such as NLR, D-dimer, CRP, lactate dehydrogenase (LDH), and Ferritin showed significant association among patients with severe disease as described in Table 3.

Table 1: Demographic characteristics of patients

Age and Gender distribution among study patients			
Variable	**Category**	***n***	**%**
Age	≤ 20 years	4	2.0
	21–40 years	41	20.5
	41–60 years	88	44.0
	61–80 years	60	30.0
	>80 years	7	3.5
		Mean	**Standard deviation**
Gender	Mean	53.2	16.1
	Range	18–89	
	Male	112	56.0
	Female	88	44.0

Table 2: Distribution of patients based on the clinical severity and outcome

Variable	Category	*N*	%
Severity	Severe	84	42.0
	Non-severe	116	58.0
Survival	Survivor	142	71.0
	Non-survivor	58	29.0

Table 3: Comparison of mean values of diagnostic markers based on the clinical severity

Parameters	Severity	*n*	Mean	Standard deviation	Mean Diff	*P*-value
NLR	Severe	83	11.10	10.72	6.39	<0.001*
	Non-severe	115	4.71	7.68		
D-DIMER	Severe	84	14.27	91.89	13.42	<0.001*
	Non-severe	116	0.85	1.96		
CRP	Severe	84	10.12	16.32	5.77	<0.001*
	Non-severe	116	4.35	6.50		
LDH	Severe	55	576.59	364.36	233.98	<0.001*
	Non-severe	41	342.61	209.73		
FERRITIN	Severe	51	1051.80	1208.77	614.79	<0.001*
	Non-severe	62	437.01	424.55		

*p <0.05, LDH: Lactate dehydrogenase

Table 4: Comparison of mean values of diagnostic markers based on the outcome

Parameters	Outcome	*n*	Mean	Standard deviation	Mean Diff	*P*-value
Age	Survivor	140	49.96	16.26	−11.02	<0.001*
	Non-survivor	58	60.98	12.70		
NLR	Survivor	140	3.48	3.30	−13.37	<0.001*
	Non-survivor	58	16.85	12.76		
D-DIMER	Survivor	142	0.78	1.85	−19.69	<0.001*
	Non-survivor	58	20.47	110.31		
CRP	Survivor	142	4.03	5.74	−9.46	<0.001*
	Non-survivor	58	13.49	18.85		
LDH	Survivor	45	320.47	138.01	−294.01	<0.001*
	Non-survivor	51	614.48	382.36		
FERRITIN	Survivor	70	426.98	406.57	−755.53	<0.001*
	Non-survivor	43	1182.51	1272.57		

*p <0.05, LDH: Lactate dehydrogenase

Our study showed significant association of NLR, D-dimer, CRP, LDH, and Ferritin mean values with non-survivors with $P < 0.001$. This is described in Table 4.

ROC curve analysis showed that D-dimer, NLR, CRP, Ferritin, and LDH are fair enough test to detect inflammatory marker among severe and non-severe patients, as described in Table 5 and Figure 1.

DISCUSSION

Host cell exhibits different immunological reaction against various infectious agents. An effective immune response is essential to control viral infection; an exaggerated or prolonged response will result in immunopathogenesis.

Table 5: ROC curve analysis for diagnostic parameters for determining the cutoff between severe and non-severe COVID-19 patients

Variable	AUC	Std. Error	95% Conf. Interval		*P*-value	Cutoff	Sn (%)	Sp (%)
			Lower	Upper				
D-Dimer	0.76	0.04	0.70	0.82	<0.001*	>0.43	75.00	70.69
NLR	0.78	0.03	0.72	0.84	<0.001*	>3.77	75.90	71.30
CRP	0.72	0.04	0.65	0.78	<0.001*	>5.93	58.33	79.31
Ferritin	0.73	0.05	0.64	0.81	<0.001*	>879.5	50.98	90.32
	0.79	0.05	0.70	0.87	<0.001*	>323.0	85.45	70.73

*p <0.05, LDH: Lactate dehydrogenase

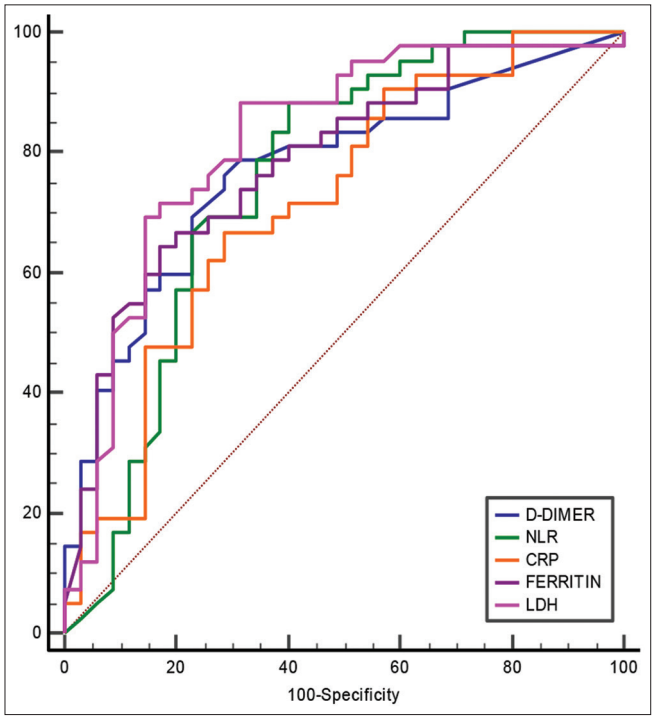

Figure 1: Comparison of ROC curves for different diagnostic parameters based on the severity

Excessive production of inflammatory mediators is involved in the pathogenesis of development of organ dysfunction. Hence, it is necessary to identify the rise in the level of inflammatory markers to monitor the progression of disease and to treat the patients at the earliest.[6]

Activation of neutrophils releases large amount of reactive oxygen species that causes DNA damage and further produces cytokines. Neutrophil releases are triggered by various inflammatory factors such as IL-6, IL-8, TNF-alpha, and granulocyte colony stimulating factors. Interferon-gamma produced by lymphocyte and endothelial cells.

Immune responses triggered by viral infection mainly depend on lymphocytes whereas systemic inflammation significantly depresses cellular immunity which decreases CD4+ lymphocyte and increases CD8+ suppressor lymphocyte. Thus, virus triggered inflammation increases NLR, which promotes COVID-19 progression.[7] Our study showed significant association between NLR and severe disease with mean being 11.10. The study done by Al-Ping Yang concluded that NLR is an independent prognostic biomarker for COVID-19 patients.[7]

CRP concentration is a very useful biochemical marker of inflammation, measurement of which contributes to monitoring of the response to treatment of inflammation and infection [8]. Ali et al. concluded that elevated level of CRP maybe a valuable early marker in predicting the severity of COVID 19 infection [9].Our study showed association between severe disease and C-reactive protein with mean being 10.12 and 4.35 among non-severe. A study done by Nurshad Ali showed that elevated levels of CRP may be valuable early marker in predicting the possibility of disease progression in non-severe patients with COVID-19 so that the treatment can be initiated at an early stage.[10]

D-dimer is also a marker of inflammation in addition to being a measure of hypercoagubility. In our study, mean value of D-dimer among severe disease was 14.27 and 0.85 among non-severe disease, which shows significant association among severe disease. Yumeng Yao *et al.* concluded that D-dimer is commonly elevated in patients with COVID-19 and it correlates with disease severity and is a reliable prognostic marker for in-hospital mortality in COVID-19 patients.[10]

LDH is an enzyme involved in energy production by interconversion of lactate and pyruvate. It is present in almost all body cells with the highest levels in heart, liver, lungs, muscles, kidney, and blood cells. LDH is released following acute or chronic tissue damage and is considered as an inflammatory marker. In COVID-19 patients, LDH

might represent as an expression of lung damage and might reflect the respiratory distress secondary to abnormal inflammatory status.[11] In a study done by Henry *et al*., they concluded that elevated LDH levels were associated with six fold increase in odds of developing severe disease and sixteen fold increase in odds of mortality in patients with COVID-19.[12] In our study, LDH has a significant association with severe disease with $P < 0.001$, mean being 576.59 among severe and 342.61 among non-severe COVID-19 patients.

Ferritin is an acute phase reactant elevated in inflammatory responses of any type. Study done by Katia Lino concluded that the magnitude of inflammation present at admission in COVID-19 patients represented by the high ferritin levels is an independent predictor of in hospital mortality.[13] In our study, mean serum ferritin was high among patients with severe disease with value around 1051.80 and 437 among non-severe COVID-19 patients.

In this study, we conclude that neutrophil lymphocyte ratio, D-dimer, C-reactive protein, LDH, and ferritin were positively correlated with severity of COVID-19 disease.

CONCLUSION

SARS COV-2 infection results in elevated levels of inflammatory markers, which may be associated with severity of the disease and the outcome. Hence, by monitoring the levels of inflammatory markers, one can predict the severity of the disease and its prognosis.

REFERENCES

1. Available form: https://www.COVID-19.who.net [Last accessed on 2021 Dec 13].
2. Zeng F, Huang Y, Guo Y, Yin M, Chen X, Xiao L, *et al*. Association of inflammatory markers with the severity of COVID 19: A metaanalysis. Int J Infect Dis 2020;96:467-74.
3. Guan WJ, Ni ZY, Hu Y, Liang WH, Ou CQ, He JX, *et al*. Clinical characteristics of coronavirus disease 2019 in china. N Engl J Med 2020;382:1708-20.
4. Tay MZ, Poh CM, Renia L, MacAry PA, Ng LF. The trinity of COVID 19: Immunity, inflammation and intervention. Nat Rev Immunol 2020;20:363-74.
5. Xu Z, Shi L, Wang Y, Zhang J, Huang L, Zhang C, *et al*. Pathological findings of COVID 19 associated with acute respiratory distress syndrome. Lancet Respir Med 2020;8:420-2.
6. Zeng Z, Yu H, Chen H, Qi W, Chen L, Chen G, *et al*. longitudinal changes of inflammatory parameters and their correlation with disease severity and outcomes in patients with COVID 19 from Wuhan, China. Crit Care 2020;24:525.
7. Yang AP, Liu JP, Tao WQ, Li HM. The diagnostic and predictive role of NLR, d-NLR and PLR in COVID-19 patients. Int Immunopharmacol 2020;84:106504.
8. Pepys MB, Hirschfield GM. C-reactive protein: A critical update. J Clin Invesr 2003;111:1805-12.
9. Ali N. Elevated level of C-reactive protein may be an early marker to predict risk for severity of COVID 19. J Med Virol 2020;92:2409-11.
10. Yao Y, Cao J, Wang Q, Shi Q, Liu K, Luo Z, *et al*. D-dimer as a biomarker for disease severity and mortality in COVID-19 patients: A case control study. J Intensive Care 2020;8:49.
11. Sepulveda J. Accurate results in the clinical laboratory. In: Dasgupta A, Sepulveda JL, editors. Challenges in Routine Clinical Chemistry Analysis: Proteins and Enzymes. Ch. 9. Netherlands: Elsevier; 2013. p. 131-48.
12. Henry BM, Aggarwal G, Wong J, Benoit S, Vikse J, Plebani M, *et al*. Lactate dehydrogenase levels predict coronavirus disease 2019 (COVID 19) severity and mortality: A pooled analysis. Am J Emerg Med 2020;38:1722-26.
13. Lino K, Guimarães GM, Alves LS, Oliveira AC, Faustino R, Fernandes CS, *et al*. Serum ferritin at admission in hospitalized COVID 19 patients as a predictor of mortality. Braz J Infect Dis 2021;25:101569.

How to cite this article: Gowda MAS, Smruthi K, Shilpa TA. Role of Inflammatory Markers in the Severity and Outcome in Patients with COVID-19 Infection. Int J Sci Stud 2022;9(10):59-62.

Source of Support: Nil, **Conflicts of Interest:** None declared.

Print ISSN: 2321-6379
Online ISSN: 2321-595X

Original Article

Reproductive Morbidity in Adolescents: A Case-control Study in the Central India

Meeta Banerjee, G K Banerjee

Assistant Professor, Department of Obstetrics and Gynaecology, R.D. Gardi Medical College, Ujjain, Madhya Pradesh, India

Abstract

Background: Adolescents are the rapidly growing segment of world's population and their health is not only important for their sake but is a major factor in determining the health of families and societies. International attention focused on maternal mortality but little is known about the prevalence of overall reproductive morbidity which is one of the important global health problems.

Objectives: Our objective was to assess the magnitude of obstetrics, gynecological, and family planning related problem in adolescent girls. The aim of the study was to study the incidence, complications, and outcome of teenage pregnancy as compared to adults. The study aimed to study gynecological morbidity and family planning related morbidity in adolescents as compared to adults.

Materials and Methods: Our study is a prospective, analytical, hospital-based case-control study conducted in the Department of Obstetrics and Gynaecology, M.G. Institute of Medical Sciences, Sevagram, Wardha, (Maharashtra). Two hundred and fifty adolescents' girls between 10 and 19 years were enrolled for the study along with 500 controls from adult age group. Obstetrics, gynecological, and family planning related morbidities among adolescents were studied. Prevalence measures and awareness were also noted.

Results: In our study, 250 adolescents of age group 10–19 years and 500 controls from adult age were enrolled. Out of 250 adolescents, 223 (89.2%) obstetrics cases and 27 cases had gynecological problems. The incidence of teenage pregnancy was 3.82% and 39 (17.5%) were unmarried. The majority of teenagers are primigravidas. Anemia was found more in adolescents 89.68% as compared to 78.02% in controls. The incidence of preeclampsia in study cases was 12.55% and 7.39% in controls. There was one case of eclampsia (0.44%) in study subjects as compared to 6 (1.34%) in controls. Preterm labor, intrauterine growth retardation (IUGR), and premature rupture of membranes, occurred more frequently in study subjects as compared to adults. Other complications which were observed in study and control were antepartum hemorrhage (0.89% and 3.36%), malpresentation (2.24% and 5.38%), and post-dated pregnancy (8.52% and 8.29%). About 2.48% in study subjects had postpartum hemorrhage compared to 0.28% in controls. In study subjects, vaginal deliveries – 78.26% and lower segment cesarian section (LSCS) – 18.64% of cases compared to 68.22% and 26.58% in controls. Fetal distress was common indication for LSCS in study subjects. The majority of gynecological morbidities in adolescents was menstrual complaints (88.85%) followed by pain in abdomen. Out of these four cases (14.80%) of ovarian tumors in adolescents out of which two were benign and two were malignant. Only 11.65% adolescents were using some form of contraception as compared to 19.5% in controls.

Conclusion: Teenage pregnancy is high risk for mother and baby both and may lead to various morbidities to both. Health education is important measure to prevent. Complications do occur in both adolescents and adult age group but adolescents are more prone to develop preeclampsia, anemia, preterm labor and IUGR. Proper prenatal care would reduce severity of the complications. The most of menstrual disorder are either due to endocrine abnormality or immaturity of hypothalamic-pituitary ovarian axis which needs further evaluation, correction, and awareness.

Key words: Adolescence, Contraception, Gynaecological morbidity, Prevention, Reproductive morbidity, Teenage pregnancy

Access this article online

IJSS

www.ijss-sn.com

Month of Submission : 11-2021
Month of Peer Review : 12-2021
Month of Acceptance : 12-2021
Month of Publishing : 01-2022

INTRODUCTION

Reproductive morbidity can be defined as any morbidity or dysfunction of reproductive organ or any morbidity which is a consequence of reproductive behavior including pregnancy, abortion, and child birth. It includes obstetrics, gynecological, and family planning related morbidity, and

Corresponding Author: Dr. Meeta Banerjee, Department of Obstetrics and Gynaecology, R.D. Gardi Medical College, Ujjain, Madhya Pradesh, India.

refers to condition of ill health related to reproductive process during and outside the child bearing episode.[1-4]

Adolescence is the period of life beginning with the appearance of secondary sexual characters and terminating with the cessation of somatic growth, roughly between 10 and 19 years. According to the WHO (1987), the adolescents are the phase of life between 10 and 19 years. About 50% of world's population is under the age of 20 (WHO, 1995), 22% of Indian population is believed to be between 10 and 19 years.[5]

Adolescence is the time of gradual transition from childhood to adulthood characterized by social and physical changes in the individual, a time of biological transition of sexual reproductive maturity, psychological transition to cognitive emotional patterns of adulthood, social transition of relative, and economic and social independence from parents. It is rapidly growing segment of world's population and a crucial period of life. Hence, reproductive health of adolescents should not be neglected.

International attention focused on maternal mortality in developing countries, especially mortality in adolescents but little is known about the prevalence of overall reproductive morbidity-estimated to be of much larger magnitude.[6]

Teenage pregnancies seem to be a higher risk of some of complications such as anemia, PIH, preterm labor, intrauterine growth retardation (IUGR), and adverse perinatal outcome. Gynecological morbidity in adolescents' girl could be as long-term sequalae of teenage pregnancies or it could be gynecological disorders which may have a devastating effect on her future fertility and child bearing.

Contraceptive knowledge and use among adolescents' women are important challenges as they initiate sexual activity and are exposed to risk of pregnancy. Contraceptive measures may also lead to comorbidities such as pelvic inflammatory disease, menstrual disorders, infertility, and obesity.

In the study, we aim to understand and study the reproductive morbidities-obstetrics, gynecological, and family planning related, among the adolescents' girls in comparison to adult age group.

MATERIALS AND METHODS

This study is a prospective and hospital-based case-control study that was conducted at M.G. Institute of Medical Sciences, Sevagram, Wardha, (Maharashtra) India from January 1997 to September 1998. Before commencement of the study, approval was sought and obtained from the Institution Ethics Committee.

Two hundred and fifty adolescents' girls between 10 and 19 years were enrolled as study subjects. Two controls were taken for each case study subject. One was the one admission before study subject and one was one admission after the study subject, making a total of 500 controls. Since the number of adolescents' subject is less compared to adults, 2 controls were taken to minimize the error. Out of 250 cases, 223 obstetrics and 27 gynecological enrolled and 446 obstetrics control and 54 gynecological control included in the study.

For each case under study detailed obstetrics, gynecological, medical, and surgical history was recorded on a predesigned proforma. General and systemic examination was done as initial assessment. Local per speculum examination was done in married girls and for unmarried girls rectal examination or gentle vaginal examination done if necessary and provisional diagnosis was made.

Investigation such as hemoglobin, blood grouping, and RH typing, urine albumin, sugar, biochemical and other hematological, radiological, and ultrasound was done as per need.

In obstetrics cases, mode of delivery and details of new born baby were recorded. Maternal morbidity, perinatal mortality, and morbidity were recorded. Women who did not deliver were followed up to delivery and their outcome was noted. Twenty women in study subjects and 22 controls were lost to follow-up. Hence, their outcome could not be recorded. In gynecological cases, procedure such as D and C, biopsy, and laparoscopy was done if required.

All the data obtained were entered in a pre-tested proforma and statistical analysis was performed using statistical package for the social sciences version 16.0.

RESULTS

Our study was prospective and hospital-based case-control study of 250 adolescents of 10–19 years age group along with 500 controls from adult age group – one control before study subject and one after the study subject. In our study, 223 obstetrics and 27 gynecological study subjects and 446 obstetrics control and 54 gynecological control enrolled. During the study period, the total number of obstetrics admission was 5832 giving the incidence of teenage pregnancies 3.82%. A total number of deliveries during the study period was 4204 and teenage deliveries were 161 (3.83%). The majority of study subject (92.8%) were of late adolescents (17–19 years). Youngest being 13 years. About 55.4%

controls were between 20 and 24 years. About 81.6% of study case belongs to the lower middle and lower socio-economic group. Literacy was found to be more in adolescents 66% as compared to 43% control (statistical significance $P < 0.05$). The mean age of menarche was 14.2 years in study cases and 13.88 years in controls. As per marital status, 24.4% of women from study were unmarried and 0.8% were unmarried in controls. The majority of study subjects (91.03%) were primis as compared to 47.75% in control. However, in study group, also 8.07% were second gravida.

Only 10.31% adolescents has hemoglobin (Hb) >10 g% as compared to 21.97% in controls. About 4.03% adolescents had severe anemia (Hb <6 g%) whereas only 1.79% controls had severe anemia (statistically significant $P < 0.05$).Overall anemia was found to be more in these young girls (89.68%) as compared to (78.02%) in controls [Figure 1]. Out of 41 abortions out of 223 study subjects, 13 (5.82%) were spontaneous and 27 (12.12%) were medical termination of pregnancy (MTP's) as compared to 3.34% and 5.15% in control. Of the 27 MTP's in study subjects, majority were unmarried girls (96.22%) between 17 and 19 years.

The incidence of preeclampsia in study case was 12.55% and 7.39% in control. There was one case of eclampsia (0.44%) in study subject as compared to 6 (1.34%) in control. Preterm labor, IUGR, and premature rupture of membranes (PROM) occurred more frequently in study subject as compared to adults. Other complications which were observed in study and control were antepartum hemorrhage (APH) (0.89% and 3.36%), malpresentation (2.24% and 5.38%), and post-dated pregnancy (8.52% and 8.29%). In study subject had 2.48% postpartum hemorrhage (PPH) compared to 0.28% in controls [Table 1].

About 78.26% of adolescents delivered vaginally and only 18.64% required lower segment cesarian section (LSCS) whereas in control was 68.22% and 26.57% [Figure 2]. About 86.66% of LSCS were done in emergency in adolescents and 71.56% in controls. Fetal distress was a common indication for LSCS in study subjects followed by cephalopelvic disproportion. Of the babies born to adolescents, 39.74% were low birth weight (<2.5 kg) as compared to 25.77% controls.

The majority of gynecological morbidity has menstrual complaints (88.88%) out of which oligomenorrhea (56%), thyroid dysfunction with menstrual disorder (16%), menorrhagia (36.25%), and polycystic ovarian syndrome (15%) were the common. There were four cases (14.80%) of ovarian tumors in adolescents out of which two were benign and two were malignant [Table 2]. Out of 12 neoplasm in control, 11 (20.37%) were fibroid and 1 case (1.85%) of carcinoma cervix. Only 11.65% adolescents were using some form of contraception as compared to 19.5% in controls.

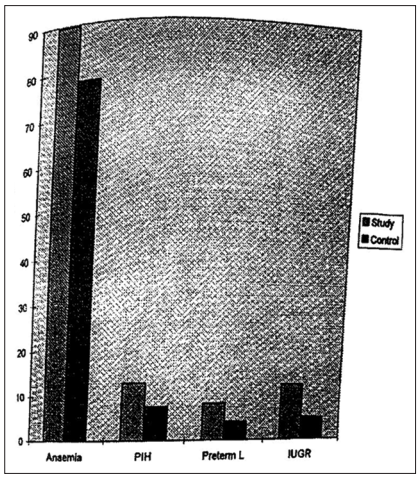

Figure 1: Distribution of cases (percentage) according of complications during pregancy

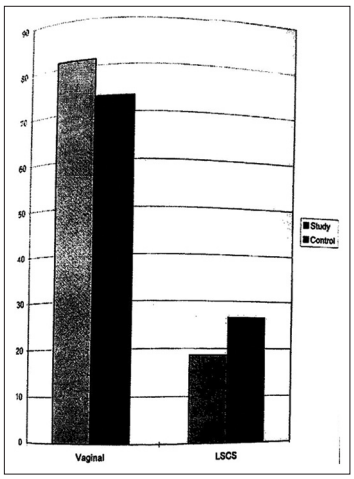

Figure 2: Distribution of cases according to mode of delivery

Table 1: Complication related to pregnancy in study subjects and controls

Complications	Study subjects (%)	Controls (%)
Preeclampsia	12.55	7.39
Eclampsia	0.44	1.34
Preterm labor	8.07	4.03
IUGR	12.10	4.93
Oligohydromnious	4.03	2.24
PROM	7.71	3.58
APH	0.89	3.36
Malpresentation	2.24	5.38
Post-date pregnancy	8.52	8.29
PPH	2.48	0.26

IUGR: Intrauterine growth retardation, PROM: Premature rupture of membranes, APH: Antepartum hemorrhage

Table 2: Gynecological morbidities

Symptoms/Clinical diagonosis	Study subjects (%)	Controls (%)
Menstrual disorders	88.85	77.26
Oligomenorrhea	56	
Menorrhagia	36.25	
Dysmenorrhea	22.21	
Thyroid dysfunction	16	
Polycystic ovarian syndrome	15	
White discharge P/V	11.11	26.07
Neoplasm		
Benign	7.4	20.37
Malignant	7.4	1.85

DISCUSSION

Adolescence, the transition period from childhood to adult autonomy, psychosexual development with acquisition of secondary sexual characters, and adult reproductive capacities, is a crucial period of human life. Adolescents have increased risk in health, social, psychological, educational, and vocational aspect of their life. The issue of pregnancy in young adolescents with its associated hazard is particularly significant in the Indian context since a large number of Indian girls marry and produce at a very young age. Teenage pregnancy can have adverse effects which lead to increase rate of morbidity and mortality with long-term sequalae for the mother and baby both. Hence, the reproductive morbidity among adolescents' girls is one of the major problems faced by health providers and planners especially obstetricians and gynecologists/neonatologists globally.[7-32]

The present prospective case-control study of 250 adolescents (223 obstetrics and 27 gynecological cases) and 500 adult controls was done to study the magnitude of reproductive morbidity in adolescent girls. Analysis of cases of adolescent age included in the study revealed that the most of them were in late adolescents, that is, 17–19 years (92.8%), and in control, the most of the women were between 20 and 24 years (55.4%). The majority of cases both in study (81.6%) and controls (79.8%) were from lower and lower middle class which is comparable to the study by Rani *et al.* (1992) who found 77% adolescents in low economic status. However, in the present series, 66.4% adolescents were literate as compared to 42.8% control (statistically significant $P < 0.05$) and are encouraging.

The incidence of teenage pregnancy was on the increase everywhere from 6.3% by Merchetti and Menkan (1950) to 21.12% by Goswain and Goswani (1989). After 1990s, reported incidence was 11.8% Chhabra (1991) and 8% was Rani *et al.* (1992). There seems to be decline in the incidence of teenage pregnancy after 1990s which may be due to increased literacy, little late marriage, and awareness about contraception. The incidence of teenage pregnancy in our study was 3.82% similar with above studies. Pachauri and Jamshedji 1983 quoted that the demographic consequences of teenage pregnancy are relevant for India where about 70% of girls are married between 15 and 19 years. In the present study, out of 250 cases, 75.6% adolescents were married before 20 years of age as compared to 380 (85.2%) out of 446 were married between 20 and 24 years in controls. Shrinivasan *et al.* (1991) found incidence of unmarried (20%) in his retrospective study of teenage pregnancy. In the present study, 91.03% adolescents were primi gravida as compared to 47.75% controls. A small significant number of teenage mother was multipara (7.18%) reflecting the early age of marriage in India. In the present study, the incidence of abortions among adolescents was found to be 18.38% as compared to 8.74% in controls. Of these, 5.82% were spontaneous and 12.5% were induced out of which 96.29% were unmarried girls and most of them (88.89%) were 17–19 years. In India, many times abortions in unmarried girls are done at private clinics or by quacks in village. Hence, it is impossible to determine the exact number of cases treated as they never bought to light unless complication occurs.

On looking into various complication of pregnancy, anemia was found to be common in these young girls. Adolescents are a period of rapid growth and have increased nutritional demand and pregnancy places additional nutritional demand and the end result of which is severe degree of anemia in the mother which subsequently complicate their pregnancy and affect the baby also. It was observed in one study, 89.69% had anemia as compared to 78.02% controls. Rami *et al.* (1992) reported high incidence 89% of anemia in adolescents whereas Pal *et al.* (1997) found 27.5% anemic adolescents. As anemia was unlikely due to malnutrition and iron deficiency, it could be corrected by proper diet, regular antenatal checkup, and iron supplementation. There is unanimous opinion that preeclampsia is more often present in younger age group. In present study, incidence was 12.55% in adolescents as compared to 7.05% in controls (statistically significant $P < 0.05$) which is comparable with studies Behera and Padke (1989) 13.5%; Chhabra (1991) 14%; Nayak *et al.* (1992)11.32%, and Pal *et al.* (1997) 15%. Various author hypothesized that underdeveloped incomplete endocrine system, incomplete uterine development, late irregular prenatal care, and improper diet are the predisposing factor to develop preeclampsia. The most of the studies had reported high incidence of preterm labor in adolescents. However, in our study, we found 8.07% adolescents had preterm

labor as compared to 4.03% in controls. Percentage in our study were less may be due to better antenatal care and more literacy found in our study. We observed 12.10% adolescents had IUGR babes as compared to 4.93% controls. Whereas Pal *et al.* (1997) reported, 27.5% in study cases compared to 8.7% in controls. About 7.17% study subjects had PROM as compared to 3.58% in controls. Nayak *et al.* (1992) also found almost same incidence in study (5.24%) and control (4.95%). Maternal age influences the outcome of pregnancy and labor and risk factors increase significantly at extremes of reproductive life as immaturity of birth canal and pelvis may have significant role for obstetric risk among young adolescents' girls. Hence, younger the adolescent more are the chances of operative interference. Short statured adolescents have more chances of LSCS because of small pelvis. We found 78.26% normal deliveries in adolescents as compared to 68.24% in control which is consistent with the findings of Biswas and Goswami (1983), Chhabra (1991), Nayak (1992), and Pal *et al.* (1997). In present study, 18.64% adolescents require LSCS as compared to 26.58% controls which is consistent with the previous above studies.

Gynecological morbidity can be a long-term sequalae of teenage pregnancy or other gynecological problems such as menstrual disorders and reproductive tract infection. In present study, we found oligomenorrhea (56%), menorrhagia (36.26%), thyroid dysfunction with menstrual disorder, and polycystic ovary syndrome (15%) which are compatable with the studies of David *et al.* (1998), Arora *et al.* (1992), and Vir (1990).

CONCLUSION

Reproductive morbidity in adolescent women is one of the major global health problems and should not be neglected. Teenage pregnancy is a high risk for mother and baby both and leads to various morbidities to both, teenage pregnancy seems to be a higher risk for various antenatal, natal, and post natal complications and many gynecological morbidity could be as long-term sequelae of teenage pregnancy. Important measures should be taken for prevention of teenage pregnancy such as delay marriage, delay first pregnancy, delay subsequent pregnancy-along with health education, contraception knowledge, and its uses. Although immaturity of hypothalamic pituitary ovarian axis is considered to be the most common cause of menstrual irregularities in adolescent girls, endocrine abnormalities, namely, thyroid dysfunction and hyperandrogenism may be responsible in some cases, thus warranting further evaluation.

REFERENCES

1. Amini SB, Patric M, Lerey J, Li M. Births to teenagers: Trends and obstetric outcome. J Obstet Gynaecol 1996;87:668-74.
2. Arora R, Rajaram P. Population based study of menstrual disorder in pondichery-a prelimenary study. J Obstel Gynaecol Ind 1992;42:492-7.
3. Bhaduria S, Singh S, Sarkar B. Teenage pregnancy-a retrospective study. J Obstel Gynecol Ind 1991;41:454-6.
4. Behera RC, Padke K. Unwanted adolescent pregnancy, it's present status. J Obstel Gynecol Ind 1991;41:25-9.
5. Bhatia BD, Chandra R. Adolescent mother-an un prepared child. Ind J Mat Child Health 1993;4:67-70.
6. Younis N, Khattab H, Zurayk H, El-Mouelhy M, Amin MF, Farag AM, *et al*. A community study of gynaecologicl and related morbidities in rural Egypt. Stud Fam Plann 1993;24:175-86.
7. Chhabra S. Perinatal outcome in Teenage mother. J Obstel Gynecol Ind 1991;41:30-6.
8. Coupey SM, Ahlstrom P. Common menstrual disorder. Pediatr Clin North Am 1989;36:551-71.
9. Datta K, Sharma R, Razak P. Matennal morbidities affects teens. Network 1994;14:8-11.
10. David A, Paul O. Abdominal pain. In: Garden AG, editor. Paeditdic and Adolescent Gynaecology. Berlin, Germany: Karger Publishers; 1998. p. 219-41.
11. Elster AB. The effect of maternal age, parity and perinatal care on perinatal outcome in adolescent mother. Am J Obstel Gynecol 1984;149:845-7.
12. Goswami BK, Goswami TK. Teenage pregnancy in rural area. J Obstel Gynecol Ind 1989;39:475-7.
13. Handa PR, Mahajan V, Gupta I. A comperative study of socio-clinical profile of ummarried and married subject seeking medical termination of pregnancy. J Obstel Gynecol Ind 1991;41:288-91.
14. Hughes ME, Fursten F, Teitter J. The impact of an increase in family planning on a teenage population of Philadelphia. Fam Plann Perspect 1995;22:246-52.
15. Joshi B, Mukherjee S, Patil A, Purandare A, Chauhan S, Vaidya R. A cross-sectional study of polycystic ovarian syndrome among adolescents and young girls in Mumbai, India. Indian J Endocrinol Metab 2014;18:317-24.
16. Khwaja SS, Sibai H, Suleiman A. Obstetric implication of pregnancy in adolescence. Acta Obstel Gynecol Scand 1986;65:57-61.
17. Konje JC, Palmer A, Watson A. Early teenage pregnancy in Hull. Br J Obstet Gynecol 1992;99:969-73.
18. Kristensen J, Langhoffross J, Kristen B. Implication of idiopathic preterm delivery for previous and subsequent pregnancies. Obstet Gycol 1995;86:800-4.
19. Millar HS, Lessar KB, Reed KL. Adolescence and very low birth weight infants disaproportionate association. J Obstet Gynecol 1996;87:83-8.
20. Nitwe MT, Desai V, Walrekar R. Teenage pregnancy-a health hazard. J Obtel Gynecol Ind 1989;39:303-6.
21. Osbourne GK, Howat RC, Jordom MM. The obstetric outcome of teenage pregnancy. Br J Obtet Gynecol 1981;88:215-21.
22. Pathak KB, Ram F. Adolescent motherhood: Problem and consequences. J Fam Welfare 1993;39:17-23.
23. Pal A, Gupta K, Randhawa I. Adolescent pregnancy-a high group. JAMA 1997;95:127-8.
24. Patted SA, RaoK, Ramkumar V. Adolescent pregnancy. J Obstet Gynecol Ind 1997;47:236-9.
25. Pachauri S, Jamshedji A. Risk of teenage pregnancy. J Obtet Gynecol Ind 1983;33:477-82.
26. Shrinivasan C, Shrinivasan J, Prabhu RB. Clinical study of teenage pregnancy. J Obstet Gynecol Ind 1985;35:666-9.
27. Salvi V, Damania K, Daftary S, Patel D. MTP's Indian adolescents. J Obstet Gynecol Ind 1991;41:33-6.
28. Vir S. Adolescent growth in girls. The Indian perspective. Ind Paediatr 1990;24:1249-55.
29. World Health Organization. Young People's Health: A Challenge for Society. WHO Technical Report Series. No 731. Geneva: World Health Organization; 1987. p. 9-17.

30. World Health Organization. Female Genital Mutilation Draft from a WHO Technical Working Meeting. Geneva: World Health Organization; 1995. p. 17-9.
31. World Health Organization. Complication of Abortion and their Prevention. Technical Report Series. 871. Geneva: World Health Organization; 1997. p. 54-8.
32. Waszah C. Contraceptive Method: A Teenage Perspective, Network. Geneva: World Health Organization; 1993.

How to cite this article: Banerjee M, Banerjee GK. Reproductive Morbidity in Adolescents: A Case-control Study in the Central India. Int J Sci Stud 2022;9(10):63-68.

Source of Support: Nil, **Conflicts of Interest:** None declared.

Print ISSN: 2321-6379
Online ISSN: 2321-595X

Original Article

Comparison of Efficacy of Intrathecal 2-Chloroprocaine and 2-Chloroprocaine with Fentanyl in Perianal Surgery: A Randomized Control Study

S Arivazhagan[1], T Padma Rubini[1], V Thiruchelvan[2]

[1]Assistant Professor, Department of Anesthesiology, Government Villupuram Medical College, Villupuram, Tamil Nadu, India, [2]Associate Professor, Department of Anaesthesiology, Government Medical College Kallakurichi, Villupuram, Tamil Nadu, India

Abstract

Background: Spinal anesthesia is considered a reliable and safe technique for perianal surgeries. The revival of older local anesthetics, such as 2-Chloroprocaine (CP) a short acting amino ester has been successfully used for spinal anesthesia in ambulatory setting. The addition of intrathecal opioids as adjuvants has been well proven to improve the quality of spinal anesthesia and prolong the duration of analgesia.

Aim: This study is aimed to evaluate and compare efficacy of spinal anesthesia and recovery profile using 2-CP and fentanyl as an adjuvant to 2-CP in elective perianal surgeries.

Materials and Methods: This prospective, randomized, and comparative study included 90 adult patients planned perianal surgeries with subarachnoid block. These patients were categorised into two groups and administered 30 mg of 2-CP and 0.4 ml normal saline intrathecally (Group A) or 30 mg of 2-CP and 0.4 ml (20 µg) fentanyl (Group B) intrathecally.

Results: A clinically significant difference in the meantime for sensory regression to L1 between two groups ($P < 0.001$) was witnessed in the study. The mean systolic blood pressure of Group A compared to Group B was lower and was statistically significant. With ($P < 0.0001$) between the two groups, there was statistical significance in the requirement of first rescue analgesia. There was no significant difference between groups in the intraoperative parameters of sensory and motor characteristics, including meantime to readiness for surgery, time to achieve peak sensory block.

Conclusion: The addition of fentanyl (20 mcg) to 2-CP (30 mg) has clinical value as it improved the quality of the block with a superior analgesic effect. In addition, it is an effective combination with a favorable recovery profile and immediate eligibility for home discharge compared with intrathecal 2-CP.

Key words: Adjuvants, Early discharge, Fentanyl, 2-chloroprocaine

INTRODUCTION

In daycare surgeries, spinal anesthesia is reliable, safe, and provides adequate analgesic effect but delayed ambulation and risk of urinary retention limit its use.[1] Recently, the revival of older local anesthetics such as 2-Chloroprocaine (CP) offers a solution for a search of ideal agents in the modern ambulatory setting.[2]

Local anesthesia is the chemical compound capable of reversibly inhibiting the propagation of impulses in nerve cells. Based on the link between the aromatic portion and the intermediate hydrocarbon chain, the amino ester group has an ester linkage, while the amino amides have an amide link.

Low doses of long-acting local anesthetics such as bupivacaine, ropivacaine, and levobupivacaine are commonly administered intrathecally. However, they cause

Access this article online

www.ijss-sn.com

Month of Submission : 11-2021
Month of Peer Review : 12-2021
Month of Acceptance : 12-2021
Month of Publishing : 01-2022

Corresponding Author: Dr. T Padma Rubini, Department of Anesthesiology, Government Villupuram Medical College, Villupuram, Tamil Nadu, India.

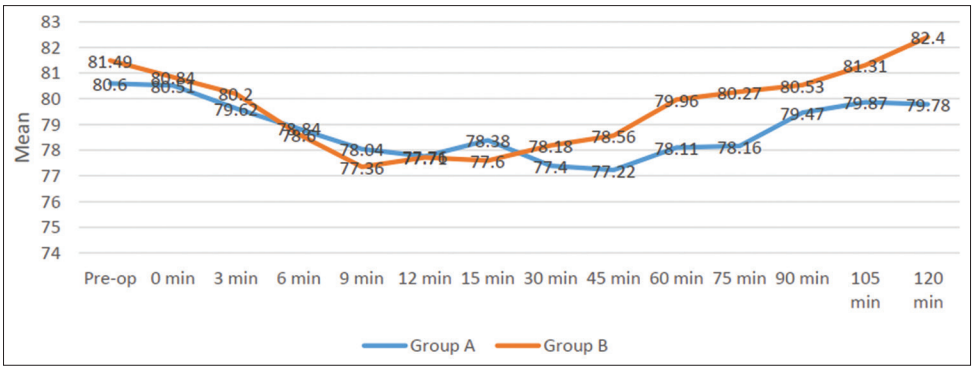

Figure 1: Mean pulse rate in the two groups

considerable delay in recovery, hospital discharge with lower block efficacy.[3]

2-CP, an amino ester local anesthetic, has been successfully used for spinal anesthesia since 1952.[4] In the early 1980s, it was withdrawn from commercial use due to concerns regarding neurotoxicity following accidental intrathecal injection during epidural labor analgesia.[5]

In recent studies, the preservative-free 2-CP seems to be a predictable drug with a good recovery profile and has generated interest among clinicians working in fast-paced ambulatory surgical settings.[6] 2-CP has advantages of quick onset and short duration of action. Plain 2-CP 1% free of both antioxidants and preservatives was introduced in 2004 and is less toxic than other local anesthetics. 2-CP has a rapid onset of action of 5–10 min because of its high tissue penetrance. The duration of the block is dose-dependent, with complete resolution of sensory block after 70–150 min with 30–60 mg.

The recent trend in ambulatory surgery is to administer a lower dose of local anesthetic with adjuvants such as opioids to provide segmental block; opioids create a synergistic effect by acting directly on opioid receptors in the spinal cord. The addition of intrathecal opioids as adjuvants improves the quality of spinal anesthesia and prolongs the duration of analgesia. Fentanyl is a synthetic opioid agonist which is 15–125 times more potent than morphine.

Fentanyl has pure agonist action on stereotypic μ type opioid receptors and can also bind to delta and kappa receptors with low affinity. It is very highly lipophilic, so it easily crosses the blood-brain barrier, decreases neurotransmission, and has a rapid onset of action with greater potency. Fentanyl has been proven to be a safe drug that enhances the analgesic effect when administered intrathecally. Fentanyl injected intrathecally would display moderate spinal selectivity, that is, provide the benefit of analgesia at the spinal level without the problems of respiratory depression at the systemic level.

Our study outcome was to estimate the onset and duration of sensory and motor blockade, evaluate the hemodynamic alteration, and estimate the time to reach eligibility for discharge from hospital if given in combination with opioid fentanyl.

MATERIALS AND METHODS

This prospective, randomized, and clinical study included that 90 patients (45 in each group) scheduled to undergo perianal surgeries were conducted at Government Villupuram Medical College. After being duly approved by the Institutional Ethics Committee, patients were enrolled after receiving informed consent between December 2019 and August 2020.

Patients with the American Society of Anesthesiologists physical status Class I and Class II of either sex, age between 18 and 60 years, weighing between 50 and 70 kg, and willing to participate were included in the study.

Patients with American Society of Anesthesiologists physical status Class III and Class IV aged above 18 years with a clinical condition such as any coagulopathy, taking anticoagulants therapy, neurological and musculoskeletal disorder, skin infection at lumbar area, allergy, or intolerance to local anesthetic were not willing to participate in the study and were excluded from the study.

Pre-anesthetic evaluation included, details (associated comorbidities, previous surgeries, medication, and drug allergy) were noted. General examination of height, weight, pulse rate, blood pressure (BP), oxygen saturation, and routine baseline investigations such as complete blood count, blood urea nitrogen and serum creatinine, random blood sugar, electrocardiogram, and chest X-ray was carried out. The anesthetic procedure was standardized for all patients, wherein they were instructed to overnight fasting for 6 h.

The patient was shifted to OT and baseline vital parameters were recorded. Then, intravenous access was secured using an 18G cannula and preloading was done with Ringer Lactate at 10 ml/kg.

After skin sterilization with betadine, the skin was infiltrated with 2% lignocaine in the L3-L4 interspace. Using 27G, Quincke's needle subarachnoid block was performed. The drug was injected as per the randomization group:

- GROUP A – 30 mg (3 ml) of 2-CP and 0.4 ml normal saline intrathecally
- GROUP B – 30 mg (3 ml) of 2-CP and 0.4 ml (20 μg) fentanyl intrathecally.

After completing the spinal injection, the patients were immediately placed in a supine position. After 5 min, the patients were put in the lithotomy position. Hemodynamic variables were recorded every 3 min for the first 15 min then every 5 min for the next 30 min and every 15 min for 120 min. Hypotension was treated with injection ephedrine 3 mg IV in incremental doses if systolic BP falls >20% from the baseline value. Bradycardia was treated if heart rate <50 beats/min with injection atropine 0.6 mg IV. Sensory and motor blockade was recorded for every 3 min during the initial 15 min period and after the surgical procedure. The time of completion of spinal drug injection was considered as zero time. The sensory level of the block was assessed in a caudal to cephalad direction by pinprick sensation using a 22Gsterile needle.

The time to readiness for surgery was assessed as the time interval between local anesthetic injection and the onset of complete loss of pinprick sensation in the anterior axillary bilaterally at T10 level. Other parameters observed were maximum sensory block height reached; time to reach maximum block height, time taken for regression to L1, time taken for complete regression of sensory block, time to ambulation, time to micturition, and time to eligibility for discharge from hospital were also recorded post-operation.

Statistical Analysis

The Chi-square test was used as a test of significance for qualitative data. An independent *t*-test was used as a test of significance between quantitative variables. $P < 0.05$ was considered statistically significant.

Statistical Software

MS Excel and Statistical Package for the Social Sciences version 22 (IBM SPSS Statistics, Somers NY, USA) were used to analyze data.

RESULTS

The demographic profile of patients in Groups A and B varied from 19 years to 53 and 55, respectively, as shown in Table 1. However, the distribution of patients across the age group was not significant ($P > 0.5$).

The Chi-square test shows no significant difference between the groups for males and females. ($P = 0.058$) as shown in the graph. The independent' *t*-test results revealed no significant difference in mean height ($P = 0.183$) and weight ($P = 0.643$) for the comparable groups.

The different types of surgical procedures were used in the study, showing no significant difference between the groups ($P = 0.337$).

The *P*-value of American Society of Anesthesiologists (ASA) physical status was 0.830, which was also statistically not significant. Although there was no significant difference in pulse rate, diastolic BP was noted between the two groups in the intra-operative and post-operative periods. The mean systolic BP of Group A compared to Group B was lower and statistically significant ($P = 0.016$) at 105 min intervals [Figures 1-4].

Five patients (11.1%) in Group A and two patients (4.4%) in Group B developed hypotension. One patient (2.2%) in Group B developed bradycardia with hypotension and treated with Atropine and Ephedrine. The Chi-square test shows no significant difference between the groups concerning complications [Figure 4].

There was no significant difference between groups in the meantime to readiness for surgery, time to achieve peak

Table 1: Distribution of patients characteristics

Patient's characteristics	Group A	Group B	*P*-value
Age	35.08±9.29	36.42±9.37	0.474
Height	161.68±4.97	160.2±5.5	0.183
Weight	67.82±8.37	66.93±9.7	0.643

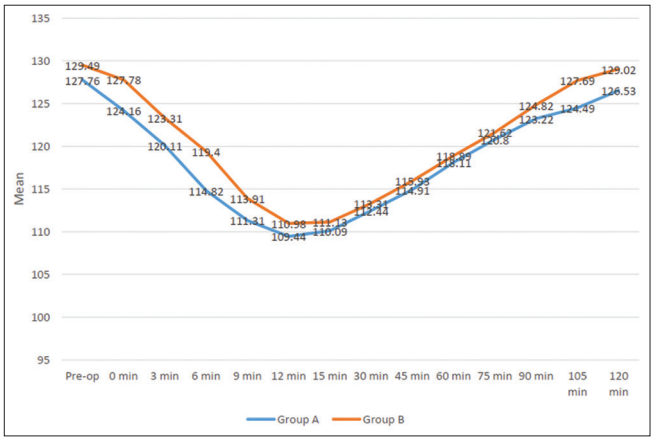

Figure 2: Mean systolic blood pressure in the two groups

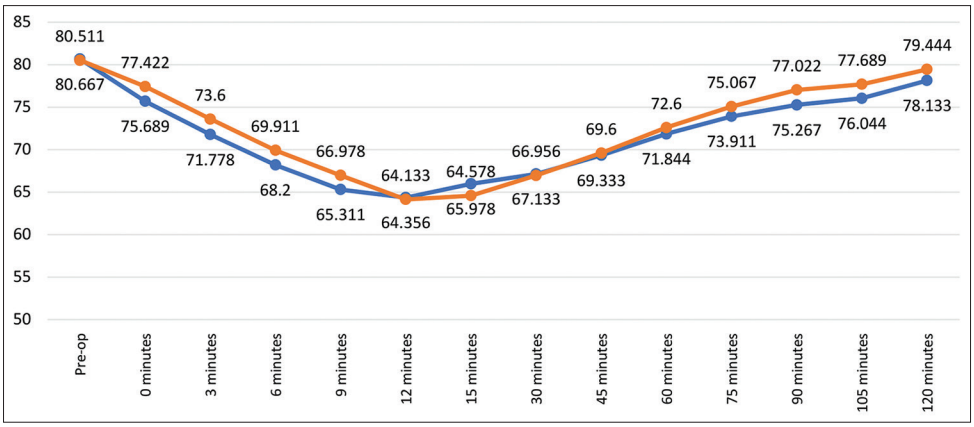

Figure 3: Mean comparison of diastolic blood pressure in the two groups

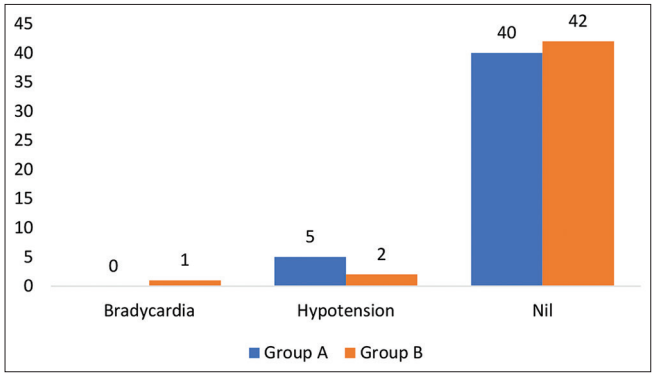

Figure 4: Distribution of complications

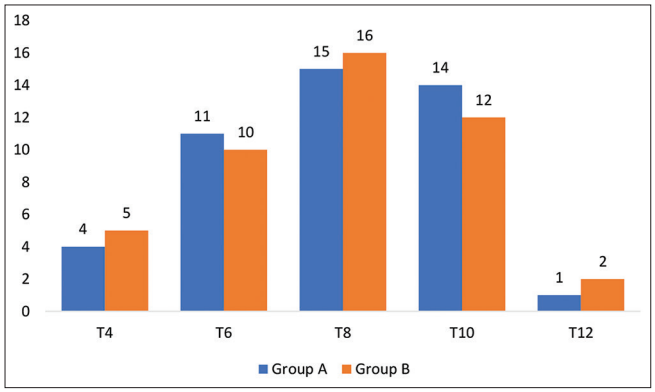

Figure 5: Maximum level of sensory block attained in two groups

sensory block, peak motor block, and time to reach motor block score of 4 [Table 2].

Group B had slower sensory regression to L1 than Group A and a clinically significant difference in the meantime for sensory regression to L1 between the two groups ($P < 0.001$). Regarding the duration of the sensory blockade and motor blockade, $P < 0.0001$ compared between two clinically significant groups. Group B had a longer sensory block and motor block duration than Group A [Figure 5 and Table 3].

In Group A, mean duration of requested rescue analgesia was 90.2 ± 8.2 min compared to Group B 125.44 ± 9.7 min with $P < 0.0001$, which was statistically significant.

The post-operative nausea and vomiting incidences were 4.4% and 2.1% in Groups A and B, respectively. The incidence of Pruritis in Group B was 55.6%, and there was no case in Group A, revealing a highly significant difference with $P < 0.001$. The mean time to ambulation in Group A and Group B was statistically significant with $P = 0.022$. The observed mean time for voiding in Group A compared to Group B was statistically significant with $P = 0.017$.

The observed mean time to reach eligibility for home discharge was almost similar in both groups (205.7 ± 13 min vs. 200.5 ± 12 min) with no clinically significant difference noted between Group A and Group B.

DISCUSSION

In the study by Schmittner *et al.*, spinal anesthesia is superior to total intravenous anesthesia in patients undergoing perianal surgery in terms of analgesic requirements and post-operative recovery.[7] The most of the perianal surgeries are short duration, to improve the perioperative efficiency, the intrathecal agent should provide rapid recovery with effective discharge time. One of the aminoester is 2-CP, with a short half-life of 40 min. Free of both antioxidants and preservatives, it was reintroduced in the market after being withdrawn due to neurotoxicity concerns. It fulfills the key criteria of an ideal intrathecal agent for ambulatory surgery.[8] 2-CP has a faster offset of action, leading to early post-operative pain, which is important in determining safe discharge. Intrathecal opioids provide effective analgesia in the post-operative period. Fentanyl, a short-acting lipophilic opioid, stimulates μ1 and μ2 receptors potentiating the afferent sensory blockade without prolonging recovery and facilitating a reduction in local anesthetic dose.[9] This study

Table 2: Distribution of intraoperative parameters

Intra operative parameters	Group A	Group B	*P*-value
Time to readiness for surgery	4.2±1.74	4.867±1.949	0.091
Time to achieve peak sensory block	6.6±1.763	7.267±1.75	0.075
Peak motor block achieved by Modified Bromage Scale	3.956±0.208	3.889±0.318	0.242
Time to reach motor block score of 4	4±1.43	4.533±1.517	0.09

Table 3: Distribution sensory and motor blockade

Patient's characteristics	Group A	Group B	*P*-value
Sensory regression to L1	59.66±6.6	72.77±8.56	<0.0001
Duration of sensory block	83.77±8.53	103.77±7.39	<0.0001
Duration of motor block	68.77±7.62	83.11±7.7	<0.0001
Duration of analgesia	90.22±8.25	125.44±9.76	<0.0001

was a prospective, randomized, and double-blinded clinical study. In our study, no statistically significant difference was found in both groups compared to age, sex, height, weight, ASA physical status, duration, and type of surgery. Based on the previous clinical studies observation, considering the type and duration of surgical procedure, in our study, we decided to perform spinal anesthesia in a sitting position with 30 mg of 2-CP in both groups.

Our study found that the meantime for surgery readiness (at T10) in both groups was not statistically significant. We observed faster onset than the time observed in the study done by Lacasse *et al.* (6 min).[10] Peak block height with relation to the height of patients was comparable. In Group A 8.9%, 24.4%, 33.3%, and 31.1% whereas in Group B 11.1%, 22.2%, 33.3%, and 26.7%, people achieved a peak block height of T4, T6, T8, and T10, respectively. The sensory level blockade T8 was noted in patients of both groups (33.3% vs. 33.3%).

In the study by Vath and Kopacz,[11] peak block height reached T3 level in the fentanyl group, which was higher compared to our study due to the low dose of 2-CP used in our study. In studies conducted by Bhaskara *et al.*[12] and Siddaiah *et al.*[13] with fentanyl as an adjuvant to 2-CP, the maximum level of sensory blockade observed was T8 with no statistical significance concurs with our study. In our study, the addition of intrathecal fentanyl resulted in prolongation of sensory blockade, as demonstrated by delay in time to L1 regression and complete sensory regression.

In our study, fentanyl significantly prolonged the post-operative analgesia by 1.65 times compared to another group. A significant prolongation of sensory and motor blockade by adding fentanyl to 2-CP was observed by Vaghadia *et al.*,[14] which was similar to our study. Our results were similar to the studies wherein Vath and Kopacz[11] used 20 μg of fentanyl with 2-CP, and Davis and Kopacz[15] added 15 μg of clonidine to 30 mg of 2-CP.

No dissimilarity was observed in both groups' quality and motor block onset. Yet, the duration of motor blockade was prolonged by 15 min in Group B. Indeed, adjuvants such as opioids remarkably minimize the complication by reducing the dose of local anesthesia. Our study patients neither developed desaturation nor apnea due to respiratory depression. A previous study found that 25 μg of intrathecal fentanyl was well tolerated in the elderly, but the incidence of respiratory depression has an increasing trend with a dose of 40–50 μg. Thus, our dose of fentanyl 20 μg is unlikely to cause respiratory depression.[16]

Our finding suggests that the addition of fentanyl (20 mcg) to 2-CP (30 mg) has clinical value as it improved the quality of the block with a superior analgesic effect. Furthermore, it is an effective combination with a favorable recovery profile and prompt eligibility for home discharge.

In our study, there was no remarkable difference in the time of voiding between the two groups but statistically significant compared to the study of Liu *et al.*,[17] where the meantime of voiding was not prolonged with the addition of a small dose of intrathecal fentanyl. Our data demonstrated that the time to void was shorter, and the incidence of urinary retention is negligible in the Fentanyl group. This effect might be explained by the fact that fentanyl decreases bladder compliance and causes relaxation of the internal urethral sphincter due to the potent inhibitory effect.

CONCLUSION

Our finding suggests that the addition of fentanyl (20 mcg) to 2-CP (30 mg) has clinical value as it improved the quality of the block with a superior analgesic effect. Furthermore, it is an effective combination with a favorable recovery profile and prompt eligibility for home discharge.

REFERENCES

1. Mulroy MF, Salinas FV, Larkin KL, Polissar NL. Ambulatory surgery patients may be discharged before voiding after short-acting spinal and epidural anesthesia. Anesthesiology 2002;97:315-9.
2. Förster JG, Kallio H, Rosenberg PH, Harilainen A, Sandelin J, Pitkänen MT. Chloroprocaine vs. articaine as spinal anaesthetics for day-case knee arthroscopy. Acta Anaesthesiol Scand 2011;55:273-81.
3. Förster JG, Rosenberg PH. Revival of old local anesthetics for spinal anesthesia in ambulatory surgery. Curr Opin Anaesthesiol 2011;24:633-7.
4. Foldes FF, McNall PG. 2-Chloroprocaine: A new local anesthetic agent.

Anesthesiology 1952;13:287-96.
5. Ravindran RS, Bond VK, Tasch MD, Gupta CD, Luerssen TG. Prolonged neural blockade following regional analgesia with 2-chloroprocaine. Anesth Analg 1980;59:447-51.
6. Smith KN, Kopacz DJ, McDonald SB. Spinal 2-chloroprocaine: A dose-ranging study and the effect of added epinephrine. Anesth Analg 2004;98:81-8.
7. Schmittner MD, Schreiber H, Janke A, Weiss C, Blunk J, Bussen DG, Luecke T. Randomized clinical trial of perianal surgery performed under spinal saddle block versus total intravenous anaesthesia. J Br Surg 2010;97:12-20.
8. Shariat A, Marcus B, Latmore M. High turnover for ambulatory orthopedic surgery. Curr Opin Anaesthesiol 2021;34:659-65.
9. Hindle A. Intrathecal opioids in the management of acute post-operative pain. Contin educ anaesthesia. Crit Care Pain 2008;8:81-5.
10. Lacasse MA, Roy JD, Forget J, Vandenbroucke F, Seal RF, Beaulieu D, *et al*. Comparison of bupivacaine and 2-chloroprocaine for spinal anesthesia for outpatient surgery: A double-blind randomised trial. Can J Anesth 2011;58:384-91.
11. Vath JS, Kopacz DJ. Spinal 2-chloroprocaine: The effect of added fentanyl. Anesth Analg 2004;98:89-94.
12. Bhaskara B, Prabhakar SA, Rangadhamaiah R. Intrathecal 1% 2-chloroprocaine with fentanyl in comparison with ropivacaine (0.5%) with fentanyl in day care perianal surgery: Prospective randomised comparative study. Anesth Essays Res 2019;13:471.
13. Siddaiah J, Pujari VS, Madalu AS, Bevinaguddaiah Y, Parate LH. A comparative study on the effect of addition of intrathecal buprenorphine to 2-chloroprocaine spinal anesthesia in short duration surgeries. J Anaesthesiol Clin Pharmacol 2019;35:533.
14. Vaghadia H, Neilson G, Lennox PH. Selective spinal anesthesia for outpatient transurethral prostatectomy (TURP): Randomised controlled comparison of chloroprocaine with lidocaine. Acta Anaesthesiol Scand 2012;56:217-23.
15. Davis BR, Kopacz DJ. Spinal 2-chloroprocaine: The effect of added clonidine. Anesth Analg 2005;100:559-65.
16. Celleno D, Capogna G, Emanuelli M, Sebastiani M, Costantino P, Cipriani G, *et al*. Ventilatory effects of subarachnoid fentanyl in the elderly. Anesth Analg 1990;70:S53.
17. Liu S, Chiu AA, Carpenter RL, Mulroy MF, Allen HW, Neal JM, *et al*. Fentanyl prolongs lidocaine spinal anesthesia without prolonging recovery. Anesth Analg 1995;80:730-4.

How to cite this article: Arivazhagan S, Rubini TP, Thiruchelvan V. Comparison of Efficacy of Intrathecal 2-Chloroprocaine and 2-Chloroprocaine with Fentanyl in Perianal Surgery: A Randomized Control Study. Int J Sci Stud 2022;9(10):69-74.

Source of Support: Nil, **Conflicts of Interest:** None declared.

Print ISSN: 2321-6379
Online ISSN: 2321-595X

Original Article

Role of Computed Tomography in Assessing Anatomical Variants of Nasal Cavity and Paranasal Sinuses in Chronic Sinusitis

A Aravindhan[1], M Annas[1], N Thamarai Selvi[1], A P Jaya Iswarya[2]

[1]Internship Students, Department of Radiology, A.C.S Medical College and Hospital, Chennai, Tamil Nadu, India, [2]Assistant Professor, Department of Radiology, Faculty of Allied Health Sciences, A.C.S Medical College and Hospital, Chennai, Tamil Nadu, India

Abstract

Introduction: Chronic sinusitis is an inflammation of the nasal cavity and paranasal sinuses (PNS) that lasts for at least 12 weeks.

Purpose: The aim of the study is to assess anatomical variants of nasal cavity and PNS in chronic sinusitis using 32 slice computed tomography.

Materials and Methods: A total of 100 patients with symptoms of chronic sinusitis were included in the study. All the patients in this study underwent computed tomography scan. The image was acquired in axial plane and coronal, sagittal planes were reconstructed.

Results: Among the sample with symptoms of chronic sinusitis which was monitored under computed tomography, radiological evidence of sinusitis was noted in 92% of patients, in this study, anatomical variants are key factors in causation of chronic sinusitis. Most common anatomical variants are deviated nasal septum, concha bullosa, and hypertrophified inferior turbinate.

Conclusion: Thus the study suggests that radiologists must pay close attention to anatomical variations in chronic sinusitis which can be better diagnosed using Computed Tomography.

Key words: Anatomical variants, Chronic Sinusitis, Computed Tomography, Deviated nasal septum, Paranasal sinuses

INTRODUCTION

Chronic sinusitis is defined as a long-term inflammation of the nasal cavity and paranasal sinuses (PNS). It occurs due to viral, bacterial, or fungal activities. Allergy, nasal polyposis, and mucosal vasomotor dysfunction are all possible conditions which occur in chronic sinusitis.[1] Computerized tomography (CT) scan can be used to examine the structure of the nasal cavity and PNS, as well as their drainage.[2]

Many staging systems for determining the severity of chronic sinusitis are based on CT scan imaging. By partitioning the PNS and staging them according to their opacity and mucosal thickness, CT can be utilized to estimate the severity of chronic sinusitis.[3] CT imaging is used to assess the anatomical variations in the nasal cavity and PNS, as well as the extent of the disease.[4]

A fundamental knowledge of the PNS anatomy is essential not only for the diagnosis of chronic sinusitis but also for the pre-operative planning before sinus surgery. However, orientation of the PNS still remains a challenge among otolaryngologists due to the anatomic variations and diversity of prevalence among different ethnicity. Divided anatomical variants into those with potential impact on sinus drainage and operative safety.[5]

A brief overview of PNS architecture is not only required for the diagnosis of chronic sinusitis, but also for pre-operative planning before sinus surgery.[5] The anatomic variants and diversity of frequency among different ethnicities make orienting the PNS a problem for otolaryngologists.[6] Anatomical variants were divided

Access this article online

www.ijss-sn.com

Month of Submission : 11-2021
Month of Peer Review : 12-2021
Month of Acceptance : 12-2021
Month of Publishing : 01-2022

Corresponding Author: A Aravindhan, NO 2/18 Nehru Street, M.A. Nagar, Redhills, Chennai - 600 052, Tamil Nadu, India.

into those that could have an impact on sinus drainage and operation safety.[7]

Concha bullosa, paradoxical middle turbinate, congenital absence of middle turbinate, pneumatized or absent uncinate process, septal pneumatisation, and bulla ethmoidalis are some of the conditions that affect sinus drainage.[8] Several of these anatomic anomalies can substantially block the osteomeatal complex.[9] As a result of these differences, normal mucociliary outflow in the sinuses is obstructed, increasing the risk of chronic sinusitis.[10] Anatomical anomalies that restrict the free flow of mucociliary movement have been associated to greater mucus viscosity and weakened mucosal immunity to sinus infections, according to the study. This explains the link between structural features of the PNS, such as size, location, and mucosal contact, and the progression and severity of chronic sinusitis in patients.[11] The aim of the study is to assess anatomical variants of nasal cavity and PNS in chronic sinusitis.

MATERIALS AND METHODS

This study was conducted in Department of Radiology and Imaging Technology, A.C.S Medical College and Hospital, Chennai, from period of January 2021 to July 2021 after getting clearance from Institutional Ethical Community; informed consent was obtained from all patients before investigations. In this study, 100 patients of both genders with a history of SINUSITIS were included. Patients were identified from those who were clinically diagnosed with SINUSITIS with symptoms of running nose, heaviness of head, sneeze, nasal blockage, facial pain, loss of smell, and fatigue were advised CT scan of PNS. Patients who had facial metallic implants and those who underwent functional endoscopic sinus surgery were excluded from the study. CT scan was done with field of view from frontal sinus to maxillary sinus on 32 slices (SEIMENS SOMATOM SCOPE). The study was acquired in axial plane and coronal and sagittal plane was reconstructed, the CT scan evaluated both sinonasal cavity and anatomical variants.

Statistical Methods

The recorded data were compiled and entered in a spreadsheet (Microsoft Excel) and then exported to data editor of SPSS version 21.0. Categorical variables were summarized as frequencies and percentages. Graphically, the data were presented by bar diagrams. Chi-square test was employed for comparing anatomical variants and age group. $P < 0.05$ was considered statistically significant.

RESULTS

A total of 100 patients who presented to the Department of Radiology, ACS medical College Hospital with diagnosis of chronic sinusitis were enrolled in the study. Among 100 patients, the age group of the patients was from 13 to 62 years. The youngest patient was 13-years-old and the oldest patient was 62-years-old [Figure 1]. The maximum number of patients with sinusitis was among the age group of 19–35 years accounting to 64% of the total cases [Table 1]. Regarding the gender, 67 were males and 33 were females in which male patients were more prone to chronic sinusitis when compared to females.

Running nose, nasal blockage, and headache were the most prevalent clinical complaints among the study participants, accounting for 30%, 23%, and 17%, respectively [Figure 2]. Under computed CT, the pathological states of 100 patients with long-term complaints were monitored. In the study population, radiological evidence of sinusitis was found in

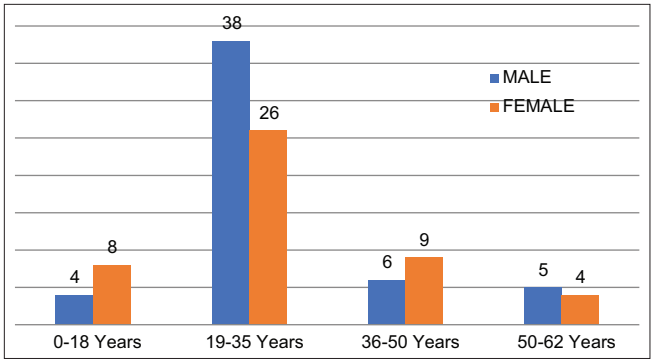

Figure 1: Age and sex distribution with condition of chronic sinusitis

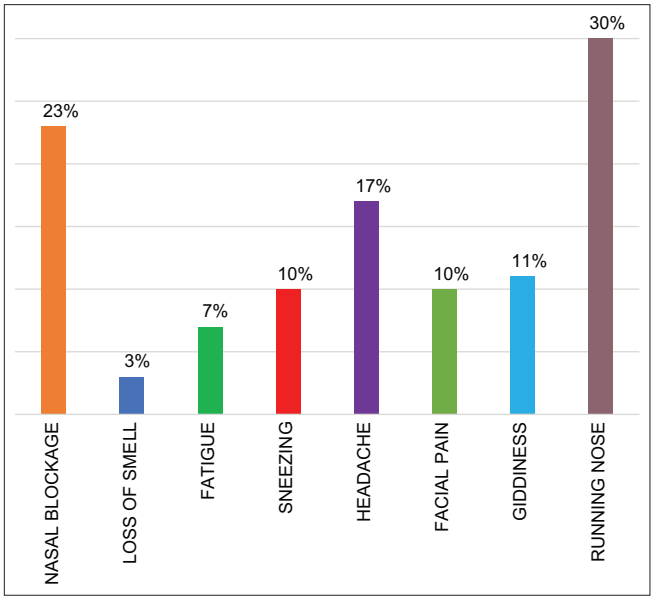

Figure 2: Symptoms of the patients included in this study

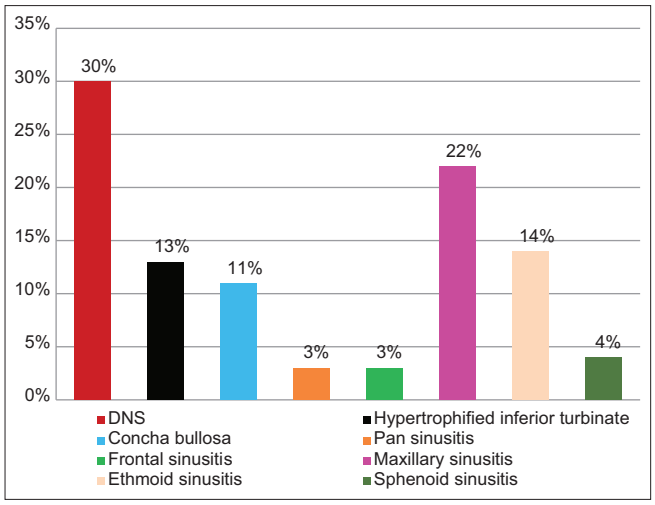

Figure 3: Conditions over a study group of 100 patients with prolonged symptoms

46% of the participants, with at least one of the PNSs being present. Deviated nasal septum (30%), bilateral maxillary sinusitis (22%), right ethmoid sinusitis (16.32%), ethmoid sinusitis bilateral (14%), hypertrophied inferior turbinate (13%), and concha bullosa (13%) were the most prevalent disorders with chronic symptoms (11%) [Figure 3]. About 46% patients who had only sinus pathology had maxillary sinusitis accounting for 22% [Table 2]. There is no significant association with sinus pathology and the age group of the study population ($P = 0.577$) [Table 3].

In the study, all the patients had at least one anatomical variant. Among the anatomical variants deviated nasal septum, hypertrophified inferior turbinate, and concha bullosa were the most common anatomical variants. About 56% patients who had only anatomical variants had deviated nasal septum accounting for 30%. In our study, DNS was the commonest variant (60%), followed by Concha Bullosa (26%) and hypertrophified inferior turbinate (22%). DNS were categorized into the left and right, left-sided DNS (31%) and right-sided DNS (20%) [Table 4]. There is no significant association with anatomical variants and the age group of the study population ($P = 0.947$) [Table 5].

DISCUSSION

Chronic sinusitis is a disorder that impairs the quality of life of more than 5% of the population and is caused mostly by anatomical blockage, infections, or allergies. According to the literatures, some of the region in PNS is at risk for injuries with consequential intra-operative complications. Hence, the knowledge on these PNS anatomical variants is essential for endoscopic surgeons as well as for radiologists for pre-operative evaluation and to avoid iatrogenic complications. Some of these variants are found to be associated with chronic sinusitis, possibly by obstructing drainage pathways from the sinuses and nasal cavity. Appropriate radiologic imaging and accurate interpretation of anatomical variants play an important role in the diagnosis and management of this chronic sinusitis.

Table 1: Age and sex distribution with condition of chronic sinusitis

Age (in years)	Male	Female
0–18	4	8
19–35	38	26
36–50	6	9
50–62	5	4

Table 2: Sinusitis conditions which were classified into the left, right, and bilateral sinusitis

Classification of sinusitis	Percentage
Left frontal sinusitis	2
Right frontal sinusitis	2
Bilateral frontal sinusitis	2
Left ethmoid sinusitis	2
Right ethmoid sinusitis	16
Bilateral ethmoid sinusitis	14
Left sphenoid sinusitis	2
Right sphenoid sinusitis	5
Bilateral sphenoid sinusitis	5
Left maxillary sinusitis	14
Right maxillary sinusitis	12
Bilateral maxillary sinusitis	24

Table 3: Significance between sinusitis and age group

Sinusitis	0–18 years	19–35 years	36–50 years	50–62 years
Frontal sinusitis	3	7	1	1
Maxillary sinusitis	5	17	10	12
Ethmoid sinusitis	2	12	8	6
Sphenoid sinusitis	1	5	1	1

CT provides comprehensive sinonasal anatomy for surgery and reveals great anatomical soft tissue and bone details, which aids in diagnosis. CT scans aid in determining the severity of sinus pathology as well as identifying anatomical abnormalities and their critical relationships with the PNS. In our study, we have observed about male patients were commonly prone to chronic sinusitis when compared to female; most male patients were in the age of 19–35 category. Surapaneni *et al.* 2016,[12] to evaluate the underlying cause, clinical features, and therapeutic impact on chronic sinusitis patients, found that 41.7% of chronic rhinosinusitis patients were between the ages of 16 and 30, which was similar to our findings. Another study by Gibelli *et al.* 2017[13] found that the affected age group for chronic

Table 4: Anatomical variants which were classified into left, right and bilateral variants

Anatomical variants	Percentage
Dns left	31
Dns right	20
Hypertrophified inferior turbinate left	6
Hypertrophified inferior turbinate right	9
Bilateral hyper trophified inferior turbinate	11
Right concha bullosa	6
Left concha bullosa	11
Bilateral concha bullosa	6

Table 5: Significance between anatomical variants and age group

Anatomical variants	0–18 years	19–35 years	36–50 years	50–62 years
Deviated nasal septum	3	15	7	5
Hypertrophied inferior turbinate	2	5	3	3
Concha bullosa	2	6	2	1

sinusitis was 21–40 years old, accounting for 65.3% of the study population.

In our study, we have observed about male patients were commonly prone to chronic sinusitis when compared to female which is similar to the study done by Mathuram *et al.*, 2019[14] revealed that males were more commonly affected with chronic sinusitis accounting for 58% and females accounted for 42%. This is also similar to the study conducted by Surapaneni *et al.* 2016[12] which had reported the incidence of male candidates affected to be 60% and females 40%. The most of the previous studies performed by Vinodhini *et al.*,[15] Dua *et al.*,[16] Iseh *et al.*,[17] and Gibelli *et al.*[13] had showed male preponderance with 66%, 57.5%, 52%, and 63%, respectively.

Numerous authors noted that certain anatomical variants have been associated with the pathophysiology of sinusitis particularly in sinus drainage. In our study, the most common clinical symptoms were running nose (30%), nasal obstruction (23%), headache (17%), and sneezing (10%). In the study conducted by Sandhu *et al.*, 2017,[18] the most common clinical symptoms were nasal obstruction (96%), headache (72%), and sneezing (60%). In our study, deviated nasal septum (30%) is the most common variant which is similar to the study done by Mathuram *et al.*, 2019,[14] among all the anatomical variants, deviated nasal septum is the most common variant, found in 142 study population accounting for 71% of cases. Most of the recent previous studies by Adeel *et al.*, 2013,[19] Aramani *et al.*, 2014,[20] and Suri *et al.*, 2016[21] had also showed that deviated nasal septum as most common anatomical variant accounting for 26%, 74.1%, and 75%, respectively. In a study done by Mamtha *et al.*,[22] prevalence of deviated nasal septum in chronic sinusitis cases was reported to be 60% and 65%, respectively. In our study, deviated nasal septum to the left was more common than to the right side, accounting for 31% which was similar to the study done by Marutham *et al.*, 2019,[14] which revealed that deviated nasal septum to the left was more common than to the right side, accounting for 40% on the left side. Similar to our study, the study done by Moorthy *et al.* in the year 2014[23] showed deviation of nasal septum to the left side (54%) more common than the right side (36.5%). Surapaneni *et al.* 2016[12] had concluded that CT scans to be valuable tool in diagnosing the disease which is similar to our study. The importance of anatomical variations in the development of chronic sinusitis has been questioned. Although the evidence suggests that anatomical variations increase the risk of developing chronic sinusitis.

CONCLUSION

CT plays an important role in the visualization of anatomical variants in PNS, and our study reemphasizes the concept that anatomical variations particularly in key factors are the causation of sinusitis. CT of the PNS has improved the visualization of PNS anatomy and has allowed greater accuracy in evaluating PNS disease. The PNS anatomical variants are highly variable as proved by various previous studies.

In our study, the most common anatomical variant was deviated nasal septum, followed by hypertrophified inferior turbinate and Concha Bullosa and most common sinusitis were maxillary sinusitis followed by ethmoid sinusitis. CT helps in evaluating the complex anatomy of PNS which is not possible with plain radiographs. We suggest that the radiologist must pay close attention to anatomical variants in the pre-operative evaluation and help avoid possible complications and improve success of management strategies.

ACKNOWLEDGEMENT

We deeply acknowledge the help rendered by Department of Radiology for their valuable contributions. I would like to sincerely thank all the patients for cooperating throughout the study.

REFERENCES

1. Scadding GK. Rhinitis and sinusitis. Clin Respir Med 2008;409-23. https://doi.org/10.1016/B978-032304825-5.10032-7
2. Cashman EC, MacMahon PJ, Smyth D. Computed tomography scans of

paranasal sinuses before functional endoscopic sinus surgery. World J Radiol 2011;3:199.
3. Rathor A, Bhattacharjee A. Clinical-radiological correlation and role of computed tomography staging in chronic rhinosinusitis. World J Otorhinolaryngol Head Neck Surg 2017;3:169-75.
4. Zinreich SJ. Paranasal sinus imaging. Otolaryngol Head Neck Surg 1990;103 Suppl 5:863-9.
5. Varshney H, Varshney J, Biswas S, Ghosh SK. Importance of CT scan of paranasal sinuses in the evaluation of the anatomical findings in patients suffering from sinonasal polyposis. Indian J Otolaryngol Head Neck Surg 2016;68:167-72.
6. Bolger WE, Parsons DS, Butzin CA. Paranasal sinus bony anatomic variations and mucosal abnormalities: CT analysis for endoscopic sinus surgery. Laryngoscope 1991;101:56-64.
7. Çalışkan A, Sumer AP, Bulut E. Evaluation of anatomical variations of the nasal cavity and ethmoidal complex on cone-beam computed tomography. Oral Radiol 2017;33:51-9.
8. Kalaiarasi R, Ramakrishnan V, Poyyamoli S. Anatomical variations of the middle turbinate concha bullosa and its relationship with chronic sinusitis: A prospective radiologic study. Int Arch Otorhinolaryngol 2018;22:297-302.
9. Leung RM, Kern RC, Conley DB, Tan BK, Chandra RK. Osteomeatal complex obstruction is not associated with adjacent sinus disease in chronic rhinosinusitis with polyps. Am J Rhinol Allergy 2011;25:401-3.
10. Nouraei SA, Elisay AR, Dimarco A, Abdi R, Majidi H, Madani SA, *et al*. Variations in paranasal sinus anatomy: Implications for the pathophysiology of chronic rhinosinusitis and safety of endoscopic sinus surgery. J Otolaryngol Head Neck Surg 2009;38:32.
11. Bachert C, Pawankar R, Zhang L, Bunnag C, Fokkens WJ, Hamilos DL, *et al*. ICON: Chronic rhinosinusitis. World Allergy Organ J 2014;7:1-28.
12. Surapaneni H, Sisodia SS. Aetiology, diagnosis and treatment of chronic rhinosinusitis: A study in a teaching hospital in Telangana. Int J Otorhinolaryngol Head Neck Surg 2016;2:14-7.
13. Gibelli D, Cellina M, Gibelli S, Oliva AG, Termine G, Sforza C. Anatomical variants of sphenoid sinuses pneumatisation: A CT scan study on a Northern Italian population. Radiol Med 2017;122:575-80.
14. Mathuram AC, Aiyappan SK, Agarwal S, Valsala NH, Shanmugam V. Assessment of sinonasal anatomical variants using 128-slice MDCT in patients with chronic rhinosinusitis. Int J Contemp Med Surg Radiol 2019;4:B120-6.
15. Vinodhini P, Bhat S, Sree Ram MN. Anatomical variations of the nose and paranasal sinuses in palakkad population using CT scan-a case control study. Online J Health Allied Sci 2017;16:6.
16. Dua K, Chopra H, Khurana AS, Munjal M. CT scan variations in chronic sinusitis. Indian J Radiol Imaging 2005;15:315-20.
17. Iseh KR, Makusidi MM. Rhinosinusitis; a retrospective analysis of clinical pattern and outcome in North Western Nigeria. Ann Afr Med 2010;9:20-6.
18. Sandhu S, Gupta V, Matreja PS. Clinicotherapeutic profile of patients suffering from sinusitis. J Transm Dis Immun 2017;1:1.
19. Adeel M, Rajput MS, Akhter S, Ikram M, Arain A, Khattak YJ. Anatomical variations of nose and para-nasal sinuses; CT scan review. J Pak Med Assoc 2013;63:317-9.
20. Aramani A, Karadi RN, Kumar S. A study of anatomical variations of osteomeatal complex in chronic rhinosinusitis patients-CT findings. J Clin Diagn Res 2014;8:KC01-4.
21. Suri N, Janardan T, Parmar H. Correlation of anatomical variations of paranasal sinuses and chronic rhinosinusitis. IAIM 2016;3:8488.
22. Mamtha H, Shamasundar NM, Bharathi MB, Prasanna LC. Variations of osteomeatal complex and its applied anatomy: A CT scan study. Indian J Sci Technol 2010;3:904-7.
23. Moorthy P, Kolloju S, Madhira S, Jowkar A. Clinical study on deviated nasal septum and its associated pathology. Int J Otolaryngol Head Neck Surg 2014;3:75-81.

How to cite this article: Aravindhan A, Annas M, Thamarai Selvi N, Iswarya AP. Role of Computed Tomography in Assessing Anatomical Variants of Nasal Cavity and Paranasal Sinuses in Chronic Sinusitis. Int J Sci Stud 2022;9(10):75-79.

Source of Support: Nil, **Conflicts of Interest:** None declared.

Print ISSN: 2321-6379
Online ISSN: 2321-595X

Original Article

Echocardiographic Evaluation of Asymptomatic Type 2 Diabetes Mellitus Patients for Cardiovascular Disease in a Tertiary Care Hospital

Parimal Sarkar[1], B Khaham Debbarma[2]

[1]Associate Professor, Department of General Medicine, Agartala Government Medical College and GB Pant Hospital, Agartala, Tripura, India, [2]Post Graduate Trainee, Department of General Medicine, Agartala Government Medical College and GB pant Hospital, Agartala, Tripura, India

Abstract

Introduction: Diabetes mellitus (DM) is one of the most common diseases in the world and is acquiring epidemic proportions. Its prevalence is growing in both developed and developing countries. It is a major risk factor for cardiovascular diseases (CVD) and CVD is the leading cause of morbidity and mortality in people with diabetes. The diastolic abnormalities are present in diabetic patients without overt diabetic complications of the cardiovascular system; It is the earliest and specific functional abnormality in diabetic cardiomyopathy and can affect patients who are free of macrovascular complications. Left ventricular diastolic dysfunction (LVDD) thus represents the first stage of diabetic cardiomyopathy preceding changes in systolic function, reinforcing the importance of early examination of ventricular function in individuals with diabetes.

Material and Methods: It is an observational, Hospital-based Cross-Sectional study. It was carried out among outpatient and inpatient with type 2 DM as per the American Diabetes Association's guidelines attending the General Medicine department of AGMC and GBP Hospital. Sample size was 100 patients.

Results: Of 100 types 2 DM study participants 40.0% were female and 60.0% were male. Mean age of patients was 52.8000 ± 6.2829. About 64.0% patients had LVDD out of 100 patients. 93.8% had LVDD grade 1 and 6.3% patients had LVDD grade 2. 8.0% patients had left ventricular systolic dysfunction among 100 patients. Diastolic dysfunction is significantly associated with increasing age, duration of diabetes, and glycemic index assessed by glycosylated haemoglobin (HbA1c).

Conclusion: the prevalence of LVDD in type 2 Diabetic Mellitus without any cardiovascular symptoms is much higher than previously suspected. Diastolic dysfunction is significantly associated with increasing age, duration of diabetes, and glycemic index assessed by HbA1c. Early diagnosis and treatment for LVDD in diabetic patients without any cardiac symptoms will reduce morbidity and improve outcomes by preventing future development of heart failure.

Key words: Diabetes, Left ventricular Diastolic dysfunction

INTRODUCTION

Diabetes mellitus (DM) is one of the most common diseases in the world and is acquiring epidemic proportions. Its prevalence is growing in both developed and developing countries. Its incidence is increasing rapidly, and by 2030, this number is estimated to be almost double. The greatest increase in prevalence is, expected to occur in Asia and Africa.

Access this article online

www.ijss-sn.com

Month of Submission : 11-2021
Month of Peer Review : 12-2021
Month of Acceptance : 12-2021
Month of Publishing : 01-2022

India has more diabetics than any other country in the world, according to the International Diabetes Foundation. The disease affects more than 50 million Indians (7.1% of the nation's adults) and kills about 1 million Indians a year. The average age of onset is 42.5 years.[1]

DM is a heterogeneous group of metabolic disorders characterized by chronic hyperglycemia with disturbance of carbohydrate, fat, and protein metabolism. It results from defects in insulin secretion, insulin action, or both. The effect of DM includes long-term damage, dysfunction, and failure of various organs such as eyes, kidneys, nerves,

Corresponding Author: Dr. B Khaham Debbarma, Department of General Medicine, Agartala Government Medical College and GB pant Hospital, Agartala, Tripura, India.

heart, brain, and blood vessels. Several distinct types of DM are caused by complex interaction of genetics and environmental factors.

The persistence of these metabolic disturbances leads to permanent and irreversible functional and structural changes in the cells of the body which in turn lead to the development of "diabetic complications," characteristically affecting, the cardiovascular system, eye, kidney, and nervous system mainly.

Diabetes is a life-threatening condition, It is a major risk factor for cardiovascular diseases (CVD) and CVD is the leading cause of morbidity and mortality in people with diabetes. Four million people die each year as a result of diabetes and a high proportion of these deaths are attributable to CVD complications such as heart attack and stroke.

Given that people with diabetes are at greater risk of CVD, increasing their knowledge and awareness of CVD at the right time can reduce the chances of developing diabetes complications and thus help to reduce diabetes morbidity and mortality.

The existence of a diabetic cardiomyopathy was first proposed by Rubler *et al.* in 1972 on the basis of post-mortem findings. In 1974, Framingham study showed that heart failure was more common in diabetes due to diabetic cardiomyopathy. The Framingham Study demonstrated that patients with diabetes had a greater likelihood of developing clinical heart failure. The relative risk of developing heart failure was 3.8 in diabetic men and 5.5 in diabetic women compared with non-diabetic patients. The study also revealed a marked increase in congestive heart failure, coronary artery disease, and myocardial Infarction in diabetic patients.[2]

Patients with signs and symptoms of heart failure with preserved left ventricular systolic function, i.e., ejection fraction of 60% are said to have diastolic heart failure (DHF). DHF is observed in 40% of patients with other heart failure. DM is one of the major risk factors for DHF. The mortality rates among the patients with DHF ranges from 5 to 8% annually as compared with 10 to 15% among patients with systolic heart failure.[3]

In the Framingham heart study, it was shown that patients with DM carry an increased risk for coronary heart disease (CHD). Framingham data suggest that hyperglycemia as such is an independent risk factor.

The leading cause of left ventricular systolic dysfunction (LVSD) and congestive heart failure in developed countries is CHD with a prevalence in the recent multi-center heart failure trials of 66%. Thus, CHD often contributes to the manifestation of heart failure, and the progression of heart failure in many cases may be a reflection of progression of CHD. This indicates that the prevention and treatment of heart failure in many patients should include the use of established primary and secondary prevention guidelines, including control of blood pressure, use of statins and aspirin, smoking cessation, and implementation of angiotensin-converting enzyme inhibitor therapy in persons with diabetes and cardiovascular risk factors.

Despite similar LVSD, patients with diabetes have more pronounced heart failure symptoms, use more diuretics, and have an adverse prognosis compared with those without diabetes; one putative explanation for these discrepancies is diastolic dysfunction of the left ventricle in DM.[4]

Left ventricular diastolic dysfunction (LVDD) thus represents the first stage of diabetic cardiomyopathy preceding changes in systolic function, reinforcing the importance of early examination of ventricular function in individuals with diabetes.[5,6] Its timely recognition may help to avoid or significantly delay the concept of CHF.

The diastolic abnormalities are present in diabetic patients without overt diabetic complications of the cardiovascular system;[7] It is the earliest and specific functional abnormality in diabetic cardiomyopathy and can affect patients who are free of macrovascular complications, even in newly diagnosed DM patients or in those with a disease duration of <1 year.[8]

Diastolic dysfunction refers to a condition in which abnormalities in mechanical function are present during diastole. The causes of diastolic dysfunction may be subdivided into a decrease in passive myocardial diastolic compliance, and an impairment in active left ventricular relaxation. Abnormalities in diastolic function may occur in the presence or absence of a clinical syndrome of heart failure and with normal or abnormal systolic function. Therefore, whereas diastolic dysfunction describes an abnormal mechanical property, DHF describes a clinical syndrome.

Currently, the only available surrogate measure of diastolic function is echocardiography. Assessment of mitral valve inflow using pulsed wave Doppler is used routinely in clinical practice to noninvasively identify the five progressive filling categories: normal, abnormal relaxation, pseudo-normal, reversible restrictive filling and non-reversible restrictive filling, based upon early (E) and late (A) peak filling velocities and E deceleration time.

In view of the above facts, this study is designed and proposed to be conducted for the 1st time at AGMC and GBP Hospital to study echocardiography of type 2 DM patients who do not have any cardiovascular symptoms, as this kind of study has never been conducted earlier in any tertiary care hospitals of Tripura, India.

Aim and Objectives

Aim

To study echocardiography of type 2 DM patients who do not have any cardiovascular symptoms.

Objectives

1. To assess the cardiac status of type 2 DM patients by echocardiography, who are otherwise asymptomatic clinically of any cardiovascular symptoms.
2. To determine the association of diastolic dysfunction with the socio-demographic factors (age and sex), duration of DM, glycemic control, and obesity indices.

MATERIALS AND METHODS

Study Design

Hospital-based Cross-Sectional study.

Type of Study

Observational study.

Study Setting

Department of General medicine, AGMC and GB Pant Hospital.

Study Duration

1 ½ year.

Study Population

Outpatient and inpatient with type 2 DM as per American Diabetes Association's (ADA) guidelines attending the General Medicine department of AGMC and GBP Hospital and following exclusion and inclusion criteria were included in the study.

Sample Size

100.

Sample Technique

Systemic random sampling.

Operational Definitions

- Diagnosis of type 2 DM was made as per ADA guidelines
- Diagnostic criteria (American diabetes association)
- FBS ≥126 mg/dl
- 2 h plasma glucose ≥200 mg/dl during an OGTT.
- RBS ≥200 mg/dl with symptoms (polyuria, polydipsia, polyphagia, and weight loss) Glycosylated hemoglobin
- HbA1C >6.5%.

Body Mass Index (BMI)

BMI Was derived from the weight (kilograms) and height (metres) by using formula - weight(kilograms)/[height(metres)]^2. Using this the patients were categorized as underweight (BMI <18.5 kg/m^2), normal weight (BMI between 18.5 and 22.9 kg/m^2), overweight (BMI between 23.0 and 24.9 kg/m^2), and obese (BMI ≥25 kg/m^2) based on revised consensus guidelines for India. The mean BMI (mean ± s.d) of patients was 24.5268 ± 2.7819.

Diagnosis of LVDD

Reduction in peak velocity of early mitral flow (E), increase over peak velocity of late mitral flow (A), with E/A ratio of <1, and increase in left atrial (LA) size with preserved ejection fraction were considered as the evidence of LVDD.

Inclusion Criteria

Patients of both sex aged above 30 years, with type 2 DM with no clinical symptoms of cardiovascular involvement and blood pressure <130/80 mm Hg with normal ECG, without renal impairment and without any neurologic impairment.

Exclusion Criteria

Patients with type 2 DM with evidence of CHD, Congenital heart disease, valvular heart diseases, cardiomyopathies, hypertensive patients, patients with previously diagnosed LVSD, age more than 60 years, Those who did not give consent to participate in the study.

Method of Data Collection

All the cases were selected consecutively during the study period when they are presented following the inclusion and exclusion criteria. The data were collected from type 2 DM patients attending AGMC and GBP Hospital, Agartala.

All the patients were personally subjected to detailed history regarding name, age, sex, occupation, socio-economic status, educational status, chief complaints, present illness, past illness, general physical examination, and systemic examination. These findings were recorded in a predesigned and pretested proforma.

Investigations

The following investigations were undertaken immediately after admission Complete hemogram, random blood sugar, fasting blood sugar, Post-prandial blood sugar, HbA1c, renal function test, serum electrolytes, fasting lipid profile, urine routine, and microscopy, fundoscopy, electrocardiogram, chest radiography, liver function tests, and 2D echocardiography.

The diastolic function was evaluated using M mode and two-dimensional transthoracic echocardiography and color flow Doppler examination.

In the Doppler study following values were evaluated.

a. E- peak velocity of early mitral flow
b. A- peak velocity of late mitral flow
c. E/A ratio
d. LA size: Reduction in E velocity, increase in A velocity,
e. E/A <1 and increase in LA size is considered as the evidence of LVDD.

Consent for collecting the required data was obtained. A pre-structured proforma was used to record the relevant information from each individual subjects selected for the study.

Data Management

After completion of data collection, the obtained data were coded and entered into Microsoft excel worksheet and was subjected for statistical analysis using Statistical Package for the Social Sciences (SPSS) software.

For categorical data, comparison was done by chi-square test or Fisher's exact test and for continuous data *t*-test or Z- test was applied.

Statistical Analysis

For statistical analysis, data were entered into a Microsoft Excel spreadsheet and then analyzed by SPSS (version 27.0; SPSS Inc., Chicago, IL, USA) and Graph Pad Prism version 5. Data had been summarized as mean and standard deviation for numerical variables and count and percentages for categorical variables. Two-sample *t*-tests for a difference in mean involved independent samples or unpaired samples. Paired *t*-tests were a form of blocking and had greater power than unpaired tests. One-way analysis of variance (one-way ANOVA) was a technique used to compare means of three or more samples for numerical data (using the F distribution). A Chi-squared test (χ^2-test) was any statistical hypothesis test wherein the sampling distribution of the test statistic is a chi-squared distribution when the null hypothesis is true. Without other qualifications, "Chi-squared test" often is used as short for Pearson's chi-squared test. Unpaired proportions were compared by Chi-square test or Fischer's exact test, as appropriate. Explicit expressions that can be used to carry out various *t*-tests are given below. In each case, the formula for a test statistic that either exactly follows or closely approximates a *t*-distribution under the null hypothesis is given. Furthermore, the appropriate degrees of freedom are given in each case. Each of these statistics can be used to carry out either a one-tailed test or a two-tailed test. Once a *t* value is determined, a *P*-value can be found using a table of values from Student's t-distribution. If the calculated *P*-value is below the threshold chosen for statistical significance (usually the 0.10, the 0.05, or 0.01 level), then the null hypothesis is rejected in favor of the alternative hypothesis. $P \leq 0.05$ was considered for statistically significant.

RESULTS

In our study, 6 (6.0%) patients were 30–40 years old, 34 (34.0%) patients were 41–50 years old and 60 (60.0%) patients were 51–60 years old. The mean age (mean ± s.d.) of patients was 52.8000 ± 6.2829 Figure 1.

In our study, 40 (40.0%) patients were female and 60 (60.0%) patients were male Figure 2.

In our study, 24 (24.0%) patients had normal weight, 44 (44.0%) patients were obese, 30 (30.0%) patients had over weight and 2 (2.0%) patients had under weight Figure 3.

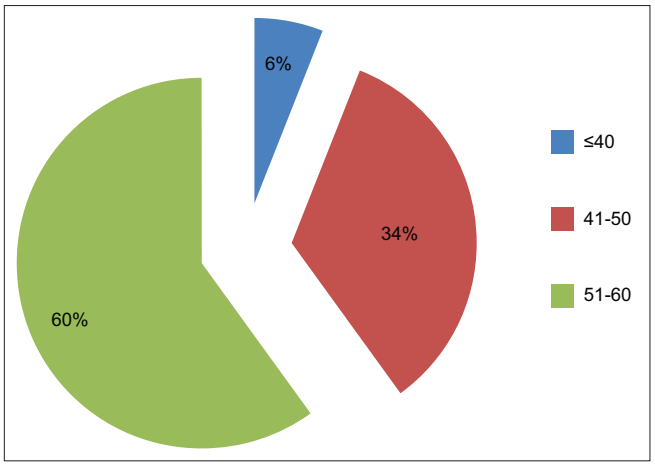

Figure 1: Distribution of age

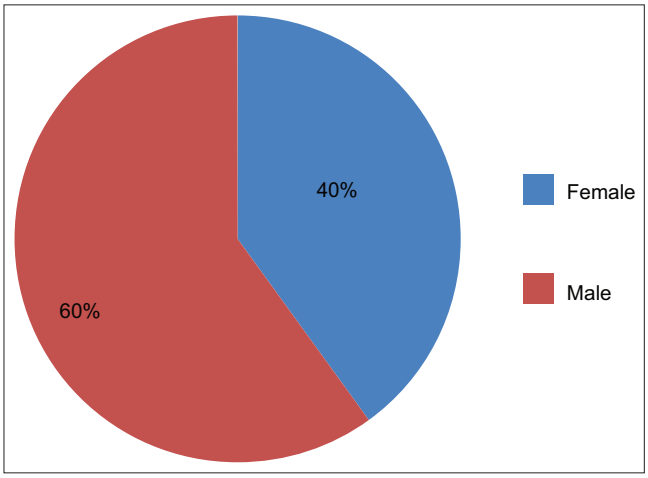

Figure 2: Distribution of sex

In our study, 18 (18.0%) patients were in <10 years duration of diabetes, 82 (82.0%) patients were in >10 years duration of diabetes. The mean duration of diabetes in years (mean ± s.d.) of patients was 16.5800 ± 6.2671 Figure 4.

In our study, 36 (36.0%) patients were HBA1c level 6.5–8.0, 44 (44.0%) patients were HBA1c level 8.1–10.0 and 20 (20.0%) patients were HBA1c level >10.0. The mean HBA1c (mean ± s.d.) of patients was 8.7572 ± 1.5427 Figure 5.

The mean FBS (mean ± s.d.) of patients was 152.5920 ± 46.3410. The mean PPBS (mean ± s.d.) of patients was 286.6580 ± 73.8340. The mean EF (mean ± s.d.) of patients was 62.5160 ± 7.4088 Table 1.

In our study, 64 (64.0%) patients had LVDD Figure 6 and Table 2.

In our study, 60 (93.8%) patients had LVDD grade 1 and 4 (6.3%) patients had LVDD grade 2 Figure 7 and Table 3.

In our study, 8 (8.0%) patients had LVSD Figure 8 and Table 4.

In our study, 12(12.0%) patients had Concentric left ventricular hypertrophy (LVH) Figure 9.

In LVDD, 2 (3.1%) patients were 30–40 years old, 14(21.9%) patients were 41–50 years old and 48(75.0%)

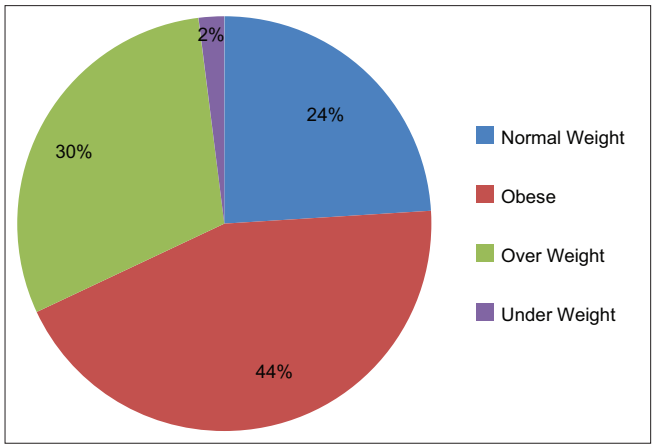

Figure 3: Distribution of body mass index

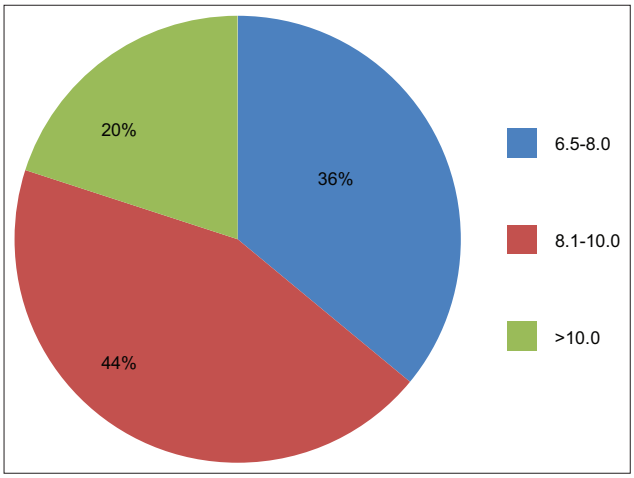

Figure 5: Distribution of glycosylated hemoglobin

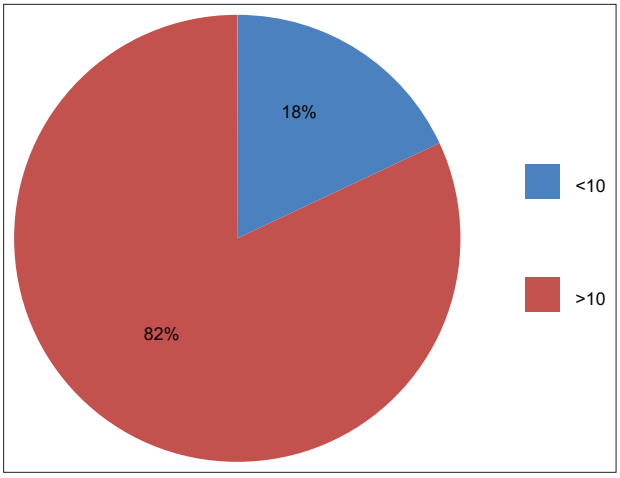

Figure 4: Distribution of duration of diabetes

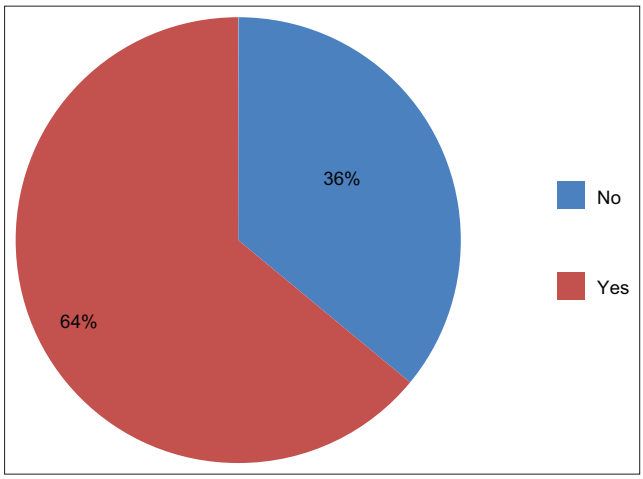

Figure 6: Distribution of left ventricular diastolic dysfunction

Table 1: Distribution of LVDD

LVDD	Frequency	Percent
No	36	36.0
Yes	64	64.0
Total	100	100.0

Table 2: Distribution of LVDD grade

LVDD grade	Frequency	Percent
Grade 1	60	93.8
Grade 2	4	6.3
Total	64	100.0

patients were 51–60 years old. Association of Age with LVDD was statistically significant ($P = 0.0002$) Figure 10.

In LVDD, 22(34.4%) patients were female and 42(65.6%) patients were male. The association of sex with LVDD was not statistically significant ($P = 0.1257$).

In the LVDD Group, 14(21.9%) patients had normal weight, 16(25.0%) patients had over Weight, 32(50.0%) patients were obese, and 2(3.1%) patients had under weight. Association of BMI with LVDD was not statistically significant ($P = 0.2218$) Figure 11.

In the LVDD Group, 2 (3.1%) patients were in <10 years duration of diabetes, 62 (96.9%) patients were in >10 years duration of diabetes. The Association between duration of diabetes and LVDD was statistically significant ($P < 0.0001$) Figure 12.

In LVDD, 6 (9.4%) patients were HBA1c level 6.5–8.0, 38 (59.4%) patients were HBA1c level 8.1–10.0 and 20 (31.3%) patients were HBA1c level >10.0. Association of HBA1c with LVDD was statistically significant ($P < 0.0001$) Figure 13.

DISCUSSION

The present study was carried out as an observational type hospital-based Cross-Sectional study at the Department

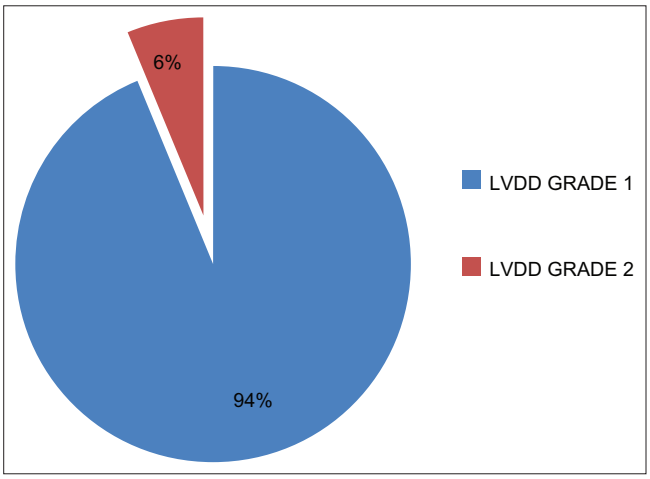

Figure 7: Distribution of left ventricular diastolic dysfunction grade

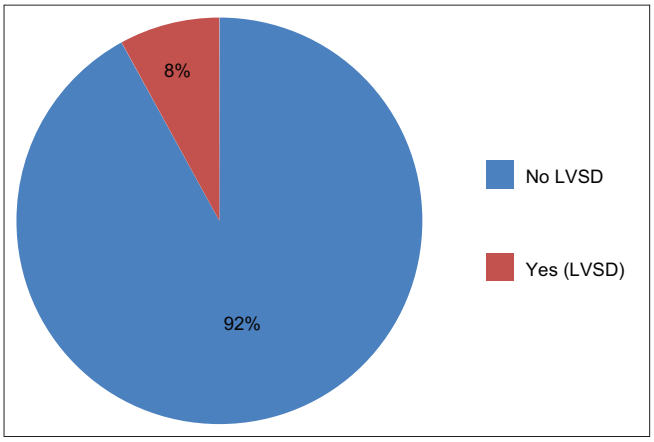

Figure 8: Distribution of left ventricular systolic dysfunction

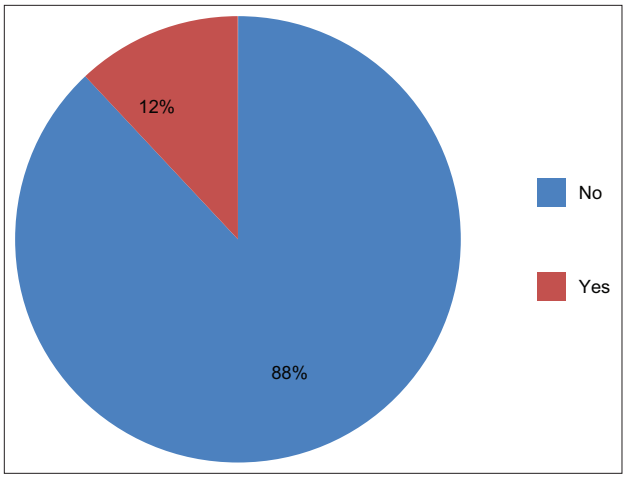

Figure 9: Distribution of concentric left ventricular hypertrophy

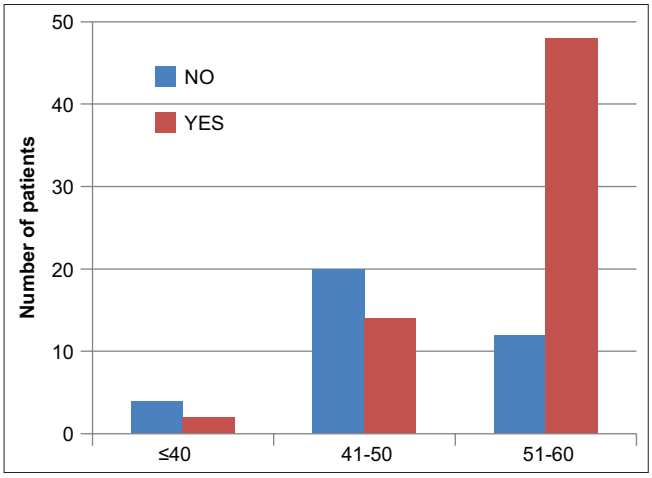

Figure 10: Association between age and LVDD

Table 3: Distribution of LVSD

LVSD	Frequency	Percent
No	92	92.0
Yes	8	8.0
Total	100	100.0

Table 4: Distribution of concentric LVH

Concentric LVH	Frequency	Percent
No	88	88.0
Yes	12	12.0
Total	100	100.0

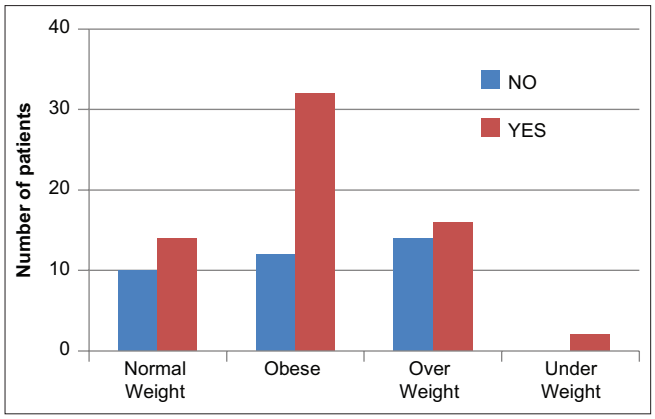

Figure 11: Association between BMI and LVDD

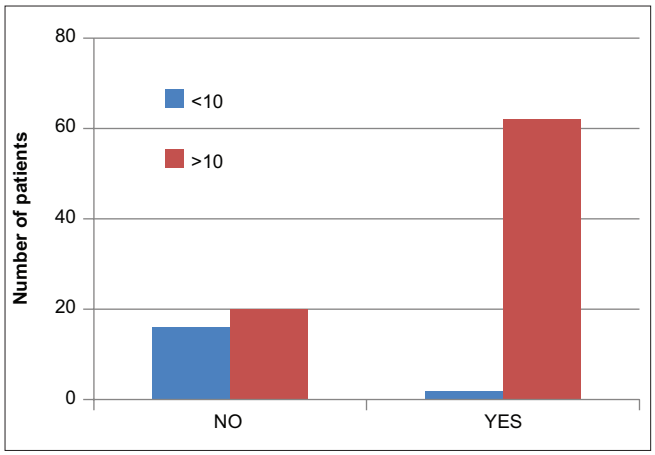

Figure 12: Association between duration of diabetes and left ventricular diastolic dysfunction

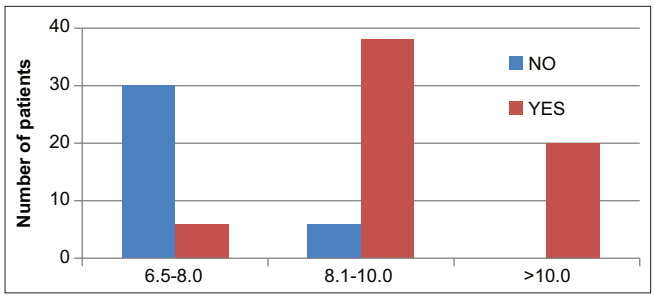

Figure13: Association between HBA1c and LVDD.

of General Medicine, AGMC, and GB Pant Hospital and taken 1 ½ years. We have collected data from Outpatient and inpatient with type 2 DM, as per ADA guidelines, attending the General Medicine department of AGMC and GBP Hospital as per the exclusion and inclusion criteria. A total of 100 patients was taken in our study.

In our study, out of 100 patients, 6.0% were ≤40 years old, 34.0% were between 41 and 50 years old and 60.0% were between 51 and 60 years old. 40.0% of patients were female and 60.0% patients were male out of 100 patients. About 18.0% were in <10 years duration of diabetes Group, 82.0% were in >10 years duration of diabetes group out of 100 patients. Our study found that 24.0% had normal weight, 44.0% were obese, 30.0% were over weight and 2.0% were under weight. Of 100 patients 36.0% had HBA1c level 6.5–8.0, 44.0% HBA1c level 8.1–10.0 and 20.0% had HBA1c level >10.0.

In our study, 64.0% of patients had LVDD out of 100 patients. Patil *et al.*[9] in their study observed LVDD in 64% of their patient, which is similar to our study. Ayman *et al.*[10] in their study observed LVDD in 61% of their patient, which is similar to our study. In our study, 93.8% had LVDD grade 1 and 6.3% of patients had LVDD grade 2, among LVDD patients. Arora *et al.*[11] in their study observed mild, moderate, and severe LVDD among 41%, 10%, and 2% of the subjects respectively, which is similar to our study. In our study, 8.0% of patients had LVSD among 100 patients. Arora *et al.*[11] 38% of patients were detected with LVSD. The finding in their study is not similar to our study. Kumar *et al.*[12] in their study assessed systolic function by fractional shortening (FS) and EF. EF though it is reduced in diabetes patients, it is within normal limits with a mean of 57.98 ± 2.1. The finding in their study is similar to our study. About 12.0% patients had Concentric LVH.

In our study we observed that among the patients with LVDD, 3.1% patients were between 30 and 40 years old, 21.9% patients were between 41 and 50 years old and 75.0% patients were between 51 and 60 years old. Association of Age with LVDD was statistically significant ($P = 0.0002$). Arora *et al.*[11] found Type II DM has a significant impact on the functioning of the left ventricular. This effect increases with the advancing age. Patil *et al.*[9] found there was a linear progression of diastolic dysfunction with the increase age group. Mahesh *et al.*[13] found that Diastolic dysfunction was found to be significantly higher among elderly individuals (60%) when compared to young study participants. The above three studies have similar findings as our study. Incidence of LVDD increases with increasing age. In our study, we found LVDD is more common among male patients (65.6%) compared to female patients (34.4%). In our study, we found among LVDD patients, 21.9% of patients had Normal Weight, 50.0% of patients were Obese, 25.0% of patients had over weight and 3.1% patients had under weight. The Association of BMI with LVDD was not statistically significant ($P = 0.2218$).

In our study we found, in LVDD Group, 3.1% of patients were in <10 years duration of diabetes, 96.9% patients were in >10 years duration of diabetes. The Association of duration of diabetes with LVDD was statistically significant ($P < 0.0001$). Patil *et al.*[9] found the prevalence of diastolic dysfunction increased with longer duration

of diabetes. **Ayman** *et al.*[10] found Diastolic dysfunction is highly prevalent in patients with newly diagnosed DM and is positively correlated with HbA1c level, obesity, dyslipidemia, and the duration of diabetes. Arora *et al.*[11] in their study observed that with the duration of the diabetes, the incidence of LVDD was increased. The findings from the above studies are similar to our finding, the incidence of LVDD increases with duration of diabetes.

In patients with LVDD, 9.4% patients were HBA1c level 6.5-8.0, 59.4% patients were HBA1c level 8.1–10.0 and 31.3% patients were HBA1c level >10.0. The Association of HBA1c with LVDD was statistically significant ($P < 0.0001$). Patil *et al.*[9] found Diastolic dysfunction was significantly associated with uncontrolled diabetes as assessed by HbA1c levels. Ayman *et al.*[10] found that LVDD was more prevalent in diabetic patients with HbA1c ≥ 8.1 (75%). The findings of the above studies are similar to our finding.

CONCLUSION

We found that most of the patients were 51–60 years old. In our study male population was higher than the female population. LVDD is found in 64% of patients. It was found that HBA1c was significantly increased in patients with LVDD. We found that the duration of diabetes >10 years was mostly observed in patients with LVDD which was statistically significant. In our study patients with Obese BMI were more observed with LVDD. Our study showed that the duration of diabetes and HBA1c were significantly increased in patients with LVDD.

From the present study, it can be concluded that the prevalence of LVDD in type 2 Diabetic Mellitus without any cardiovascular symptoms is much higher than previously suspected. Diastolic dysfunction is significantly associated with increasing age, duration of diabetes, and glycemic index assessed by HbA1c.

Early diagnosis and treatment for LVDD in diabetic patients without any cardiac symptoms will reduce the morbidity and improve the outcomes by preventing future development of heart failure. Hence, it can be suggested that all patients of diabetes should routinely undergo echocardiographic evaluation to assess cardiac function regardless of any clinical cardiac symptoms for long-term management.

LIMITATIONS

In spite of every sincere effort, my study has lacunae.

The notable shortcomings of this study are:

1. The sample size was small. Only 100 cases are not sufficient for this kind of study.
2. The study has been done in a single center.
3. The study was carried out in a tertiary care hospital, so hospital bias cannot be ruled out.
4. Ongoing COVID 19 pandemic and lockdown have further hampered the study.

REFERENCES

1. Dikshit NM, Wadia PZ, Shukla DK. Diastolic dysfunction in diabetes mellitus. Natl J Med Res 2013;3:249-52.
2. Rubler S, Deluges J, Yuceoglu YZ, Kumar T, Bran Wood AW, Grishman A. New type of cardiomyopathy associated with diabetic glomerulosclerosis. Am J Cardiol 1972;30:595-602.
3. Kannel WB, Hjortland M, Castelli WP. Role of diabetes in congestive heart failure: The Framingham study. Am J Cardiol 1974;34:29-34.
4. Shindler DM, Kostis JB, Yusus S, Quinones MA, Pitt B, Stewart D, *et al*. Diabetes mellitus, a predictor of morbidity and mortality in the studies of left ventricular dysfunction (SOLVD) trials and registry. Am J Cardiol 1996;77:1017-20.
5. Cosson S, Kevorkian JP. Left ventricular diastolic dysfunction: An early sign of diabetic cardiomyopathy. Diabetes Metab 2003;29:455-66.
6. Zarich SW, Nesto RW. Diabetic cardiomyopathy. Am Heart J 2001;35:166-8.
7. Sujino T, Kawasaki d, Bonow RO. New insights into diastolic heart failure: Role of diabetes mellitus. Am J Med 2005;116 Suppl 6:34S-45S.
8. Vanninen E, Pitale SU. Left ventricular function and dimensions in newly diagnosed non-insulin-dependent diabetes mellitus. Am J Cardiol 1992;70:371-8.
9. Patil MB, Burji NP. Echocardiographic evaluation of diastolic dysfunction in asymptomatic Type 2 diabetes mellitus. J Assoc Physicians India 2012;60:23-6.
10. Mahesh NK, Kumar A, Verma N, Bhat KG, Kumar D. Echocardiographic evaluation of diastolic dysfunction in diabetes mellitus without covert cardiac involvement. Int J Adv Med 2018;5:1.
11. Arora M, Singh VK, Sirohi TR, Singhal S. Study the frequency of left ventricular dysfunction in normotensive Type 2 diabetic patients. Int J Contemp Med Res 2021;8:C1-5.
12. Kumar VS, Sreelatha M, Ramesh K, Shekar GC. Study of left ventricular diastolic dysfunction in Type 2 diabetes mellitus patients. Int J Sci Stud 2017;5:219-24.
13. Ayman KH, Mahmoud AA, Eman AA, Marwa S, Mona MS, Yehia TK. Correlation between left ventricular diastolic dysfunction and dyslipidaemia in asymptomatic patients with new-onset Type 2 diabetes mellitus. Egypt J Intern Med 2021;33:1.

How to cite this article: Sarkar P, Debbarma BK. Echocardiographic Evaluation of Asymptomatic Type 2 Diabetes Mellitus Patients for Cardiovascular Disease in a Tertiary Care Hospital. Int J Sci Stud 2022;9(10):80-87.

Source of Support: Nil, **Conflicts of Interest:** None declared.

Print ISSN: 2321-6379
Online ISSN: 2321-595X

Original Article

Diagnostic Accuracy of Hounsfield Unit on Non Contrast Computed Tomography in Predicting Chemical Composition of Urinary Calculi

Padma V Badhe[1], Sanika Patil[2], Jagneet S Chatha[2], K N Puneethkumar[2]

[1]Professor, Department of Radiology, Seth Gordhandas Sunderdas Medical College, Mumbai, Maharashtra India, [2]Senior Resident, Department of Radiology, Seth Gordhandas Sunderdas Medical College, Mumbai, Maharashtra, India

Abstract

Introduction: Non-contrast computed tomography (NCCT) has become the imaging modality of choice for renal colic due to its high sensitivity in detecting renal stones. Predicting the chemical composition of renal stones based on radio-opacity can guide management strategies and therapeutic outcomes. The primary aim of our study was to evaluate the predictive efficacy of radio-opacity measures to accurately diagnose the chemical composition of the renal stones.

Methodology: NCCT of 250 consecutive adult patients were analyzed prospectively for whom chemical analysis of urinary stones was available over 18 months at an academic hospital in Western India. Multinomial univariate logistic regression was used to evaluate the predictive accuracy of radio-opacity measures - Hounsfield unit (HU) and Hounsfield density (HD). Data processing and multinomial logistic classifier training were done using a machine learning package in Python. Receiver operating characteristic (ROC) analysis was done using the R programming language.

Results: Calcium oxalate (61.2%) stones were the most common in our study populations, followed by Struvite (13.6%), calcium phosphate (13.2%), and uric acid (12%). Using ROC of uric acid versus struvite, HU provided a superior area under the curve (AUC) coverage of 100% compared to HD (AUC = 95.59%, CI95% = 91.23–99.95%), revealed by DeLong's test (Z = –1.9835, P = 0.047). Using the closest top-left method, an HU threshold of 731 (CI95% = 721–901%) with 100% specificity and 100% sensitivity. Similarly for struvite was predicted at 1136 HU versus calcium oxalate and phosphate stones with 76.47% specificity (CI95% = 64.71–88.24%) and 82.26% sensitivity (CI95% = 69.35–90.32%).

Conclusion: NCCT-based radio-opacity measures can identify uric acid from struvite, calcium stones in vivo with a high degree of accuracy at a threshold of 731 HU, and struvite from calcium oxalate and phosphate stones in vivo with a moderate degree of accuracy at a threshold of 1136 HU.

Key words: Chemical analysis of calculi, Non-contrast computed tomography, Renal stones/renal calculi, Urinalysis

INTRODUCTION

Ureteric colic caused by urolithiasis is an important and frequent emergency condition in medical practice. Approximately 5–12% of the world population will have a urinary tract stone during their lifetime with a 50% recurrence rate.[1] In the Indian scenario, recent estimates suggest a slightly elevated prevalence rate of 12–15% with a 50% recurrence rate of renal stones.[2] Non-contrast computed tomography (NCCT) has become the preferred imaging modality for the diagnosis of renal colic.[3] The American College of Radiology estimates a 98% diagnostic specificity of NCCT when a patient presents with acute flank pain suspicious of an obstructing stone.[4]

Access this article online

www.ijss-sn.com

Month of Submission : 11-2021
Month of Peer Review : 12-2021
Month of Acceptance : 12-2021
Month of Publishing : 01-2022

In addition to the size, location of the stone, and overall status of the kidney, there is increasing evidence for a correlation between the radio-opacities and chemical compositions of renal stones.[5-7] Predicting the chemical composition of renal stones based on radio opacity is important as their early identification can guide management strategies and therapeutic outcomes. For instance, uric acid stones can be treated by oral chemolysis, avoiding invasive therapies,

Corresponding Author: Dr. Padma V Badhe, Department of Radiology, Seth Gordhandas Sunderdas Medical College, Mumbai, Maharashtra, India.

while on the other hand, calcium oxalate stones are denser and less amenable to extra-corporeal shock wave lithotripsy (ESWL).[8,9] Dietary modifications are a very important part of the management of patients with renal stones and vary according to the composition of the stone.[10] Identification of chemical composition based on radio-opacity of stones on NCCT has shown promise in predicting the success and efficacy of ESWL and in the subsequent determination of appropriate medical management of renal stones.[5,7,11]

Since renal stones cannot always be obtained for chemical analysis, the need for accurate alternative methods for prediction of stone composition exists. Relatively few large stones are missed on NCCT but small stones (<3 mm) might slip between tissue imaging planes and evade detection.[12]

We carried out this study to assess the distribution of renal stones, to characterize them using radio-opacity measures, to evaluate the predictive efficacy of these measures toward the classification of chemical composition of the stones, and to identify optimal thresholds for classification. We sought to carry out robust statistical estimation and hypothesis testing for inference.

MATERIALS AND METHODS

The prospective observational study was carried out in the Department of Radiology, King Edward Memorial Hospital, Mumbai, India, over a period of 18 months from May 2016 to December 2018. An institutional ethics committee approval was obtained for the same. Patients were referred to us for computed tomography of kidney, ureters, and bladder (CT KUB) scan (KUB), and from these, a subset was included in the study for whom chemical composition analysis of stone was also carried out as per requests of referring clinicians. This included both out-patients as well as in-patients. Patients above 18 years of age were included in the study. Stones ≥10 mm were included in the study.

Scanning was performed as per standardized protocols for CT KUB scan. Each scan was interpreted by a professional radiologist, and radio-opacities of the stone (in Hounsfield units, HU) and the greatest transverse diameter of the stone was measured in millimeters. HU were calculated by drawing a circular region-of-interest mask over the two-third area of each stone. The transverse diameter was taken by measuring the maximum dimension of the calculus. Hounsfield density (HD) was calculated as the ratio of HU over the greatest transverse diameter in millimeters.

Chemical analysis of the stone was performed and evaluated in groups as calcium oxalate and phosphate, uric acid, and struvite stones. CT scan data were obtained with following parameters: Field of view: 350 mm, Slice thickness: 2 mm, Increment: 1 mm, Filter: Standard (B), Window: C: 60 W: 360 modifiable, and Matrix: 512, Pitch: 1.5:1.

Descriptive statistics are presented as 20% trimmed means and bootstrapped 95% confidence intervals, which are robust estimates of the underlying distribution.[13] Normality tests were carried out using the Shapiro–Wilk test. Hypothesis testing was done using a bootstrapped robust analysis of variance (ANOVA), which tests the null hypothesis for equal 20% trimmed means across groups.[13] All bootstrap-based methods involved 10,000 iterations of resampling.

The predictive efficiency of radio-opacity measures was evaluated through multinomial univariate logistic regression. This was carried out separately for HU and HD each after carrying out recursive feature elimination for feature ranking with three-fold cross-validation. Optimization for the logistic regression model fitting was done using the L-BGFS algorithm to minimize cross-entropy loss regularized by the L2 penalty. Diagnostics for the model fit are presented in the form of classification performance, predicted probabilities, log-loss or cross-entropy loss, and Matthew's correlation coefficient (MCC).[14]

Data processing and multinomial logistic classifier training were done using pandas[15] and scikit-learn[16] machine learning package in Python. Robust estimation and hypothesis testing were carried out using the Wilcox' Robust Statistics package,[13,17] Receiver operating characteristic (ROC) analysis was carried out using the predictive ROC (pROC) package by Robin *et al.*,[18] plotting was done using Wickham[19] and Wilke *et al.*[20] packages for the R programming language.[21]

RESULTS

Renal stone analysis of the 250 patients included in the study revealed a highest proportion of calcium oxalate (61.2%), followed by struvite (13.6%), calcium phosphate (13.2%), and uric acid (12%). The proportions of chemical composition, presented in Table 1, did not differ significantly across gender ($\chi^2 = 0.110$, $P = 0.993$, 104 Monte Carlo simulations). Ages ranged from 20 to 55 (Mean 20% trim = 39.64, SE = 1.66), and did not differ significantly across chemical compositions (F3,

Table 1: Contingency tables–chemical compositions across sex

Sex	Chemical Composition				Total
	Uric acid	Struvite	Oxalate	Phosphate	
Female	13	16	68	15	112
Male	17	18	85	18	138
Total	30	34	153	33	250

χ^2=0.110 (p_{sim}=0.993, based on 10,000 Monte Carlo simulations)

42.42 = 0.884, $P = 0.476$). Maximum measured dimensions across the stone ranged from 1.2 cm to 2.6 cm (Mean 20% trim = 1.86, SE = 0.07), and also did not differ across chemical compositions (F3, 45.13 = 2.869, $P = 0.0538$).

The distributions of radio-opacity measures –HD and HU, summarized in Table 2, were non-normal. Separate robust one-way ANOVA tests for HD and HU across chemical compositions, presented in Table 3, estimated significant statistics with relatively large effect sizes. Pairwise bootstrapped robust *post hoc* tests revealed significant differences between all pairs of chemical compositions for both measures except for differences in HD between calcium oxalate and calcium phosphate, summarized in Table 4 and Figure 1.

To assess the predictive efficiency of the radio-opacity measures, multinomial univariate logistic classifiers were trained separately on HD and HU for the chemical composition classes – uric acid, struvite, and calcium (oxalate and phosphate combined). For HD, model fitting converged in 43 iterations achieving overall classification accuracy of 85.2%, with cross-entropy loss of 0.394 and MCC of 0.613. For HU, model fitting converged in 76 iterations achieving overall classification accuracy of 89.2%, with cross-entropy loss of 0.279 and MCC of 0.726. Classifier performance for both HD and HU is summarized in Table 5 and class predictions for chemical compositions are presented in Figure 2.

ROC curve estimation was carried out for estimation of discrimination thresholds in the binary classification of uric acid–struvite and struvite–calcium using HD and HU. The pROC package for R was used for the analysis and estimation of bootstrapped thresholds and performance metrics. For multi-class ROC, area under the curve (AUC) was estimated to be 91.88% for HD and 94.71% for HU.

For binary classification of uric acid versus struvite, HU provided a superior AUC coverage of 100% compared to HD (AUC = 95.59%, CI95% = 91.23–99.95%), revealed by DeLong's test ($Z = -1.9835$, $P = 0.047$). Using the closest top-left method, an HU threshold of 731 (CI95% = 721–901%) with 100% specificity and 100% sensitivity, performed better than a HD threshold of 46 (CI95% = 40–48%) with 91.18% specificity (CI95% = 82.35–100%), and 90% sensitivity (CI95% = 80–100%).

For binary classification of struvite versus calcium, HU provided a AUC coverage of 84.14% (CI95% = 76.64–91.64%) while HD provided coverage of 80.76% (CI95% = 73.44–88.07%), with no differences in AUC as revealed by DeLong's test ($Z = 0.687$, $P = 0.492$). Using the closest top-left method, a HU threshold of 1136 (CI95% = 1092.5–1208.5%) with 76.47% specificity (CI95% = 64.71–88.24%) and 82.26% sensitivity (CI95% = 69.35–90.32%), performed better than an HD threshold of 63.5 (CI95% = 59.5–70.5%) with 76.47% specificity (CI95% = 61.76–94.12%) and 73.66% sensitivity (CI95% = 55.91–87.63%). Estimates using Youden's J statistic were very similar to the ones obtained using the closest top-left method. Estimated ROC curves are presented in Figure 3, while performance estimates of discrimination thresholds are summarized in Figure 4.

DISCUSSION

Our findings demonstrate significant differences in radio-opacity measures both – normalized over the greatest transverse

Table 2: Characterization of NCCT-based radio-opacity measures across chemical compositions of renal calculi

Measure	Estimate	Overall	Uric acid	Struvite	Oxalate	Phosphate
Hounsfield Density	Mean±SE†	73.12±1.67	33.63±1.73	59.26±2.06	79.18±1.63	95.24±5.45
	20% Trimmed Mean±SE†	70.85±1.63	33.05±2.08	58.86±2.30	76.54±1.82	92.67±7.47
	Median±SE†	68.50±1.64	32.50±2.52	58.50±3.13	75.00±1.91	85.00±12.04
	Minimum	18.00	18.00	36.00	27.00	50.00
	Maximum	156.00	55.00	90.00	136.00	156.00
	5th Percentile	30.00	19.10	39.75	54.00	52.80
	95th Percentile	122.10	52.25	81.00	117.6	144.80
	Shapiro–Wilk (W)	0.976	0.973	0.980	0.961	0.916
	Shapiro–Wilk (*P*)	<0.001*	0.616	0.760	<0.001*	0.014*
Hounsfield Units	Mean±SE†	1179.06±18.32	566.80±15.54	1064.12±26.55	1273.03±18.32	1418.36±33.62
	20% Trimmed Mean±SE†	1218.51±16.87	564.55±21.49	1052.68±25.66	1271.01±14.99	1425.95±43.32
	Median±SE†	1215.50±15.79	557.00±23.55	1030.00±31.95	1276.00±18.32	1439.00±43.25
	Minimum	420.00	420.00	760.00	908.00	1045.00
	Maximum	1722.00	702.00	1433.00	1658.00	1722.00
	5th Percentile	544.80	451.95	813.00	995.20	1096.00
	95th Percentile	1563.65	700.00	1357.60	1560.00	1686.80
	Shapiro–Wilk (W)	0.937	0.936	0.968	0.990	0.950
	Shapiro–Wilk (*P*)	<0.001*	0.073	0.405	0.347	0.137

†SE indicates the bootstrapped Standard Error of the estimate based on 10,000 iterations, NCCT: Non-contrast computed tomography

diameter of the stone (HD) as well as for unnormalized (HU), across chemical compositions of renal stones. Among reports involving radio-opacities of renal stones in Indian populations, HU estimates from our sample were higher for uric acid (420–702 vs. 200–450), lower for struvite (760–1433 vs. 600–900), and calcium oxalate (908–1658 vs. 1700–2800) and similar for calcium phosphate (1045–1722 vs. 1200–1600).[22] Compared to another study in the Indian setting,[23] HU estimates from our sample were higher for struvite (760–1433 vs. 486–1169) and calcium oxalate (908–1658 vs. ~258–1447), and similar for uric acid (420–702 vs. 433–634).

Table 3: Robust ANOVA†: HD and HU across chemical compositions

Measure	df1	df2#	F	*P*	ξ‡
HD	3	46.85	77.480	<0.001*	0.900
HU	3	43.92	243.819	<0.001*	0.841

†Tests hypothesis of equal trimmed means using the bootstrap-t method with 10,000 iterations; #Estimated adjusted degrees of freedom; ‡Explanatory measure of effect size, HD: Hounsfield density, HU: Hounsfield units, ANOVA: Analysis of variance

We found uric acid stones to have the lowest HD and HU measures followed by struvite and calcium stones. The predictive performance of HU exceeded that of HD for the classification of chemical compositions, with better performing thresholds for discrimination of uric acid from struvite than calcium from struvite. We observed that uric acid stones were differentiated easily from the rest using HU with a very high degree of accuracy, while differentiation of calcium from struvite stones was only moderately accurate.

Predicting the chemical compositions of renal stones is vital for their management and treatment outcomes. ESWL is largely prohibitive for uric acid stones due to their relative fragility. On the other hand, calcium containing stones, notably oxalate monohydrate, are denser and more resistant to ESWL. Marks and Teichman,[24] 2007, have reported on the efficacy of Holmium laser as a function of chemical composition, wherein they observed a low susceptibility for fragmentation in the case of calcium oxalate monohydrate stones, and a moderate susceptibility for fragmentation of uric acid and

Table 4: Robust *post hoc* comparisons for HD and HU across chemical compositions of renal calculi

Measure	Comparison	Test statistic	SE†	*P*	p_{FDR}#	ψ‡	CI_{Lower}	CI_{Upper}
Hounsfield Density (HD)	Oxalate–Phosphate	–2.061	7.82	0.054	0.054	–16.13	–37.65	5.39
	Oxalate–Struvite	6.020	2.94	<0.001*	<0.001*	17.67	9.60	25.75
	Oxalate–Uric acid	14.834	2.931	<0.001*	<0.001*	43.48	35.42	51.54
	Phosphate–Struvite	4.259	7.94	0.001*	0.002*	33.80	11.98	55.63
	Phosphate–Uric acid	7.513	7.93	<0.001*	<0.001*	59.61	37.79	81.43
	Struvite–Uric acid	8.019	3.22	<0.001*	<0.001*	25.81	16.96	34.66
Hounsfield Units (HU)	Oxalate–Phosphate	–3.143	49.29	0.007*	0.007*	–154.94	–295.01	–14.87
	Oxalate–Struvite	7.223	30.23	<0.001*	<0.001*	218.33	132.44	304.22
	Oxalate–Uric acid	26.345	26.82	<0.001*	<0.001*	706.45	630.26	782.65
	Phosphate–Struvite	6.932	53.85	<0.001*	<0.001*	373.27	220.26	526.28
	Phosphate–Uric acid	16.561	52.01	<0.001*	<0.001*	861.40	713.61	1009.19
	Struvite–Uric acid	14.156	34.48	<0.001*	<0.001*	488.13	390.15	586.11

†Bootstrapped Standard Error of the test statistic and ‡bootstrapped robust estimate of the difference based on 10,000 iterations; #*P*-values adjusted for control of Family-wise Error Rate using Bonferroni correction, HD: Hounsfield density, HU: Hounsfield units

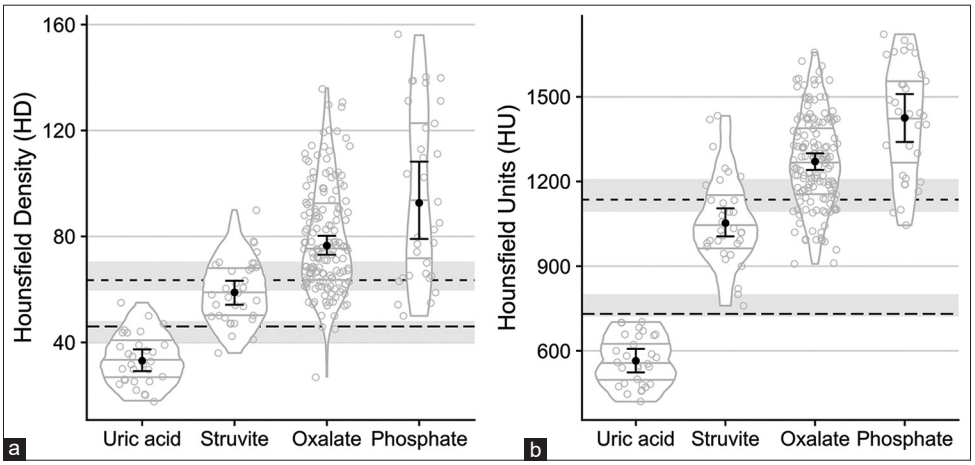

Figure 1: Distribution of Hounsfield Density (a) and Hounsfield Units (b) across chemical compositions. Point estimate represents the 20% trimmed mean, and the interval estimate represents the bootstrapped 95% confidence interval adjusted for control of the Family Wise Error Rate. Dashed lines represent the estimated thresholds for classification, and the gray band surrounding them represents the bootstrapped 95% confidence interval

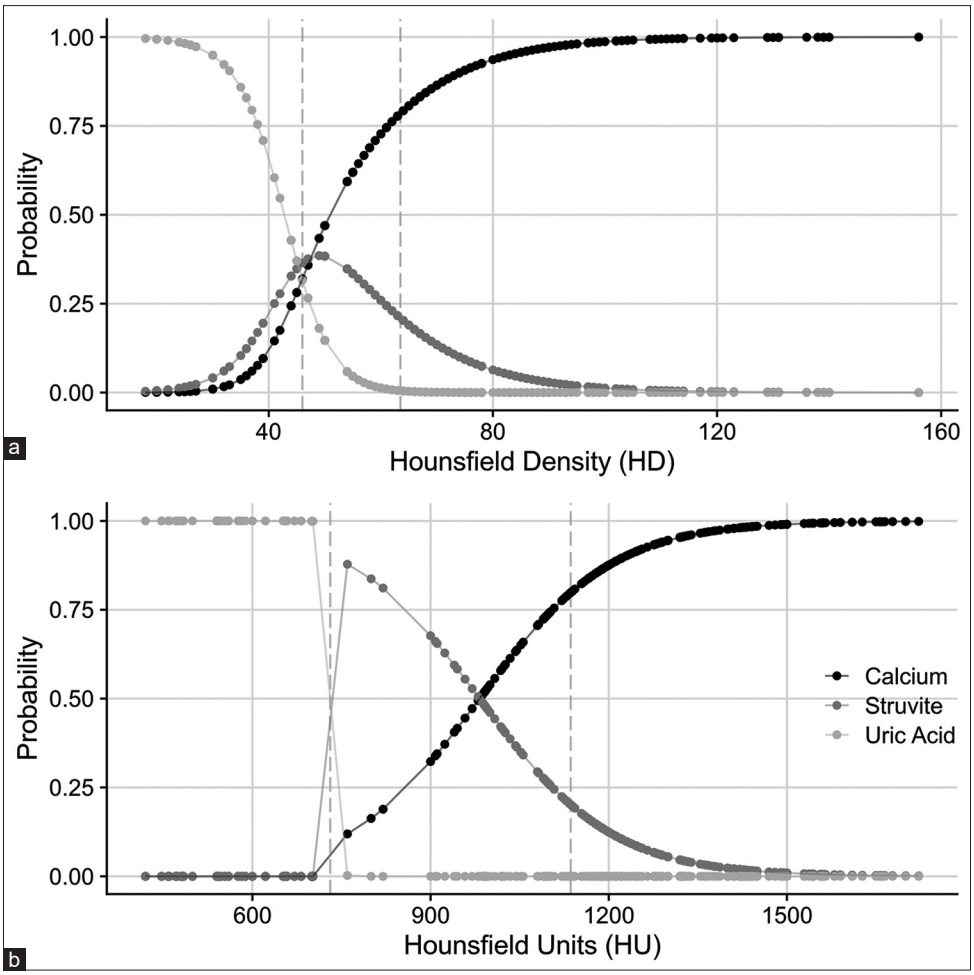

Figure 2: Probabilities predicted for observed samples by the multinomial logistic classifier using Hounsfield density (a), Hounsfield units (b). Vertical dashed lines indicate estimated thresholds

Table 5: Multinomial logistic regression† performance

Composition	Precision (%)	Sensitivity (%)	Specificity (%)	F_1 score‡ (%)
Hounsfield Density				
Calcium	85.92	98.39	53.13	91.73
Struvite	60.00	8.82	99.07	15.38
Uric acid	84.38	90.00	97.72	87.10
$Mean_{Weighted}$	82.21	85.20	64.73	80.79
Hounsfield Units				
Calcium	88.41	98.39	62.50	93.13
Struvite	76.92	29.41	98.61	42.55
Uric acid	100.00	100.00	100.00	100.00
$Mean_{Weighted}$	88.24	89.20	71.91	80.79

†L_2 penalized model that minimizes cross-entropy loss, learnt using a L-BGFS solver in 43 (HD) and 76 (HU) iterations; ‡F_1 score is the harmonic mean of precision and sensitivity, HD: Hounsfield density, HU: Hounsfield units

cystine stones. Uric acid has a solubility of ~50% at urinary pH of 5.75, while it is nearly completely soluble at urinary pH of 7. Precipitation of uric acid at low urinary pH predisposes patients to uric acid stones, thereby rendering non-invasive therapies like urine alkalinization a viable therapeutic strategy. Thus, separating uric acid stones from stones with other chemical compositions is critical. Both struvite and calcium stones are associated with urinary tract infections, with a higher risk of post-treatment sepsis and recurrence. Identification of these stones *in vivo* may help in directing appropriate therapy well in advance of stone extraction.

The present study was a single-center prospective effort, with a potential for selection bias. We believe that our usage of resampling methods and robust statistics would have addressed crucial statistical issues due to imbalanced

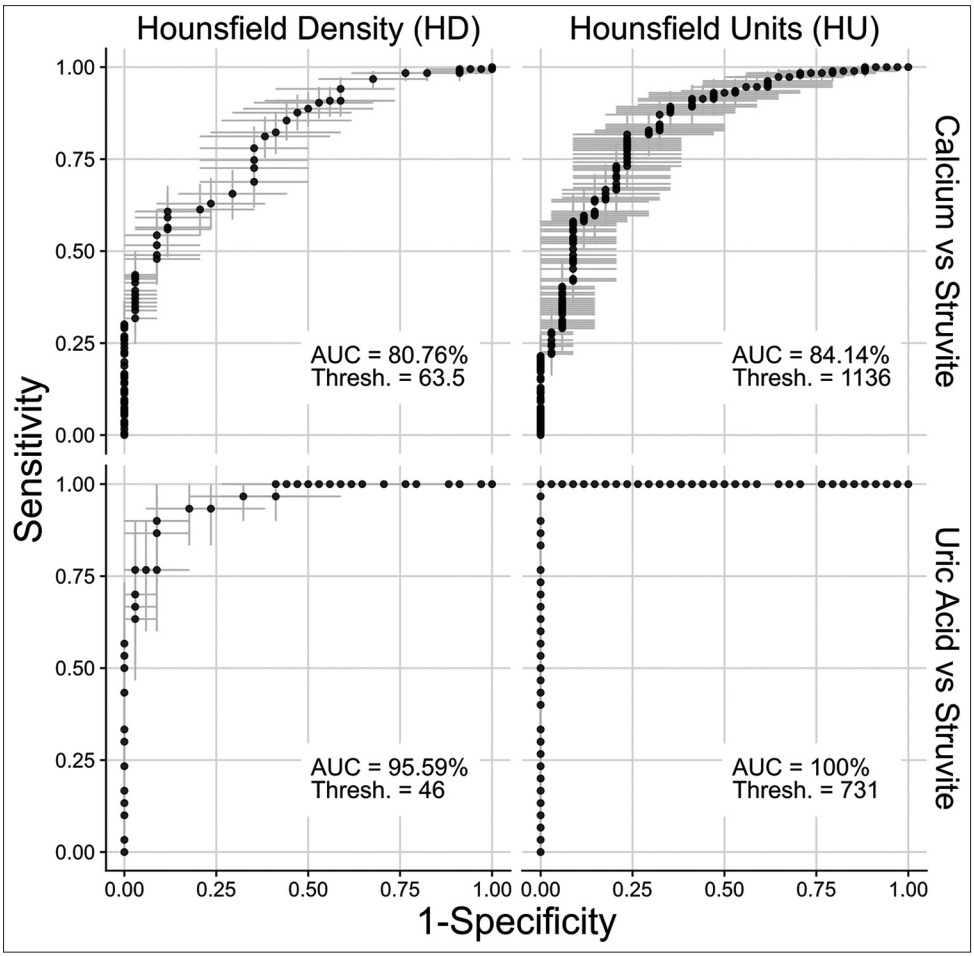

Figure 3: Receiver operating characteristic curve for Hounsfield density and Hounsfield units for binary classification of uric acid versus struvite and calcium versus struvite. Gray hatched lines indicate the bootstrapped 95% confidence interval for sensitivity and specificity

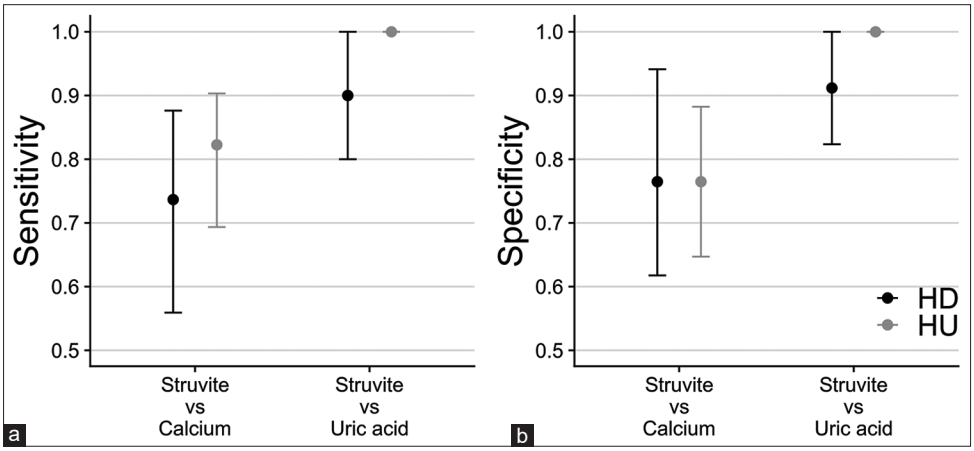

Figure 4: Performance of discrimination thresholds estimated from receiver operating characteristic curves. Point estimates indicate sensitivity and specificity at the estimated thresholds, while interval estimates indicate bootstrapped 95% confidence intervals. No intervals estimated for thresholds with 100% sensitivity and specificity

sample sizes within chemical compositions; however, the extent of this reduction cannot be determined. We did not encounter any cysteine, brushite, or hydroxyapatite stones. Furthermore, given the design of the study, we could not assess the impact of stone composition detection using NCCT on patient management and outcomes. We could not assess stone density, which may complement heterogeneity indices and offer reliable predictive performance. Finally,

we did not carry out statistical inference on the trained multinomial logistic classifier due to difficulties presented by regularization and given our aim of univariate model selection for prediction accuracy.

CONCLUSIONS

NCCT-based radio-opacity measurement can identify uric acid from struvite, calcium oxalate, and phosphate stones *in vivo* with a high degree of accuracy at a threshold of 731 HU, and struvite from calcium oxalate and phosphate stones *in vivo* with a moderate degree of accuracy at a threshold of 1136 HU. Using pooled datasets, additional predictors and robust techniques, a higher and more reliable predictive performance are achievable, with immense scope for facilitation of management strategies.

ACKNOWLEGMENT

The authors express their gratitude to the Department of Radiology of, Seth G.S Medical College and KEM Hospital, Mumbai, for providing the required platform to complete this Original Research Article. The authors express their gratitude to their colleagues for valuable suggestions regarding the article. Finally, the authors are thankful to the patient without whose help it would not have been possible to complete the article. The authors have not declared a specific grant for this research from any funding agency in the public, commercial, or not-for-profit sectors.

REFERENCES

1. Masarani M, Dinneen M. Ureteric colic: New trends in diagnosis and treatment. Postgrad Med J 2007;83:469-72.
2. Gupta S, Baghel MS, Bhuyan C, Ravishankar B, Ashok BK, Patil PD. Evaluation of anti-urolithiatic activity of Pashanabhedadi Ghrita against experimentally induced renal calculi in rats. AYU 2012;33:429.
3. Feroze S, Singh B, Gojwari T, Manjeet S, Athar B, Hamid H. Role of non-contrast spiral computerized tomography in acute ureteric colic. Indian J Urol 2007;23:119.
4. Brisbane W, Bailey MR, Sorensen MD. An overview of kidney stone imaging techniques. Nat Rev Urol 2016;13:654-62.
5. El-Assmy A, El-Nahas AR, Abou-El-Ghar ME, Awad BA, Heir KZ. Kidney stone size and hounsfield units predict successful shockwave lithotripsy in children. Urology 2013;81:880-4.
6. Gücük A, Üyetürk U. Usefulness of Hounsfield unit and density in the assessment and treatment of urinary stones. World J Nephrol 2014;3:282-6.
7. Yamashita S, Kohjimoto Y, Iwahashi Y, Iguchi T, Nishizawa S, Kikkawa K, *et al*. Noncontrast computed tomography parameters for predicting shock wave lithotripsy outcome in upper urinary tract stone cases. BioMed Res Int 2018;2018:e9253952.
8. Williams JC, Saw KC, Paterson RF, Hatt EK, McAteer JA, Lingeman JE. Variability of renal stone fragility in shock wave lithotripsy. Urology 2003;61:1092-6.
9. Ringdén I, Tiselius HG. Composition and clinically determined hardness of urinary tract stones. Scand J Urol Nephrol 2007;41:316-23.
10. Prezioso D, Strazzullo P, Lotti T, Bianchi G, Borghi L, Caione P, *et al*. Dietary treatment of urinary risk factors for renal stone formation. A review of CLU Working Group. Arch Ital Urol Androl 2015;87:105.
11. Ouzaid I, Al-Qahtani S, Dominique S, Hupertan V, Fernandez P, Hermieu JF, *et al*. A 970 Hounsfield units (HU) threshold of kidney stone density on non-contrast computed tomography (NCCT) improves patients' selection for extracorporeal shockwave lithotripsy (ESWL): Evidence from a prospective study. BJU Int 2012;110:E438-42.
12. Memarsadeghi M, Heinz-Peer G, Helbich TH, Schaefer-Prokop C, Kramer G, Scharitzer M, *et al*. Unenhanced multi-detector row CT in patients suspected of having urinary stone disease: Effect of section width on diagnosis. Radiology 2005;235:530-6.
13. Wilcox RR. Introduction to Robust Estimation and Hypothesis Testing. 4th ed. Waltham, MA: Elsevier; 2016.
14. Baldi P, Brunak S, Chauvin Y, Andersen CA, Nielsen H. Assessing the accuracy of prediction algorithms for classification: An overview. Bioinformatics 2000;16:412-24.
15. Reback J, McKinney W, Van den Bossche J, Augspurger T, Cloud P, Klein A, *et al*. Pandas-dev/Pandas: Pandas 1.2.2. United Kingdom: Zenodo; 2021.
16. Pedregosa F, Varoquaux G, Gramfort A, Michel V, Thirion B. Scikit-learn: Machine learning in python. J Mach Learn Res 2011;12:2825-30.
17. Mair P, Wilcox R. Robust statistical methods in R using the WRS2 package. Behav Res 2020;52:464-88.
18. Robin X, Turck N, Hainard A, Tiberti N, Lisacek F, Sanchez JC. pROC: An open-source package for R and S+ to analyze and compare ROC curves. BMC Bioinform 2011;12:77.
19. Wickham H. ggplot2: Elegant Graphics for Data Analysis. New York: Springer-Verlag; 2016. Available from: https://www.ggplot2.tidyverse.org [Last accessed on 2020 Nov 23].
20. Wilke C, Fox SJ, Bates T, Manalo K, Lang B, Barrett M, Stoiber M, *et al*. Wilkelab/Cowplot: 1.1.1. United Kingdom: Zenodo; 2021.
21. R Core Team. R: A Language and Environment for Statistical Computing. Vienna, Austria: R Foundation for Statistical Computing; 2018. Available from: https://www.R-project.org [Last accessed on 2020 Nov 23].
22. Naik D, Jain A, Hegde AA, Kumar AA. Determination of attenuation values of urinary calculi by non-contrast computed tomography and correlation with outcome of extracorporeal shock wave lithotripsy-a prospective study. Int J Anat Radiol Surg 2017;6:81-6.
23. Mahalingam H, Lal A, Mandal AK, Singh SK, Bhattacharyya S, Khandelwal N. Evaluation of low-dose dual energy computed tomography for *in vivo* assessment of renal/ureteric calculus composition. Korean J Urol 2015;56:587-93.
24. Marks AJ, Teichman JM. Lasers in clinical urology: State of the art and new horizons. World J Urol 2007;25:227-33.

How to cite this article: Badhe PV, Patil S, Chatha JS, Puneethkumar KN. Diagnostic Accuracy of Hounsfield Unit on Non Contrast Computed Tomography in Predicting Chemical Composition of Urinary Calculi. Int J Sci Stud 2022;9(10):88-94.

Source of Support: Nil, **Conflicts of Interest:** None declared.

Print ISSN: 2321-6379
Online ISSN: 2321-595X

Original Article

Study of Silodosin, Darifenacin, and Combination Therapy for the Treatment of Ureteral Stent-Related Discomfort

G. Latha

Assistant professor, Department of Urology, Government medical college and Hospital, Pudukottai, Tamilnadu

Abstract

Objective: To compare the safety and efficacy of silodosin and Darifenacin in treating ureteral stent-related symptoms in patients with Double-J ureteral stents.

Materials and Methods: This is an observational study with a prospective design. After retrograde ureteroscopy for urinary stones, a single surgeon conducted retrograde double-J stenting on 75 patients (48 males and 27 women). Group 1 – Silodosin – 4 mg once daily, Group 2 – Darifenacin - 7.5 mg once daily, Group 3 – Silodosin (4mg) and Darifenacin (7.5 mg) once daily. The patient completed written International Prostate Symptom Score questionnaires the day before surgery, on a post-operative day 1, and on the day of stent removal. All groups received drugs for 14 days.

Results: After the stent was removed, the IPSS total score for group one was 12.62, 11.03 for group two, and 7.82 for group three. These differences were substantial (p=0002), and there were no differences in pre-and post-operative circumstances. Similarly, after stent removal, the IPSS irritative and obstructive symptom scores showed significant differences (p=0.004, p=0.025), with group one scoring 8.31, group two 6.18, and group three 4.82. The IPPS irritative and obstructive ratings for groups one and two were 4.99, 5.28, and 3.25, respectively.

Conclusion: Combination of silodosin and darifenacin was sufficient for obstructive symptoms following stent removal, the combination of these two was more effective than either medication alone.

Key words: Double-J ureteral stents, IPSS, Stent-related symptoms

INTRODUCTION

In 1967, Zimskind *et al*. introduced ureteral stents, which are now widely used in urinary tract disease.[1] The double J stent is the most commonly used type of ureteral stent, and it is used to treat ureteral edema, obstructive pyelonephritis, ureter perforation, renal colic, and Stein Strasse.[2,3] Even though stents are extremely beneficial, patients still experience a variety of issues, such as pain and inflammation, which negatively impact their health.[4] The known causes of these symptoms are unknown. According to Thomas' report, the main cause of stein-related symptoms is the pressure transferred to the renal pelvis by the stent's intravesical portion during trigonal irritation and urination.[5] Many studies have recently been published to reduce these stent symptoms. Pharmacological management, such as prescribing selective alpha-1-blockers and antimuscarinic agents, is one example of such efforts to reduce stein symptoms.[6]

Access this article online

www.ijss-sn.com

Month of Submission : 11-2021
Month of Peer Review : 12-2021
Month of Acceptance : 12-2021
Month of Publishing : 01-2022

Pharmacologic management is thought to be simpler to implement than other management methods. Silodosin is a highly selective alpha-1 adrenergic receptor antagonist that is used to treat lower urinary tract symptoms (LUTS) in men who have a suspected bladder outlet obstruction due to benign prostatic hyperplasia (BPH). Darifenacin is a medication used to treat overactive bladder-related urinary incontinence. Darifenacin is an antimuscarinic medication. It prevents frequent, urgent, or uncontrolled urination by relaxing the muscles of the urinary bladder. The goal of this study was to examine and compare the efficacy of Silodosin and Darifenacin alone and in combination

Corresponding Author: Dr. G. Latha, Assistant professor, Department of Urology, Government medical college and Hospital, Pudukottai, Tamilnadu

in treating lower urinary tract symptoms in patients with indwelling double-J ureteral stents.

MATERIALS AND METHODS

This is a prospective observational study. A single surgeon performed retrograde double-J stenting on 75 patients (48 men and 27 women) after retrograde ureteroscopy for urinary stones. A retrospective chart review was used to obtain patient data. Patients with benign prostatic hyperplasia or overactive bladder who had previously been prescribed a selective alpha-1-blocker or antimuscarinic agent were excluded from this study. Patients who were taking analgesics prior to surgery were also excluded. The ureteral stent was made of polyurethane and had a diameter of 6 Fr as well as lengths of 24 cm and 26 cm. The ureteral stent's length was determined by the patient's height.

The procedure was carried out under general anesthesia, and the stent's position was confirmed by plain X-ray. Fourteen days after surgery, the stents were removed. Three groups of patients were formed. Group 1 (n = 25) received Silodosin 4 mg once daily. Darifenacin 7.5 mg was given to Group 2 (n = 25) once a day, every day. Group 3 (n = 25) was given Silodosin 4 mg and Darifenacin 7.5 mg on a daily basis. Each patient completed written International Prostate Symptom Score/Quality of Life (IPSS/QoL) questionnaires the day before surgery, on post-operative day 1, and on the day of stent removal. The IPSS was divided into three parts: total score, obstructive symptom score, and irritative symptom score. The Chi-square test, one-way ANOVA, and one-way repeated measures ANOVA were used for comparisons between each of the three groups. Values of $p<0.05$ were considered statistically significant. Statistical analyses were performed with SPSS ver. 18.0 (SPSS Inc., Chicago, IL, USA).

RESULTS

The patients' mean age was 50.24±12.90 years, and there were no significant differences between groups (n=25). There are three groups in this study, each with 25 participants. This study included a total of 26 females and 48 males. Table 1 shows that of the 75 patients studied, 22 (29.4%) had percutaneous nephrolithotomy (PCNL) and 53 (70.6%) had ureteroscopic lithotomy (URSL) for stone treatment (Table 1). ANOVA with repeated measures revealed a significant difference (p.0002) after stent removal. The IPPS total score for group one was 12.62, 11.03 for group two, and 7.82 for group three. In pre-and post-operative conditions, there was no significant difference in IPPS total score between groups [Table 2]. Similarly, IPSS irritative and obstructive symptom scores showed significant differences ($p = 0.004$, $p = 0.025$) after stent removal, with group one having 8.31, group two having 6.18, and group three having 4.82. The IPPS irritative and obstructive scores were 4.99 for group one, 5.28 for group two, and 3.25 for group three. In pre- and post-operative conditions, there was no significant difference in IPSS irritative and obstructive subscores between groups (Table 3 and Table 4).

DISCUSSION

Significant pain and discomfort are associated with ureteral stents.[7] According to Joshi *et al.*, 80% of patients experienced stent-related pain.[8] Numerous studies have been conducted to reduce stent-related discomfort and pain through the use of drugs such as alpha-blockers, anticholinergics, phosphodiesterase inhibitors, and others, as well as new stent designs, stent materials, and stent

Table 1: shows the age, gender, and procedure used in all of the patients who took part in the study.

	Group 1	Group 2	Group 3
Age	52.48±17.24	54.85±16.17	51.66±15.37
Gender			
Male	17	16	16
Female	8	9	9
Procedure			
PCNL	7	8	7
URSL	18	17	18

Table 2: Compares the three groups' IPSS total scores.

IPSS total score	Group 1	Group 2	Group 3	P value
Pre-op	8.14	8.99	8.24	0.725
Post-op	12.34	11.19	10.98	0.538
Stent removal	12.62	11.03	7.82	0.002

Table 3: Compares the three groups' IPSS irritative subscore.

IPSS irritative subscore	Group 1	Group 2	Group 3	P value
Pre-op	4.64	4.79	5.14	0.821
Post-op	8.03	6.75	7.59	0.474
Stent removal	8.31	6.18	4.82	0.004

Table 4: Compares the three groups' IPSS obstructive subscore

IPSS obstructive subscore	Group 1	Group 2	Group 3	P value
Pre-op	4.71	4.68	4.19	0.774
Post-op	5.01	4.92	4.58	0.841
Stent removal	4.99	5.28	3.25	0.025

dimensions.[9-12] The majority of the available literature focuses on stent-related morbidity while the stent is in place. However, it is not uncommon for any urologist to see patients complaining of renal colic-like pain after stent removal, which frequently necessitates additional analgesics and admission due to the severity of the pain. Pain during stent removal is most likely caused by nociceptors being activated, friction between the stent and the mucosa causing ureteral smooth muscle irritability, trigonal irritation, and pressure-induced changes in the pelvi-calyceal system.[10,13] However, pain after stent removal is frequently unreported or ignored for an extended period of time. There are several approaches to optimise the compatibility of this stent using preventive and pharmacological techniques. Stent length should be adjusted according to the patient's height, stent use should be limited, different stent designs such as drug-releasing or biodegradable stents should be considered, hydrophilic material coated stents with tapering ends should be considered, and proper counseling of patients for their pain and discomfort should be provided. These strategies come under the category of preventive techniques. In pharmacological strategies drugs such as alpha-blockers and anticholinergics reduced the pressure transmitted toward the renal pelvis during micturition, reduce the peak contraction pressure leading to ureteral dilation and decrease bladder irritation with the intravesical portion of the stent that will lead to less discomfort related to stents.[10,11] Alpha-blockers, anticholinergics, and their combinations have shown to be effective in the treatment of stent-related symptoms.[14] PDE5Is have recently been linked to stent-related symptoms in some trials.[15] However, for the assessment of stent-related symptoms, the majority of these studies haven't employed the most validated score with better quality of life. The combination of silodosin and darifenacin alleviated stent-related symptoms and increased quality of life in our observational study. Silodosin has also been demonstrated to be beneficial in patients with stent-related symptoms by Tsai *et al.* and Kim *et al.* stent-related symptoms is usually treated with alpha-blockers, and other studies have demonstrated that these medicines are useful in lowering stent-related symptoms.[14,16] Anticholinergics, both alone and in conjunction with alpha-blockers, were found to be useful in treating stent-related symptoms in patients, but combination therapy was found to be more effective than monotherapy. Bhattar et al. discovered that combination therapy with silodosin and solifenacin (group E) was helpful for treating stent-related symptoms, with better quality of life and less analgesic need than any other group.[17] Similarly, in our study, Silodosin 4 mg and Darifenacin 7.5 mg daily groups had statistically significant differences in the IPSS total score, irritative and obstructive subscore. The other scores were not significantly different. The following are the study's limitations. There was a lack of receiving valuable and totally credible information because this was a prospective and observational study. On a preoperative day or after stent removal, some patients did not submit their complete IPSS score questionnaire. As a result, we were unable to use this questionnaire. The statistical significance of each scale was difficult to evaluate due to very small groups. As a result, further sizable, prospective studies are needed to provide more precise data.

CONCLUSION

Combination therapy with silodosin and darifenacin improved both irritative and obstructive symptoms more than in the other groups. Combination therapy should be strongly considered for patients who complain of stent-related symptoms.

REFERENCES

1. Zimskind PD, Fetter TR, Wilkerson JL. Clinical use of long term indwelling silicone rubber ureteral splints inserted cistoscopically. J Urol. 1967;97:840–4.
2. Jeong, H., Kwak, C. and Lee, S.E., 2004. Ureteric stenting after ureteroscopy for ureteric stones: a prospective randomized study assessing symptoms and complications. BJU international, 93(7), pp.1032-1034.
3. Chew BH, Knudsen BE, Denstedt JD. The use of stents in contemporary urology. Curr Opin Urol [Internet]. 2004;14(2):111–5. Available from: http://dx.doi.org/10.1097/00042307-200403000-00011
4. Joshi HB, Stainthorpe A, Keeley FX Jr, MacDonagh R, Timoney AG. Indwelling ureteral stents: evaluation of quality of life to aid outcome analysis. J Endourol [Internet]. 2001;15(2):151–4. Available from: http://dx.doi.org/10.1089/089277901750134421
5. Thomas R. Indwelling ureteral stents: impact of material and shape on patient comfort. J Endourol [Internet]. 1993;7(2):137–40. Available from: http://dx.doi.org/10.1089/end.1993.7.137
6. Lim KT, Kim YT, Lee TY, Park SY. Effects of tamsulosin, solifenacin, and combination therapy for the treatment of ureteral stent related discomforts. Korean J Urol [Internet]. 2011;52(7):485–8. Available from: http://dx.doi.org/10.4111/kju.2011.52.7.485
7. Pollard SG, Macfarlane R. Symptoms arising from double-J ureteral stents. J Urol [Internet]. 1988;139(1):37–8. Available from: http://dx.doi.org/10.1016/s0022-5347(17)42282-8
8. Joshi HB, Stainthorpe A, MacDONAGH RP, Keeley FX, Timoney AG. Indwelling ureteral stents: Evaluation of symptoms, quality of life and utility. J Urol [Internet]. 2003;169(3):1065–9. Available from: http://dx.doi.org/10.1097/01.ju.0000048980.33855.90
9. Beddingfield R, Pedro RN, Hinck B, Kreidberg C, Feia K, Monga M. Alfuzosin to relieve ureteral Stent discomfort: A prospective, randomized, placebo controlled study. J Urol [Internet]. 2009;181(1):170–6. Available from: http://dx.doi.org/10.1016/j.juro.2008.09.026
10. Dellis A, Joshi HB, Timoney AG, Keeley FX. Relief of Stent related symptoms: Review of engineering and pharmacological solutions. J Urol [Internet]. 2010;184(4):1267–72. Available from: http://dx.doi.org/10.1016/j.juro.2010.06.043
11. Gupta M, Patel T, Xavier K, Maruffo F, Lehman D, Walsh R, *et al*. Prospective randomized evaluation of periureteral botulinum toxin type A injection for ureteral Stent pain reduction. J Urol [Internet]. 2010;183(2):598–602. Available from: http://dx.doi.org/10.1016/j.juro.2009.10.021
12. Deliveliotis C, Chrisofos M, Gougousis E, Papatsoris A, Dellis A, Varkarakis IM. Is there a role for alpha1-blockers in treating double-J stent-related symptoms? Urology [Internet]. 2006;67(1):35–9. Available from: http://dx.doi.org/10.1016/j.urology.2005.07.038
13. Damiano R, Autorino R, De Sio M, Giacobbe A, Palumbo IM,

D'Armiento M. Effect of tamsulosin in preventing ureteral stent-related morbidity: a prospective study. J Endourol [Internet]. 2008;22(4):651–6. Available from: http://dx.doi.org/10.1089/end.2007.0257

14. Tsai PC, Wang CJ, Chang CH, Chen HW, Hsu CS. Effects of Silodosin on Lower Urinary Tract Symptoms Due to a Double-J Stent: A Prospective Randomized Study. IJ Neph Kid Failure. 2015;1(4):1–4.
15. Hajebrahimi S, Farshi A, Jabbari A, Sadegi Bazargani H, Babaei H, Mostafaie H. 1080 Does tadalafil alleviate ureteral stent related symptoms? A randomized controlled trial. Eur Urol Suppl [Internet]. 2015;14(2):e1080. Available from: http://dx.doi.org/10.1016/s1569-9056(15)61068-5
16. Kim HW, Lee J-H, Shin DG, Lee JZ. The effects of silodosin in the treatment of ureteral stent related symptoms. J Incl Phenom Macrocycl Chem [Internet]. 2015;82(1–2):259–63. Available from: http://dx.doi.org/10.1007/s10847-015-0494-y
17. Bhattar R, Tomar V, Yadav SS, Dhakad DS. Comparison of safety and efficacy of silodosin, solifenacin, tadalafil and their combinations in the treatment of double-J stent-related lower urinary system symptoms: A prospective randomized trial. Turkish Journal of Urology. 2018;44(3).

How to cite this article: Latha G. Study of Silodosin, Darifenacin, and Combination Therapy for the Treatment of Ureteral Stent-Related Discomfort**.** Int J Sci Stud 2022;9(10):95-98.

Source of Support: Nil, **Conflicts of Interest:** None declared.