

Bone Marrow Necrosis: A Case Report

Shaista Choudhary¹, H T Jayaprakash², B R Shiva Kumar³, G Suba⁴

¹Associate Professor, Department of Pathology, Dr. B. R. Ambedkar Medical College, Bengaluru, Karnataka, India, ²Professor and Head, Department of Pathology, Dr. B. R. Ambedkar Medical College, Bengaluru, Karnataka, India, ³Professor, Department of Medicine, Dr. B. R. Ambedkar Medical College, Bengaluru, Karnataka, India, ⁴Assistant Professor, Department of Pathology, Dr. B. R. Ambedkar Medical College, Bengaluru, Karnataka, India

Abstract

The bone marrow is one of the largest organs in the human body (Lund, 2000). It is the major hematopoietic organ and is important as both a primary and secondary lymphoid organ. Since it is a potential target organ of various disorders, evaluation of blood and bone marrow is an important component of any overall assessment studies. Bone marrow evaluation studies provide information about bone marrow tissue architecture like cellularity, cell lineages, vascular or stromal alterations, inflammation or necrosis. When it is used in conjunction with a complete blood count, the histological examination of bone marrow provides information regarding the hematopoietic system that might otherwise be missed by examination of peripheral blood smear alone. Bone marrow is rarely affected by various disorders like metastatic tumors storage disorders, leukemia, lymphomas, etc. Few such lesions result in necrosis of bone marrow. This signals bad prognosis. The various disorders which affect the bone marrow are leukemias, lymphomas, storage disorders, tuberculosis, metastatic deposits, and fungal infections. We report a case of 65-year-old female who underwent bone marrow biopsy. Histological features were consistent with necrosis of bone marrow.

Keywords: Bone marrow, Hematopoietic, Necrosis, Thrombocytopenia

INTRODUCTION

Bone marrow necrosis is defined as necrosis of myeloid tissue and medullary stroma in large areas of hematopoietic bone marrow.¹ It is an unusual histological finding most commonly encountered after autopsy in patients with leukemia or sickle cell disease. Though there are various other disorders which can lead to bone marrow necrosis, still the above-mentioned two causes remain the most common ones.²

Bone marrow necrosis was first described by Wade and Stevenson in 1942. That patient had sickle cell disease and died of cerebral infarction.³ Most of the available data about bone marrow necrosis are from the post mortem studies because there was the lack of awareness and lack of documentation of the very few cases which were diagnosed during the lifetime of the patient.

CASE REPORT

A 56-year-old female patient was admitted in the medical ward with history of (h/o) weakness, tiredness, fatigue, and fever of 15 days duration on and off. General physical examination did not reveal features of anemia. No organomegaly or lymphadenopathy was noted. Clinical opinion of pyrexia of unknown origin was given. Routine hematological investigations were done. The reports are as follows: Hemoglobin - 06 g%, total count - 5400 cells/cumm, platelet count - 40,000. Impression on peripheral smear report was anemia with thrombocytopenia.

Bone marrow aspiration and biopsy were performed under local anesthesia. Patient was cooperative during the procedure aspirated material was mixed with trisodium citrate in a petridish and biopsy material was transferred to formalin solution. Before transferring to formalin, multiple imprint smears were taken on glass slides. Histopathology section received specimen of bone marrow biopsy in formalin, measuring 1.7 cm in length. Specimen was kept in formalin for 24 h for better fixation. Then material was transferred to decalcification fluid (5% nitric acid) for 24 h. To confirm decalcification, chemical test was employed. Finally, the material was sent for routine processing. Staining was done using routine hematoxylin-eosin stain.

Access this article online



www.ijss-sn.com

Month of Submission : 11-2014
Month of Peer Review : 12-2014
Month of Acceptance : 12-2014
Month of Publishing : 01-2015

Corresponding Author: Dr. Shaista Choudhary, House no. 60, 10th A cross, WOC Road, Bengaluru, Karnataka, India.
 Phone: +91-9901474389. E-mail: drshaista5@rediffmail.com

Grossly specimen consisted of two grey white firm pieces of tissue larger one measuring 1.5 cm and smaller one 0.3 cm in length. Entire tissue was processed. Microscopy showed evidence of extensive bone marrow necrosis. Focal areas showed mild myelofibrosis. Hematopoietic cells were very much reduced. Some bony spicules show evidence of osteosclerosis. Impression: Secondary myelofibrosis with evidence of marrow necrosis suggested bone scan and radiological to rule out malignancy. Initially, patient did not agree for any other investigations and her condition deteriorated. Patient died after 5 days of histopathological diagnosis (Figures 1-3).

DISCUSSION

Bone marrow necrosis is relatively infrequent diagnosis in routine bone marrow biopsy specimens. In leukemia, hemoglobinopathies and malignancies marrow necrosis are mainly due to impairment in blood supply.³ The incidence of bone marrow necrosis is variable, i.e, 0.5-3%. Vesterby and Jensen reported bone marrow necrosis to be 6.5% in autopsies of leukemic patients. Dunn *et al.* reported an incidence of 0.37% in consecutive bone marrow aspirates performed alone or with biopsies.⁴ Layla *et al.* reported the incidence as 1.6% of consecutive biopsies. Bone marrow necrosis is classified into three types based on the area involved with necrosis. Hence, if necrosis is restricted to a focal area it is called mild, if intermediate involvement is seen it is termed as moderate and if extensive involvement of the bone marrow is noted then it is termed as severe type. Accordingly, it is graded as follows Grade I - <20%, Grade II - 20-50% and Grade III is >50%. As per literature 90% of the cases of bone marrow necrosis show malignancy as an underlying cause and in 60% cases it is hematopoietic malignancy (acute leukemia being the commonest). The other causes are tuberculosis, drugs, sickle cell disease and disseminated intravascular coagulation.⁵ Colon carcinoma as an underlying cause for thrombotic thrombocytopenic purpura and bone marrow necrosis has been reported by Lee *et al.*⁶ Anemia and thrombocytopenia is observed in 90% and 80% cases respectively. White blood cell count may be normal, low or elevated in 30%, 45% and 25% cases respectively. Leuco-erythroblastic reaction is noted in 55% cases. Lactate dehydrogenase, alkaline phosphatase and/or alkaline transaminase and uric acid values may show elevation. The presenting symptoms are bone pain, fever, back pain, malaise, and weight loss.

Our patient presented with fever and back pain as the chief complaints. Laboratory investigations showed significant anemia and thrombocytopenia. The other parameters were in normal limits.

The patient died within a week of bone marrow biopsy diagnosis. Further follow-up including bone scan could not be done since the patient died within 5 days of bone marrow biopsy diagnosis.

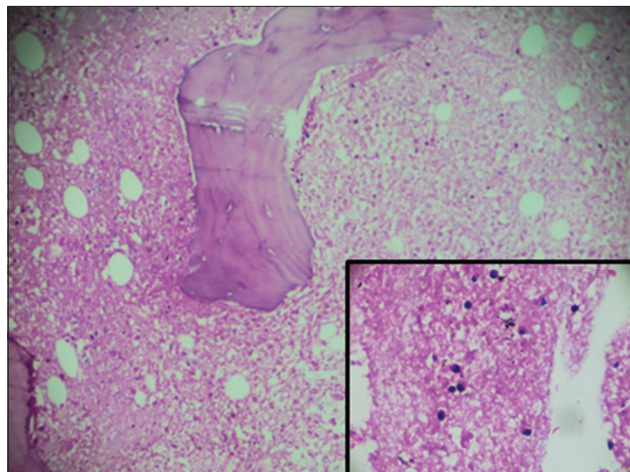


Figure 1: Bony trabeculae with areas of necrosis and sparse bone marrow cellularity

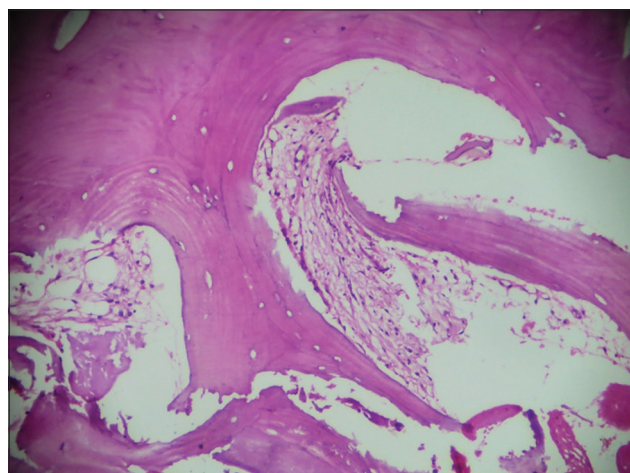


Figure 2: Sclerosis and focal marrow fibrosis

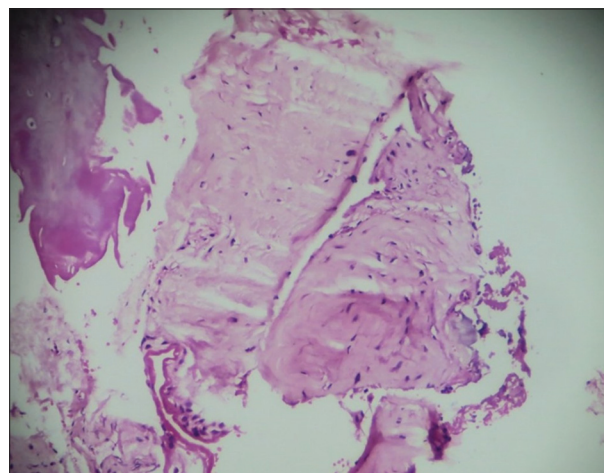


Figure 3: Areas of fibrosis with scant cellularity in background

Patients usually die within months and even days after the diagnosis. Occasional cases of survival up to 2 years has been noted where the diagnosis on bone marrow biopsy was tuberculosis.

Let us understand the histopathology of bone marrow necrosis. It is characterized by gelatinous transformation and necrosis of the myeloid tissue, focal hypoplasia, and background of amorphous, pink material. Grading of necrosis is essential because it helps one to assess the degree of damage to the bone marrow. Prognostic factors of bone marrow necrosis are greatly dependent on age of patient and nature of associated disease. Children with hematopoietic malignancies like acute myeloid leukemia with bone marrow necrosis appear to have the same prognosis as those without necrosis. Adult with bone marrow necrosis associated with non-cancerous condition may have better chances of complete recovery and long term survival than adults with hematologic malignancy. Prognosis in certain cases is difficult to predict if necrosis is due to a drug or disseminated intravascular coagulation versus an underlying malignancy.⁷

According to the available literature, the overall prognosis of cases with bone marrow necrosis is poor.

Early diagnosis can improve the survival rate. It can be achieved by treating the underlying cause/disease and providing supportive measures for anemia, thrombocytopenia or any other complication.⁸

CONCLUSION

This case is being presented because of the observations that patients with hematopoietic malignancies or solid

malignancies do present with certain alarming signs/symptoms or abnormal laboratory reports. One needs to be alert and correlate these abnormal parameters with the general condition of the patient. Various studies on the same subject have shown that the patient survival is limited to few months or even days after the histopathological diagnosis. What information does it convey? Early diagnosis is required especially in old age group patients presenting with fever, lethargy and abnormal laboratory reports. The underlying cause can be leukemia, lymphomas, solid malignancy poisoning or even infections.

ACKNOWLEDGMENT

Technicians of department of pathology.

REFERENCES

1. Janssens AM, Offner FC, Van Hove WZ. Bone marrow necrosis. *Cancer* 2000;88:1769-80.
2. Cowan JD, Rubin RN, Kies MS, Cerezo L. Bone marrow necrosis. *Cancer* 1980;46:2168-71.
3. Shafiq M, Ali N. Bone marrow necrosis - initial presentation in sickle cell anemia. *Am J Case Rep* 2013;14:416-8.
4. Al-Gwaiz LA. Bone marrow necrosis. *Ann Saudi Med* 1997;17:374-6.
5. Paydas S, Ergin M, Baslamisli F, Yavuz S, Zorludemir S, Sahin B, *et al.* Bone marrow necrosis: Clinicopathologic analysis of 20 cases and review of the literature. *Am J Hematol* 2002;70:300-5.
6. Lee JL, Lee JH, Kim MK, Cho HS, Bae YK, Cho KH, *et al.* A case of bone marrow necrosis with thrombotic thrombocytopenic purpura as a manifestation of occult colon cancer. *Jpn J Clin Oncol* 2004;34:476-80.
7. Devi K, Patnaik L, Chakravorty S, Mishra K, Mohanty GN. Bone marrow necrosis in paediatric patients. *Indian J Pathol Microbiol* 2000;43:47-50.
8. Santana AN, Ramos RG, Zanandrea EF, Brandão-Neto RA. Bone marrow necrosis successfully treated with corticosteroid. *Eur J Haematol* 2005;74:75-6.

How to cite this article: Choudhary S, Jayaprakash HT, Kumar BRS, Suba G. Bone Marrow Necrosis: A Case Report. *Int J Sci Stud* 2015;2(10):163-165.

Source of Support: Nil, **Conflict of Interest:** None declared.