

Duplication Renal Anomalies in Children: A Single Centre Experience

Sriram Krishnamoorthy¹, Shivraj Barath Kumar², Ramesh Babu³

¹Professor, Department of Urology, Sri Ramachandra Medical College & Research Institute, Chennai, Tamil Nadu, India, ²Post-graduate Student, Department of Urology, Sri Ramachandra Medical College & Research Institute, Chennai, Tamil Nadu, India, ³Professor, Department of Paediatric Urology, Sri Ramachandra Medical College & Research Institute, Chennai, Tamil Nadu, India

Abstract

Introduction: Duplication anomalies are one of the most common congenital anomalies of the urinary tract. The overall incidence of duplex kidneys is 1% of all live births. With routine antenatal screening by obstetricians becoming a common practice these days, more and more of such conditions are being detected antenatally

Purpose: Duplication anomalies of the kidneys are congenital anomalies, characterized by the presence of two separate pelvi-calyceal units. They may be associated with or without duplication of ureters. The overall incidence of duplex kidneys is 1% of all live births.

Materials & Methods: This was a retrospective audit on patients with duplication anomalies of the kidneys. All children with such duplication anomalies, who were admitted in our institution, were included in our study.

Results: Forty-two children were diagnosed to have duplication anomalies over a period of 11 years from 2004 to 2014. Nineteen children, who fitted well in our inclusion criteria and needed surgical intervention, were included in our study. Recurrent UTI was the most predominant mode of presentation. More than 50% of children needing surgical intervention ($n=10$) had presented with febrile UTI, recurrent break through infections necessitating multiple repeated admissions and a progressive deterioration of renal function. Ureterocele of the upper moiety was the most common anomaly observed in 10. Of these, two children had associated non-functioning upper moiety and underwent Hemi Nephrectomy.

Conclusion: Duplication anomalies require a systematic evaluation with all available armamentarium. Management of these conditions is tailor made based on the type of anatomy and function. A minimally invasive option is often successful in a majority of such patients. A systematic approach looking for specific objective ultrasound parameters will be helpful in diagnosis of children with duplication renal anomalies. High index of suspicion often leads to earlier detection and an earlier post natal intervention.

Key words: Duplication anomaly; Ectopic ureter; Hemi Nephrectomy; hydronephrosis, Ureterocele

INTRODUCTION

Duplication anomalies are one of the most common congenital anomalies of the urinary tract. The overall incidence of duplex kidneys is 1% of all live births.¹ It also accounts for 7.2% of patients with congenital urinary tract anomalies.² With increasing usage of antenatal screening

by obstetricians, more and more of such conditions are being detected antenatally.³

Duplication anomalies of the kidneys are congenital anomalies, characterized by the presence of two separate pelvicalyceal units. They may be associated with or without duplication of ureters.

Despite being one of the most common anomalies of the kidney, this condition is grossly under reported most of the times, owing largely to many of the cases that are either missed out during routine antenatal screening and/or as they remain largely asymptomatic in the early postnatal period.⁴ However, the risk of renal infection in children is increased by 20 folds with advancement in age.⁵ Many

Access this article online



www.ijss-sn.com

Month of Submission : 11-2015
Month of Peer Review : 12-2015
Month of Acceptance : 01-2016
Month of Publishing : 01-2016

Corresponding Author: Ramesh Babu, Department of Paediatric Urology, Sri Ramachandra Medical College, Chennai - 600 116, Tamil Nadu, India. Phone: +91-9840359062. E-mail: drrameshbabu1@gmail.com

of these children develop serious complications in their childhood or in the early adolescent period with recurrent breakthrough urinary tract infections, urinary incontinence or progressive deterioration of renal function, needing some form of medical or surgical intervention.⁶

The traditional classification of the duplex system into complete (two ureters) and incomplete (Y-shaped ureters) is based on intravenous urogram. With the advent of computed tomography (CT) urography, based on the radiological features of both the moieties, Rui defined a new classification. Here, the duplex kidney was classified into five types which can be depicted by CT urography prior to management that could facilitate in selecting an appropriate mode of treatment.⁷ However, magnetic resonance urography (MRU) has largely revolutionized the understanding of the complexity of pelvicalyceal anatomy, and the most comprehensive morphologic and functional evaluation of duplex systems can be achieved using MRU.⁸

The purpose of this article is to retrospectively audit the various duplication anomalies of the kidneys that we have come across in our institution and also to highlight their various modes of presentation, the various modalities of treatment offered and their long-term follow-up.

MATERIALS AND METHODS

This was a retrospective audit on patients with duplication anomalies of the kidneys. All children with duplication anomalies of the kidneys, who were admitted to Sri Ramachandra Medical College and Research Institute and subsequently underwent surgical correction of these anomalies, were included in our study.

Those children with recurrent urinary tract infections, life-threatening urosepsis or having intractable symptoms or progressive deterioration of renal function were subjected for surgical intervention.

Children with associated neurovesical dysfunction or those who presented with life-threatening urosepsis needing emergency temporary diversion procedures or those with the duplex system not needing any form of surgical intervention and those who had not turned up for a regular post-operative follow-up were all excluded from our study.

The pre-operative evaluation included Voiding cystourethrogram (VCUG), Intravenous urogram, CT assisted urogram, Nuclear Scintigraphy, and Magnetic Resonance Urogram whichever we felt as required and appropriate. All these patients were followed up

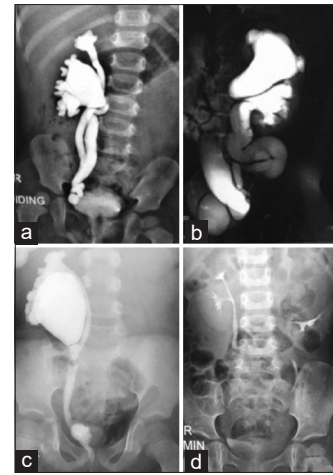


Figure 1: Describes the various types of duplication anomalies encountered in our study. (a) Vesico-ureteral reflux with both moieties functioning - underwent common sheath reimplant, (b) Ureterocele with functioning upper moiety - underwent endoscopic incision, (c) Lower pole PUJ with functioning moiety - underwent uretero-pyelostomy, (d) Non-functioning upper pole with ectopic ureter - underwent lap heminephrectomy

postoperatively with urine culture, ultrasound abdomen, and nuclear scintigraphy. VCUG was done in children with persistent urinary tract infections. The management of cases was individualized based on the anatomy and functioning status of the moieties.

RESULTS

A total of 42 children were diagnosed to have duplication anomalies over a period of 11-year from 2004 to 2014. Of these 19 children, who needed surgical intervention were included in our study.

Female children were more commonly involved than males, with the female to male ratio being 1.4-1. The mean age of presentation was 38 months, with the youngest presenting at 7 months and the oldest being 10 years of age. The median age of presentation was 36 months. Table 1 summarizes the details of all the 19 patients who had undergone surgical intervention.

Two patients had bilateral VUR, and one had unilateral VUR. All three underwent common sheath reimplantation. Duplication anomaly was seen almost equally on both sides, with the left ureter showing duplication in 10 children. Figure 1a-d gives examples of the various types of duplication anomalies that we had managed in our study.

Recurrent UTI was the most predominant mode of presentation. More than 50% of children needing surgical intervention ($n = 10$) had presented with febrile UTI, recurrent breakthrough infections necessitating multiple

Table 1: Patient characteristics, management, and follow-up of all children managed surgically

S. No.	Age (in months)/gender	Laterality	Presenting complaints	USG/MCU/IVU/CT/MRI/RENOGRAM	Surgical management	Follow-up (at 1 year)
1	60/F	L	Constant dribbling	Left ectopic ureter from non-functioning upper pole; no VUR into left lower/right	Lap upper pole HN	Preserved left lower pole function
2	11/F	L	Recurrent UTI	Ureterocele from non-functioning upper pole; no VUR into left lower/right	Lap upper pole HN	Preserved left lower pole function
3	10/M	L	Antenatal HN	Left duplex; ureterocele from functioning upper moiety; no VUR in any	TUI	Preserved left lower pole function; grade 2 VUR following incision; no UTIs
4	7/F	L	Antenatal HN	Left duplex; ureterocele from non-functioning upper moiety; no VUR	Lap upper pole heminephrectomy	Loss of function in left lower pole also at follow-up/no intervention; no UTIs
5	48/M	L	Recurrent UTI	Ureterocele from functioning upper pole; no VUR	TUI	No further UTIs; no VUR
6	120/F	L	Constant dribbling	Left ectopic ureter from functioning upper pole; no VUR into left upper/right	Uretero-pyelostomy left upper pole to lower pole; Ectopic ureter from left upper pole excised as low as possible	No UTIS, no more dribbling
7	72/M	R	Antenatal HN and recurrent UTI	VUR with non-functioning lower pole right; no VUR on left	Lap right lower pole heminephrectomy	Preserved right upper pole function; no further UTIs.
8	48/F	R	Recurrent UTI	Right sided duplex with VUR and both upper and lower functioning on right side/no VUR on left	Right common sheath reimplantation	No further UTIs
9	24/M	R	Recurrent UTI	Ureterocele from functioning upper pole; no VUR	TUI	No further UTIs; grade 3 VUR into upper pole; stable/no intervention
10	12/F	L	Antenatal HN	Left duplex; ureterocele from functioning upper moiety; no VUR in any	TUI	Preserved left lower pole function; No VUR following incision; no UTIs
11	36/M	BL	Recurrent UTI	Bilateral duplex with VUR and both upper and lower functioning	Bilateral common sheath reimplantation	No further UTIs
12	48/F	BL	Recurrent UTI	Bilateral duplex with VUR and both upper and lower functioning on both sides	Bilateral common sheath reimplantation	No further UTIs
13	60/M	L	Recurrent epididymo orchitis	Left ectopic ureter from non-functioning upper pole opening in verumontanum; grade 2 VUR into left lower/right	Lap upper pole heminephrectomy	Preserved left lower pole function; no UTIs; VUR managed conservatively
14	24/F	R	Antenatal HN	Ureterocele from functioning upper pole; no VUR	TUI	No further UTIs; grade 1 VUR; no UTIs
15	12/F	L	Antenatal HN	Ureterocele from functioning upper pole; grade 2 VUR lower pole	TUI	No further UTIs; Grade 1 VUR settled during follow-up; no UTIs
16	48/F	R	Constant dribbling	Right ectopic ureter from non-functioning upper pole; no VUR into right lower/right	Lap upper pole heminephrectomy	Preserved right lower pole function
17	36/M	L	Recurrent UTI	Ureterocele from functioning upper pole; no VUR	TUI	No further UTIs; no VUR
18	48/M	R	Recurrent UTI	Incomplete duplication; Lower pole PUJ; preserved function; VUR into common ureter left	Lower to upper Pyelo ureterostomy and left ureteric reimplantation	No Further UTI s
19	10/F	R	Antenatal HN	Ureterocele with functioning upper pole	TUI	No further UTIs. No VUR

M: Male, F: Female, R: Right; L: Left; BL: Bilateral, UTI: Urinary tract infections, HN: Hydronephrosis, VUR: Vesico-ureteral reflux, USG: Ultrasonogram of abdomen, CT: Computed tomography, IVU: Intravenous urogram, MCU: Micturating cystourethrogram, MRI: Magnetic resonance imaging, TUI: Transurethral incision, HN: Heminephrectomy

repeated admissions and a progressive deterioration of renal function. Those children who were antenatally diagnosed to have hydronephrosis and subsequently followed up in the postnatal period constituted the second most common mode of presentation ($n = 6$). All four children with ectopic ureter had incontinence of urine needing surgical intervention, but one of them, a 5-year-old male child had recurrent epididymo-orchitis, needing heminephrectomy.

Ureterocele of the upper moiety was the most common anomaly observed in 10 patients. Of these, two children had associated non-functioning upper moiety and underwent heminephrectomy.

All patients were symptom-free at the end of 1 year. None of the patients had any complication either during the procedure or thereafter. Four patients had reflux into the upper moiety following endoscopic incision. But none of

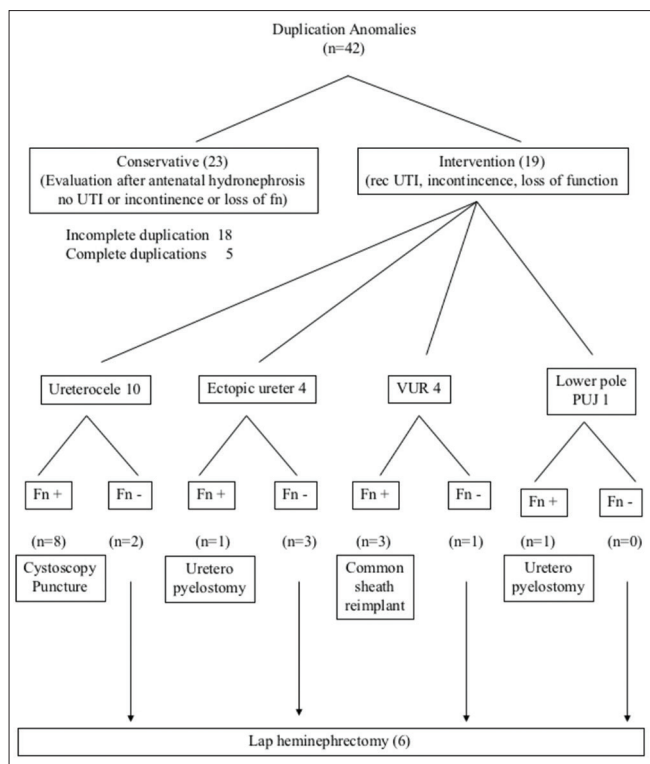


Figure 2: Algorithm giving an overview of management of all patients with duplication anomalies

them required intervention, as there were no breakthrough infections in any of these patients. One child had a slight decrease in upper moiety function after incision but is being followed up, as she is asymptomatic. One child, who underwent upper pole heminephrectomy, had a decrease in function of the lower moiety as well. As she did not have any symptoms, she has been kept under close monitoring. None of our children had any problems with the remnant stump after heminephrectomy. The flow chart in Figure 2 summarizes the details of the management of all patients with duplication anomalies.

DISCUSSION

The routine use of antenatal ultrasound screening in the second trimester has significantly increased the detection of various congenital anomalies in the fetuses. In one of the largest studies on more than 7000 fetuses, the urinary tract anomalies constituted 17.3% of the total fetal anomalies.⁹ Duplication of the renal pelvis and ureters is the most common urogenital anomaly.¹⁰ The overall reported incidence of duplication of upper urinary tract is 0.7-1%, and the most common anomaly associated with duplex system is vesico-ureteric reflux.¹¹

The development of the duplex system is known to be due to an additional ureteral bud arising from the mesonephric

duct and meeting the renal blastema at a separate site from the original bud.¹² It is not uncommon to have more than one renal abnormality in patients with the duplex system. In cases of complete duplication, the ureters enter the bladder in contrast to the moieties that they drain. The orifice of the upper moiety is characteristically located medial and caudal than the orifice of the lower moiety that is located cranial and lateral. This relationship is so consistent that it is called, Weigert-Meyer rule, which is seen to be obeyed in more than 90% of the cases.¹³

In one of the series of excretory urograms performed in 1716 children and 3480 adults to find out the overall incidence and complications of renal duplication anomalies, Privett *et al.* observed that the duplication anomalies were present in 1.8% of the general population, and females were twice as commonly involved as males.¹⁴ In our study, nearly 60% of the patients were females and bilateral in 10% of the cases.

With an ever increasing awareness in doing routine antenatal screening ultrasounds these days, more and more of these asymptomatic duplex anomalies are being diagnosed. Whitten *et al.* had observed that the use of routine antenatal ultrasound has considerably increased in the recent years, resulting in increased diagnosis of such malformations of the kidneys.⁴ From their retrospective audit of all patients who had antenatal USG, they were able to identify and classify the likelihood of duplex kidney based on objective ultrasound parameters. In their study, they were able to correctly diagnose the condition in as high as 75% of the cases using such prognostic features. In our series, 7 children were diagnosed antenatally (about 37%) and treated appropriately.

Ureteroceles have been one of the most common associated anomalies in patients with duplex systems. Godinho reports 4 cases of fetal ureterocele diagnosed at a mean gestational age of 23 weeks.¹⁵ Yong observed that ectopic ureteroceles were frequently associated with ureteral duplication.¹⁶ In their retrospective study on the post-operative results on 39 patients in 12 years' period, they observed that the median age at operation (common sheath reimplantation) was 16 months. In our study, the mean age at common sheath reimplantation was 44 months. 10 out of 19 children had ureteroceles in our study, and all of them were intravesical. Eight of them benefitted with endoscopic transurethral ureterocele incision. Two had non-functioning upper moiety and underwent upper moiety heminephrectomy.

The management of asymptomatic ureteroceles in the duplex system has always been a challenging task. The management depends on whether it is intravesical or extravasical, functional status of the upper moiety and

presence of associated reflux in the lower moiety. The endoscopic incision is the widely accepted appropriate treatment for a completely intravesical ureterocele.¹⁷ Sander observed a higher need for second surgery in children undergoing endoscopic incision of ureteroceles in the duplex system.^{18,19} In our study, 4 children had mild reflux following incision, but were asymptomatic and followed up with conservative measures.

In a select group of patients, non-surgical expectant treatment of antenatally detected ureteroceles has also been an accepted protocol. Shankar *et al.* observed in his study that in those with duplex system ureteroceles, 27% of them were asymptomatic and were followed up for 8 years and none of them required surgery or developed urinary tract infections.²⁰ In our series also, ureteroceles that were asymptomatic were followed up conservatively.

Uretero-pyelostomy or uretero-ureterostomy is a feasible option in a select group of patients with the duplex system and functioning moieties in whom the existing function of the moieties needs to be preserved. Choi and Oh, in their series of 63 children with complete duplex system concluded that uretero-ureterostomy had been the most successful nephron-sparing additional surgery, especially if the upper moiety is salvageable. Similar views were echoed by various other authors as well.^{19,21} In our series, two children were benefitted by uretero-pyelostomy (one for ectopic ureter and the other for pelvi-ureteric obstruction of lower moiety) with an excellent long-term follow-up.

The management of non-functioning moieties has been a relatively easy task. Laparoscopic heminephrectomy has been the standard treatment of poorly functioning moiety. It is a relatively safe mode of treatment, reproducible with relatively low morbidity and better treatment outcomes.²² Traditionally, the majority preferred a transperitoneal approach, but the retroperitoneal approach is a relatively new and well-tolerated minimally invasive approach despite being technically demanding.²³ The robotic transperitoneal approach is fast catching up and is now considered as an acceptable modality of treatment. Malik noted that robotic-assisted heminephrectomy provided comparable results in regard to complication rate and renal function of the remnant moiety.²⁴ In their comprehensive review of robot-assisted laparoscopic urology procedures, Song SH supported the view that despite a high purchase and maintenance cost involved, robotic technology has been a technically feasible and safe approach, especially for managing complex duplication anomalies.²⁵

On the other hand, heminephrectomy is not without complications. Gundeti *et al.*, in his study on assessment

of functional outcome 101 patients following heminephrectomy, observed that there was a mild decrease in the function of the remaining moiety in more than 50% of the patients.²⁶ Dalsan *et al.* reiterated the need for following up all remnant moieties with nuclear scintigraphy even though the extent of functional damage is subtle.²⁷ Complete ureterectomy along with heminephrectomy also has its own drawbacks. The risk of injury to the good ureter may outweigh the benefits of complete ureterectomy.²⁸ It's prudent to leave behind a distal ureteric stump in such cases.

Leclair reiterated that the possibility of vascular damage to the remaining moiety warranted a very cautious dissection of the renal pedicle. One should not hesitate to convert if clear visualization of vascular anatomy could not be ascertained.²⁹

Hisamatsu observed that recurrent infections after heminephrectomy were all treatment outcomes based on the initial surgical approach to ectopic ureterocele rather than isolated problems associated with a distal ureteral stump. They concluded that total ureterectomy is unnecessary at the time of heminephrectomy for a poorly functioning moiety because the distal ureteral stump rarely causes a problem.³⁰ In our series, we left behind a distal ureteral stump in all six cases to avoid injury to the adjacent normal ureter. None of them had complications as a result of this.

Most of the patients with the duplex system are asymptomatic. Many of the antenatally detected patients with duplication anomalies, when they were followed up in the postnatal period, were found to have a rather benign course. Treatment is indicated only when these patients are symptomatic either in the form of recurrent breakthrough infections or if there are clinical signs of deterioration of renal function. The treatment strategies are modified based on the functional status of the moieties, the degree of obstruction and the extent of dilatation of pelvicalyceal system, symptomatic status of ureteroceles, grade of vesico-ureteral reflux, and the site of the insertion of ectopic ureters.

In our institution, all children with antenatal hydronephrosis are followed up in the immediate postnatal period. All children are subjected for repeated periodic ultrasound abdomen, micturating cystourethrograms, and serial DTPA renograms. At any point of time, where if the infection is not settling with conservative measures, or if there is a progression of hydronephrosis or a deterioration of renal function, they are subjected for surgical intervention.

CONCLUSIONS

Duplication anomalies require a systematic evaluation with all available armamentarium. The management of these conditions is tailor made based on the type of anatomy and function. A minimally invasive option is often successful in a majority of such patients. A systematic approach looking for the presence of certain specific objective ultrasound parameters will be very helpful in the diagnosis of children with duplication renal anomalies. A high index of suspicion leads to an earlier detection of these anomalies and offers potential benefits, including earlier postnatal intervention. This considerably decreases the morbidity, risks of recurrent urinary tract infections, and progressive renal deterioration.

REFERENCES

- Abuhamad AZ, Horton CE Jr, Horton SH, Evans AT. Renal duplication anomalies in the fetus: Clues for prenatal diagnosis. *Ultrasound Obstet Gynecol* 1996;7:174-7.
- Fufezan O, Tatar S, Dee AM, Cramariuc R, Asavaoie C, Cosarca M. Large spectrum of complete urinary collecting system duplication exemplified by cases. *Pictorial essay. Med Ultrason* 2013;15:315-20.
- Adiego B, Martínez-Ten P, Perez-Pedregosa J, Illescas T, Barron E, Wong AE, *et al.* Antenatally diagnosed renal duplex anomalies: Sonographic features and long-term postnatal outcome. *J Ultrasound Med* 2011;30:809-15.
- Whitten SM, McHoney M, Wilcox DT, New S, Chitty LS. Accuracy of antenatal fetal ultrasound in the diagnosis of duplex kidneys. *Ultrasound Obstet Gynecol* 2003;21:342-6.
- Rodriguez MM. Congenital anomalies of the kidney and the urinary tract (CAKUT). *Fetal Pediatr Pathol* 2014;33:293-320.
- Whitten SM, Wilcox DT. Duplex systems. *Prenat Diagn* 2001;21:952-7.
- Ma R, Wu RD, Liu W, Wang G, Wang T, Xu ZD, *et al.* A new classification of duplex kidney based on kidney morphology and management. *Chin Med J (Engl)* 2013;126:615-9.
- Adeb M, Darge K, Dillman JR, Carr M, Epelman M. Magnetic resonance urography in evaluation of duplicated renal collecting systems. *Magn Reson Imaging Clin N Am* 2013;21:717-30.
- Stefos T, Plachouras N, Sotiriadis A, Papadimitriou D, Almoussa N, Navrozoglou I, *et al.* Routine obstetrical ultrasound at 18-22 weeks: Our experience on 7,236 fetuses. *J Matern Fetal Med* 1999;8:64-9.
- De Caluwé D, Chertin B, Puri P. Long-term outcome of the retained ureteral stump after lower pole heminephrectomy in duplex kidneys. *Eur Urol* 2002;42:63-6.
- Carter C, Malone P, Lewington V. Lower moiety heminephroureterectomy in the duplex refluxing kidney: The accuracy of isotopic scintigraphy in functional assessment. *Br J Urol* 1998;81:356-9.
- Callahan MJ. The drooping lily sign. *Radiology* 2001;219:226-8.
- Weiss JP. Embryogenesis of ureteral anomalies: A unifying theory. *Aust N Z J Surg* 1988;58:631-8.
- Privett JT, Jeans WD, Roylance J. The incidence and importance of renal duplication. *Clin Radiol* 1976;27:521-30.
- Godinho AB, Nunes C, Janeiro M, Carvalho R, Melo MA, da Graça LM. Ureterocele: Antenatal diagnosis and management. *Fetal Diagn Ther* 2013;34:188-91.
- Lee YS, Im YJ, Shin SH, Bascuna RT Jr, Ha JY, Han SW. Complications after common sheath reimplantation in pediatric patients with complicated duplex system. *Urology* 2015;85:457-62.
- Merlini E, Lelli Chiesa P. Obstructive ureterocele-an ongoing challenge. *World J Urol* 2004;22:107-14.
- Sander JC, Bilgutay AN, Stanasel I, Koh CJ, Janzen N, Gonzales ET, *et al.* Outcomes of endoscopic incision for the treatment of ureterocele in children at a single institution. *J Urol* 2015;193:662-6.
- Chacko JK, Koyle MA, Mingin GC, Furness PD rd. Ipsilateral ureteroureterostomy in the surgical management of the severely dilated ureter in ureteral duplication. *J Urol* 2007;178:1689-92.
- Shankar KR, Vishwanath N, Rickwood AM. Outcome of patients with prenatally detected duplex system ureterocele; natural history of those managed expectantly. *J Urol* 2001;165:1226-8.
- Choi H, Oh SJ. The management of children with complete ureteric duplication: Selective use of uretero-ureterostomy as a primary and salvage procedure. *BJU Int* 2000;86:508-12.
- You D, Bang JK, Kim KS. Analysis of the learning curve for laparoscopic renal surgeries in children. *Korean J Urol* 2009;50:380-6.
- Wallis MC, Khoury AE, Lorenzo AJ, Pippi-Salle JL, Bägli DJ, Farhat WA. Outcome analysis of retroperitoneal laparoscopic heminephrectomy in children. *J Urol* 2006;175:2277-80.
- Malik RD, Pariser JJ, Gundeti MS. Outcomes in pediatric robot-assisted laparoscopic heminephrectomy compared with contemporary open and laparoscopic series. *J Endourol* 2015;29:1346-52.
- Song SH, Kim KS. Current status of robot-assisted laparoscopic surgery in pediatric urology. *Korean J Urol* 2014;55:499-504.
- Gundeti MS, Ransley PG, Duffy PG, Cuckow PM, Wilcox DT. Renal outcome following heminephrectomy for duplex kidney. *J Urol* 2005;173:1743-4.
- You D, Bang JK, Shim M, Ryu DS, Kim KS. Analysis of the late outcome of laparoscopic heminephrectomy in children with duplex kidneys. *BJU Int* 2010;106:250-4.
- Ade-Ajayi N, Wilcox DT, Duffy PG, Ransley PG. Upper pole heminephrectomy: Is complete ureterectomy necessary? *BJU Int* 2001;88:77-9.
- Leclair MD, Vidal I, Suply E, Podevin G, Hélorou Y. Retroperitoneal laparoscopic heminephrectomy in duplex kidney in infants and children: A 15-year experience. *Eur Urol* 2009;56:385-9.
- Hisamatsu E, Takagi S, Nakagawa Y, Sugita Y. Nephrectomy and upper pole heminephrectomy for poorly functioning kidney: Is total ureterectomy necessary? *Indian J Urol* 2012;28:271-4.

How to cite this article: Krishnamoorthy S, Kumar SB, Babu R. Duplication Renal Anomalies in Children: A Single Centre Experience. *Int J Sci Stud* 2016;3(10):12-17.

Source of Support: Nil, **Conflict of Interest:** None declared.