

Feracrylum Versus Topical Adrenaline for Hemostasis in Tonsillectomy

D C Sathyaki¹, Mereen Susan Roy¹, M Mohan², Nibha Raghu³, Razal M Sheriff³

¹Assistant Professor, Department of ENT, Sri Siddhartha Medical College, Tumkur, Karnataka, India, ²Professor and Head, Department of ENT, Sri Siddhartha Medical College, Tumkur, Karnataka, India, ³Postgraduate Student, Department of ENT, Sri Siddhartha Medical College, Tumkur, Karnataka, India

Abstract

Background: Primary hemorrhage is the most common and fatal complication of tonsillectomy.

Aims and Objectives: The study was to compare the efficacy of feracrylum and topical adrenaline in hemostasis.

Materials and Methods: A total of 40 patients were divided into two groups of 20 patients each. Feracrylum was used in one group and topical adrenaline in the other.

Results: Hemorrhage was lesser in the group where feracrylum was used.

Conclusion: Feracrylum is advisable to achieve hemostasis in tonsillectomy.

Key words: Complication, Hemorrhage, Tonsillectomy

INTRODUCTION

Tonsillectomy is one of the most common surgeries performed by otolaryngologists. Tonsillectomy is generally performed as an inpatient surgery because of concerns regarding post-tonsillectomy hemorrhage. Hemorrhage, which is a severe complication associated with this procedure, has been reported to occur in 2-4% of patients.¹ Furthermore, bleeding in the upper aerodigestive tract always represents a significant risk.² Primary bleeding is generally considered to be related to surgical technique, whereas environmental factors that influence oropharyngeal healing contribute to secondary hemorrhage. For primary hemostasis, two different techniques are mainly used, bipolar diathermy, and suture ligation. Suturing the faucial pillars is typically used in severe hemorrhage where other techniques have failed.³

In this study, we intend to compare the use of gauze soaked in feracrylum with that of adrenaline pledgets.

Aims and Objectives

The study was to compare the efficacy of feracrylum with that of adrenaline in the management of primary hemorrhage in tonsillectomy.

MATERIALS AND METHODS

A total of 40 patients who underwent tonsillectomy in a tertiary care center from January 2016 to June 2016 were included in this study (Figure 1). They were divided into two groups of 20 patients each. Topical Adrenaline was used in one group and feracrylum in the other. Dissection and snare method was performed (Figure 2).

Inclusion Criteria

1. Age above 5 years
2. Chronic tonsillitis
3. Recurrent attacks of a sore throat.

Exclusion Criteria

1. Patients with bleeding diathesis
2. Acute exacerbation of chronic tonsillitis
3. Patients undergoing tonsillectomy for quinsy.

Access this article online



www.ijss-sn.com

Month of Submission : 11-2016
Month of Peer Review : 12-2016
Month of Acceptance : 12-2016
Month of Publishing : 01-2017

Corresponding Author: Dr. D C Sathyaki, Department of ENT, Sri Siddhartha Medical College, Agalakote, Tumkur, Karnataka, India. Phone: +91-9900284892. E-mail: sathyaki_dc@yahoo.co.in

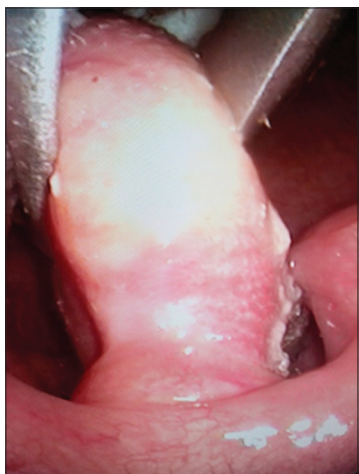


Figure 1: Tonsil being grasped

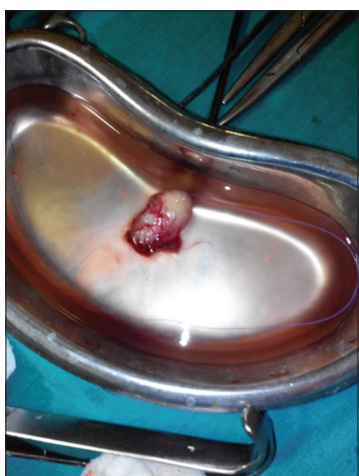

Figure 2: Tonsillectomy specimen

Observation

Age distribution

A total of 2 patients each were present in the age group of below 10 years. In the age group of 11-20 years, there were 4 patients in the adrenaline group and 8 patients in feracrylum group. In the age group of 21-30 years, there were 5 patients in the adrenaline group and 3 in feracrylum group. In the age group of 31-40 years, there were 7 patients in Adrenaline group and 6 in feracrylum group. In the age group of above 40 years, there were 2 patients in Adrenaline group and 1 in feracrylum group (Table 1).

Sex distribution

There were 13 female patients in both the groups and 7 male patients in both the group (Table 2).

Primary hemorrhage was present in 6 patients in adrenaline group (Table 3). Patients in the feracrylum group did not suffer from primary hemorrhage. $P = 0.02$ which was significant.

Bleeding vessels needed ligation in 12 patients belonging to adrenaline group (Table 4). Patients in the feracrylum

Table 1: Age distribution of patients who underwent tonsillectomy

Age in years	Adrenaline (%)	Feracrylum (%)	Total (%)
<10	2 (10)	2 (10)	4 (10)
10-20	4 (20)	8 (40)	12 (30)
21-30	5 (25)	3 (15)	8 (20)
31-40	7 (35)	6 (30)	13 (32.5)
>40	2 (10)	1 (5)	3 (7.5)
Total	20 (100)	20 (100)	40 (100)
Mean±SD	26.95±11.88	21.70±12.26	24.33±12.01

Table 2: Sex distribution of patients who underwent tonsillectomy

Gender	Adrenaline (%)	Feracrylum (%)	Total (%)
Female	13 (65)	13 (65)	26 (65)
Male	7 (35)	7 (35)	14 (35)
Total	20 (100)	20 (100)	40 (100)

Table 3: Primary haemorrhage

Primary haemorrhage	Adrenaline (%)	Feracrylum (%)	Total (%)
Absent	14 (70)	20 (100)	34 (85)
Present	6 (30)	0 (0)	6 (15)
Total	20 (100)	20 (100)	40 (100)

Table 4: Ligation of vessels during tonsillectomy

Ligation of vessels	Adrenaline (%)	Feracrylum (%)	Total (%)
Not ligated	8 (40)	20 (100)	28 (70)
Ligated	12 (60)	0 (0)	12 (30)
Total	20 (100)	20 (100)	40 (100)

group did not need ligation of vessels. $P < 0.001$ was also significant. Chi-square test was used.

DISCUSSION

Post-tonsillectomy hemorrhage remains the most serious and even fatal complication of tonsillectomy. Minor bleeding does not require any active measures, but major bleeding necessitates control of hemorrhage under general anesthesia in the operation theater. Hemostasis is usually secured by ligating the bleeders or coagulating them by diathermy, or by a combination of both of these. Primary hemorrhage generally occurs due to surgical technique. Secondary hemorrhage occurs due factors that influence wound healing. Most cases of fatal post-operative bleeding occur within the first 24 h after surgery. Mortality rate due to post-tonsillectomy hemorrhage is 2 in 10000 tonsillectomies. Post-operative monitoring of at least 6 h postsurgery is recommended in literature.³

Tong *et al.* did not report a single case of primary hemorrhage in their study of 90 tonsillectomies.⁴ Anwar *et al.* concluded

that suture ligation and coagulation diathermy are equally effective in the management of primary hemorrhage.³ Robb *et al.* concluded that perioperative use of tranexamic acid reduces primary hemorrhage.⁵ Senska *et al.* advocated suturing of tonsillar pillars to reduce primary hemorrhage.² Clark *et al.* concluded that incidence of post-tonsillectomy hemorrhage is more in adults than children.⁶

Feracrylum is a novel hemostatic agent. It is used in control of oozing in many of the surgeries. It decreases post-operative wound infection as it has antimicrobial properties. It activates thrombin which subsequently causes conversion of fibrinogen to fibrin which leads to clot formation. When it comes in contact with serum proteins, it forms a thin film which acts as a mechanical barrier preventing exogenous contamination. Feracrylum has a molecular weight of 500000-800000 Daltons, thus has no systemic absorption and no adverse effects on kidney, liver, cardiovascular, and hemopoietic systems.⁷

The previous studies have not mentioned the use of feracrylum in reducing post-tonsillectomy hemorrhage.

CONCLUSION

Use of feracrylum in tonsillectomy reduces the post-operative hemorrhage significantly. As it has antimicrobial property, it reduces the incidence of secondary hemorrhage also.

REFERENCES

1. Zaher G, Al-Noury K. The value of routine preoperative testing in the prediction of operative hemorrhage in adenotonsillectomy. *Indian J Otolaryngol Head Neck Surg* 2014;66 Suppl 1:30-6.
2. Senska G, Schröder H, Pütter C, Dost P. Significantly reducing post-tonsillectomy haemorrhage requiring surgery by suturing the faucial pillars: A retrospective analysis. *PLoS One* 2012;7:e47874.
3. Anwar K, Ahmad R, Khan M. Control of bleeding by silk ligation and diathermy coagulation during tonsillectomy: A comparison of efficacy of the two techniques in the first 24 hours after surgery. *Pak J Med Sci* 2015;31:961-4.
4. Tong WH, Hui TS, Wee CA. Is daycare tonsillectomy safe. *Iran J Otorhinolaryngol* 2016;28:183-8.
5. Robb PJ, Thorning G. Perioperative tranexamic acid in day-case paediatric tonsillectomy. *Ann R Coll Surg Engl* 2014;96:127-9.
6. Clark MP, Waddell A. The surgical arrest of post-tonsillectomy haemorrhage: Hospital episode statistics. *Ann R Coll Surg Engl* 2004;86:411-2.
7. Lahoti BK, Aggarwal G, Diwaker A, Sharma SS, Laddha A. Hemostasis during hypospadias surgery via topical application of feracrylum citrate: A randomized prospective study. *J Indian Assoc Pediatr Surg* 2010;15:87-9.

How to cite this article: Sathyaki DC, Roy MS, Mohan M, Raghu N, Sheriff RM. Feracrylum Versus Topical Adrenaline for Hemostasis in Tonsillectomy. *Int J Sci Stud* 2017;4(10):34-36.

Source of Support: Nil, **Conflict of Interest:** None declared.