

Maxillary Impacted Canine: Diagnosis and Contemporary Ortho Surgical Management Guidelines

Nitubroto Biswas¹, Soma Halder Biswas², Ajoy Kr Shahi³

¹Professor, Department of Periodontia and Implantology, Buddha Institute of Dental Sciences and Hospital, Patna, Bihar, India, ²Clinical Tutor, Department of Orthodontics, Dr. R. Ahmed Dental College and Hospital, Kolkata, West Bengal, India, ³Professor, Department of Oral and Maxillofacial Surgery, Buddha Institute of Dental Sciences and Hospital, Patna, Bihar, India

Abstract

Canines contribute significantly in functional occlusion and form the foundation of an esthetic smile. So, any factor that interferes with the normal development and eruption of canine has serious consequences. Surgical exposure and orthodontic traction of impacted canine demand patient cooperation, long treatment duration, high cost, and chances of damage to the tooth and adjacent structure. Early diagnosis of canine impaction is essential for proper deimpaction of canine. Determination of the prognosis of the impacted canine is essential before orthosurgical approach for management of this specific malocclusion. Proper knowledge of the position of canine in relation to the other anatomical structure is very important in surgical exposure and orthodontic management of impacted maxillary canine. In the present article, with an overview of incidence and etiology, we have mostly concentrated on diagnosis, prognosis, and orthosurgical management of impacted canine.

Key words: Diagnosis, Impacted canine, Management, Prognosis

INTRODUCTION

Impacted tooth is one that fails to erupt and will not attain its anatomical position beyond the chronological eruption date even after its root completion. The impacted maxillary canine is a frequently encountered clinical problem.

Maxillary canine is the most commonly impacted teeth, second only to third molars.¹ The permanent maxillary canine is frequently misplaced teeth in relation to other teeth in the maxilla. The prevalence of non-eruption and ectopic eruption of this tooth has been reported to be 0.9-2.0% in samples not previously selected for orthodontic treatment. The canine is the most frequently found palatal to the lateral incisor. Impactions are twice as common in

females. 8% have bilateral impactions.² Approximately, one-third of impacted maxillary canine is located labially, and two-thirds are located palatally.³

ETIOLOGY

Several etiologic factors are responsible for impaction of maxillary canine broadly termed under localized, systemic, and genetic.

Buccally impacted canine is mostly due to tooth size-arch length deficiency. Study shows only 17% of labial impacted canine shows insufficient space, whereas palatally impacted canine has sufficient space in 85% cases for eruption.⁴

Etiology of palatally impacted canine is related to two major theories - guidance theory and genetic theory.

The guidance theory proposes that canine erupts through a long, tortuous path. Lateral incisors serve as a guide to canine during the course of the eruption. If the root of lateral incisor is missing or malformed, the canine will not erupt. The presence of the lateral incisor root with the right length, formed at the right time, is an important

Access this article online



www.ijss-sn.com

Month of Submission : 11-2015
Month of Peer Review : 12-2015
Month of Acceptance : 01-2016
Month of Publishing : 01-2016

Corresponding Author: Dr. Soma Halder, Department of Orthodontics, Dr. R. Ahmed Dental College and Hospital, 114, A. J. C. Bose Road, Kolkata -14, West Bengal, India. Phone: +91-09475679714. E-mail: stdc32@gmail.com

variable needed to guide the mesially erupting canine in a more favorable distal and incisal direction.⁵

The genetic theory points genetic factor as primary etiology of palatally impacted canine and may be associated with missing or small lateral incisor.⁶ It has been suggested that transcription factors such as MSX1 and PAX9 might be involved in the genetic control of palatally displaced canines. Some studies reported that palatally impacted canines in association with enamel hypoplasia, small lateral incisor, aplasia of the second premolar, and infra occlusion of primary molars signifies genetic involvement.⁷

ROOT RESORPTION OF MAXILLARY LATERAL INCISORS

Ericsson and Kurol⁸ found that resorption of maxillary lateral incisors in relation to impacted canine was found to be more common in girls than in boys. The sex ratio was 3:1. The position of the cusp of the maxillary canine was positioned more mesially in the resorption group.

DIAGNOSIS

The diagnosis of canine impaction is based on both clinical and radiographic examinations.

Clinical Evaluation

It has been suggested that the following clinical signs must be correlated with chronological and dental age of the patient for proper diagnosis of maxillary canine impaction.⁹

- Delayed eruption of the permanent canine or prolonged retention of the deciduous canine beyond 14-15 years of age
- Absence of a normal labial canine bulge
- Presence of a palatal bulge (Figure 1)
- Delayed eruption, distal tipping, or migration of the lateral incisor.

Radiographic Evaluation

Extraoral radiographs such as cephalogram determine the relationship of the impacted teeth to the other facial structure and orthopantomograph (OPG) used to localize impacted teeth in all three planes. Intraoral radiographs such as occlusal radiograph (OR) determine the position of the impacted teeth relative to the midline. Intra-oral periapical radiograph determines the integrity of lamina dura.

Most widely recommended technique of localization of impacted canine is the parallax method. In radiologic terms, parallax (image/tube shift) is the apparent displacement of an image, relative to the image of a reference object, caused

by an actual change in the angulation of the X-ray beam. The reference object is normally the root of an adjacent tooth. The image of the tooth that is farther away from the X-ray tube moves in the same direction as the tube, and the image of the tooth closer to the X-ray tube moves in the opposite direction to the tube. A tube shift may be carried out in either the horizontal or the vertical plane.

Clark used two periapical radiographs in different horizontal angulation for a horizontal tube shift technique.

Keur used the combination of panoramic (PR) and ORs for a vertical tube shift (VTS).¹⁰ A PR is often taken as an initial radiograph, this combination of radiographs only requires one additional exposure, the OR. The PR tube is actually positioned behind the head at an angle of -7° to the occlusal plane. The OR is taken at an angle of $+60-65^\circ$ to the occlusal plane, i.e. there is an effective difference of $53-58^\circ$ between the taking of the two films. The image of the canine that is farther away from the X-ray tube moves in the same direction as the tube. If impacted teeth move more downward in OR than in OPG it is buccal in location if it moves upward, it is palatal in location. If the position is same in both radiographs, the tooth may be in mid alveolus (Figures 2 and 3).

VTS technique is preferred because OPG, which provides information about all the teeth, jaws, and the surrounding structures, is often taken as an initial radiograph and this combination only requires one additional exposure the OR. 50° of differences between the two radiographs makes it less technique sensitive procedure.¹¹

Complex and severe cases may demand a cone beam computed tomography (CBCT) for better visualization and precise surgical planning. Extent of damage of the adjacent tooth root, amount of bone surround each tooth, size of the follicle and precise buccolingual location can be determined from CBCT images. A comparison of two-dimensional image with CBCT shows a 21% disagreement in mesiodistal location and 16% disagreement in buccopalatal location.¹²

Determination of Prognosis

Prognosis of deimpaction of canine depends on the age of the patient, availability of space in the arch, favorable position of the impacted canine in the maxilla.

To determine the favorable position of the impacted canine one highly relevant classification is sector classification.¹³ It predicts the chance of future canine impaction as well as chances of correction by early intervention. Ericson and Kurol found that tip of impacted canine located more close to dental midline are

more prone to impaction.¹⁴ On the basis of this sector, classification was created. One line each was drawn a tangent to the mesial and distal height of contour of lateral incisor. The long axis of lateral incisor was drawn.

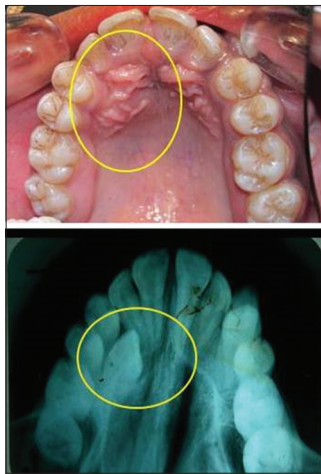


Figure 1: Palatal bulge in impacted palatal canine

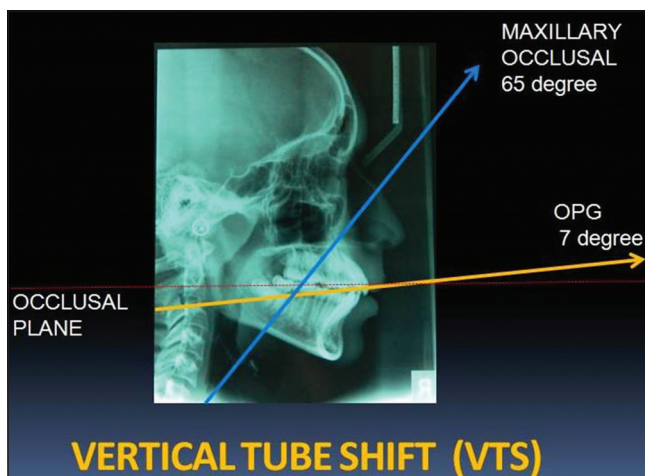


Figure 2: Diagrammatic representation of vertical tube shift technique

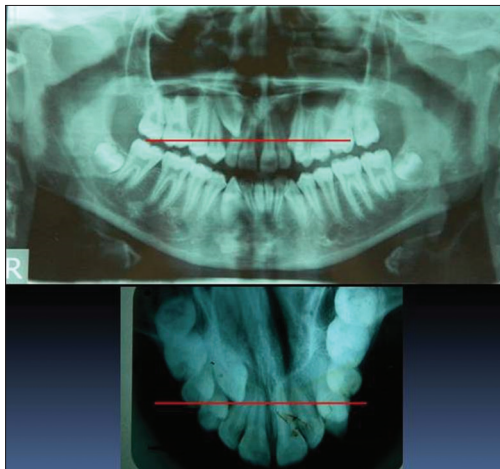


Figure 3: Vertical tube shift showing palatal impaction of canine

So, the area were divided into four sectors I, II, III, and IV from distal to mesial (Figure 4). 78% of the canines are destined to be impacted if their cusp tips are located in the sectors I, II, and III.

Another method of prediction of chances of canine impaction is the calculation of angulation of long axis of canine to the midline in OPG.¹⁵ If the angulation is more than 31 degree, the chance of spontaneous eruption after preventive treatment is less (Figure 5).

Management of Impacted Canines

Ideal approach for the management of impacted canine is interdisciplinary management comprises of a team of an orthodontist, oral surgeon, and periodontist. Intervention at an early age (10-13 years) with extraction of deciduous canine spontaneous eruption of permanent canine increases by 75% cases and severity of impaction decreases by 94% cases.¹⁶ Removal of physical barrier like a supernumerary tooth, odontome, fibrous bands, and tooth sac are helpful in tooth eruption. Creation of sufficient space by maxillary

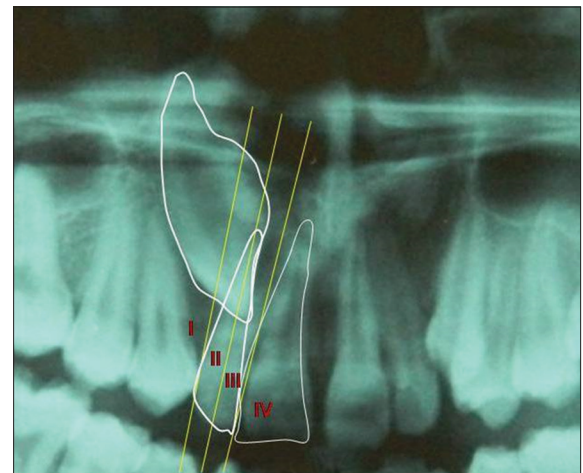


Figure 4: Sector classification

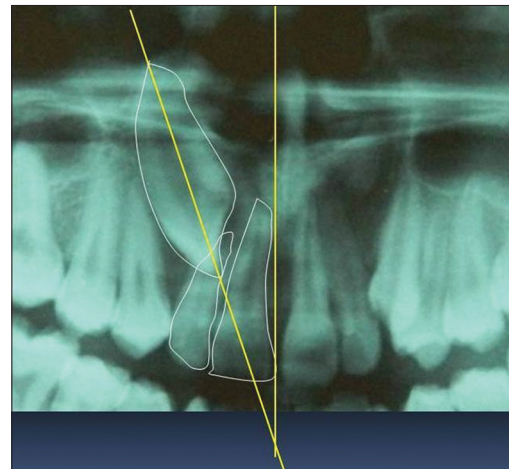


Figure 5: Angulation of canine to the midline

expansion and molar distalization improves the prognosis of canine impaction.

Surgically assisted orthodontic guidance is required when a definitive diagnosis of impaction is established, and possibilities of spontaneous eruption are exhausted. It is considered after complete root apex formation.¹⁷

Two different methods of surgical exposure of impacted canine have evolved, one method is commonly known as the open eruption technique, and the other method is called the closed eruption technique.

Open eruption involves the surgical excision of a wedge-shaped section of the overlying palatal mucosa after removal of the bone covering the ectopic canine. A surgical or periodontal pack is then placed over the exposed tooth for 7-10 days. After pack removal, the ectopic canine is often left to erupt naturally for a period of 4-6 day before a bonded attachment is placed, and orthodontic traction is commenced. This technique is mostly used for palatally impacted canines (Figure 6).

An alternative closed eruption method of surgical exposure is preferred by many oral surgeons and orthodontists. This technique usually involves raising a large full thickness flap with a minimum degree of bone removal to uncover the ectopic canine. Efforts are made not to uncover the cemento-enamel junction or not to disturb the periodontal ligament. Instead, an attachment or bracket with a braided wire ligature or gold chain connected to it is bonded to the crown of the exposed canine during surgery. The mucosa is then sutured back into place with the end of the wire ligature extending into the mouth either through the wound margin or through an incision placed in the flap. Orthodontic traction is usually commenced soon after the surgical exposure. This technique is mostly used for labially impacted canines (Figure 7).

When considering the periodontal implications of surgical exposure, an apically repositioned flap or closed eruption through keratinized gingival tissue is recommended for a labially ectopic canine. The soft tissues on the buccal aspect of the maxilla comprise keratinized attached gingiva at the alveolar margin and mobile non-keratinized tissue in the sulcus. There is conclusive evidence that an open eruption approach through non-keratinized gingiva should be avoided. Long-term periodontal health is better when the more resilient keratinized gingival tissue is maintained on the labial aspect of the canine.¹⁸

For palatally impacted canine significantly deeper mean pocket depths found palatal to the previously ectopic canine for those patients treated by the closed eruption

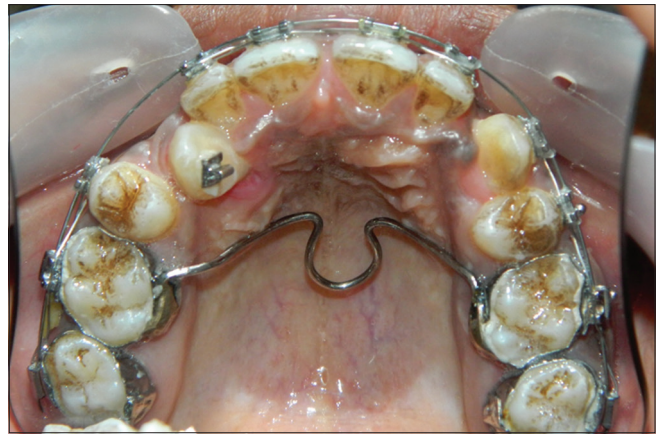


Figure 6: Open eruption technique

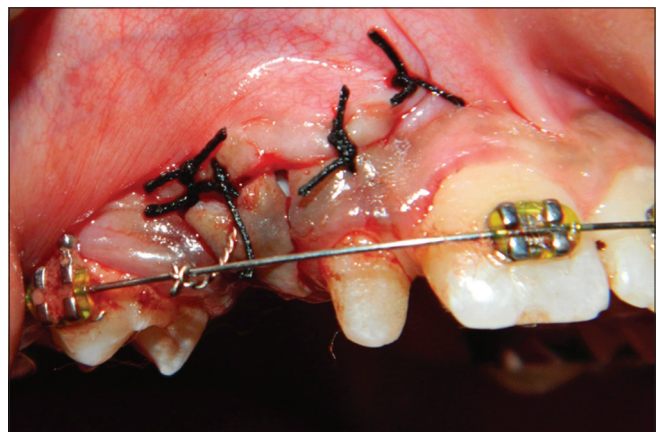

Figure 7: Closed eruption technique

technique than those patients treated by the open eruption. The removal of palatal mucosa during the open eruption technique had the same effect as a gingivectomy in reducing pocket depth. The mean attachment loss on the palatal aspect was significantly greater for the patients treated by open eruption than the patients treated by the closed eruption, but it has limited esthetic value. The interdental bone levels did not differ significantly.¹⁹

Orthodontic Management

For applying orthodontic traction following considerations are recommended:

- Creation and maintenance of sufficient space before surgical exposure
- Attachments should preferably low labiolingual profile, preventing flap tearing and buttonholing
- Orthodontic traction application is recommended soon after surgical exposure; the canine is pulled directly to its correct position and prevented from adopting a more anterior or palatal position and takes less treatment time²⁰
- Light force ranging around 60 g for orthodontic traction is used. The direction of orthodontic traction

is intended for vertical eruption away from the roots of the incisors

- Provision of arch wire of sufficient stiffness
- Torquing auxiliaries are used only in finishing stages. Ectopic canines requiring torquing root movements had 4% less bony support than those aligned by tipping or extrusive movements.²¹

Contemporary orthodontic devices are “Ballista spring”²² attached on the buccal surface of the posterior teeth, with a transpalatal arch as anchorage, provide a comfortable and controlled movement of the uncovered palatally impacted canine. For labially impacted canine stainless steel archwire auxiliary, cantilever spring, and titanium molybdenum alloy box loop, Australian helical archwire are used.^{23,24} Temporary anchorage device are nowadays used with great success in providing orthodontic traction to impacted canine.²⁵

Retention of deimpacted canine must be considered as, relapse of rotation and spacing may occur after completion of the orthodontic treatment of an impacted canine occurs in 17.4% of cases in comparison to 8.7% of the control tooth.²⁶ To minimize or prevent relapse supracrestal fiberotomy and bonded fixed retainers are required after completion of treatment.

CONCLUSION

The management of impacted canine is a complex procedure, require a multidisciplinary treatment approach. The clinician should communicate with each other to provide the patient with proper diagnosis, idea of prognosis, and optimal treatment plan based on scientific rationale.

REFERENCES

1. Mesotten K, Naert I, van Steenberghe D, Willems G. Bilaterally impacted maxillary canines and multiple missing teeth: A challenging adult case. *Orthod Craniofac Res* 2005;8:29-40.
2. Bishara SE. Impacted maxillary canines: A review. *Am J Orthod Dentofacial Orthop* 1992;101:159-71.
3. Ericson S, Kuroi J. Radiographic assessment of maxillary canine eruption in children with clinical signs of eruption disturbance. *Eur J Orthod* 1986;8:133-40.
4. Jacoby H. The etiology of maxillary canine impactions. *Am J Orthod* 1983;84:125-32.
5. Becker A. In defense of the guidance theory of palatal canine displacement. *Angle Orthod* 1995;65:95-8.
6. Peck S, Peck L, Kataja M. The palatally displaced canine as a dental anomaly of genetic origin. *Angle Orthod* 1994;64:249-56.
7. Baccetti T. A controlled study of associated dental anomalies. *Angle Orthod* 1998;68:267-74.
8. Ericson S, Kuroi PJ. Resorption of incisors after ectopic eruption of maxillary canines: A CT study. *Angle Orthod* 2000;70:415-23.
9. Ericson S, Kuroi J. Longitudinal study and analysis of clinical supervision of maxillary canine eruption. *Community Dent Oral Epidemiol* 1986;14:172-6.
10. Keur JJ. Radiographic localization techniques. *Aust Dent J* 1986;31:86-90.
11. Jacobs SG. Localization of the unerupted maxillary canine: How to and when to. *Am J Orthod Dentofacial Orthop* 1999;115:314-22.
12. Haney E, Gansky SA, Lee JS, Johnson E, Maki K, Miller AJ, *et al.* Comparative analysis of traditional radiographs and cone-beam computed tomography volumetric images in the diagnosis and treatment planning of maxillary impacted canines. *Am J Orthod Dentofacial Orthop* 2010;137:590-7.
13. Lindauer SJ, Rubenstein LK, Hang WM, Andersen WC, Isaacson RJ. Canine impaction identified early with panoramic radiographs. *J Am Dent Assoc* 1992;123:91-2, 95-7.
14. Ericson S, Kuroi J. Early treatment of palatally erupting maxillary canines by extraction of the primary canines. *Eur J Orthod* 1988;10:283-95.
15. Power SM, Short MB. An investigation into the response of palatally displaced canines to the removal of deciduous canines and an assessment of factors contributing to favourable eruption. *Br J Orthod* 1993;20:215-23.
16. Olive RJ. Orthodontic management of palatally impacted canine. *Aust Orthod J* 1994;65:99-102.
17. Warford JH Jr, Grandhi RK, Tira DE. Prediction of maxillary canine impaction using sectors and angular measurement. *Am J Orthod Dentofacial Orthop* 2003;124:651-5.
18. Vanarsdall RL, Corn H. Soft-tissue management of labially positioned unerupted teeth. *Am J Orthod* 1977;72:53-64.
19. Wisth PJ, Norderval K, Booe OE. Comparison of two surgical methods in combined surgical-orthodontic correction of impacted maxillary canines. *Acta Odontol Scand* 1976;34:53-7.
20. Burden DJ, Mullally BH, Robinson SN. Palatally ectopic canines: Closed eruption versus open eruption. *Am J Orthod Dentofacial Orthop* 1999;115:640-4.
21. Kohavi D, Becker A, Zilberman Y. Surgical exposure, orthodontic movement, and final tooth position as factors in periodontal breakdown of treated palatally impacted canines. *Am J Orthod* 1984;85:72-7.
22. Jacoby H. The “ballista spring” system for impacted teeth. *Am J Orthod* 1979;75:143-51.
23. Lindauer SJ, Isaacson RJ. One-couple orthodontic appliance systems. *Semin Orthod* 1995;1:12-24.
24. Hauser C, Lai YH, Karamaliki E. Eruption of impacted canines with an Australian helical archwire. *J Clin Orthod* 2000;34:538-41.
25. Park HS, Kwon OW, Sung JH. Micro-implant anchorage for forced eruption of impacted teeth. *J Clin Orthod* 2004;38:297-302.
26. Becker A, Smith P, Behar R. The incidence of anomalous maxillary lateral incisors in relation to palatally-displaced cuspids. *Angle Orthod* 1981;51:24-9.

How to cite this article: Biswas N, Halder S, Shahi AK. Maxillary Impacted Canine: Diagnosis and Contemporary Ortho Surgical Management Guidelines. *Int J Sci Stud* 2016;3(10):166-170.

Source of Support: Nil, **Conflict of Interest:** None declared.