

# Malignant Peripheral Nerve Sheath Tumor in Polio Affected Lower Limb: A Rare Case Report

J C Ravi Shankar<sup>1</sup>, Abhijit D Hiregoudar<sup>2</sup>, Priyanka<sup>3</sup>, Akshay V Gokak<sup>3</sup>

<sup>1</sup>3<sup>rd</sup> Year Post Graduate, Department of General Surgery, Karnataka Institute of Medical Sciences, Hubli, Karnataka, India, <sup>2</sup>Associate Professor, Department of General Surgery, Karnataka Institute of Medical Sciences, Hubli, Karnataka, India, <sup>3</sup>2<sup>nd</sup> Year Post Graduate, Department of General Surgery, Karnataka Institute of Medical Sciences, Hubli, Karnataka, India

## Abstract

Malignant peripheral nerve sheath tumors (MPNSTs) are highly aggressive soft tissue sarcomas that rarely occur sporadically in the general population. However, in patients with neurofibromatosis-1, they occur with a lifetime incidence of 8-13%. A 28-year-old polio affected male presented with a rapidly growing swelling in the polio affected left lower limb. Fine needle aspiration cytology and incisional biopsy showed features of MPNST. Above knee amputation followed by radiotherapy was given. Though sporadic MPNSTs are described, its presentation in a polio affected limb has not been described in the literature. This is the first such reported case, a rarest of presentation of a rare tumor.

**Key words:** Malignant peripheral nerve sheath tumors, Neurofibromatosis, Polio, Soft tissue sarcomas

## INTRODUCTION

Malignant peripheral nerve sheath tumors (MPNSTs) are highly aggressive soft tissue sarcomas that rarely occur sporadically in the general population. However, in patients with neurofibromatosis-1 (NF1), they occur with a lifetime incidence of 8-13%.<sup>1</sup> They account for 5-10% of soft tissue sarcomas.<sup>2,3</sup> The incidence of sporadic MPNSTs is low, with a lifetime risk of 0.001%.<sup>4</sup> Most MPNSTs are associated with major nerves of the body wall and extremities. These tumors originate from the nerve sheath rather than from the nerve itself.<sup>1</sup> All ages and both sexes may be affected. Sporadic cases are most common between 40 and 50 years of age while those occurring in the setting of NF1 are diagnosed some 10 years earlier.<sup>3</sup> The male and female ratio is 1:1.<sup>2</sup>

## CASE DESCRIPTION AND RESULTS

A 28-year-old male patient, who is polio affected individual presented with a history of rapidly growing

swelling in the polio affected limb since 4-5 months (Figure 1). He had no other symptoms and co-morbidities. His routine blood investigations were normal. Fine-needle aspiration cytology from the swelling showed features of soft tissue sarcoma probably MPNST. An incisional biopsy was done, which revealed spindle cell tumor suspicious of malignancy. Ultrasound abdomen and chest X-ray were done to rule out metastasis and were found to be normal. Because of the rapidity of the growth, above knee amputation was done (Figure 2). The patient was given radiotherapy and is in the regular follow-

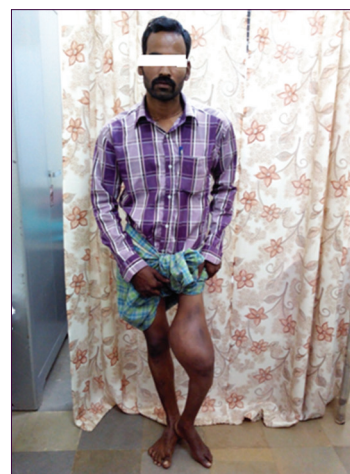

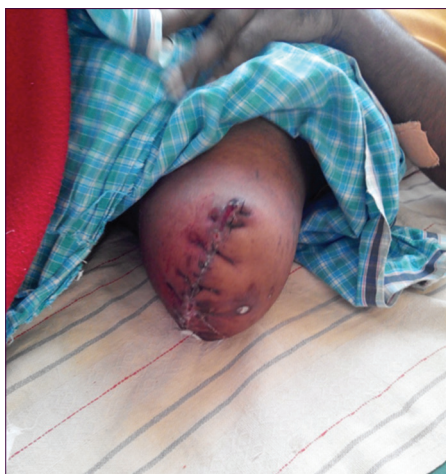Figure 1: Pre-op picture of the patient

Access this article online	
 www.ijss-sn.com	Month of Submission : 05-2015
	Month of Peer Review : 06-2015
	Month of Acceptance : 06-2015
	Month of Publishing : 07-2015

**Corresponding Author:** Dr. J C Ravi Shankar, Room No. 156, Vivek Boys Hostel, Kims, Vidyanagar, Hubli - 580 022, Karnataka, India. Phone No.: 91-8792367804. E-mail: drravishankarjc89@Gmail.Com

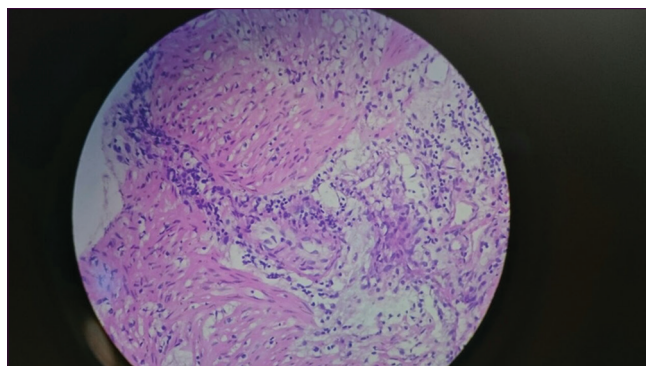


**Figure 2: Post-op picture of the patient**

up. Histopathology section showed spindle cells with a pleomorphic nucleus, and coarse nuclear chromatin, and prominent nucleoli (Figure 3). Immunohistochemistry from the growth showed diffuse cytoplasmic positivity to vimentin, focal positivity for smooth muscle actin and no reactivity for desmin and S-100.

## DISCUSSION

Soft tissue sarcomas constitute <1% of overall malignant tumors. The annual incidence rate of soft tissue sarcoma range between 1.4 and 5.0 cases per 100,000. Incidence patterns vary considerably by histologic type and subtype. The incidence for most types of soft tissue sarcoma increases progressively with age.<sup>1</sup> MPNSTs account for up to 10% of all soft tissue sarcomas.<sup>5</sup> Both sporadic and NF1-associated MPNSTs display complex karyotypes and clonal chromosomal aberrations. No clear difference in karyotypic profile between sporadic cases and NF1-associated MPNSTs has been detected.<sup>3</sup> The NF1 gene is implicated in sporadic as well as NF1-associated MPNST. TP53 (on 17p13) is frequently inactivated in MPNST through mutations or deletions, correlating with the frequent loss of 17p.<sup>1</sup> One study has reported poor overall patient survival associated with simultaneous gain of 17q and 7p.<sup>3</sup> Morphologically, MPNSTs are monomorphic spindle cell tumors often with alternating myxoid and cellular areas. The spindle cells in MPNSTs are typically focally reactive for S100 protein in 50-70% of cases.<sup>1,3</sup> Etiology and risk factors include genetic factors (NF), radiation (9%) and trauma. The most common sites affected are extremities followed by retroperitoneal/intraabdominal and truncal. In few cases affecting intracranial nerves are also reported.<sup>4</sup> They commonly present with a rapidly enlarging mass. Imaging modalities include computed tomography, magnetic resonance imaging, positron emission tomography scan. Most common sites of metastasis are lungs (extremity),



**Figure 3: Histopathology picture showing spindle cells**

liver (retroperitoneal or visceral) and subcutaneous tissue.<sup>1,2</sup> Treatment is complete surgical excision with or without radiotherapy, or neoadjuvant chemotherapy with surgery.<sup>1,6</sup> Isolated limb perfusion is used for treating extremity sarcomas for whom amputation is the only option for local treatment.<sup>7</sup>

Due to the relative rarity of MPNSTs, there have been few large studies into survival and those reporting 5-year survival lack consistency, with survival rates in the range of 39-85%. Few studies have suggested NF1 as an independent indicator of poor prognosis in MPNSTs.<sup>5</sup> A combination of clinical, pathological, and immunohistochemistry helps in diagnosing these tumors. Primary site, size, and surgical margins are significant for disease-free survival and overall survival.<sup>6</sup> Though multimodality therapy, including surgical resection and adjuvant radiotherapy, is available, the prognosis remains dismal.<sup>8,9</sup>

Recent studies have suggested the overexpression of *CD155*, a poliovirus receptor was observed in various types of soft tissue sarcoma and upregulated *CD155* expression was a significant predictor of local recurrence. Based on these studies, a promising target for oncolytic virotherapy using live attenuated poliovirus for soft tissue sarcoma has been thought.<sup>10</sup>

## CONCLUSION

This case report supports the fact that oncolytic virotherapy using poliovirus can be a potential treatment modality for soft tissue sarcomas. Further research is needed to in this regard to consider the same in the near future.

## ACKNOWLEDGMENT

Authors would like to acknowledge Dr. Rames Hosmani, Dr. Narayan Hebsur and Dr. Sandhya N for their critical review of the manuscript.

## REFERENCES

1. DeVita VT, Lawrence TS, Rosenberg SA. DeVita, Hellman, and Rosenberg's Cancer: Principles and Practice of Oncology. 9th ed. Philadelphia: Wolters Kluwers Publication; 2011.
2. Stark AM, Buhl R, Hugo HH, Mehdorn HM. Malignant peripheral nerve sheath tumours – Report of 8 cases and review of the literature. *Acta Neurochir (Wien)* 2001;143:357-63.
3. Mertens F, Lothe RA. Peripheral nerve sheath tumours. *Atlas Genet Cytogenet Oncol Haematol* 2001;5:210-2.
4. Ziadi A, Saliba I. Malignant peripheral nerve sheath tumor of intracranial nerve: A case series review. *Auris Nasus Larynx* 2010;37:539-45.
5. Porter DE, Prasad V, Foster L, Dall GF, Birch R, Grimer RJ. Survival in malignant peripheral nerve sheath tumours: A comparison between sporadic and neurofibromatosis type-1 associated tumours. *Sarcoma* 2009;2009:756395.
6. Longhi A, Errani C, Magagnoli G, Alberghini M, Gambarotti M, Mercuri M, *et al.* High grade malignant peripheral nerve sheath tumors: outcome of 62 patients with localized disease and review of the literature. *J Chemother* 2010;22:413-8.
7. Feig BW, Berger DH, Fuhrman GM. The M. D. Anderson T. Surgical Oncology Handbook. 4<sup>th</sup> ed. Texas: Lippincott Williams and Wilkins Publication; 2006.
8. Kosmas C, Tsakonas G, Evgenidi K, Gassiamis A, Savva L, Mylonakis N, *et al.* Malignant peripheral nerve sheath tumor in neurofibromatosis type-1: Two case reports. *Cases J* 2009;2:7612.
9. Kar M, Deo SV, Shukla NK, Malik A, DattaGupta S, Mohanti BK, *et al.* Malignant peripheral nerve sheath tumors (MPNST) – Clinicopathological study and treatment outcome of twenty-four cases. *World J Surg Oncol* 2006;4:55.
10. Atsumi S, Matsumine A, Toyoda H, Niimi R, Iino T, Sudo A. Prognostic significance of CD155 mRNA expression in soft tissue sarcomas. *Oncol Lett* 2013;5:1771-6.

**How to cite this article:** Ravi Shankar JC, Hiregoudar AD, Priyanka, Gokak AV. Malignant Peripheral Nerve Sheath Tumor in Polio Affected Lower Limb: A Rare Case Report. *Int J Sci Stud* 2015;3(4):165-167.

**Source of Support:** Nil, **Conflict of Interest:** None declared.