

# Fetus Papyraceous: A Rare Case Report and Review of Literature

N Usharani<sup>1</sup>, Suyajna D Joshi<sup>2</sup>, D Veena<sup>3</sup>

<sup>1</sup>Associate Professor, Department of Obstetrics and Gynecology, Vijayanagara Institute of Medical Sciences (VIMS), Bellary, Karnataka, India,

<sup>2</sup>Professor and HOD, Department of Obstetrics and Gynecology, Vijayanagara Institute of Medical Sciences (VIMS), Bellary, Karnataka, India,

<sup>3</sup>PG in Department of Obstetrics and Gynecology, Vijayanagara Institute of Medical Sciences (VIMS), Bellary, Karnataka, India

## Abstract

Fetus papyraceous (FP) is a rare obstetric complication in multiple gestations. It is defined as a compressed fetus, the mummified, parchment-like remains of a dead twin that is retained *in-utero* after intrauterine death in the second trimester. The data of various reports on FP were collected from internet literature search. Though the maternal and fetal complications in affected cases can be severe, most cases can be managed conservatively without any complications. We report a case of FP with a literature review of maternal and neonatal outcomes and management. Successful outcome is related to careful monitoring during pregnancy.

**Key words:** Fetal death, Fetus papyraceous, Twin pregnancy

## INTRODUCTION

The term fetus papyraceous (FP) is used when intrauterine fetal demise of a twin, early in pregnancy, occurs, with retention of the fetus for a minimum of 10 weeks, resulting in mechanical compression of the small fetus such that it resembles parchment paper.<sup>1</sup> When the fetus dies in early pregnancy, the amniotic fluid, and placental tissue are absorbed and the fetus is compressed between the membranes with the co-living twin. It is usually discovered among the placenta and membranes of its well-developed twin. Appearance of a FP frequently indicates the presence of a hostile intrauterine environment.<sup>2</sup>

FP occurs in subjects with multiple gestations. There is an increase in the incidence of multiple fetal pregnancies as the consequence of advances in assisted reproductive technologies. Prior to antenatal visits and use of ultrasound examination, the diagnosis of FP was only possible after delivery. The advent of real-time ultrasound using the

intravaginal probe permitted the diagnosis of multiple gestations as early as 4 weeks after conception. In late second and third trimesters, it is not always possible to diagnose FP by ultrasound examination.<sup>3</sup> But with the advanced ultrasound machines and techniques used today, there are even more early multiple fetal gestations being documented. The death of one twin in first trimester with vanishing twin syndrome is relatively common (up to 29%) and the pregnancy usually continues with little adverse effect on the mother and twin. But, the death of one twin in second or third trimester is more serious with an increased risk for surviving twin and possibility of maternal disseminated intravascular coagulation (DIC). It is emphasized that a close high-risk obstetric management must be used and a careful pediatric follow-up must be done afterward.<sup>4</sup> The sequel of single fetal death in a twin pregnancy depends on gestation and placentation. Conservative management is preferred. Adequate counselling, psychological support, and long-term follow-up are mandatory. If FP is diagnosed antenatally, serial evaluation of the surviving fetus by sonography, biophysical profile, Doppler, and maternal coagulation factors should be done serially. Zygosity and chorionicity evaluation should be performed antenatally. The timing and procedure for the termination of a pregnancy with a surviving twin are determined primarily by the maturity of the fetus and type of the placenta.<sup>5</sup> In many cases of FP, there are no complications to the mother or the surviving

### Access this article online



www.ijss-sn.com

**Month of Submission :** 05-2015  
**Month of Peer Review :** 06-2015  
**Month of Acceptance :** 07-2015  
**Month of Publishing :** 07-2015

**Corresponding Author:** N Usharani, Opd No.123, Department of Skin and STD, Vijayanagara Institute of Medical Sciences (VIMS), Bellary - 583 104, Karnataka, India. Phone Nos.: 09739678553, 09739678554. E-mail: ushadrrani@gmail.com

twin. Expectant management with close maternal and fetal surveillance is advised.

Here, we report a case of FP identified on curettage for retained products of conception based on check scan done after normal vaginal delivery in view of ultrasonography (USG) finding of intrauterine death (IUD) of one twin in second trimester.

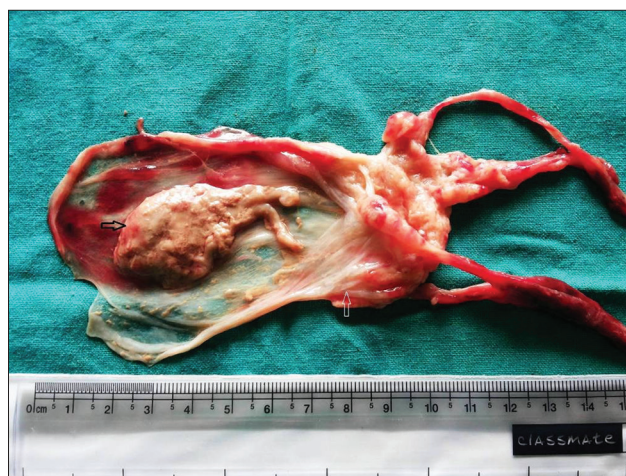## CASE REPORT

A 25-year-old woman (G<sub>2</sub>P<sub>1</sub>L<sub>0</sub>) with 38 weeks of gestation presented to our department, with labor pains. She had pre-eclampsia during the previous pregnancy and an induced preterm delivery of baby weighing 1.5 kg. Baby died 12 hours following birth due to prematurity. During the present pregnancy, first trimester (11 weeks) USG showed dichorionic diamniotic discordant twins. At 17 weeks, USG showed IUD of one twin and live second twin. Serial scans done at 20, 24, and 28 weeks of gestation showed a persistence of dead fetus at the right side of the uterine wall. However, scans done at 32 weeks and 35 weeks gestational age failed to visualize the dead twin due to compression by the live fetus. Throughout the antenatal period, she was followed up regularly for infections, consumptive coagulopathy and also for well-being of the live twin.

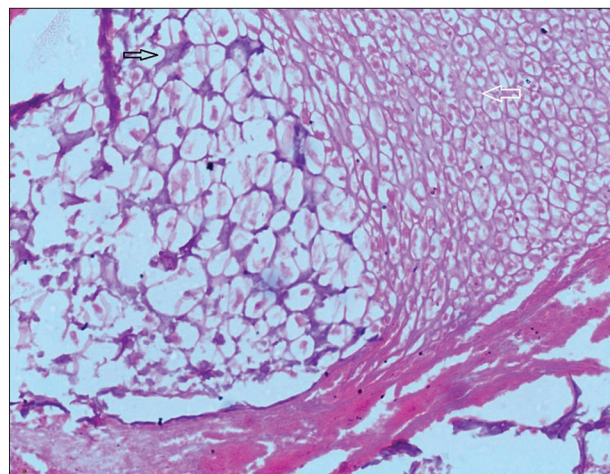
On general physical examination, vitals were stable. Abdominal examination showed term size uterus with adequate contractions, cephalic presentation, engaged head, and normal fetal heart rate. On vaginal examination, she was in active labor. Routine investigations and coagulation profile were normal. She delivered vaginally, a live term male baby weighing 2.5 kg within 2 hours of admission without any postpartal complication. As the dead second twin was not expelled within 24 hours following delivery, a check scan was advised which suggested retained products of conception measuring 24 × 18 × 12 mm. The patient underwent check curettage under short general anesthesia on the second post-natal day, and mass measuring 3 × 2 cm (Figure 1) was removed. Histopathology confirmed the diagnosis of FP (Figure 2). Post-procedure patient was stable. She was followed up for 6 weeks every fortnightly, and there were no further complications.

## DISCUSSION

Being a rare complication, the incidence of FP has been reported at 1 in 12,000 pregnancies and ranges between 1:184 and 1:200 twin pregnancies.<sup>6</sup> But the actual rate of multiple pregnancies is significantly larger than that observed during labor because of the fact that in the



**Figure 1: Gross specimen showing dead mummified fetus (black arrow) and the placenta (white arrow)**



**Figure 2: Microscopic appearance showing areas of calcification (black arrow) and areas of ghost cells (white arrow)**

course of pregnancy IUD of one or more fetuses may occur.<sup>7</sup> Depending on the gestational period at which fetal death occurs, there are three forms of this complication; vanishing twin syndrome in the first trimester, FP in the second and the macerated twin in the third trimester. In most cases, death occurs in the second trimester.

The only sign of the death of one embryo of a multiple pregnancies in the first 6-8 weeks may be a cyst on the fetal surface of the surviving twin's placenta. After 8 weeks, the death of one embryo, with resorption of amniotic fluid and mummification of the fetal parts, will cause a FP.<sup>8</sup> The degree of compression depends on the time span between fetal death and delivery; the larger the fetus, the more difficult it is to become a FP.<sup>9</sup> Attributable causes for the IUD of one fetus include twin-twin transfusion syndrome, membranous or velamentous cord insertion, true cord knot, cord stricture, placental insufficiency, and congenital anomalies.<sup>10</sup> Cord complications have been

**Table 1: Maternal and neonatal outcomes and management of FP**

Study	Years	Special features
Airede <i>et al.</i> <sup>14</sup>	2005	Healthy female baby weighing 2.5 kg. FP weighing 150 g with obvious musculoskeletal abnormalities
Kursheed <i>et al.</i> <sup>4</sup>	2008	Diamniotic dichorionic placenta. Developed pregnancy induced hypertension at 38 weeks gestation treated with methyldopa 500 mg twice daily. Healthy female baby weighing 3 kg. FP weighing about 100 g with placenta 50 g
Manjula <i>et al.</i> <sup>15</sup>	2011	Live pre-term female baby delivered by breech presentation weighing 1 kg. Manual removal of placenta with FP weighing 100 g and 8 cm in length. FP obstructed placental expulsion
Rahman <i>et al.</i> <sup>5</sup>	2013	Monochorionic monoamniotic placenta. Emergency CS was done in view of breech presentation. Healthy female baby weighing 2.9 kg with FP weighing 700 g delivered
Bozkurt <i>et al.</i> <sup>3</sup>	2013	Diamniotic dichorionic pregnancy. Healthy baby weighing 3.2 kg. FP weighing 200 g, measuring 15 cm in length
Dahiya <i>et al.</i> <sup>16</sup>	2014	Monochorionic diamniotic twin pregnancy. Healthy male baby weighing 2.8 kg, FP weighing 150 g, 8 cm length. Second fetus was dead with a gestational age of 17 weeks.
Kaur <i>et al.</i> <sup>17</sup>	2014	A dead second fetus at 13 weeks 2 days. Emergency CS because of first twin presenting as breech. Female FP weighing 80 g. Diamniotic and dichorionic pregnancy
Mynso <i>et al.</i> <sup>18</sup>	2015	Twin FP, about 13.5 and 9.5 cm in length, flattened, parchment-like and compressed. Single healthy male baby weighing 3.1 kg
Present report	2015	Dichorionic diamniotic discordant twins. A live term male baby weighing 2.5 kg. Check curettage on second post-natal day showed mass measuring 3×2 cm, with histopathology confirming FP

FP: Fetus papyraceous, CS: Caesarean section

found in 30%, congenital anomalies in 25% of cases and birth weight discordance has been responsible in 11-12% of cases. In our case, there was discordant growth.

The primary concern of FP is its effect on mother and surviving co-twin. The prognosis for surviving fetuses of a multigestational pregnancy with a spontaneous fetal demise depends on several factors: Number of the fetuses, gestational age at the time of the death, the reason for the death, the chorionicity and the length of time between demise and delivery of surviving fetus/es (Table 1). In dichorionic twins, the prognosis for the surviving twin is relatively better and immaturity is the risk factor. In the case of monochorionic twins, the prognosis is poor and associated with neurological damage in the survivor.<sup>11</sup>

In a the systematic review by Ong *et al.* of prognosis for the co-twin showed the odds of IUD of the co-twin, neurological abnormality and pre-term labor among survivors to be six, four, and two times higher in monochorionic compared with dichorionic pregnancies.<sup>12</sup> But in our case, there was no such complication seen in surviving co-twin.

Maternal complications include pre-term labor, infection from a retained fetus, severe puerperal hemorrhage, consumptive coagulopathy, and obstruction by a low-lying FP causing dystocia leading to caesarean delivery. It is necessary to make a timely diagnosis to prevent severe complications. It is important to reassure the patient that normal outcome is expected in most of the cases. Maternal consumptive coagulopathy as a complication of a late fetal demise is a rarely reported complication.<sup>13</sup> The possible explanation for such a low incidence of consumptive coagulopathy is the short relative interval from death until delivery of the surviving fetus. Gross disruption of the

maternal coagulation mechanism rarely develops within 1-month after the fetal death, although, if retained longer, approximately 25% will develop a coagulopathy. However, in many cases of FP, there are no complications to the mother or the surviving twin, similar to our case.

Due to the possible occurrence of several complications, the condition of both the mother and the surviving fetus requires close supervision and specialist obstetric care. It is necessary to document the IUD of one of the fetuses, for legal protection against the accusation of malpractice and having caused neurological damage to the child during birth.

## CONCLUSION

Delayed recognition of FP can have a grave prognosis. Hence, early diagnosis and prevention to avoid the possible complications is the best measure. Patients should be followed closely for fetal well-being and the possibility of maternal infection or consumptive coagulopathy by serial ultrasound examinations, hematological, and biochemical monitoring of the mother in the antenatal period and also after the delivery. A complete and careful examination of the placenta is must.

## REFERENCES

1. Dickey RP, Taylor SN, Lu PY, Sartor BM, Storment JM, Rye PH, *et al.* Spontaneous reduction of multiple pregnancy: Incidence and effect on outcome. *Am J Obstet Gynecol* 2002;186:77-83.
2. Dash S, Nanda SS, Behera A. Fetus papyraceous: A case report. *Sch J Appl Med Sci* 2013;1:587-8.
3. Bozkurt M, Kara D. Fetus papyraceous in a twin pregnancy: A case report without any maternal and fetal complications. *Proc Obstet Gynecol* 2013;3:1-5.
4. Kursheed R, Ahmed A, Parveen K. Foetus papyraceous in twin pregnancy-a case report. *Internet J Gynecol Obstet* 2008;11:2.

5. Rahman H, Pathak R, Dubey S, Chavan P, Sharma BK, Khaldi E. Fetus papyraceus in uniovular twin: Death of one twin in early third trimester and successful outcome of other twin at term: A rare case report. *Gen Med* 2013;1:1-4.
6. Woo HH, Sin SY, Tang LC. Single foetal death in twin pregnancies: Review of the maternal and neonatal outcomes and management. *Hong Kong Med J* 2000;6:293-300.
7. Landy HJ, Keith LG. The vanishing twin: A review. *Hum Reprod Update* 1998;4:177-83.
8. Daw E. Fetus papyraceus--11 cases. *Postgrad Med J* 1983;59:598-600.
9. Benirschke K. Intrauterine death of a twin: Mechanisms, implications for surviving twin, and placental pathology. *Semin Diagn Pathol* 1993;10:222-31.
10. Akbar M, Ikram M, Talib W, Saeed R, Saeed M. Fetus papyraceus: Demise of one twin in second trimester with successful outcome in second twin at term. *Prof Med J* 2005;12:351-3.
11. Fusi L, Gordon H. Twin pregnancy complicated by single intrauterine death. Problems and outcome with conservative management. *Br J Obstet Gynaecol* 1990;97:511-6.
12. Ong SS, Zamora J, Khan KS, Kilby MD. Prognosis for the co-twin following single-twin death: A systematic review. *BJOG* 2006;113:992-8.
13. Novak CM, Patel SV, Baschat AA, Hickey KW, Petersen SM. Maternal coagulopathy after umbilical cord occlusion for twin reversed arterial perfusion sequence. *Obstet Gynecol* 2013;122:498-500.
14. Airede LR, Ahmed Y. Fetus papyraceus: A case report. *Ann Afr Med* 2005;4:136-8.
15. Manjula NV, Sujani BK, Shetty S. Fetus papyraceus: A case report of premature rupture of membranes with adherent placenta. *Proc Obstet Gynecol* 2011;2:16.
16. Dahiya P, Bains R. Conservative management of fetus papyraceus: A report of two cases. *Oman Med J* 2014;29:132-4.
17. Kaur K, Kaur P, Kaur A, Singh B, Walia S, Rani M. Fetus papyraceus in a twin pregnancy: A case report. *Indian J Clin Pract* 2014;25:558-60.
18. Mynso KS, Singh LB, Singh NN, Meetie LT, Devi KP, Sharma S. Fetus papyraceus – A case report with successful maternal and fetal outcome of the triplet. *IOSR J Dent Med Sci* 2015;14:9-11.

**How to cite this article:** Usharani N, Joshi SD, Veena D. Fetus Papyraceus: A Rare Case Report and Review of Literature. *Int J Sci Stud* 2015;3(4):184-187.

**Source of Support:** Nil, **Conflict of Interest:** None declared.