

Prevalence of Visual Impairment after Blunt Ocular Trauma in a Tertiary Hospital

M A Rani Sujatha¹, Aysha Nazlin², Sridevi Prakash², Sabeeha Nousheen²

¹Professor & Head, Department of Ophthalmology, Dr. B.R. Ambedkar Medical College and Hospital, Bengaluru, Karnataka, India, ²Post-graduate Student, Department of Ophthalmology, Dr. B.R. Ambedkar Medical College and Hospital, Bengaluru, Karnataka, India

Abstract

Background: Ocular trauma is a major cause of visual morbidity. The visual impairment caused due to blunt ocular trauma has been neglected in developing countries.

Purpose: To study the prevalence of visual impairment in victims of blunt ocular trauma presenting to a tertiary hospital.

Materials and Methods: A prospective study was done. The study included 100 patients. Demographic data, detailed history, clinical data, best-corrected visual acuity of all patients were noted at presentation. Patients treated medically and depending on their condition, surgical intervention done as required. Follow-up was done after 1-week, 1-month, 6-months, and 1-year of presentation.

Results: The mean age group of patients was 25 years. When adjusted for sex, males were more affected, that is, of the 100 patients, 83 were male, 27 were female. 23 patients had visual impairment at presentation. Impairment in vision resulted from corneal edema/partial corneal tears (3%), iridocyclitis (4%), cataract (9%), subluxated lens with vitreous herniation (2%), hyphema with vitreous hemorrhage and retinal detachment (2%), commotio retinae/retinal hemorrhages (2%), optic neuritis (1%). 13 patients (who had curable blindness, with vision <6/60) were surgically treated, and vision restored. On 1-year follow-up, two patients had a visual impairment, their vision being 6/9 and 6/12.

Conclusion: Prevalence of visual impairment in our study was 2%, thus requiring its prevention and early management to be a public health priority.

Key words: Morbidity, Trauma, Visual impairment

INTRODUCTION

Ocular trauma, once described as the “neglected disorder,” has recently been highlighted as a major cause of visual morbidity.¹ Annually, over 2.5 million Americans suffer an eye injury, and globally more than half a million blinding injuries occur every year.² The prevalence of ocular trauma in India was reported as 2.4%.³ Worldwide, there are approximately 1.6 million people blind from eye injuries, 2.3 million bilaterally visually impaired, and 19 million with unilateral visual loss.⁴

Ocular trauma is a major cause of preventable monocular blindness and visual impairment in the world.⁵ 40,000-60,000 of eye injuries lead to visual loss.⁶ Despite its public health importance, there is relatively less population-based data on the magnitude and risk factors for ocular trauma, especially from developing countries.⁷

Purpose

To study the prevalence of visual impairment in victims of blunt ocular trauma presenting to a tertiary hospital.

MATERIALS AND METHODS

A prospective, observational study was done on 100 patients with blunt ocular trauma.

The study duration spanned over a period of 2 years from August 2012 to June 2014.

Access this article online



www.ijss-sn.com

Month of Submission : 05-2015
Month of Peer Review : 06-2015
Month of Acceptance : 07-2015
Month of Publishing : 07-2015

Corresponding Author: Dr. Aysha Nazlin, No. 95, 1st Stage, 1st Block, HBR Layout, Bengaluru - 560 043, Karnataka, India.
 Phone: +91-9632603965. E-mail: nazlin_787@yahoo.co.in

Inclusion Criteria

- Patients presenting to ophthalmology outpatient departments of Dr. B. R. Ambedkar Medical College, Bengaluru, India, with history and signs of blunt ocular trauma
- Patients who were willing to give consent.

Exclusion Criteria

- Patient in whom assessment is difficult due to severe head injury with reduced level of consciousness and cooperation
- History of any past ocular pathology, which impairs best-corrected visual acuity (BCVA).

Demographic data, detailed history, clinical data were recorded. Detailed ocular examination which included visual acuity (both distant and near), retinoscopy, anterior segment evaluation with diffuse light, slit-lamp examination, intraocular pressure (IOP) with GAT, gonioscopy with Goldmann three mirror gonioscope, posterior segment evaluation using +90D lens, +78D lens and indirect ophthalmoscope with +20D lens, visual fields by Humphrey Field Analyzer, B-scan, X-ray orbit, computerized tomography/magnetic resonance imaging was done.

BCVA of all patients was noted at presentation and during follow-up. Follow-up was done after 1-week, 1-month, 6 months, 1-year of presentation.

RESULTS

Age

Mean age group of patients in our study was 25 years. There were 8 patients in the age group of 1-10 years, 16 patients in the age group of 11-21 years, 57 patients in the age group of 21-30 of years, 18 patients in the age group of 31-40 years, and 1 patient in the age group of 41-50 years. In our study, young adults were more prone to blunt ocular trauma.

Sex Distribution

Of the 100 patients, 83 were male and 17 were female.

Demography

Study included 22 patients from the rural sector and 78 patients from the urban sector.

Cause of Blunt Trauma

The cause of blunt trauma in our study was road traffic accident as seen in 22 patients, history of fall in 19 patients, history of assault in 32 patients, injury with blunt objects in 21 patients, and miscellaneous causes in 6 patients.

Visual Impairment

Of the 100 patients, 23 had a visual impairment. The best corrected visual acuity of these patients on presentation was as follows:

Best Corrected Visual Acuity on Presentation

In our study, there was 1 patient with visual acuity ranging from 6/12 to 6/18, 5 patients with visual acuity ranging from 6/24 to 6/36, and 16 patients with visual acuity ranging from 6/60 to <6/60.

Cause of Visual Impairment

Cause of visual impairment in our study was noted to be due to corneal edema as seen in 2 patients, partial corneal tear in 1 patient, traumatic iridocyclitis in 4 patients, traumatic cataract in 9 patients, subluxated lens in 2 patients, vitreous hemorrhage with retinal detachment in 2 patients, and traumatic optic neuritis in 1 patient (Figures 1-4).

Of this, 13 were surgically treated and improvement in vision was noted.

On Follow-up

Best corrected visual acuity after 1-week showed 2 patients with visual acuity between 6/6 and 6/9, 11 patients with visual acuity between 6/12 and 6/18, 4 patients with visual acuity between 6/24 and 6/36, 5 patients with visual acuity between 6/60 and <6/60.

Best corrected visual acuity after 6 months and 1-year showed 21 patients with visual acuity of 6/6, 1 patient with visual acuity of 6/9, and 1 patient with visual acuity of 6/12. Thus showing visual impairment in 2 patients at 1-year follow-up (Table 1).

DISCUSSION

Pathogenesis of Blunt Trauma

Blunt trauma to the globe results in anteroposterior compression with simultaneous expansion in the equatorial plane associated with a transient but severe increase in IOP. The impact is primarily absorbed by the lens iris diaphragm and the vitreous base.

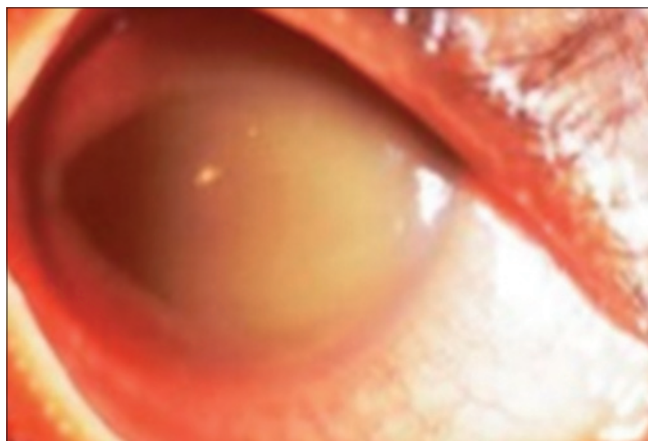
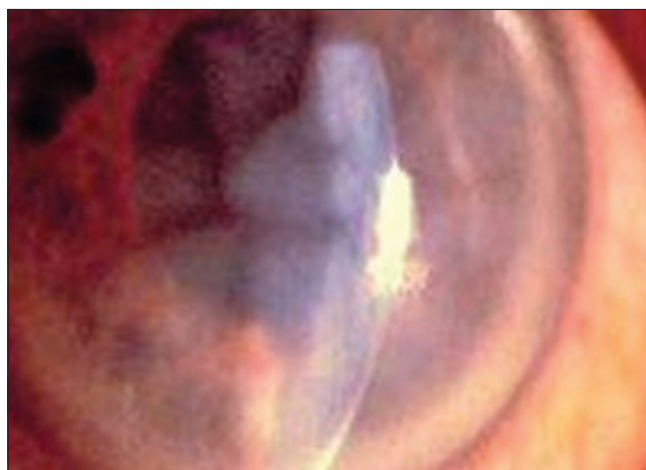
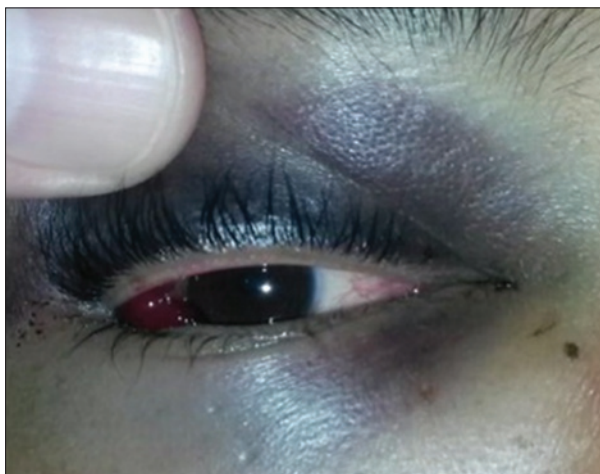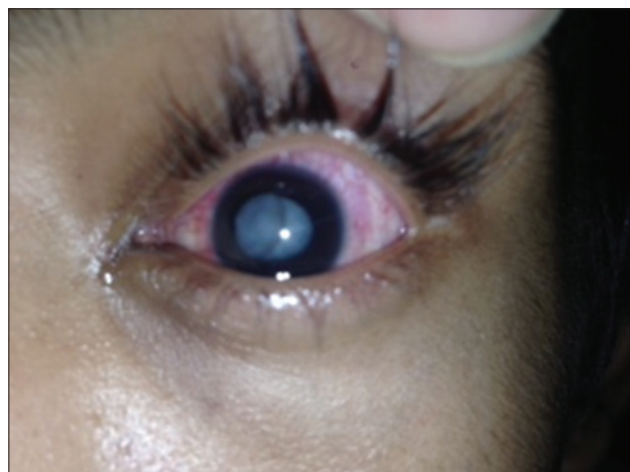Mechanics of Blunt Trauma to Eyeball

1. Direct impact on the globe: It produces maximum damage at the point where the blow is received. It can be due to:
 - a. Compression wave force: It is transmitted through the fluid contents in all the directions. Maximum damage is produced at a point distant from the place of impact. This is called contrecoup damage
 - b. Reflected compression wave force: After striking

Table 1: BCVA on presentation to the 1-year follow-up

Best corrected visual acuity	Number of patients on presentation	Number of patients after 1-week	Number of patients after 1-month	Number of patients after 6 months	Number of patients on 1-year follow-up
6/6-6/9	0	2	17	21	21
6/12-6/18	1	11	1	1	1
6/24-6/36	5	4	1	0	0
6/60-<6/60	16	5	3	0	0

BCVA: Best corrected visual acuity

**Figure 1: Total hyphema****Figure 3: Corneal edema****Figure 2: Periorbital ecchymosis with subconjunctival hemorrhage****Figure 4: Traumatic cataract**

the outer coats of the eyeball, the compression waves are reflected toward the posterior pole and may cause foveal damage

- c. Rebound compression wave force: After striking the posterior wall of the globe, the compression waves rebound back anteriorly. This force damages the retina and choroid by forward pull and lens-iris diaphragm by forward thrust from the back.
2. Indirect force: Indirect forces act on the eyeball from the bony walls and elastic contents of the orbit when globe suddenly strikes against these structures.

Our study showed men and young adults to be more prone to blunt ocular trauma. This result was consistent with previous study done by Vats *et al.*⁸

Our study also showed a higher incidence in the urban population as compared to a rural one. In the study by Dandona *et al.*⁹ and Nirmalan *et al.*,¹⁰ it showed that a rural population (4.5%) may have a higher prevalence as compared to an urban one (3.97%).^{9,10} Since our study was done in urban Bengaluru, our results can thus be substantiated.

The prevalence of visual impairment in our study was 2%. The study done by Glynn *et al.* reports cumulative prevalence of visual impairment (VA <20/40) due to ocular trauma is 8.5 per 1000 persons.⁷

Limitations in our study being loss of one patient on follow-up and its small sample size.

CONCLUSION

Prevalence of visual impairment in our study is 2%. Ocular trauma has to be considered as a public health priority in developing countries like India as most of the patients affected belong to the economically productive age group. As blunt ocular trauma is a major cause of preventable visual impairment, “prevention is better than cure” aptly applies here. Prevention can be done by public awareness and education on the use of helmets while riding, use of protective glasses. Patients presenting with blunt trauma should be promptly and efficiently treated. Reducing the magnitude of visual impairment due to blunt trauma is the responsibility of both the patient and the ophthalmologist.

REFERENCES

1. Parver LM. Eye trauma. The neglected disorder. Arch Ophthalmol 1986;104:1452-3.
2. Négrel AD, Thylefors B. The global impact of eye injuries. Ophthalmic Epidemiol 1998;5:143-69.
3. Katz J, Tielsch JM. Lifetime prevalence of ocular injuries from the Baltimore eye survey. Arch Ophthalmol 1993;111:1564-8.
4. Schein OD, Hibberd PL, Shingleton BJ, Kunzweiler T, Frambach DA, Seddon JM, *et al.* The spectrum and burden of ocular injury. Ophthalmology 1988;95:300-5.
5. McCarty CA, Fu CL, Taylor HR. Epidemiology of ocular trauma in Australia. Ophthalmology 1999;106:1847-52.
6. Wong TY, Klein BE, Klein R. The prevalence and 5-year incidence of ocular trauma. The beaver dam eye study. Ophthalmology 2000;107:2196-202.
7. Glynn RJ, Seddon JM, Berlin BM. The incidence of eye injuries in New England adults. Arch Ophthalmol 1988;106:785-9.
8. Vats S, Murthy GV, Chandra M, Gupta SK, Vashist P, Gogoi M. Epidemiological study of ocular trauma in an urban slum population in Delhi, India. Indian J Ophthalmol 2008;56:313-6.
9. Dandona L, Dandona R, Srinivas M, John RK, McCarty CA, Rao GN. Ocular trauma in an urban population in southern India: The Andhra Pradesh eye disease study. Clin Experiment Ophthalmol 2000;28:350-6.
10. Nirmalan PK, Katz J, Tielsch JM, Robin AL, Thulasiraj RD, Krishnadas R, *et al.* Ocular trauma in a rural south Indian population: The Aravind comprehensive eye survey. Ophthalmology 2004;111:1778-81.

How to cite this article: Sujatha MA, Nazlin A, Prakash S, Nousheen S. Prevalence of Visual Impairment after Blunt Ocular Trauma in a Tertiary Hospital. Int J Sci Stud 2015;3(4):36-39.

Source of Support: Nil, **Conflict of Interest:** None declared.