

Assessment of Regenerate in Limbs by Ilizarov External Fixation

T Suresh Kumar¹, Swagat Mahapatra²

¹Assistant Professor, Department of Orthopaedics, Vinayaka Missions Kirupananda Variyar Medical College and Hospital, Salem, Tamil Nadu, India, ²Assistant Professor, Department of Orthopaedics, Mahatma Gandhi Medical College and Research Institute, Puducherry, India

Abstract

Introduction: Limb lengthening procedures are performed to correct significant length discrepancies, in the upper or lower extremities, that have resulted from various congenital or acquired abnormalities. The issue of limb lengthening was introduced in orthopedic surgery in the year 1950 and has been practiced up to the present time. This study comprises an analysis of bone regeneration, especially the response of bone, periosteum and endosteum to distraction limb lengthening.

Materials and Methods: This study involves all patients in a tertiary care teaching hospital from January 2010 to July 2015, where bone regenerate has been produced by Ilizarov methods. 131 regenerates have been analyzed. Ilizarov external fixator was applied, and corticotomy was done. Distraction was started at a rate of 1 mm/day after the latent period (7-10 days). X-rays were taken at intervals of 1 month. Occasionally, ultrasonography was used to assess the early regenerate.

Results: There were 105 normotrophic regenerate, 14 hypertrophic regenerate, and 14 hypotrophic regenerate. The lengthening achieved ranged between 3 cm and 23 cm. The average increase in length was 6.4 cm. The incidence of major complications, in our study, was 30.1 %, and overall complication was 60%.

Conclusion: Ilizarov external fixator is used in limb lengthening, deformity correction, and segmental long bone defect reconstruction. In our study, we achieved good to excellent results in 90% of our cases which is at par with many other studies. We achieved 10.7% excellent, 81.7% good, and 7.6% poor results. We had good to excellent or better results in the upper tibial metaphyseal area compared to any other area.

Key words: Corticotomy, Ilizarov, Limb lengthening, Regenerate

INTRODUCTION

Professor Gavriil Abramovich Ilizarov of U.S.S.R known as the “magician” of Kurgan invented the ring external fixator now known as Ilizarov external fixator. With this, he was also the pioneer in the most stunning discovery in orthopedics. The biological production of new tissues was termed as neo-osteogenesis or osteoneogenesis.¹ When it encompassed all tissues, which were generated during limb lengthening, were coined as histoneogenesis or neo-histogenesis. Limb lengthening procedures are performed to correct significant length discrepancies, in the upper

or lower extremities, that have resulted from various congenital or acquired abnormalities. The issue of limb lengthening was introduced in orthopedic surgery in the year 1950 and has been practiced up to the present time. Although clinical studies have proved the effectiveness of different methods of limb lengthening, there is still need for further research to study regeneration of the bone tissue. This study comprises an analysis of bone regeneration, especially the response of bone, periosteum and endosteum to distraction using ring fixators. Clinical studies include radiological and functional outcome, long-term results, and patient satisfaction after limb reconstruction.

MATERIALS AND METHODS

This was a prospective interventional study conducted in a high volume tertiary care teaching hospital in Southern India for almost 5 years from January 2010 to July 2015. This study involved all patients who fulfilled the inclusion criteria. The patients undergoing limb lengthening or

Access this article online



www.ijss-sn.com

Month of Submission : 05-2016
Month of Peer Review : 06-2016
Month of Acceptance : 07-2016
Month of Publishing : 07-2016

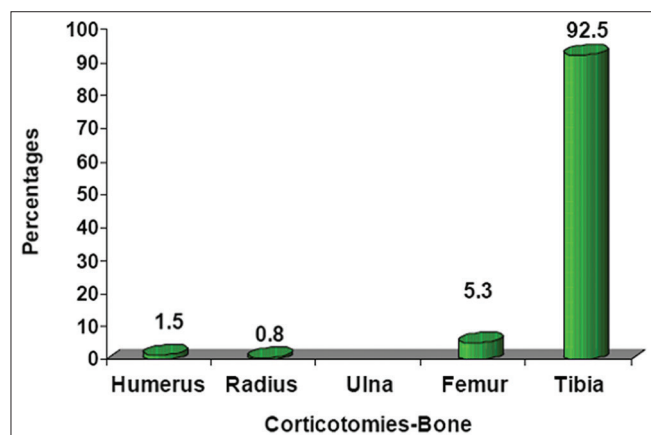
Corresponding Author: Dr. T Suresh Kumar, No-64, S N D Road, Tiruchengodu, Dt - Namakkal - 637 211, Tamil Nadu, India.
E-mail: drsuresh79@yahoo.co.in

bone transport using Ilizarov external fixation following congenital, post-traumatic, post-polio residual paralysis, infected nonunion of long bones, and tumors were included. Patients lost to follow-up, and limbs which were amputated before regenerate was consolidated were excluded from the study. The objectives of this study were to investigate bone regeneration after corticotomy and distraction lengthening, to assess treatment of posttraumatic shortening of limbs using the Ilizarov distraction device and to evaluate the results of limb lengthening. In our study, there was a total of 133 corticotomies in 113 patients. Two patients were lost to follow-up. Hence, 131 regenerates were finally analyzed. Ilizarov external fixator was applied, and corticotomy was done. Distraction was started at a rate of 1 mm/day after the latent period (7-10 days). X-rays were taken at intervals of 1 month. Occasionally, ultrasound was used to assess the early regenerate before it was visible on X-rays. Depending on the quality of regenerate in the X-rays and or ultrasound, if the quality of regenerate was poor, the distraction was either stopped and delayed or slowed down and distraction did at a rate of 0.5 mm/day. In some patients, compression was done to reduce the gap and distracted again (accordion technique). Bone marrow infiltration was done in 12 patients, where we saw either

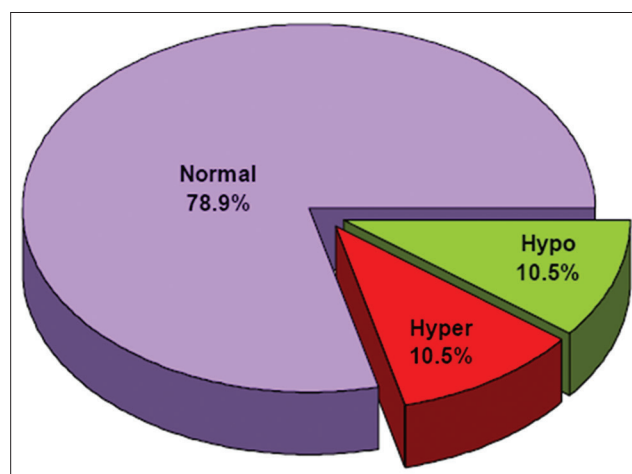
poor regenerate or delayed consolidation. Results of regenerate were evaluated on the basis of four parameters, both clinically and radiologically. The parameters included consolidation of regenerate, absence of deformity, absence of limb length discrepancy, and absence of infection. The score was excellent - all four parameters; good - 3 parameters; poor - 2 or less.

OBSERVATIONS AND RESULTS

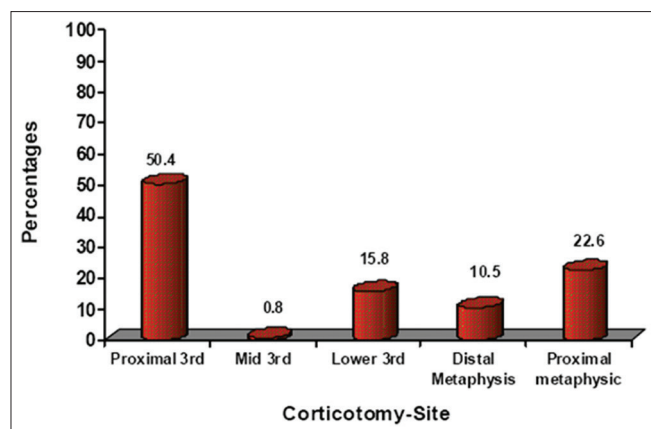
A total of 131 regenerates in 113 patients were analyzed. 83 (73.5%) were males and 30 were females, and the maximum number of patients (38) were in the age group of 21-30 years. Maximum affected and operated bone was the tibia, which was 92.5% of cases in our series (Graph 1). Anatomical site of corticotomy was proximal metaphysis in a maximum number of cases (Graph 2, Graph 5). A type of regenerate was normotrophic in 78.9% cases, hypertrophic in 10.5% cases, and hypotrophic in 10.5% cases (Graph 3). The residual shortening was maximum in post polio residual paralysis cases followed by acute fractures (Graph 4). The lengthening achieved ranged between 3 cm and 23 cm. The average increase in length



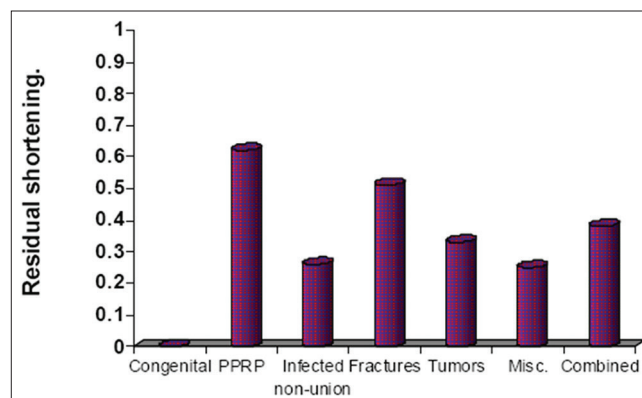
Graph 1: Bones involved in Ilizarov fixation



Graph 3: Type of regenerate



Graph 2: Site of corticotomy



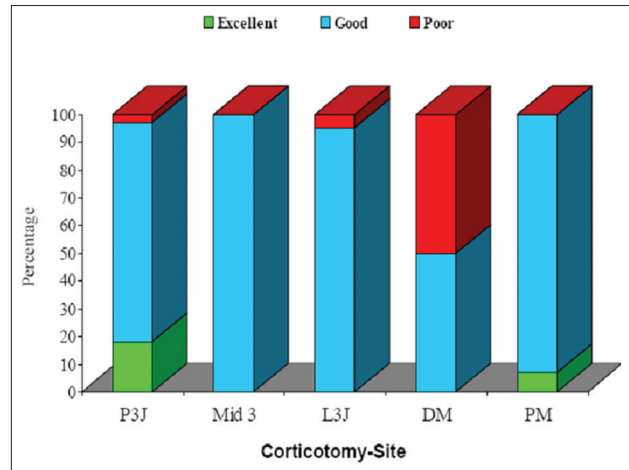
Graph 4: Residual shortening according to diagnosis

was 6.4 cm. Good to excellent results were achieved in 90% of cases (Graph 6). The incidence of minor complications in our study was 29%, and overall complication was 60%. The most common complication encountered was pin tract infection followed by deformity of the regenerate (Graph 7).

DISCUSSION

Ilizarov external fixator results in rapid advances in limb lengthening, deformity correction, and segmental long bone defect reconstruction.²⁻⁴ The mechanical features of and biologic response to using distraction osteogenesis with the circular external fixator are the unique aspects of Ilizarov's contribution. Alan found in his study that the average increase in length was 5.9 cm and the rate for the lengthening phase was 12 days for one centimeter with the Ilizarov technique.⁵ Paley found in his study that the average increase in length was 5.6 cm. In our study, the

average increase in length was 6.4 cm and the lengthening phase was 10 days for one centimeter.⁶ Aronson found that



Graph 5: Assessment of outcome of regenerate according to corticotomy site

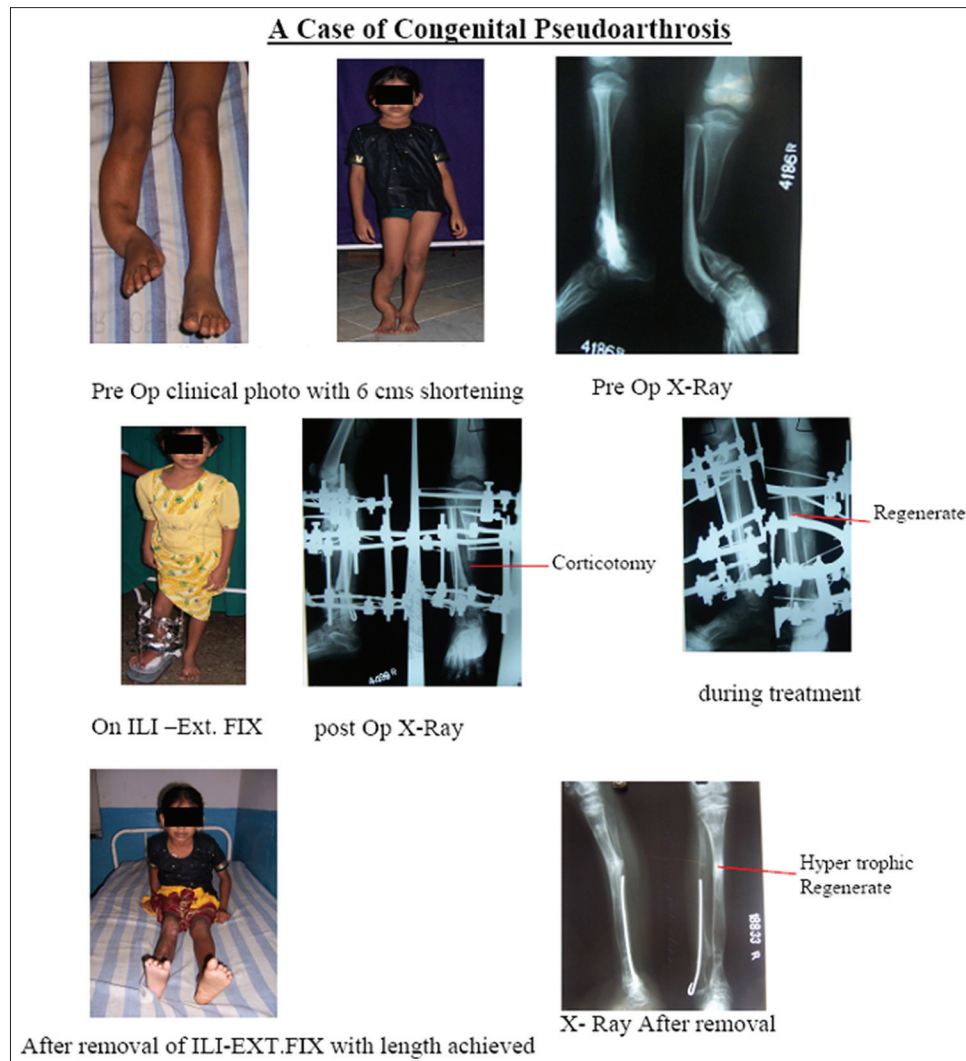


Figure 1: Case of Congenital pseudoarthrosis of Tibia managed with Ilizarov

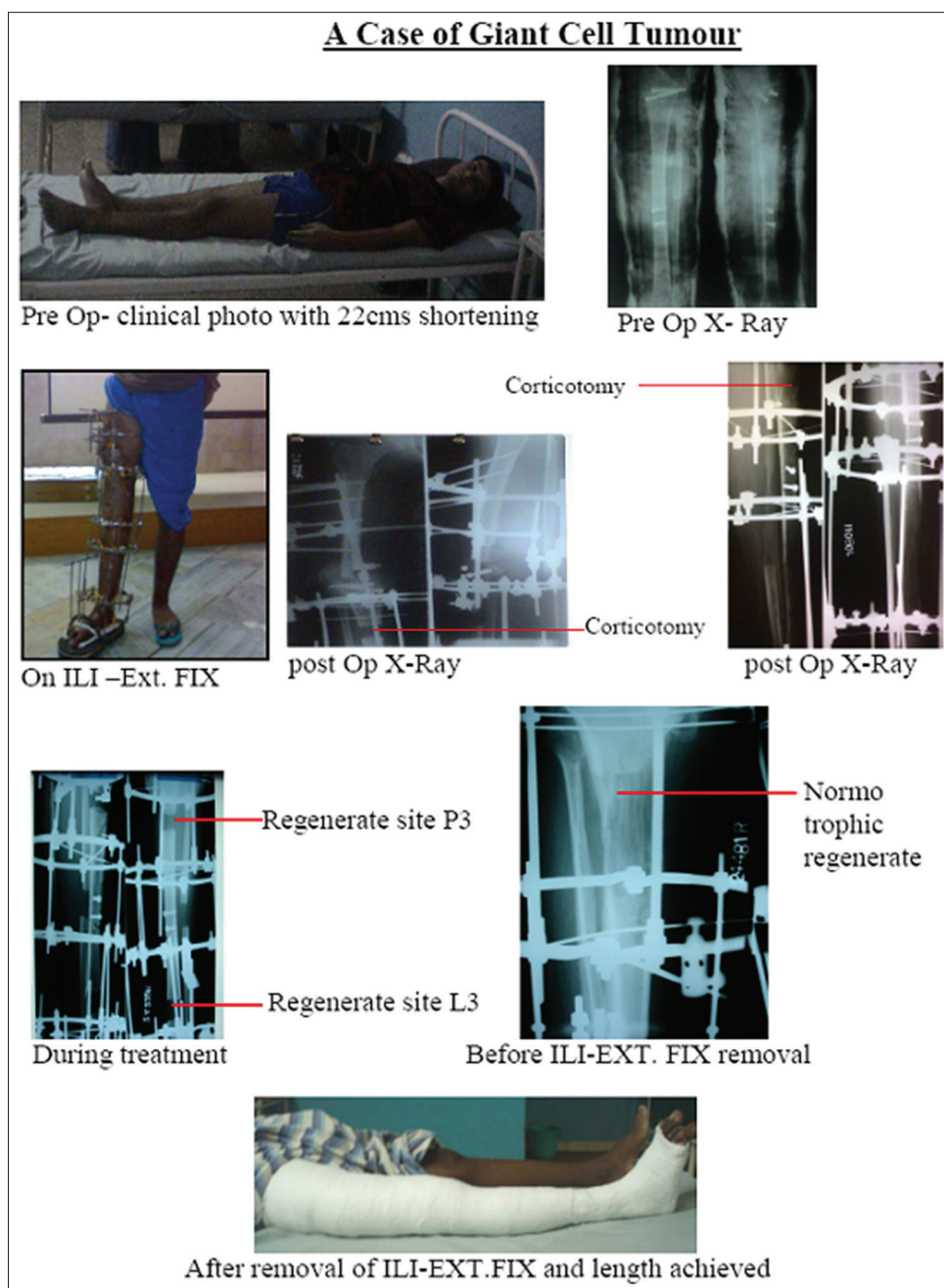


Figure 2: Case of Giant cell tumor, post excision with shortening managed with Ilizarov

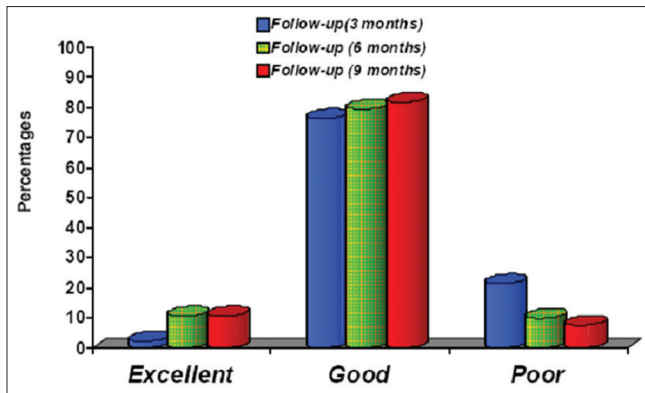
new bone formation was better and faster in metaphyseal than in diaphyseal bone.⁷ In our study, we had good to excellent results in the upper tibial metaphyseal area. Poor or hypotrophic regenerates seen in corticotomies performed in cortical bones and in post-polio residual paralysis patients whose bone diameter was less and were treated with the accordion technique of compression and distraction.

Paley found the incidence of minor complications in his study was 10.6%, major complications was 20.6% and altogether was 31.2%.⁶ In our study, minor complications were 29% and major complications were 30.1% and

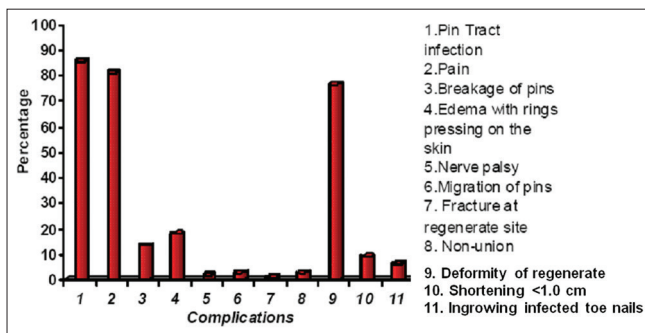
altogether was 60.3%. Yun found good to excellent results in 78% of the cases in his study.⁸ In our study, we achieved good to excellent results in 90% of our cases which is at par with many other studies.

CONCLUSION

Ilizarov external fixator is used in limb lengthening, deformity correction, and segmental long bone defect reconstruction. In all metaphyseal corticotomies rate of distraction was 1 mm/day (0.25 mm four times a day),



Graph 6: Final outcome of regenerate in long bones treated by Ilizarov external fixation



Graph 7: Complications

which has been found good enough for a good regenerate to be obtained. In all other corticotomies of cortical bone,

the initial rate of distraction from 1 mm/day had to be reduced if necessary as per X-ray findings. In radius, ulna, post-polio residual paralysis of femur and tibia which are thin, and corticotomies in the shaft of such bones, the distraction rates were reduced to 0.5 mm/day. In our study, we achieved good to excellent results in 90% of our cases which is at par with many other studies. We achieved 10.7% excellent, 81.7% good and 7.6% poor results. We had good to excellent or better results in the upper tibial metaphyseal area compared to any other area.

REFERENCES

1. Ilizarov GA. The tension - Stress effect on the genesis and growth of tissues. Transosseous osteosynthesis. Clin Orthop Relat Res 1992;1:137-291.
2. Catagni MA, Lovisetti L, Guerreschi F, Combi A, Ottaviani G. Cosmetic bilateral leg lengthening: Experience of 54 cases. J Bone Joint Surg Br 2005;87:1402-5.
3. Wagner H. Operative technique in traumatic limb lengthening. Der Chir 1971;42:260-6.
4. Shevtsov VI, Makushin VD, Kuftryrev LM. Defects of the lower limb bones. Radiographical Dynamics in Formation of Regenerate Bones during Tibial-Fibular Synostosis. Db Misc, 2000. p. 483-7.
5. Codivilla A. On the means of lengthening, in the lower limbs, the muscles, and tissues which are shortened through deformity. Am J Orthop Surg 1905;2:353-69.
6. Paley D. Problems, obstacles, and complications of limb lengthening by the Ilizarov technique. Clin Orthop Relat Res 1990;250:81-104.
7. Aronson J. Limb-lengthening, skeletal reconstruction, and bone transport with the Ilizarov method. J Bone Joint Surg Am 1997;79:1243-58.
8. Yun AG, Severino R, Reinker K. Attempted limb lengthenings beyond twenty percent of the initial bone length: Results and complications. J Pediatr Orthop 2000;20:151-9.

How to cite this article: Kumar TS, Mahapatra S. Assessment of Regenerate in Limbs by Ilizarov External Fixation. Int J Sci Stud 2016;4(4):97-101.

Source of Support: Nil, **Conflict of Interest:** None declared.