Print ISSN: 2321-6379
Online ISSN: 2321-595X
DOI: 10.17354/ijss/2016/414

Original Article

Functional Outcome of Patients Underwent Lumbar Microdiscetomy

Toms Jacob[1], U Sudheer[2], C Jayaprakash[3]

[1]Post-graduate Trainee, Department of Orthopedics, Amala Institute of Medical Science, Thrissur, Kerala, India, [2]Associate Professor, Department of Orthopedics, Amala Institute of Medical Science, Thrissur Kerala, India, [3]Head, Department of Orthopedics, Amala Institute of Medical Science, Thrissur, Kerala, India

Abstract

Introduction: Inter vertebral disc prolapse (IVDP) is a very common cause for low back ache in younger population. When conservative treatment fails or when patient develops complications like neurological deficit, then the treatment is surgical discectomy. Open laminectomy and discectomy has a lot of morbidity when compared to micro discectomy which is the treatment of choice for such patients. In this study, we analyze the advantages and functional outcome of patients underwent micro lumbar discectomy.

Materials and Methods: This is an institution-based prospective study. We performed a prospective study of 15 microscopic discectomy in 15 patients who were non-responsive to conservative management. Their pre- and post-operative symptoms like pain and functional disabilities were evaluated over a period of 2-year using direct questionnaire method.

Results: About 95% of patients reported excellent pain relief on 1 year follow-up. Neurological recovery was 80% on 2 years follow-up. 2 patients had dural tear during the procedure which was treated by suturing with 5'0 prolene.

Conclusion: It is recommended that this procedure as the gold standard surgical method for the patients with IVDP who were failed with conservative treatment method.

Key words: Patients, Lumbar, Microdiscetomy

INTRODUCTION

The life time prevalence of lumbar disc herniation is approximately 2%. The natural history of sciatica secondary to lumbar disc herniation is spontaneous improvement in the majority of cases. Among patients with radiculopathy secondary to lumbar disc herniation, approximately 10-25% experience persistent symptoms. Pain typically begins in the lumbar area and radiates to sacroiliac and buttocks region. Radicular pain extends below the knee in the region of involved nerve root. Radicular pain may be accompanied by paresthesia and weakness in the distribution of involved nerve root.[1]

Access this article online

IJSS
www.ijss-sn.com

Month of Submission : 05-2016
Month of Peer Review : 06-2016
Month of Acceptance : 07-2016
Month of Publishing : 07-2016

The supine straight leg raise test (Laseugues test) and its variants (sitting straight leg raise test, bowstring test, contra lateral straight leg raise test) increase tension in sciatic nerve and are used to assess L5 and S1 nerve roots. The femoral nerve stretch test (reverse straight leg raise test) increases tension along femoral nerve and is used to assess the L2, L3, and L4 nerve roots.

Plain radiographs are not helpful in initial evaluation of suspected lumbar disc herniations. Although radiograph may show degenerative changes (disc space narrowing and osteophyte formation), there is poor correlation between these findings and clinical symptoms because these findings are also present in asymptomatic patients. Magnetic resonance imaging (MRI) is the preferred imaging test because it provides greatest amount of information about the lumbar region. About 90% of lumbar disc herniation occurs at L4 L5 and L5 S1 level. L3 L4 level is the next common level for symptomatic lumbar disc herniation.[2]

Disc herniation is described based on the circumference of the annulus fibrosus as central, posterolateral, foraminal,

Corresponding Author: Dr. U Sudheer, Associate Professor, Department of Orthopedics, Amala Institute of Medical Science, Thrissur Kerala, India. E-mail: sudheeranortho@gmail.com

or extra foraminal. A posterolateral L4 L5 disc herniation compresses L5 nerve root. An L4 L5 foraminal or extra foraminal disc herniation compresses L4 nerve root. A central disc herniation compresses one or more of the caudal nerve roots.

Appropriate criteria for surgical intervention are follows:
1. Functionally incapacitating leg pain extending below the knee within a nerve root distribution
2. Nerve root tension signs with or without neurologic deficit
3. Failure to improve with 4-8 weeks of nonsurgical treatment
4. Confirmatory imaging study which correlates with patients' physical findings and pain distribution.

Open lumbar discectomy using microsurgical techniques remains the gold standard for the treatment of symptomatic lumbar disc herniation. Although a variety of alternative procedures have been proposed, no procedure has demonstrated superior surgical outcome compared with microsurgical approach.[3]

Complications of microscopic lumbar discectomy include:
1. Vascular injury
2. Nerve root injury
3. Dural tear
4. Infection
5. Increased back pain
6. Recurrent disc herniation
7. Cauda equina syndrome
8. Medical complications such as thrombophlebitis, urinary tract infection, etc.

The most common cause of surgical failure following lumbar discectomy is poor patient selection and wrong level of surgery. The incidence of recurrent disc herniation following non-surgical lumbar discectomy is 5-10%. If symptoms are predominantly radicular repeat lumbar discectomy may be beneficial. If symptoms include a combination of radicular pain and low back pain, discectomy combined with fusion may be considered in select patients.[4]

MATERIALS AND METHODS

Analysis of functional outcome of patients with herniated lumbar disc who have undergone microdiscectomy at Amala Institute of Medical Science, Thrissur over a period of 2-year. We performed a prospective study of 15 microscopic discectomy in 15 patients who were non responsive to conservative management. Pre- and post-operative neurological status, pain, functional disability were evaluated. Other studied variables were mean age sex ratio, level of prolapse, mean hospital stay, and time to return to work.

All patients with sciatica caused by herniated lumbar discs who did not respond to conservative treatment were enrolled in the study to undergo microdiscectomy between 2011 and 2013. The inclusion criteria were the presence of a herniated lumbar disc observed on MRI scans and the persistence of sciatica after 4-8 weeks of conservative treatment with rest, analgesia, nonsteroidal anti-inflammatory drugs, and physical therapy. The exclusion criteria were as follows age older than 60 years, previous surgery, associated lumbar spine stenosis, foraminal, or extraforaminal disc herniations. Only those patients with a final post-operative follow-up period of at least 2-year were included in this study. After the inclusion criteria were met and an informed consent was obtained, the patients were included in the study. The surgical procedures were performed under general anesthesia with the patient in the prone position with hip flexed to 90°. Prophylaxis with the first-generation cephalosporin was introduced 1 h before anesthesia and kept for 8 h after the procedure.

Procedure: Patient in a prone position with hip flexed to 90° (Figures 1 and 2).

Level identification done under C-arm control which is the most crucial step.

Count the level from below upward as open spaces as seen in MRI.

For example if it is second open space from below upward in MRI, under C-arm guidance in lateral view identify the second open space. 1 inch (2.5 cm) incision made between adjacent spinous process from spinous process above to spinous process below slightly to the side depending on the predominant symptomatic side. Deep fascia and muscles retracted to either side. Self-retaining retractors applied. Base of the spinous process identified. Through the gap between the spinous process and lamina ligamentum flavum excised and reached the lateral side of spinal cord. Search for root extension from the cord. Cord is then retracted medially to see the disc underneath. Excision of the disc was done. Hemostasis attained and wound closed in layers.

Post-operative lumbar corset given. The 3rd day wound inspection done and the patient is discharged. Reviewed after 10 days for suture removal. Reviewed after 6 weeks for reassessment. On follow-up, pain is assessed using

Figure 1: Patient in a prone position with hip flexed to 90°

Figure 2: Pre-operative image - Patient in a prone position with hip flexed to 90°

questionnaire method. Neurological status is assessed by clinical examination.

The surgical variables analyzed were the level and side of the herniated disc, side of root compression, pre- and post-operative neurological deficit, and post-operative pain relief. Pre- and post-operative evaluation consisted of a neurological examination, and questionnaire method for assessment of pain. The surgical wound pain was assessed 12 h after surgery using the questionnaire method. Clinical neurological status was evaluated using the Lasegue test, motor assessment by muscle strength, and testing of the sensory system (Figures 3 and 4).

Functional outcome was evaluated using the questionnaire method. The patients were reevaluated 1 week, 6 weeks, 6 months, 12 months, and 24 months after surgery. The time required for patients to return to work was also registered.

Results

Mean age: 591/155 = 39.4

Sex: M/F - 3:2

Level: L4 L5 level: 9 (60%)

L5 S1 level: 6 (40%)

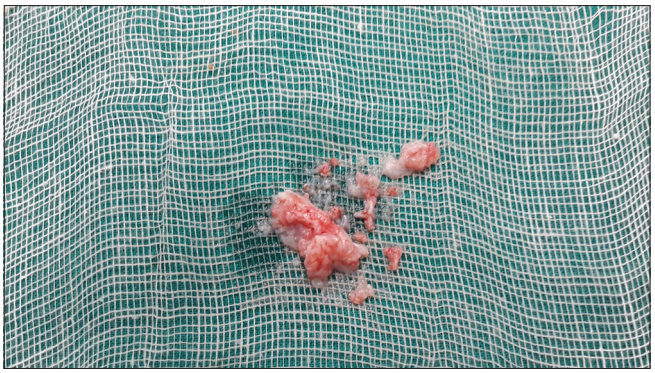

Figure 3: Excised part

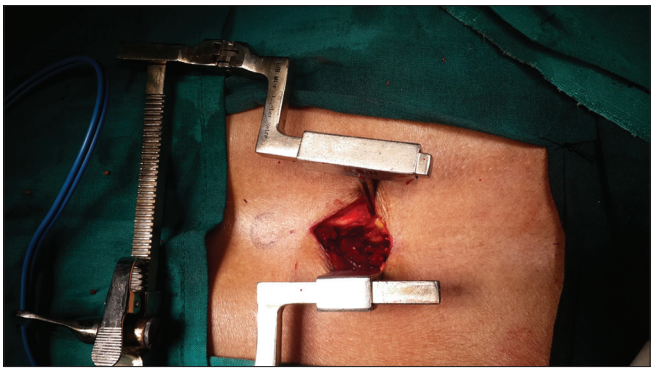

Figure 4: Post-operative

Pain relief:

Pain relief is assessed by questionnaire method.

Pain relief	1 week	6 week	6 months	1 year
Excellent	10	12	13	14
Good	4	2	1	0
Fair	0	1	1	1
Poor	1	0	0	0

Neurological status:

Motor deficit:

- Pre-operative: 10 (66.67%)
- 1 week post-operative: 8 (53.3%)
- 6 week post-operative: 5 (33.3%)
- 6 months post-operative: 4 (26.6%)
- 12 months post-operative: 4 (26.6%)
- 24 months post-operative: 3 (20%).

Sensory deficit:

- Pre-operative: 9 (60%)
- 1 week post-operative: 6 (40%)
- 6 week post-operative: 6 (40%)
- 6 months post-operative: 5 (33.3%)
- 12 months post-operative: 3 (20%)
- 24 months post-operative: 3 (20%).

RESULTS

A total of 15 patients were enrolled in the study. The mean post-operative follow-up period was 24 months. There were 9 men and 6 women with a mean age of 39.4. The vertebral level affected was L4 L5 in 9 patients, L5S1 in 6 patients. All patients is presented with pre-operative neurological impairment; 100% had a positive Lasegue sign (15 out of 15), 66.67% had motor deficits (10 out of 15), and 60% had sensory deficits (9 out of 15). After 6 months of follow-up, 26.6% had motor deficit and 33.3% had sensory deficit. After 12 months, these percentages changed to 26.67% and 20%, respectively, and after 24 months, they changed to 20% and 20%, respectively. Two patients had dural tear which was managed conservatively.

All 15 patients have full recovery from pain within 6 weeks and were able to resume their normal work.

DISCUSSION

Microscopic discectomy helps in faster post-operative mobilization, faster recovery, and resumption of work at the earliest. The development in recent years has made the treatment of herniated discs safer and less invasive. By using microscopic discectomy approaches through small incisions, nerve root decompression is achieved with minimal risk of complication and preserving normal anatomy. The superiority of microdiscectomy over traditional discectomy has been widely proven. The most important step in microdiscectomy is correct level identification and adequate decompression.

CONCLUSION

It is recommended that this procedure as the gold standard surgical method for patients with Inter vertebral disc prolapse who were failed with conservative treatment method.

REFERENCES

1. Righesso O, Falavigna A, Avanzi O. Comparison of open discectomy with microendoscopic discectomyin lumbar disc herniations: Results of a randomized controlled trial. Neurosurgery 2007;61:545-9.
2. Wong DA, Transfeldt E. Macnab' Backache. Lippincott: Williams and Wilkins; 2007.
3. Devlin VJ. Spine Secrets. Philadelphia, PA: Harley and Belfin, Elsevier; 2003.
4. Yorimitsu E, Chiba K, Toyama Y, Hirabayashi K. Long-term outcomes of standard discectomy for lumbar disc herniation: A follow-up study of more than 10 years. Spine 2001;26:652-7.

How to cite this article: Jacob T, Sudheer U, Jayaprakash C. Functional Outcome of Patients Underwent Lumbar Microdiscetomy. Int J Sci Stud 2016;4(4):242-245.

Source of Support: Nil, **Conflict of Interest:** None declared.