

Septic Arthritis Due to *Rhodococcus Equi* in an Immunocompetent Patient

Mannur Sharada¹,
Kotehal Mahesh²,
Naik Neelesh³,
B V Renushree⁴,
Shabong Rose⁵,
E R Nagaraj⁶

¹Associate Professor, Department of Microbiology, Sri Siddhartha Medical College, Tumkur, Karnataka, India, ²Professor, Department of Orthopaedics, Sri Siddhartha Medical College, Tumkur, Karnataka, India, ³Assistant Professor, Department of Microbiology, Sri Siddhartha Medical College, Tumkur, Karnataka, India, ⁴Associate Professor, Department of Microbiology, Sri Siddhartha Medical College, Tumkur, Karnataka, India, ⁵Postgraduate, Second Year, Department of Microbiology, Sri Siddhartha Medical College, Tumkur, Karnataka, India, ⁶Professor and H.O.D, Department of Microbiology, Sri Siddhartha Medical College, Tumkur, Karnataka, India

Corresponding Author: Dr. Neelesh Naik, Assistant Professor, Department of Microbiology, Sri Siddhartha Medical College, Agalakote, Tumkur, Karnataka, India - 572107.
E-mail: drneelnk@gmail.com

Abstract

Rhodococcus equi is an uncommon opportunistic pathogen in humans causing infection in immunocompromised patients. Infection in immunocompetent patients is extremely rare. We report a case of *Rhodococcus equi* causing septic arthritis in immunocompetent patient. The organism was identified based on the typical salmon coloured colonies on blood agar and biochemical reactions. It was sensitive to amikacin, ofloxacin, levofloxacin, vancomycin, cotrimoxazole and piperacillin-tazobactam and was resistant to ampicillin, ampicillin-sulbactam, amoxicillin-clavulanic acid and gentamicin. The patient responded to treatment with amikacin and rifampicin. It is important to be aware of this organism causing disease in immunocompetent patients and hence has to be differentiated from diphtheroids, so as to start early treatment of the patient.

Keywords: Immunocompetent patient, *Rhodococcus equi*, Septic arthritis

INTRODUCTION

Rhodococcus equi is a facultative, intracellular, non motile, non spore-forming, gram positive coccobacillus belonging to the family Nocardiaciae. The bacterium is called *Rhodococcus equi* (previously called *Corynebacterium equi*) because of its ability to form a red (salmon coloured) pigment.^{1,2} It was previously thought to be exclusively an equine pathogen, but in recent years *Rhodococcus equi* infection is occurring with increasing frequency in humans.² Although most infections have occurred in immunocompromised patients, especially those with AIDS, the organism has been isolated in immunocompetent persons as well.^{1,3} Human infections are predominantly airborne, but can also occur by oral ingestion or wound contamination.⁴ Most patients infected with this bacteria present with a pulmonary syndrome. Other infections include gastrointestinal infections, pericarditis, meningitis, mastoiditis, and abscesses in the liver, kidney, psoas muscles and cutaneous wounds.⁵

CASE REPORT

A 35 year old female patient was admitted to the orthopaedic ward of our hospital with history of pain and swelling in the left knee joint since 2 years. She was treated intermittently by a general physician with pain killers which subsidized the pain but the swelling was not relieved by medication. She gave history of road traffic accident with injury to the left knee 3 years back. On admission to our hospital she was carefully evaluated and initially suspected to be having osteomyelitis and was started on painkillers. She was moderately built, well oriented and conscious. Her vital signs were pulse rate: 86 bpm, BP: 120/90 mm of Hg, Respiratory rate: 17/min. she was not a known diabetic or hypertensive patient. She was a nonsmoker and a nonalcoholic. Her blood investigations were done. Hb 13.1 gm/dl, platelet count 4.11 lakhs/mm³, total leucocyte count 12500 mm³, neutrophils 75%, lymphocytes 18%, monocytes 04%, eosinophils 03%, ESR 60 mm/hr, RBS 75 mg/dl, blood urea 26.8 mg/dl, S. creatinine 1.0 mg/dl.

peripheral smear showed normocytic normochromic blood picture with neutrophilic leukocytosis. Screening tests for HIV, HBsAg and HCV were negative. Chest X ray was normal. Two days later when the swelling did not reduce synovial fluid was aspirated and sent to the microbiology laboratory. Gram stain of the fluid showed plenty of neutrophils and few gram positive coccobacilli. The fluid was cultured on Sheep blood agar and Macconkey agar and incubated aerobically at 37°C. After 48 hours of incubation smooth colonies 1-2 mm in diameter were seen on blood agar. No growth was seen on Macconkey agar. Gram stain of the colony showed gram positive coccobacilli with filamentous and branching forms (Figure 1). Weakly acid fast organisms were seen on modified acid fast stain with 1% sulphuric acid as decolouriser (Figure 2). The organism was identified as *Rhodococcus equi* based on the typical salmon coloured smooth colonies on blood agar seen after 4 days of incubation and biochemical reactions. The organism was nonmotile, catalase positive, oxidase negative, urease positive, indole negative, carbohydrate nonfermented. The organism was positive for CAMP test and grew minimally on tap water agar. Colonies

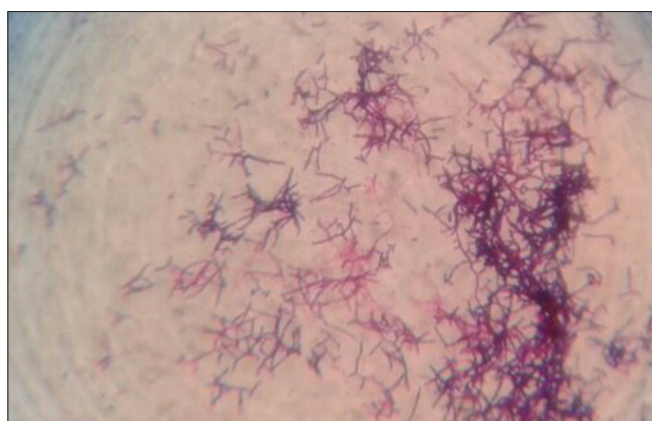

Figure 1: Gram stain of the culture smear showing gram positive coccobacilli with filamentous and branching forms

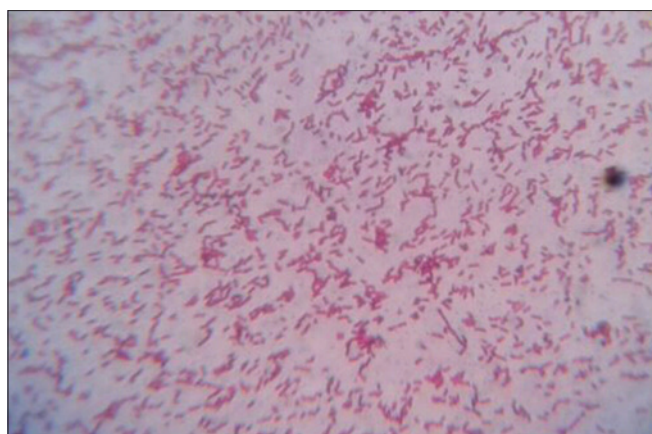


Figure 2: Modified acid fast stain of the culture smear showing acid fast organisms

from blood agar were subcultured on Lowenstein Jensen medium and Sabourads Dextrose agar and gram stain of the culture showed gram positive coccobacilli. Antibiotic susceptibility test was performed on Sheep blood agar and the organism was found to be sensitive to amikacin, ofloxacin, levofloxacin, vancomycin, cotrimoxazole and piperacillin-tazobactam and was resistant to ampicillin, ampicillin-sulbactam, amoxicillin-clavulanic acid and gentamicin. The patient responded to treatment with amikacin and rifampicin for one week.

DISCUSSION

Rhodococcus equi was first isolated in 1928 from the lungs of foals in Sweden.⁶ The first human case was reported in 1967. Since then, human cases have been described in immunocompromised patients. With the exception of Antarctica, it has been identified in soils all over the world, in fresh and sea water and in animals including horses, cattle and wild birds.⁷ The clinical manifestations, course and response to therapy differ significantly between immunocompromised and immunocompetent patients. Immunocompromised patients usually present with necrotizing pneumonia with or without sepsis, have a high mortality rate and require prolonged treatment with multiple antibiotics. In contrast, immunocompetent patients, most of them children, present with extrapulmonary lesions like abscesses, osteomyelitis, septic arthritis, etc., have a low mortality rate and respond to a shorter course of antibiotics, usually with a single agent.⁸ It is important for early identification of *Rhodococcus equi* in order to initiate a proper therapy which reduces the duration of illness. However, aetiological diagnosis can be difficult because of its similarity to non pathogenic commensals. *Rhodococcus* species should be considered when the distinctive pigmentation of colonies and pleomorphic Gram stain morphology are encountered.¹ Microscopically the organisms are gram positive filaments that fragment into cocci and bacilli. *Rhodococcus equi* is catalase and urease-positive, and oxidase-negative. It can be differentiated from other aerobic actinomycetes and other pathogenic corynebacteria by their partial acid fastness arising from the mycolic acid in their cell wall and lack of ability to ferment carbohydrates.^{1,5} *Rhodococcus* can be differentiated from *Nocardia* by growing the organism on tap water agar. *Rhodococcus* grows minimally (if at all), and *Nocardia* grows freely.¹

CONCLUSION

Rhodococcus equi is an uncommon opportunistic pathogen in humans causing infection in immunocompromised patients but in rare instances it has caused Infection in immunocompetent patients. *Rhodococcus equi* is usually

mistaken for diphtheroids and hence it is important for the microbiologists to be aware of this organism causing disease in immunocompetent patients, which will help in early diagnosis and treatment of patients.

ACKNOWLEDGMENT

We are thankful to Dr. Shivaprasad, honourable chancellor of our institution for his constant support to carry out this work.

REFERENCES

1. Conlin PA, Willingham KJ, Oliver JW. Rhodococcus bacteremia in an immunocompetent patient. *Laboratory medicine*. 2000;31(5):263-5.
2. Buckley T, McManamon E, Stanbridge S. Resistance studies of erythromycin and rifampin for Rhodococcus equi over a 10-year period. *Ir Vet J*. 2007;60(12):728-31.
3. Ulivieri S, Oliveri G. Cerebellar abscess due to Rhodococcus equi in an immunocompetent patient: Case report and literature review. *J Neurosurg Sci*. 2006;50(4):127-9.
4. Borghi E, Francesca ML, Gazzola L, Marchetti G, Zonato S, Foa P, et al. Rhodococcus equi infection in a patient with spinocellular carcinoma of unknown origin. *J Medical Microbiol*. 2008;57(11):1431-3.
5. Chen X, Feng XU, Jing-yan XIA, Cheng Y, Yang Y. Bacteremia due to Rhodococcus equi: a case report and review of the literature. *J Zhejiang Univ Sci B*. 2009;10(12):933-6.
6. Devi P, Malhotra S, Chadha A. Bacteremia due to Rhodococcus equi in an immunocompetent infant. *Indian J Med Microbiol*. 2011;29(1):65-8.
7. Guerrero R, Bhargva A, Nahleh Z. Rhodococcus equi venous catheter infection: a case report and review of the literature. *J Med Case Reports*. 2011;5(1):358-74.
8. Sistla S, Karthikeyan S, Biswas R, Parija SC, Patro DK. Acute osteomyelitis caused by Rhodococcus equi in an immunocompetent child. *Indian J Pathol Microbiol*. 2009;52(2):263-4.

How to cite this article: Sharada M, Mahesh K, Neelesh N, Renushree BV, Rose S, Nagaraj RE. Septic Arthritis Due to Rhodococcus Equi in an Immunocompetent Patient. *Int J Sci Stud* 2014;2(4):88-90.

Source of Support: Nil, **Conflict of Interest:** None declared.