Pleomorphic Lipoma with Furuncular Myiasis (Maggots) of Scalp - A Rare Case Report

K R Brahmaiah Chari[1], Lakshmi Rao[2], K L Sindhura Lakshmi[3], Seemitr Verma[4], M Deepak Nayak[5]

[1]Asst. Professor, Department of Pathology, Melaka Manipal Medical College (Manipal Campus), Manipal University, [2]Consultant Pathologist, Armed Forces Hospital, Muscat, Oman, [3]Asst. Professor, Department of Pathology, Melaka Manipal Medical College (Manipal Campus), Manipal University, [4]Speciality Medical Officer, Department of Pathology, Melaka Manipal Medical College (Manipal Campus), Manipal University, [5]Asst. Professor, Department of Pathology, Kasturba Manipal Medical College, Manipal University

Corresponding Author: *Dr. Brahmaiah Chari K.R, Asst. Professor, Department of Pathology, Melaka Manipal Medical College (Manipal Campus), Manipal University, E-mail: dr.brahma@yahoo.co.in*

Abstract

Pleomorphic/Spindle cell lipoma is a benign tumour of the adipose tissue, frequently arising from the subcutaneous fat, principally from the back of shoulder, extremities and infrequently from oral cavity retropharyngeal space, thigh and genitals. This tumour is usually well circumscribed, slow growing, unifocal and rarely ulcerates. Unusual sites of occurrence and rarity of the tumour poses problems in diagnosis for the histopathologist. Tumour histology shows mature fat with bland spindled mesenchymal cells traversed by thin ropy collagen. We herein present a case of a large pleomorphic lipoma of scalp with furuncular myiasis in a 58 year-old male who neglected the initial swelling and later consulted the surgeon for an ulcer. Surgeon resected tumour due a suspicion of malignancy. Grossly, the neoplasm measured 10 x 8 cm with an ulcerated surface; with the cut section comprising of a lobulated tumour with grey-white areas. Tumour histology consisted of mature adipocytes intersected by thin ropy collagen scattered with floret giant cells and interestingly, an accidental finding of larva of myasis.

Keywords: Myiasis, Pleomorphic lipoma, Ropy collagen, Spindle cell lipoma

INTRODUCTION

Lipoma is the most common benign tumour of head and neck.[1] Categorization of different types of lipomas is based on the mesenchymal components present in it. Oneof them being pleomorphic lipoma. It was first described by Enzinger in 1975.[1] They are rare, benign, pseudosarcomatous soft tissue tumours typically involving subcutaneous tissue of head and neck with a male preponderance.[2] Apart from afore-mentioned sites, they can involve the tongue, palm, vulva and oral cavity.[3,4] However, it is still debated to report this particular tumour as pleomorphic lipoma or atypical lipomatous tumour since these tumours rarely exceed >10 cms size. Histologically, this tumour shows mature adipocytes intersected by collagen typically known as 'ropy' collagen, intermingled with benign bland looking spindle cells and floret giant cells (multi-nucleation giving an appearance of flower petals).[5] These adipocytes are positive for CD34. A recent study showed these tumours have a characteristic partial loss of chromosome 13.[6] The literature hitherto describes less than 150 reported cases; none with an accidental finding of myiasis larva (maggots) in the tumour to the best of our knowledge.

CASE REPORT

A 58-year male, a farmer by occupation presented with a progressively increasing swelling in scalp since 2 years. Initially, he neglected the lesion until he noticed ulceration. No cervical lymphnodes were palpable. The rest of the systemic examinations and haematological investigations were normal. The surgeon resected tumour with wide margins since a suspicion of malignancy was speculated. Specimen was fixed in 10% buffered formalin and sent to histopathological examination.

Gross details

An exophytic nodular mass measured 10 × 8 × 4 cm with a central ulcer and peripheral epithelialization (Figure 1). The cut section showed lobulations with intervening yellow and white areas (Figure 2).

Figure 1: An exophytic tumour with external ulceration measuring 10 x 8 cms

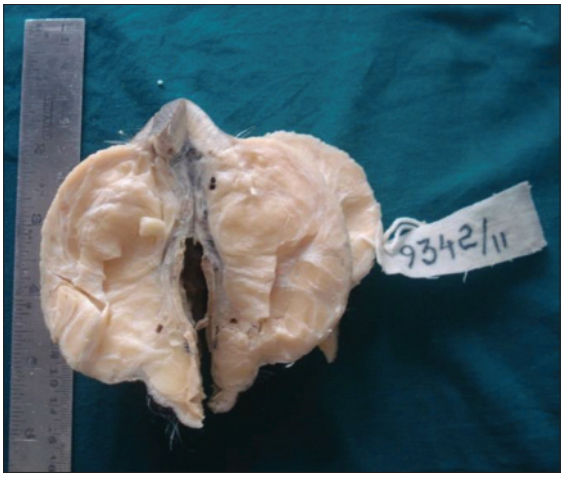

Figure 2: Cut section of tumour show lobulations with grey-white and yellow areas

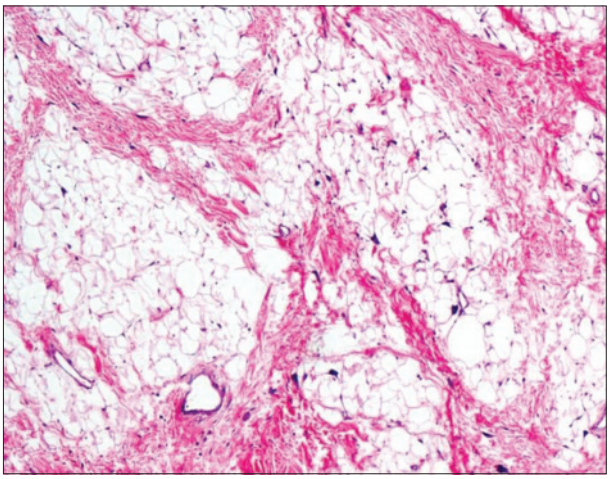

Figure 3: Tumour show adipocytes with thin bands of ropy collagen; (Hematoxylin and Eosin, 100x)

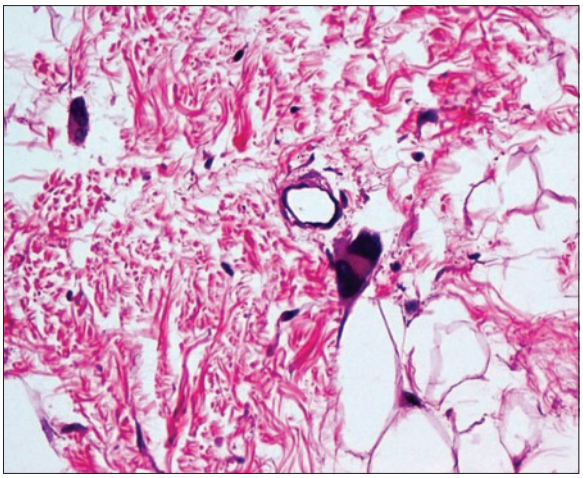

Figure 4: Pleomorphic spindle cells with smudged nuclei. (Hematoxylin and Eosin, 200x)

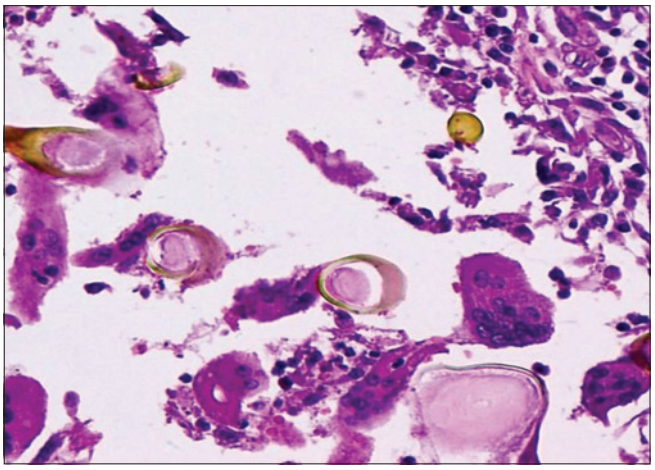

Figure 5: Floret-type giant cells and hair follicles. (Hematoxylin and Eosin, 400x)

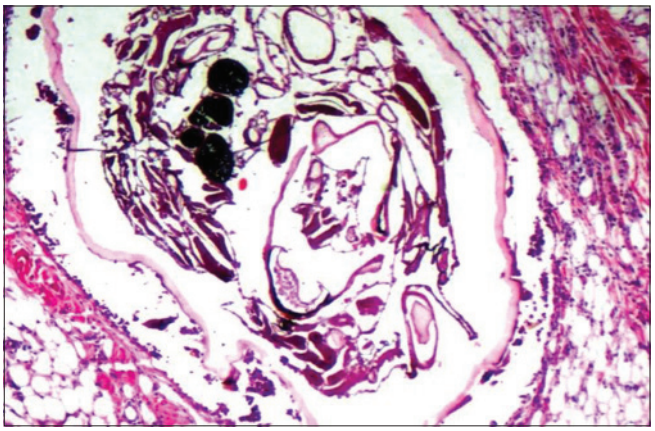

Figure 6: Myiasis larva with chitinous wall. (Hematoxylin and Eosin, 100x)

Microscopic Details

A circumscribed tumour composed of mature adipocytes intersected by ropy collagen, interspersed bland spindled mesenchymal cells along with floret- type of giant cells with accidental finding of larva of myiasis (maggots).

Table 1: The differential diagnostic lesions and their characteristics for pleomorphic lipoma[1,8]

Feature	Pleomorphic lipoma	Atypical lipoma	Well differentiated liposarcoma	Myxoid malignant fibrous histiocytoma
1.Cinical	Male Head and neck	Any site	Retroperitoneum, Extremities	Late adult life Extremities
2.Histology	Adipocytic tumor with floret- giant cells	Predominantly fibrous septae, separating adipocytes	Lipoblasts (++)	Storiform pattern of pleomorphic myofibroblasts
3.Immunohistochemistry	CD34+, S100±	CD34 -	MDM2+, CDK4 +	-

DISCUSSION

Pleomorphic lipomas are pseudosarcomatous lesions with less than 150 cases reported in literaturefrom various sites; includingthe shoulder, back, vulva, genitals, oral cavity and retropharyngeal space.[2-4] Pleomorphic lipoma and spindle cell lipoma share a common clinical, histological, immunohistochemistry and genetic characters. Differential diagnosis of this tumour includes a well-differentiated liposarcoma, atypical lipomatous tumour and a myxoid malignant fibrous histiocytoma. This poses diagnostic challenges since they are extremely difficult to distinguish grossly and have overlapping features,microscopically. Hence, immunohistochemistry is required to confirm the above with the help of CD34. Fine needle –aspiration has been diagnostic in superficial palpable lesions of the head and neck region. However, this lesion may masquerade as a malignancy on aspiration cytology.[7] The table below shows differentiating features (Table 1).

Larvae of maggots are frequently found in tropical countries like India, especially in a long- standing ulcer. Paradoxically, they are also called natural healers because enzymes secreted by digestive tract of maggots digest the unhealthy slough, thus promoting the generation of healthy granulation tissue and fastening the healing of wound.[8,9]

CONCLUSION

Pleomorphic lipomas are rare benign pseudosarcomatous lesions; commonly occurring in the subcutis region in the head and neck, that can resemble malignant sarcomas.However, with good clinical correlation, histopathological characteristics along with the help of immunohistochemistry, a definite diagnosis is possible. This serves to avoid unnecessary work-up and devastating, disfiguring surgery. Further large group studies are required to know the origin of the neoplastic cells and biological behavior of this tumour.

REFERENCES

1. Enzinger FM and Weiss SW Soft Tissue Tumors: Benign Lipomatous Tumors; 5th ed. St.Louis: Mosby, p444-56:2001.
2. Kransdorf M. Benign soft-tissue tumors in a large referral population: distribution of specific diagnoses by age, sex, and location. American journal of roentgenology 1995;164(2): 395-402.
3. Hayashi T, Tsuda N, Shimada O, Maeda H. A pleomorphic lipoma of thepalm–comparison to spindle cell lipoma. Gan No Rinsho. Japan journal of cancer clinics 1989;35(3):437-441.
4. Singh N, Dabral C, Singh PA, Singh M, Gupta SC, Jain S. Pleomorphic lipoma of the tonsillar fossa–a case report. Indian J Pathol Microbiol 2003;46(3):476-477.
5. Shmookler BM, Enzinger FM. Pleomorphic lipoma: a benign tumorsimulating liposarcoma. A clinicopathologic analysis of 48 cases. Cancer 1981;47(1):126-133.
6. Miettinen M. Modern Soft Tissue Pathology: Tumors and Non-Neoplastic Conditions. New York, NY: Cambridge University Press; 2010.
7. Rigby HS, Wilson YG, Cawthorn SJ, Ibrahim NB. Fine needle aspiration of pleomorphic lipoma: a potential pitfall of cytodiagnosis. Cytopathology 1993;4(1):55-58.
8. Austin CD, Tiessen JR, Gopalan A, Williams Jr. JM, Bangs CD, Cherry AM et al. Spindle-cell lipoma of the foot and the application of CD34 immunohistochemistry to atypical lipomatous tumors in unusual locations. Appl Immunohistochem & Molecular Morphol 2000;8(3):222-227.
9. Mumcuoglu KY. Clinical applications for maggots in wound care. Am J Clin Dermatol. 2001;2(4):219-27. Review. PubMed PMID: 11705249.

How to cite this article: Chari KRB, Rao L, Lakshmi KLS, Verma S, Nayak DM. Int J Sci Stud 2014;2(4):108-110.

Source of Support: Nil, **Conflict of Interest:** None declared.