

Study of Intraurethral Instillation of Tacrolimus for Urethral Involvement Following Lichen Sclerosus

Ranjan K Dey¹, Imran Khan², Dawood Khan²

¹Associate Professor, Department of Urology, R. G. Kar Medical College and Hospital, Kolkata, West Bengal, India, ²Post Doctoral Student, Department of Urology, R. G. Kar Medical College and Hospital, Kolkata, West Bengal, India

Abstract

Introduction: Lichen sclerosus (LS) is a lymphocyte-mediated inflammatory process that in men affects the genital skin and also the urethra, causing urethral stricture. Formerly known as balanitis xerotica obliterans, LS is the most common cause of long panurethral stricture in males. Medical management of LS in the form of topical steroids, immunomodulators like tacrolimus, and systemic retinoid acitretin have been described for diseases involving the prepuce and glans. Urethral involvement usually requires surgical intervention. This study was done to assess the efficacy of intraurethral instillation of tacrolimus as a nonsurgical modality.

Materials and Methods: Type of study: This is a prospective nonrandomized observational study. The study included 20 men with histology proven genital LS with variable length of anterior urethral involvement proximal to fossa navicularis. Pretreatment uroflowmetry and ultrasonography were done for flow and post-void residual urine status. All the patients underwent suprapubic cystostomy before therapy, for longer intraurethral dwell time of tacrolimus. Patients also underwent meatotomy for associated meatal stenosis. 1 g of 0.03% tacrolimus was instilled intraurethrally twice a day for 6 weeks. Reassessment was done at 6 weeks and 12 weeks.

Results: A total of 15 patients (75%) responded favorably to the treatment with significant improvement at 6 weeks sustained at 3 months. Four patients did not respond to the treatment. One patient showed objective and subjective improvement but found the process cumbersome and opted for Urethroplasty. The most common patient's complaint was of urethral discomfort and perineal heaviness for the initial few days, which subsided on its own.

Discussion: Intraurethral instillation of tacrolimus provides a minimally invasive tool for management of one of the difficult urethral strictures to treat. The treatment modality fulfills the three basic goals of urethral stricture management - unobstructed voiding, painless intercourse, and good cosmesis.

Key words: Intraurethral instillation, Lichen sclerosus, Tacrolimus

INTRODUCTION

Lichen sclerosus (LS) is an inflammatory disease that can affect both men and women and shows a predilection for the anogenital region. It is a lymphocyte-mediated process that in men affects the genital skin and also the urethra, causing urethral stricture. Formerly known as balanitis

xerotica obliterans (BXO), LS was first described in the late 19th century and the male form specifically by Stuhmer in 1928.¹ The term BXO had been used interchangeably with LS; however, LS is currently used exclusively since the formal adoption of the term by the international society for the study of vulvar disease.² LS is the most common cause of long panurethral stricture in males.^{3,4}

The exact etiology of LS is yet to be established, with multiple theories regarding infection, trauma, genetic, and autoimmune disorders. Of these, autoimmune etiology is the most prevalent theory.⁵⁻⁷ Multiple infectious agents have been investigated for a link to LS including borrelia burgdorferi⁸ and human papilloma virus;⁹⁻¹¹ however, there is no conclusive evidence which can show a causative relationship.

Access this article online



www.ijss-sn.com

Month of Submission : 05-2017

Month of Peer Review : 06-2017

Month of Acceptance : 07-2017

Month of Publishing : 07-2017

Corresponding Author: Dr. Imran Khan, Room No. 8, MEB Hostel, R. G. Kar Medical College Campus, Kolkata - 700 004, West Bengal, India. Phone: +91-9825530062. E-mail: imrankhan.doc@gmail.com

BXO is a rare disease that affects only 6 of 1000 males (0.06%).¹² The condition can affect male of any age, but condition rises steadily through the 3rd decade with maximum incidence in the 6th decade of life.¹³ LS is most commonly found in the genital region with a 5:1 ratio of genital compared with extragenital involvement.^{14,15} LS almost always involve the foreskin/glans and in severe cases involve the meatus and urethra up to variable length.

Medical management of LS in the form of topical steroids, immunomodulators like tacrolimus, and systemic retinoid acitretin has been described. However, these have been restricted for diseases involving the prepuce and glans. Disease involving the urethra usually requires some form of surgical intervention, with a variable rate of recurrences depending on the surgical procedure and the type of tissue used for substitution.

We performed this study to assess the efficacy of intraurethral instillation of tacrolimus as a nonsurgical modality of treatment for anterior urethral stricture due to LS extending proximal to the fossa navicularis up to variable length.

MATERIALS AND METHODS

Type of Study

This was a prospective, nonrandomized study.

Inclusion Criteria

The study included 20 men with histology proven genital LS with variable length of anterior urethral involvement proximal to fossa navicularis.

Exclusion Criteria

Patients with upper tract changes and altered renal function (serum creatinine > 1.5) were excluded from the study.

A detailed history and clinical examination was done. Blood investigations for renal function (serum creatinine), complete blood count, glycated hemoglobin (HbA1C), and liver function test were done. Patients had uroflowmetry on two consecutive days and higher of the two values for Q_{max} was taken. In the same way, ultrasonography was done on two separate occasions, 24 h apart; lower of the two residual urine value was taken. Retrograde urethrogram (RGU) was done to assess the involvement of the urethra, and whenever possible, the patients underwent ureteroscopy with a 6Fr ureteroscope to confirm the findings of the RGU, look for the proximal extent of the disease and baseline documentation of the condition of the urethra before starting the therapy.

Any urinary tract infection if present was treated. All the patients underwent suprapubic cystostomy (SPC) before therapy, which allowed for longer intraurethral dwell time of tacrolimus and rest to the urethra. Patients also underwent meatotomy for associated meatal stenosis. 1 g of 0.03% tacrolimus was instilled intraurethrally twice a day for 6 weeks.

At 6 weeks, SPC was clamped and patients were asked to void per urethra. Patients were assessed for subjective and objective (in the form of Q_{max} and post-void residual [PVRV]) improvement of voiding. Repeat RGU were done at 6 weeks. Blood investigations were done at 6 weeks to look for any systemic effects of tacrolimus.

If the patient showed subjective and objective improvement at 6 weeks, the frequency of intraurethral instillation was reduced to once in the night time. Patients continued to void per urethra and were assessed again at 3 months, and if there was persistent improvement, SPC was removed.

RESULTS

Majority of our patients were in the 4th and 5th decade of life with the youngest being 28 years and the oldest being 65 years of age. All the patients were histologically proven LS cases having significant obstructive lower urinary tract symptoms. A total of 15 patients (75%) had pan anterior urethral stricture, whereas rest 5 (25%) had involvement up to variable length into the penile urethra.

A total of 15 patients (75%) responded favorably to the treatment (Figure 1). There was significant improvement at 6 weeks in PVRV (mean of differences 126.3, 95% confidence interval [CI]=100.4-152.2, $P < 0.05$) and Q_{max} (mean of differences 6.440, 95% CI=5.126-7.754, $P < 0.05$)

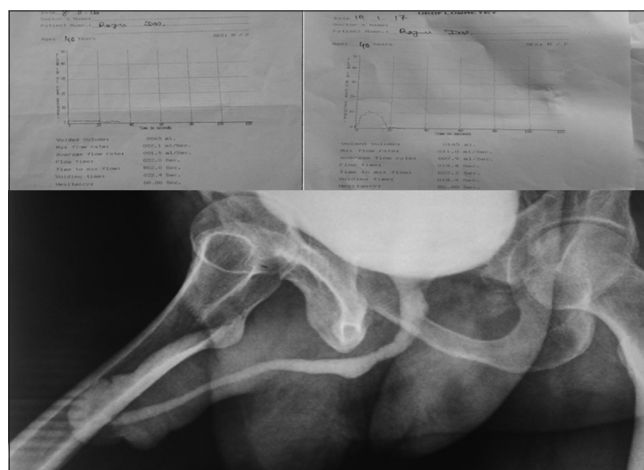


Figure 1: Improvement following intraurethral instillation of tacrolimus at 3 months

and the changes in Q_{max} were sustained at 3 months. None of the patients showed deterioration of the renal function or upper tract changes at 3 months. One of the patients who were an amputee showed excellent results at the end of 6 weeks, with a Q_{max} of 36.4 ml/s (Figure 2).

Four patients did not respond to the treatment at the end of 6 weeks of therapy, including two patients having diabetes mellitus (Figure 3). One patient had recurrent attacks of urinary tract infection and was taken up for urethroplasty. Total five breaks through urinary tract infections which were there over the course of study and controlled with oral antibiotics. One patient showed objective and subjective improvement but found the process twice daily intraurethral instillation cumbersome and opted for urethroplasty. A motivated patient and involvement of the spouse can come a long way in improving compliance of patients.

The Most common patient's complaint was of urethral discomfort and perineal heaviness for the initial few days, which subsided on its own. None of the patients had any adverse changes in blood count, HbA1C (even patients with diabetes mellitus), liver function test which might rule out systemic absorption of tacrolimus when instilled intraurethrally.

All of the patients were sexually active and satisfied during the study period. None of the female partners complained of vaginal irritation or discomfort after intercourse.

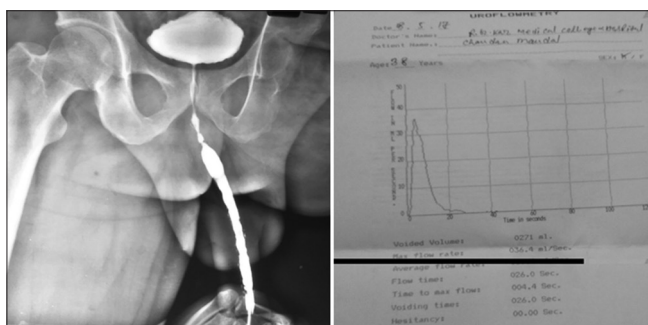


Figure 2: Improvement in an amputee patient at 6 weeks following intraurethral tacrolimus instillation

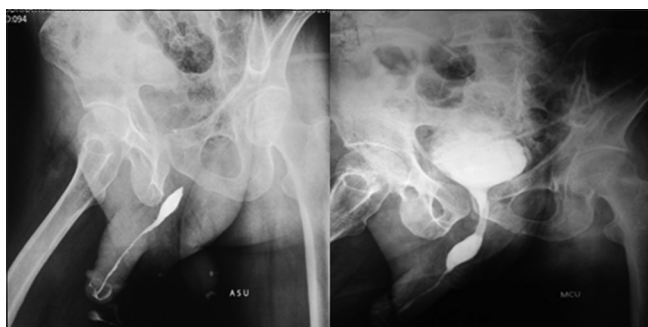


Figure 3: Failure of response at 6 weeks in a diabetic patient

DISCUSSION

Genital LS is a chronic, debilitating, and inflammatory condition that impairs urinary flow, affects sexual function and in turn affecting the psychosocial status of patient. It can affect any age group but is more prevalent in the third to fifth decade of life.

The clinical presentation and severity of genital LS can vary markedly. The onset may be insidious, pursuing a chronic course over many years with few early symptoms, or it may behave aggressively with florid disease evident within weeks of onset. Urethral involvement starts at the meatus and in long-standing disease mucosal involvement, and spongiofibrosis can spread proximally in a confluent manner as far back as the prostate. However, it has not been found in bladder mucosa. The proximal extent is usually well demarcated when in the penile urethra, although with more extensive bulbar extension of the disease, the mucosal changes may fade indistinctly, and sometimes, there are minor mucosal “skip” lesions beyond the apparent posterior limit.

Differential diagnosis might include lichen planus, localized scleroderma, leukoplakia, vitiligo, and the cutaneous rash of Lyme disease.

There are three goals for maintenance in male patients with genital LS: Unobstructed voiding, painless intercourse, and adequate cosmesis. If we achieve Goals 1 and 2, most patients rarely wish to move forward with more invasive therapies to achieve Goal number 3.

LS has been managed both medically and surgically. Medical management has been undertaken for mainly for early disease confined to the cutaneous surface. Topical corticosteroids have been the mainstay of medical management of LS. In a double-blind, placebo-controlled study of 40 boys with LS, 41% showed clinical improvement with steroid administration.¹⁶ Steroid preparations used include clobetasol propionate (0.05%), betamethasone (0.05%), mometasone (0.1%), and hydrocortisone (2.5-10%).¹⁷ Potential side effects of corticosteroids include cutaneous atrophy, adrenal suppression, and contact sensitivity.

LS of glans has been successfully treated with the tacrolimus which is a calcineurin inhibitor that blocks the production of interleukin-2 and T-cell activation. There have been encouraging studies with respect to the efficacy of tacrolimus for both primary and maintenance treatment of BXO,¹⁸⁻²⁰ which was the basis of our study.

For urethral involvement of varying degree, usually surgery is preferred, especially long segment urethral stricture.

There is no doubt that surgery provides the best results in management strictures arising out of BXO, but surgery in itself is associated with its own set of complications.

Repeated urethral dilatation is usually associated with very high recurrence rates, and the second and third dilatations for early recurrence (within 3 months) are of very little, if any value.²¹

Recurrences after surgical therapy are not uncommon in BXO, with rates as low as 9-12% with buccal mucosal grafts^{22,23} to as high as 50-100% when local flaps are used.^{24,25} Initial response to intraurethral tacrolimus instillation was quite acceptable (75%) and longer term follow-up is required, especially to assess response on the tacrolimus is stopped.

Urethroplasty is a major surgical undertaking with its own set of complications. Patients may be subjected to staged procedures, especially in BXO associated strictures, where patients land up with a temporary proximal ureterostomy and in some cases permanent ones. Potential buccal harvest site complications include hemorrhage, pain, facial swelling, damage to Stensen's duct, lip paresthesia, and restriction in mouth opening.²⁶

Many a time, age-associated comorbidities and health status become limiting factor for a major surgical undertaking. At times, we come across patients who cannot tolerate even the reasonable mild stressors of a perineal urethrostomy and intraurethral instillation of tacrolimus can be used in these patients.

Urethroplasties are associated with erectile dysfunction in varying proportion, i.e., from 1% to 50%.^{27,28} Apart from erectile dysfunction, surgery for anterior urethral stricture may be associated with change in the erect penile length and chordee of varying degree. Men with longer anterior urethral stricture and in those patients in whom penile skin flaps are used are at greater risk for erectile dysfunction. None of our patients complained of sexual dysfunction post-tacrolimus usage.

The carbon dioxide laser has been used as an alternative to incisional surgery to ablate BXO on the glans^{29,30} and for the dilatation of proximal strictures,^{31,32} with a variable success rate.

Intraurethral instillation of tacrolimus provides a minimally invasive tool for management of one of the difficult urethral strictures to treat. The study is of short duration and underpowered, but the initial results are encouraging with good response. It fulfills the 3 basic goals of urethral stricture management - unobstructed voiding, painless

intercourse, and good cosmesis. Larger studies with intraurethral instillation of tacrolimus and of longer duration, in different group of patients (primary cases, recurrent stricture disease), are required to confirm the initial encouraging results and better define the role of this modality of treatment.

REFERENCES

- Powell JJ, Wojnarowska F. Lichen sclerosis. *Lancet* 1999;353:1777-83.
- Friedrich EG. New nomenclature for vulvar disease. *Obstet Gynecol* 1976;47:122-4.
- Kulkarni SB, Joshi PM, Venkatesan K. Management of panurethral stricture disease in india. *J Urol* 2012;188:824-30.
- Barbagli G, Mirri F, Gallucci M, Sansalone S, Romano G, Lazzeri M, *et al.* Histological evidence of urethral involvement in male patients with genital lichen sclerosis: A preliminary report. *J Urol* 2011;185:2171-6.
- Oyama N, Chan I, Neill SM, Hamada T, South AP, Wessagowit V, *et al.* Autoantibodies to extracellular matrix protein 1 in lichen sclerosis. *Lancet* 2003;362:118-23.
- Sander CS, Ali I, Dean D, Thiele JJ, Wojnarowska F. Oxidative stress is implicated in the pathogenesis of lichen sclerosis. *Br J Dermatol* 2004;151:627-35.
- Regauer S. Immune dysregulation in lichen sclerosis. *Eur J Cell Biol* 2005;84:273-7.
- Edmonds E, Mavin S, Francis N, Ho-Yen D, Bunker C. *Borrelia burgdorferi* is not associated with genital lichen sclerosis in men. *Br J Dermatol* 2009;160:459-60.
- Drut RM, Gómez MA, Drut R, Rua EC, Lojo MM. Human papillomavirus is present in some cases of childhood penile lichen sclerosis: An *in situ* hybridization and SP-PCR study. *Pediatr Dermatol* 1998;15:85-90.
- Beattie PE, Dawe RS, Ferguson J, Ibbotson SH. UVA1 phototherapy for genital lichen sclerosis. *Clin Exp Dermatol* 2006;31:343-7.
- Neill SM, Lessana-Leibowitch M, Pelisse M, Moyal-Barracco M. Lichen sclerosis, invasive squamous cell carcinoma, and human papillomavirus. *Am J Obstet Gynecol* 1990;162:1633-4.
- Meuli M, Briner J, Animann B, Sacher P. Lichen sclerosis et atrophicus causing phimosis in boys: A prospective study with 5-year follow up after complete circumcision. *J Urol* 1994;152:987-9.
- Kizer WS, Prarie T, Morey AF. Balanitis xerotica obliterans: Epidemiologic distribution in an equal access health care system. *S Med J* 2003;96:9-11.
- Das S, Tunuguntla HS. Balanitis xerotica obliterans - A review. *World J Urol* 2000;18:382-7.
- Pugliese JM, Morey AF, Peterson AC. Lichen sclerosis: Review of the literature and current recommendations for management. *J Urol* 2007;178:2268-76.
- Kiss A, Csontai A, Pirót L, Nyirády P, Merksz M, Király L, *et al.* The response of balanitis xerotica obliterans to local steroid application compared with placebo in children. *J Urol* 2001;165:219-20.
- Val I, Almeida G. An overview of lichen sclerosis. *Clin Obstet Gynecol* 2005;48:808-17.
- Kyriakou A, Patsialas C, Patsatsi A, Sotiriadis D. Treatment of male genital lichen sclerosis with clobetasol propionate and maintenance with either methylprednisolone aceponate or tacrolimus: A retrospective study. *J Dermatolog Treat* 2013;24:431-4.
- Ebert AK, Rösch WH, Vogt T. Safety and tolerability of adjuvant topical tacrolimus treatment in boys with lichen sclerosis: A prospective phase 2 study. *Eur Urol* 2008;54:932-7.
- Hengge UR, Krause W, Hofmann H, Stadler R, Gross G, Meurer M, *et al.* Multicentre, phase II trial on the safety and efficacy of topical tacrolimus ointment for the treatment of lichen sclerosis. *Br J Dermatol* 2006;155:1021-8.
- Heyns CF, Steenkamp JW, De Kock ML, Whitaker P. Treatment of male urethral strictures: Is repeated dilation or internal urethrotomy useful? *J Urol* 1998;160:356-8.

22. Dubey D, Sehgal A, Srivastava A, Mandhani A, Kapoor R, Kumar A, *et al.* Buccal mucosal urethroplasty for balanitis xerotica obliterans related urethral strictures: The outcome of 1 and 2-stage techniques. *J Urol* 2005;173:463-6.
23. Kulkarni S, Barbagli G, Kirpekar D, Mirri F, Lazzeri M. Lichen sclerosus of the male genitalia and urethra: Surgical options and results in a multicenter international experience with 215 patients. *Eur Urol* 2009;55:945-54.
24. Venn SN, Mundy AR. Urethroplasty for balanitis xerotica obliterans. *Br J Urol* 1998;81:735-7.
25. Virasoro R, Eltahawy EA, Jordan GH. Long-term follow-up for reconstruction of strictures of the fossa navicularis with a single technique. *BJU Int* 2007;100:1143-5.
26. Akyüz M, Güneş M, Koca O, Sertkaya Z, Kanberoğlu H, Karaman Mİ, *et al.* Evaluation of intraoral complications of buccal mucosa graft in augmentation urethroplasty. *Turk J Urol* 2014;40:156-60.
27. Al-Qudah HS, Santucci RA. Extended complications of Urethroplasty. *Int Braz J Urol* 2005;31:315-25.
28. Mondal S, Bandyopadhyay A, Mandal MM, Pal DK. Erectile dysfunction in anterior urethral strictures after arthroplasty with reference to vascular parameters. *Med J Armed Forces India* 2016;72:344-9.
29. Rosemberg SK, Jacobs H. Continuous wave carbon dioxide treatment of balanitis xerotica obliterans. *Urology* 1982;19:539-41.
30. Ratz JL. Carbon dioxide laser treatment of balanitis xerotica obliterans. *J Am Acad Dermatol* 1984;10:925-8.
31. Hrebinko RL. Circumferential laser vaporization for severe meatal stenosis secondary to balanitis xerotica obliterans. *J Urol* 1996;156:1735-6.
32. Windahl T, Hellsten S. Carbon dioxide laser treatment of lichen sclerosus et atrophicus. *J Urol* 1993;150:868-70.

How to cite this article: Dey RK, Khan I, Khan D. Study of Intraurethral Instillation of Tacrolimus for Urethral Involvement Following Lichen Sclerosus. *Int J Sci Stud* 2017;5(4):204-208.

Source of Support: Nil, **Conflict of Interest:** None declared.