

# Supernumerary Teeth in Maxillary Anterior Region: Report of Three Cases and Their Management

Sonu Acharya

Reader, Department of Pedodontics and Preventive Dentistry, Institute of Dental Sciences, Siksha O Anusandhan University, Bhubaneswar, Odisha, India

## Abstract

A supernumerary tooth is one that is additional to the normal series and can be found in any region of the dental arch. Most of the supernumerary teeth are located in the anterior maxillary region. These supernumerary teeth again are classified according to their presence where they are located and form. These teeth when present may give rise to a variety of clinical problems. The detection of these teeth can be achieved by thorough clinical and radiographic examination. Their management should be done by outlining a comprehensive treatment plan. Here we are discussing three different and unique cases, which brought different presentations by the patients, and the different treatment protocols were followed in each case. The first case deals with a 9-year-old female with non-eruption of maxillary incisors. The supernumerary teeth were surgically extracted and unerupted teeth exposed. The second case reported is of a 13-year-old boy having a problem in closing of mouth because of the extra tooth in the palatal side of the maxilla. Surgical extraction of the supernumerary tooth was done to treat the case. The third case is a 13-year-old child with non-eruption of maxillary incisors since exfoliation of deciduous teeth. The supernumerary teeth were surgically removed, and the incisors repositioned orthodontically.

**Key words:** Clinical, Maxilla, Mesiodens, Supernumerary

## INTRODUCTION

Supernumerary teeth may be found by the dental practitioner as an occasional finding on a radiograph or may be the cause of an impacted tooth. They can also be found intra-orally and can be located anywhere in the mouth. These can be present as a single tooth or multiple teeth, unilaterally or bilaterally, erupted or impacted and in mandible/maxilla or both the jaws (Tables 1 and 2).<sup>1</sup> The prevalence of supernumerary teeth varies between 0.1% and 3.8% and is usually seen more in the permanent dentition.<sup>2-4</sup> A study has shown that these extra teeth are mostly located in maxillary incisor region (64.3%) with mesiodens accounting for 32.4% of such cases. In other areas supernumeraries in the maxillary third molar region (29.6%), mandibular third molar region (7.0%), mandibular premolar region

(7%), maxillary pre-molar region (4.2%) and mandibular incisor region (4.2%) accounted for the rest cases.<sup>5</sup> It was also noted that the prevalence of supernumerary teeth in the general Caucasian population ranged between 1% and 3%, with prevalence of 2.7% and 3.4% among Japanese and Hong Kong populations, respectively.<sup>6-8</sup> The low prevalence rate seen in cases of supernumerary teeth in primary dentition is because of being not taken seriously by the parents, mostly of normal shape (supplemental type), may erupt normally, and appear to be in proper alignment.<sup>9</sup> There are certain complications reported due to the presence of supernumerary teeth that may result in the failure in the eruption of adjacent permanent incisors.<sup>10</sup> Problems associated with supernumerary teeth are a failure of eruption,<sup>11</sup> displacement of permanent teeth,<sup>12</sup> crowding,<sup>13</sup> formation of the cyst,<sup>14</sup> compromise on implant site or it may be asymptomatic.<sup>15,16</sup> Early diagnosis of the presence and removal of supernumerary teeth is essential. The treatment is dependent on the type and position of the supernumerary tooth as well as its effect on adjacent teeth (Table 3). There are chances of delayed eruption of maxillary incisors due to the presence of supernumerary tooth or teeth.<sup>11</sup> After the removal of

Access this article online



www.ijss-sn.com

**Month of Submission :** 04-2015  
**Month of Peer Review :** 05-2015  
**Month of Acceptance :** 05-2015  
**Month of Publishing :** 06-2015

**Corresponding Author:** Dr. Sonu Acharya, Reader, Department of Pedodontics and Preventive Dentistry, Institute of Dental Sciences, Siksha O Anusandhan University, Bhubaneswar - 751 003, Odisha, India. Phone: +91-9937793095. E-mail: sonu\_ain@yahoo.com

**Table 1: Supernumerary teeth based on location**

Mesiodens	Located between maxillary central incisors (pre-maxillary regions)
Paramolar	Buccally/lingually or palatally in between 2 <sup>nd</sup> and 3 <sup>rd</sup> maxillary molars, rarely in between 1 <sup>st</sup> and 2 <sup>nd</sup> maxillary molars
Distomolar	Distal or distolingual to 3 <sup>rd</sup> molars (maxillary or mandibular, in mandibular often impacted)
Parapremolar	Additional tooth in premolar region
Paramolar root	Additional root often in mandibular molar
Paramolar tubercle	Additional cusp present on buccal surface of a permanent molar  <i>Parastyle</i> , if additional cusp is present in maxillary molar  <i>Protostylid</i> , if additional cusp is present in mandibular molar

**Table 2: Supernumerary teeth based on morphology**

Morphology	Appearance
Conical	Small/peg shaped tooth with conical root
Tuberculate	Barrel shaped crown with rudimentary root, often paired
Supplemental	Duplication of tooth in normal series (often in deciduous dentition and in permanent maxillary lateral incisors and mandibular premolars)
Odontome	No regular shape, disorganized diffuse mass of dental tissue

**Table 3: Supernumerary teeth based on eruption and orientation**

Supernumerary teeth according to eruption	Supernumerary teeth according to orientation
Erupted: Complete coronal aspect is seen in oral cavity clinically	Vertical: Oriented as normal series of dentition
Partially erupted: Only occlusal part is visible	Inverted: Upside down
Impacted: Cannot be seen in oral cavity clinically, can only be diagnosed using radiographs	Transverse: Horizontally placed

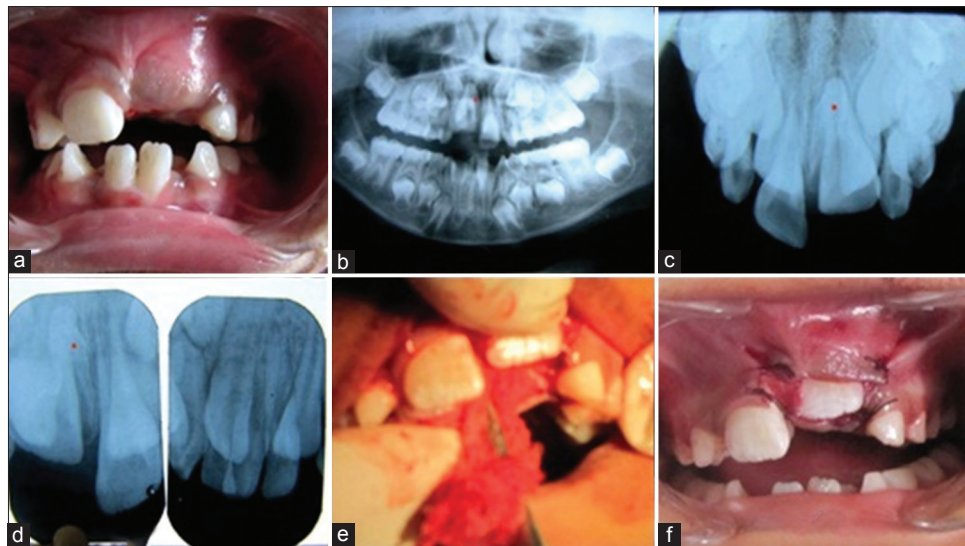
the obstacle from the path of eruption of incisors they erupt normally or sometimes they have to be extruded with the help of orthodontic forces.<sup>12</sup> Management in each case is varied, multiple supernumerary teeth present a challenge to the surgeon, and their effects create unusual orthodontic problems. The clinician is therefore, reminded always to take appropriate radiographs prior to orthodontic treatment to rule out, among other things, the presence of supernumerary teeth. It has been shown that premolars, both in the normal series and supernumeraries, may develop later than their usual anticipated times. This, therefore, means that radiographs should also be taken at some appropriate time during and after orthodontic treatment in children. Appropriate management of multiple supernumerary teeth requires careful planning and practitioners encountering this phenomenon are

advised to seek appropriate interdisciplinary opinion to enable formulation of the best possible treatment plan for the patient. Here we discuss three cases of complications caused due to supernumerary teeth and their management either surgically or combined surgical and orthodontic interventions. The basic purpose of the case reports is to make the clinicians aware of the complications, which may arise from the supernumerary teeth and their management. Most of the cases require us to extract these teeth as soon as they are detected. An immediate surgical removal is indicated after diagnosis as inter- or post-operative complications are less likely to be encountered. However, when unerupted teeth are without symptoms, do not appear to affect dentition in any way, it is best to be left in place and kept under observation. The following disadvantages might be encountered following deferred surgical plan, which includes loss of eruptive force of adjacent teeth, loss of space and crowding of the affected arch, and possible midline shifts.

## CASE REPORTS

### Case 1

A 9-year-old female child visited the Department of Pedodontics and Preventive Dentistry with a complaint of no eruption of the upper left front tooth (Figure 1a). The child was asymptomatic and medically fit. Oral examination of this child revealed unerupted upper left central incisor along with non-eruption of lateral incisors on the same side. Central and lateral incisors of the right side were in different stages of the eruption. The patient had mixed dentition with other permanent teeth in various stages of the eruption. The parents of the child were worried about the non-eruption of teeth as well as the esthetic appearance of the child. The orthopantomograph (Figure 1b) revealed the presence supernumerary tooth. The occlusal view (Figure 1c) and intra-oral periapical radiographs (Figure 1d) confirmed the presence of an inverted supernumerary tooth between both the central incisors. Here we would like to add that although patient had orthopantomograph we advised maxillary occlusal view and peri-apical radiographs for accurate localization of supernumerary teeth which will benefit both the clinician, as it reduces the surgical time, as well as the patient, as it is less traumatic for patient. The major limitation of a single radiograph is its relative inability to demonstrate the relationship of two objects that are either side by side or superimposed. It is difficult to determine whether both are in the middle of the bone or buccal or lingual to each other. The supernumerary tooth was blocking the path of eruption of both central and lateral incisor of the left side. It was decided to remove surgically the supernumerary and thus facilitate the eruption of the incisor teeth. Informed consent was



**Figure 1: (a) Unerupted left central incisor (b) Orthopantomograph showing the supernumerary teeth (c) Occlusal view, (d) Intra-oral periapical radiograph (e) Surgical exposure of central incisor (f) Post-operative**

taken from the parents. A palatal approach was planned to expose surgically (Figure 1e) the incisors and remove the supernumerary tooth after clinical and radiographic examination. Full thickness palatal flap was raised, and both incisors were exposed. Removal of bone with a round bur revealed the presence of supernumerary tooth which was extracted. Sutures were placed so as to expose both the incisors. The post-operative healing (Figure 1f) was asymptomatic and patient was healthy and happy. In this case, the complication elicited by supernumerary tooth was of non-eruption of permanent teeth and the change in the esthetic appearance of the child. The child also had a huge psychological impact as she was not able to talk and smile properly as reported by the parents. The child patient at this age is vulnerable to peer pressure and worried about their looks. Hence, the anterior teeth when not erupted till the long period of time usually causes the children to become shy and has an impact on his/her psychological makeup. The clinicians have to remove therefore the supernumerary teeth to facilitate the early eruption of anterior permanent teeth.

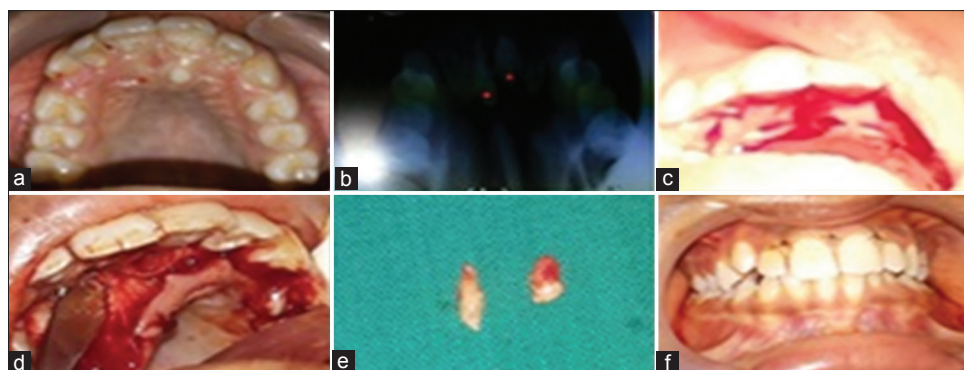
### Case 2

A 13-year-old male child reported to the department of pedodontics and preventive dentistry with complain of inability to close mouth and chew properly because of the extra tooth in the upper front region. The child was healthy and asymptomatic. Thorough oral and clinical examination revealed the presence of a supernumerary tooth at the palatal aspect behind the incisors (Figure 2a). The patient had a permanent set of teeth. On complete closure of both the jaws it was seen that the lower central incisors were in contact with the supernumerary tooth due to which the child was unable to close the mouth. The maxillary occlusal

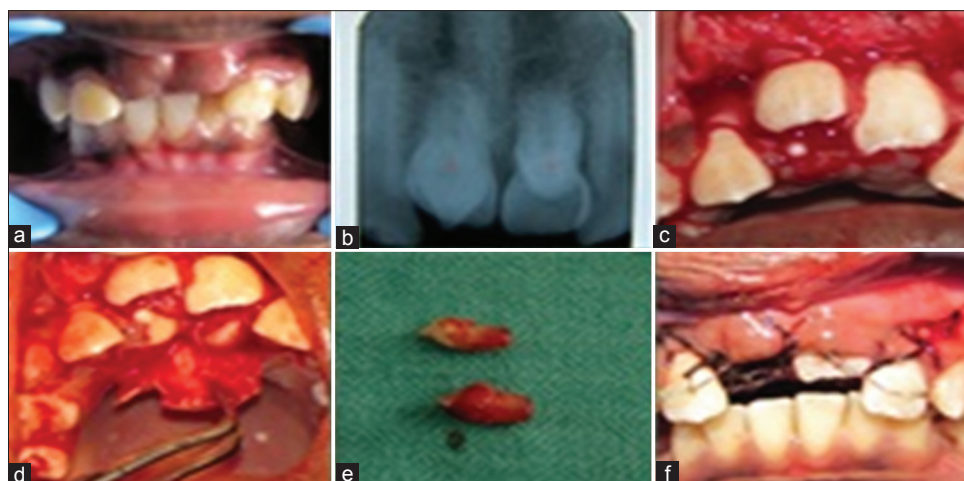
view (Figure 2b) radiographs revealed the presence of another supernumerary apart from the one seen clinically. Orthopantomograph also confirmed the presence of two supernumerary teeth. After routine blood investigations and taking informed consent from the parents of the child, it was decided to remove the supernumerary teeth causing complications. A palatal approach was taken to raise the flap and expose the supernumerary teeth (Figure 2c and d). Both the supernumerary teeth were surgically delivered (Figure 2e) and flap was repositioned in place with sutures. Post-operative healing was asymptomatic (Figure 2f) and child remained healthy and in good spirits.

### Case 3

A 13-year-old male patient came to the department of pediatric dentistry with the complaint of unerupted upper front teeth since the exfoliation of milk teeth. The patient had all other permanent teeth present for his age. There was no significant medical history. On visual examination (Figure 3a) and palpation a bulge was felt in the central incisors area confirming the presence of permanent teeth. Intra-oral peri apical radiographs (Figure 3b) revealed the presence of two conical supernumerary teeth. Routine blood investigations were advised. The parents of the child were explained about the supernumerary teeth and informed consent taken from them to proceed for the procedure. After proper local anesthesia, full thickness labial (Figure 3c) and lingual flaps were raised from maxillary right canine to the maxillary left canine regions. The crowns of maxillary right and left central incisors were seen after raising the labial flap, but the supernumerary were only visible after palatal flap (Figure 3d) with little bone removal was done. After an adequate bone removal, extraction of supernumerary teeth (Figure 3e) was done. At



**Figure 2: (a) Pre-operative view (b) Occlusal view confirms two supernumeraries (c) Incision made, (d) Flap raised (e) Surgically removed supernumerary teeth (f) Post-operative**



**Figure 3: (a) Pre-operative (b) Intra-oral radiograph showing two supernumerary teeth (c) Flap raised, (d) Supernumerary teeth exposed (e) Teeth removed (f) Traction by orthodontic wires**

the same appointment, it was decided to use orthodontic force to extrude the incisor teeth. Begg's brackets were placed and orthodontic traction (very light force at about 60-90 g) was given with the help of arch wire as elastics (Figure 3f). The teeth came into alignment within 2 months. Here in this case, we applied light orthodontic forces as the root completion had taken place, and we could have utilized the eruptive forces which is usually seen with young permanent teeth with incomplete roots.

## DISCUSSION

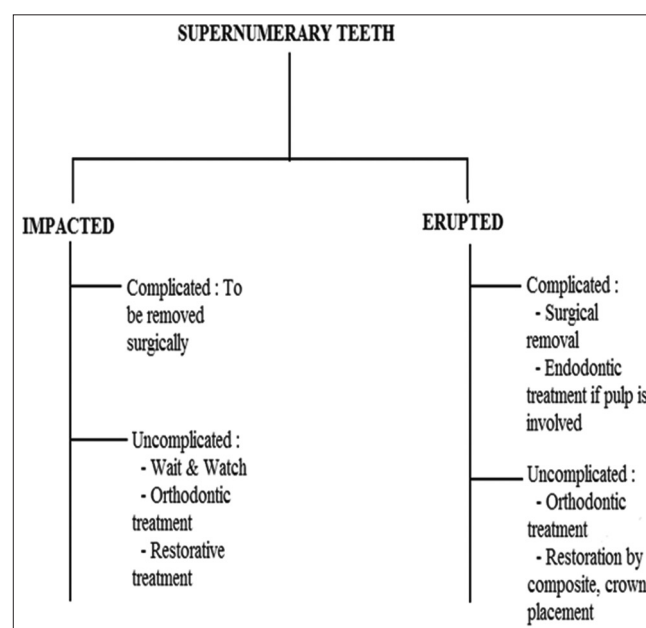
The etiology of these excess teeth is still not understood. Numerous factors can interfere with their formation. Few authors have reported that tooth anomalies can result from a complex interplay of genetic factors and developmental processes.<sup>1</sup> One interesting theory, suggests that the local and independent hyperactivity of dental lamina results in an excessive proliferation of cells, which results in the formation of extra tooth buds.<sup>17</sup> The most important step in the management of supernumerary tooth is to identify the complications associated with supernumeraries. These

extra teeth can be localized using the intra-oral radiographs of varied methods. A periapical radiograph utilizing the paralleling technique gives the best localization compared to other radiographic views. If teeth are causing no complications and are not likely to interfere with tooth movement they can be monitored with only radiographic review. The supernumerary teeth can cause many complications such as prevention and delay in eruption of associated permanent teeth, displacement or rotation of permanent teeth, crowding, incomplete space closure during orthodontic treatment, dilaceration, delayed root development of adjacent teeth, formation of cysts etc.<sup>18</sup> In our cases also the first and third case reported had come to clinic with complaint of non-eruption of anterior teeth as reported in other cases too,<sup>18</sup> similarly second case came to us with complain of non-closure of mouth properly. The patient should be warned of complications of varied nature like cystic changes and migration of roots. If the patient does not want such complications, it is advisable to remove supernumerary teeth. If supernumerary teeth are associated with complications, it is usual to extract such teeth, which usually involves a minor oral surgical

procedure.<sup>11</sup> Early extraction of supernumerary teeth, causing incisor impaction, may have the benefit of minimizing loss of eruptive potential, space loss and center line displacement. Even in those cases where the un-erupted incisors are severely rotated, it is seen that removal of the causative supernumerary tooth can result in self-correction and correct alignment.<sup>18</sup> The greatest concern with early removal is the risk of affecting the formation of adjacent roots. In addition, a young child may not be able to tolerate such a procedure and may develop a dental phobia. In the presented cases, there was a low risk of iatrogenic damage to adjacent permanent incisors root according to the clinical and radiographic findings since root development of the central incisors was complete. Furthermore, the surgical procedure was simple; patients were cooperative and are more receptive to surgical management under local anesthesia and thus easier to manage. However, delayed eruption of maxillary central incisors can result in mesial movement of the lateral incisors, space loss and diminished development of dentoalveolar height. Furthermore, in situations where a supernumerary tooth is preventing the eruption of an incisor, the eruptive potential of the incisor may be lost if intervention is delayed. Following the removal of supernumerary teeth the un-erupted teeth usually erupts faster. The surgical removal of supernumerary teeth should be performed very carefully to avoid damage to the underlying permanent teeth, which might lead to ankylosis, displacement, rotation, and ectopic position. It also has been stated that the clinician should be cautious to prevent possible complications to blood vessels and the damaging of nerves during the manipulation of the tooth, fracture of the maxillary tuberosity, perforation of the maxillary sinus, the pterygomaxillary space, and the orbit. Clinicians should also pay more attention to the possibility of supernumerary teeth being fused with the adjacent tooth structure at the crown or root level, which may make the extraction difficult. Supernumerary teeth can also be kept under observation without extraction when satisfactory eruption of related teeth has occurred with no associated pathology, but most of the researchers<sup>18-20</sup> have opined that the extraction of erupted supernumerary teeth in almost all cases except in those patients who had missing teeth. Up to 91% of impacted permanent incisors erupt within 18 months following removal.<sup>21</sup> The patient's age and the availability of space in the dental arch are the two critical factors in determining whether spontaneous eruption occurs following the removal of a supernumerary tooth. In our case too spontaneous eruption occurred in one case as the patient was young but in other case (case 3) we had to take help of orthodontic traction which is also similar to cases reported in literature.<sup>22-24</sup> In all our cases, we performed extractions to alleviate

the problems associated with these supernumerary teeth (Figure 4). The treatment depends on respective cases. These extra teeth may remain clinically symptomless and may be a chance finding or may cause complications. Unless a supernumerary tooth causes complications, it is best to follow a wait and watch procedure rather than trying to extract these teeth.<sup>25</sup> Two methods are followed for extraction of mesiodens; either early extraction before root formation of the permanent incisors or late extraction after root formation of the permanent incisors.<sup>26</sup> Some authors recommend extraction of mesiodens in the early mixed dentition in order to facilitate spontaneous eruption and alignment of the incisors.<sup>27</sup> In our cases also we saw that delay in the extraction of supernumerary teeth caused complications of non-eruption of permanent teeth. If indicated for extraction various anatomical structures in the vicinity of the supernumerary teeth have to be considered before extraction so that no complications arise later. Some authors have mentioned a decision support system for the extraction of these teeth.<sup>28</sup> In each of the cases discussed here, the authors have utilized sufficient caution while removing the supernumerary teeth so as to make the removal without post-operative complications.

**Clinical significance:** Treatment of hyperdontia depends on the respective case. In all the cases of our patients, supernumerary tooth extraction was performed. In the permanent dentition with regard to the possible complications, it is advisable to remove supernumerary teeth, including those not erupted. In cases of normal eruption and settings of supernumerary teeth, when they do not cause disturbances of the arch regularity it is possible to ignore from this rule.



**Figure 4: Treatment options for supernumerary teeth<sup>15</sup>**

## CONCLUSION

Supernumerary teeth are relatively less common but can lead to varied complications. The clinician should be able to recognize the signs as early as possible suggesting the presence of supernumerary teeth, particularly those that cause problems in eruption as seen with our presented cases, and perform the relevant investigations and treatment. On being able to diagnose such cases, each case has to be dealt in best possible way and to allay the apprehensions of parents about the complications they can create.

## REFERENCES

1. Tyrologou S, Koch G, Kuroi J. Location, complications and treatment of mesiodentes – A retrospective study in children. *Swed Dent J* 2005;29:1-9.
2. Yusof WZ. Non-syndrome multiple supernumerary teeth: Literature review. *J Can Dent Assoc* 1990;56:147-9.
3. De Oliveira Gomes C, Drummond SN, Jham BC, Abdo EN, Mesquita RA. A survey of 460 supernumerary teeth in Brazilian children and adolescents. *Int J Paediatr Dent* 2008;18:98-106.
4. Ng'ang'a PM, Ng'ang'a RN. Supernumerary teeth in a population of 8-15 year-old orthodontic patients in Kenya. *Afr J Oral Health Sci* 2000;1:16-8.
5. Scheiner MA, Sampson WJ. Supernumerary teeth: A review of the literature and four case reports. *Aust Dent J* 1997;42:160-5.
6. Cherrick HM. Radiology in the diagnosis of oral pathology in children. *Pediatr Dent* 1982;3:424.
7. Niswander JD, Sujaku C. Congenital anomalies of teeth in Japanese children. *Am J Phys Anthropol* 1963;21:569-74.
8. Davis PJ. Hypodontia and hyperdontia of permanent teeth in Hong Kong schoolchildren. *Community Dent Oral Epidemiol* 1987;15:218-20.
9. Rajab LD, Hamdan, MA. Supernumerary teeth: Review of the literature and a survey of 152 cases. *Int J Paediatr Dent* 2002;12:244-54.
10. Garvey MT, Barry HJ, Blake M. Supernumerary teeth – An overview of classification, diagnosis and management. *J Can Dent Assoc* 1999;65:612-6.
11. Welbury RR, Duggal MS, Hosey MT. *Paediatric Dentistry*. 3rd ed. Oxford: Oxford University Press; 2005.
12. von Arx T. Anterior maxillary supernumerary teeth: A clinical and radiographic study. *Aust Dent J* 1992;37:189-95.
13. Khalaf K, Robinson DL, Elcock C, Smith RN, Brook AH. Tooth size in patients with supernumerary teeth and a control group measured by image analysis system. *Arch Oral Biol* 2005;50:243-8.
14. Primosch RE. Anterior supernumerary teeth – assessment and surgical intervention in children. *Pediatr Dent* 1981;3:204-15.
15. Parolia A, Kundabala M, Dahal M, Mohan M, Thomas MS. Management of supernumerary teeth. *J Conserv Dent* 2011;14:221-4.
16. Ashkenazi M, Greenberg BP, Chodik G, Rakocz M. Postoperative prognosis of unerupted teeth after removal of supernumerary teeth or odontomas. *Am J Orthod Dentofacial Orthop* 2007;131:614-9.
17. Liu JF. Characteristics of premaxillary supernumerary teeth: A survey of 112 cases. *ASDC J Dent Child* 1995;62:262-5.
18. Shah A, Gill DS, Tredwin C, Naini FB. Diagnosis and management of supernumerary teeth. *Dent Update* 2008;35:510-2.
19. Ramesh K, Venkataraghavan K, Kunjappan S, Ramesh M. Mesiodens: A clinical and radiographic study of 82 teeth in 55 children below 14 years. *J Pharm Bioallied Sci* 2013;5:S60-2.
20. Mallineni SK, Nuvvula S. Management of supernumerary teeth in children: A narrative overview of published literature. *J Craniomaxillofac Dis* 2015;4:62-8.
21. Leyland L, Batra P, Wong F, Llewelyn R. A retrospective evaluation of the eruption of impacted permanent incisors after extraction of supernumerary teeth. *J Clin Pediatr Dent* 2006;30:225-31.
22. Kocadereli I, Turgut MD. Surgical and orthodontic treatment of an impacted permanent incisor: Case report. *Dent Traumatol* 2005;21:234-9.
23. Das D, Misra J. Surgical management of impacted incisors in associate with supernumerary teeth: A combine case report of spontaneous eruption and orthodontic extrusion. *J Indian Soc Pedod Prev Dent* 2012;30:329-32.
24. Yeluri R, Hegde M, Baliga S, Munshi AK. Multiple supernumerary teeth associated with an impacted maxillary central incisor: Surgical and orthodontic management. *Contemp Clin Dent* 2012;3:219-22.
25. Proff P, Fanghänel J, Allegrini S Jr, Bayerlein T, Gedrange T. Problems of supernumerary teeth, hyperdontia or dentes supernumerarii. *Ann Anat* 2006;188:163-9.
26. Alaçam A, Bani M. Mesiodens as a risk factor in treatment of trauma cases. *Dent Traumatol* 2009;25:e25-31.
27. Meighani G, Pakdaman A. Diagnosis and management of supernumerary (mesiodens): A review of the literature. *J Dent (Tehran)* 2010;7:41-9.
28. Amarlal D, Muthu MS. Supernumerary teeth: Review of literature and decision support system. *Indian J Dent Res* 2013;24:117-22.

**How to cite this article:** Acharya S. Supernumerary Teeth in Maxillary Anterior Region: Report of Three Cases and Their Management. *Int J Sci Stud* 2015;3(3). *Int J Sci Stud* 2015;3(3):122-127.

**Source of Support:** Nil, **Conflict of Interest:** None declared.