

Eyelid Cutaneous Sebaceous Horn: A Rare and Interesting Case Report

H R Padmini¹, Nidhi Pandey²

¹Professor and Head, Department of Ophthalmology, Adichunchanagiri Institute of Medical Sciences, Mandya, Karnataka, India,

²Post Graduate, Department of Ophthalmology, Adichunchanagiri Institute of Medical Sciences, Mandya, Karnataka, India

Abstract

Cutaneous horn also known by Latin name "Cornu cutaneum" are unusual tumors appearing like an animal horn. It is relatively rare conical tumor affecting mostly the elderly male population and often arising from the sun-exposed areas of skin. The important issue is not the horn itself which is a dead keratin, but rather its coalition with or as a reaction to a wide variety of underlying benign, premalignant and malignant skin diseases. Although often benign it is mandatory to determine the nature of the disease at the base of the lesion to rule out malignancy. Surgery is the treatment of choice. Here we report a rare case of cutaneous horn in 65-year-old elderly male, overlying a seborrheic keratosis of the left upper eyelid treated with surgical excision and primary closure of the wound.

Key words: Carcinoma, Cutaneous horn, Sebaceous cyst, Seborrheic keratosis, Squamous cell, Stratum corneum

INTRODUCTION

Cutaneous horn (cornu cutaneum)¹ is a relatively uncommon lesion consisting of projectile, conical, dense, hyperkeratotic nodule, which resembles the horn of an animal but lacks the bone core. They are most common in Caucasians¹ and relatively less common in Arabic, Asian and rare in African descent.¹ The horn is a conical projection of hyperkeratotic epidermis composed of compact keratin. The cause of cutaneous horn² is still unknown, but the racial tendency can be endorsed to the relative protection of pigmented skin from ultraviolet rays. It arises on mostly sun-exposed areas of body as, UV rays triggers the condition, which is evidenced by higher rate of cases occurring on face, pinna, nose, dorsal forearms, scalp that are often exposed to UV rays. It can occur over chest and penis. Most of them have yellow - white color, they may be straight, curved or twisted.³ They are usually small, localized but in very rare case be much larger. They are thought to result from underlying benign, premalignant,

malignant pathology. Because of their malignant potential, the lesions must always be considered for histopathological evaluation.

CASE REPORT

A 65-year-old male farmer presented with a solitary firm horn like slow growing projective growth on the outer lateral marginal part of the left upper eyelid for the last 3 years duration.² Initially, patient noticed a small itchy, hyperpigmented nodular swelling over lateral 1/3 of the left upper eyelid about 2 years ago which gradually progressed to present horny growth over the swelling. There was no history of pain or discharge from swelling. There was no regional lymphadenopathy. The patient had a history of long term sun-exposure due to farming activities.

A detailed clinical examination demonstrated a cone shaped hyperkeratotic growth measuring (1 * 1) cm in size, arising over a lichenified plaque over the outer 1/3rd of the left upper eyebrow (Figure 1). It was mimicking a horn. There was no tenderness, discharge or bleeding from the swelling and no regional lymphadenopathy. A clinical diagnosis of solitary cutaneous sebaceous horn overlying hyperkeratotic sebaceous cyst was made. Complete excision of it with horizontal incision and primary closure of the defect with vicryl (6,0) was done

Access this article online



www.ijss-sn.com

Month of Submission : 04-2015
Month of Peer Review : 05-2015
Month of Acceptance : 05-2015
Month of Publishing : 06-2015

Corresponding Author: Dr. Nidhi Pandey, Department of Ophthalmology, Adichunchanagiri Medical College, Mandya, Karnataka 571448, India. E-mail: dr.nidhipandey@yahoo.in

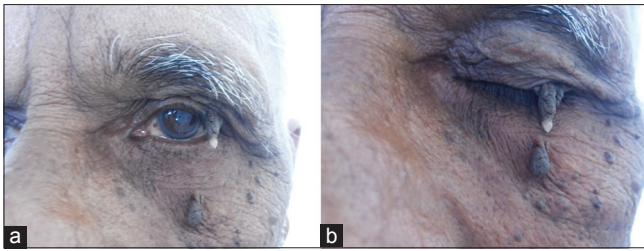


Figure 1: (a and b) Sebaceous cutaneous horn over lateral 1/3rd of left upper eyelid

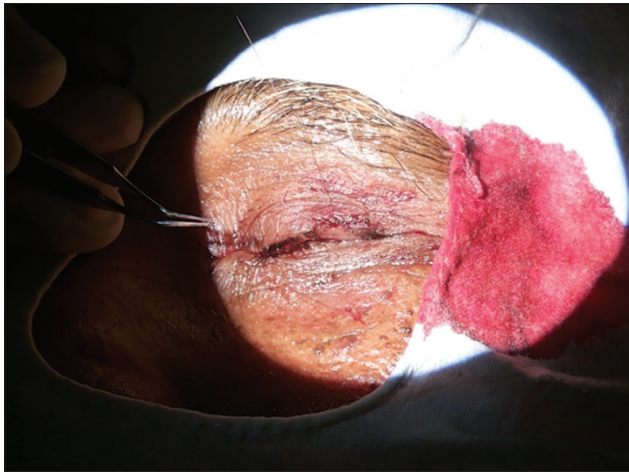


Figure 2: Excision of the horn with primary closure of the wound

under local anesthesia (Figure 2). Specimen was evaluated microscopically (Figure 3), which revealed concentric layers of cornified epithelial cells along with sebaceous cyst, areas of hyperkeratosis, parakeratosis, elongated rete pegs with chronic inflammatory cell infiltration in dermis.³ All these features were suggestive of cutaneous horn over seborrheic keratosis (Figure 4). Associated lesions was found in the left lower eyelid too including viral warts, actinic keratosis. Swelling of the viral wart was removed simultaneously with the horn. On follow-up, patient had an uneventful course with no scar formation and no clinical relapse (Figure 5).

DISCUSSION

Cutaneous horns¹ are elongated, keratinous, projections from the skin consisting of cornified material resembling an animal horn frequently occurring in rhinoceros, birds but uncommon in humans. An animal horn is composed of superficial hyperkeratotic epidermis, dermis with centrally positioned bone unlikely a human cutaneous sebaceous horn which is composed of compacted keratin with the base comprising of flat, nodular or crateriform seborrheic keratosis or actinic keratosis lesion commonly. The earliest well-documented case of cornu cutaneum²

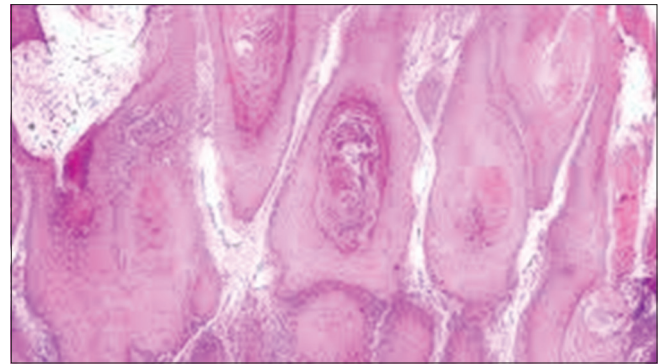


Figure 3: Histopathology of the specimen horn showing concentric layers of cornified epithelial cells



Figure 4: Excised specimen of keratin horn

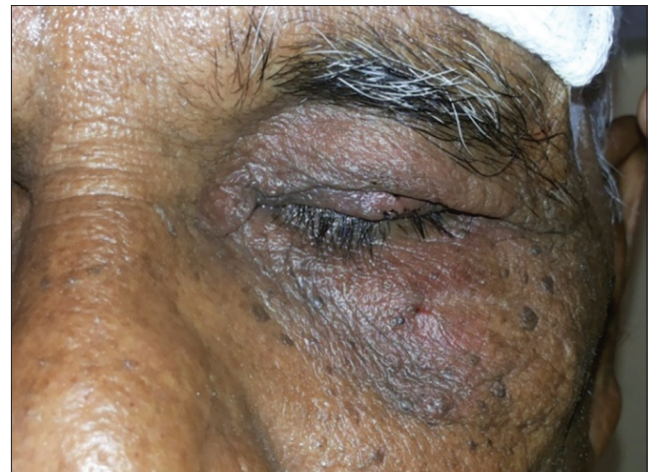


Figure 5: Post-op follow-up of patient which was uneventful with no scar formation

was reported from London in 1588 of an elderly Welsh woman. Cutaneous horns³ are classified into four varieties: Sebaceous horns, wart horns, cicatrix horns and nail horns. (1) Sebaceous horns arise from sebaceous cyst commonly on scalp; (2) Wart horns closely resembles sebaceous horns and arise from chest or penis; (3) Cicatrix horns are rare and grow from post burn; (4) Nail horns grow from big

toenail in unattended patients. Sebaceous horns of eyelid is desiccated secretions from the orifice of the sebaceous cyst (as in our case). The cutaneous horn usually occurs over sunexposed areas of the body, particularly face, eyelid, scalp, pinna, nose, forearm and dorsal aspect of the hand. They may also develop over areas not exposed to sunlight such as mucosal lower lip, chest, nasal vestibule, and penis.

In the study performed on 48 cases of eyelid horns which is very rare, by Mencia Gutierrez *et al.*³ (61.6%) horns are benign lesions, (23.2%) of them are premalignant, (15.7%) are caused due to malignant lesion lying below it. Squamous cell carcinoma is most commonly associated with horn. The important consideration is not horn but the underlying pathology and associated conditions, which may be benign (seborrheic keratosis, viral warts, histiocytoma, inverted follicular keratosis, verrucous epidermal nevus, molluscum contagiosum, actinic keratosis, keratoacanthoma, etc.), premalignant (Solar keratosis, arsenical keratosis, Bowen's disease) or malignant (squamous cell carcinoma, rarely basal cell carcinoma, granular cell carcinoma, Kaposi sarcoma). Pain, basal tenderness, and large size are common features of malignancy. Histopathologically there are thickened stratum corneum with scattered areas of parakeratosis.^{4,5} The base of horn displays the characteristic features of the pathologic process responsible for it. Treatment depends on type of lesion and its malignant potential. Excision biopsy of the lesion including base and histopathological

examination to rule out malignancy is mandatory. Complete removal of horn with curettage, down to normal tissue gives satisfactory result as in our case. Split skin graft can be used to cover big defects. Careful examination of the draining lymph nodes is done. Malignancies should be removed with appropriate margins. Other treatment options include electrocautery, cryotherapy, carbon dioxide or Nd Yag laser for the patients who refuse surgery.

CONCLUSION

Cutaneous horn as in our case was excised carefully with the closure of the defect, and histopathological examination⁴ was done to rule out malignant potential at the base of the horn.

REFERENCES

1. Oludiran OO, Ekanem VJ. Cutaneous horns in an African population. *J Cutan Aesthet Surg* 2011;4:197-200.
2. Bondeson J, Everard Home, John Hunter, Mencia Gutierrez, *et al.* Cutaneous horns: A historical review. *Am J Dermatopathol* 2001;23:362-9.
3. Michal M, Bisceglia M, Di Mattia A, Requena L, Fanburg-Smith JC, Mukensnabl P, *et al.* Gigantic cutaneous horns of the scalp: Lesions with a gross similarity to the horns of animals: A report of four cases. *Am J Surg Pathol* 2002;26:789-94.
4. Yu RC, Pryce DW, MacFarlane AW, Stewart TW. A histopathological study of 643 cutaneous horns. *Br J Dermatol* 1991;124:449-52.
5. Shanmugasundaram V. Cutaneous horn in actinic keratosis- A case report. *J Evol Med Dent Sci* 2013;2:4291-3.

How to cite this article: Padmini HR, Pandey N. Eyelid Cutaneous Sebaceous Horn: A Rare and Interesting Case Report. *Int J Sci Stud* 2015;3(3):134-136.

Source of Support: Nil, **Conflict of Interest:** None declared.